

Case Report

Internal Mammary Arterial Injury from Lead Extraction: A Clinically Subtle yet Important Complication of Implantable Device Removal

Cesar Cruz, Jonathan Langberg, Stamatios Lerakis, Ravi Veeraswamy, and Michael Lloyd

Department of Cardiology, Division of Electrophysiology, Emory University, GA 30322, USA

Correspondence should be addressed to Michael Lloyd, mlloyd2@emory.edu

Received 27 January 2011; Accepted 5 March 2011

Academic Editor: Brian Olshansky

Copyright © 2011 Cesar Cruz et al. This is an open access article distributed under the Creative Commons Attribution License, which permits unrestricted use, distribution, and reproduction in any medium, provided the original work is properly cited.

Percutaneous implantable device extraction has increased in recent years and is associated with small but significant risk. Arteriovenous fistula formation is an uncommon complication of this procedure. We report two cases where lead extraction was complicated by an arteriovenous fistula between the left internal mammary artery and the left brachiocephalic vein. In both cases, the patients were asymptomatic and the presence of a continuous murmur in the left subclavicular region led to the appropriate diagnosis. These were successfully treated with coil embolization. Auscultation around prior extraction sites should be routinely done to aid in the diagnosis of this potentially harmful complication.

1. Introduction

Percutaneous extraction of chronic implantable devices has increased in recent years. Lead extraction is associated with serious complications in 1-2% of cases [1]. In a recent multicenter prospective study of 1,449 consecutive patients undergoing laser lead extraction, procedure-related major adverse events were seen in 20 patients (1.4%) including 4 deaths (0.28%) [2]. Most complications from lead extraction are related to the difficulties encountered at freeing the lead from the surrounding scar tissue [3–5]. Life-threatening complications after lead extraction include myocardial perforation and venous laceration.

Arterial injuries from device extraction, such as arteriovenous (AV) fistula and pseudoaneurysm formation, can also occur [6–8]. Some arterial injuries may not lead to obvious symptoms and thus go unrecognized. Nonetheless, diagnosis and treatment are important to avoid eventual pseudoaneurysm rupture or the development of hemodynamically significant shunting. The most common arterial injury involves the subclavian/axillary artery due to its location adjacent to the lead insertion site. However, proximal

branches of the subclavian artery, especially those that course inferiorly towards adjacent veins such as the internal thoracic or mammary artery (IMA) are also subject to injury [9]. In this report, we present the clinical manifestations and management of two cases of AV fistula formation from LIMA to left brachiocephalic vein following lead extraction.

2. Case 1

A 29-year-old female underwent pacemaker implantation at age 15 for reported sinus node dysfunction. The method of original lead insertion by review of radiographs was subclavian venous puncture. She was referred to our facility for pacemaker extraction given ventricular lead fracture and no evidence of pacemaker use. Excimer laser (Spectranetics Inc, Colorado Springs, CO) extraction sheaths were used to remove the chronic atrial and ventricular leads. A locking stylet was unable to be advanced beyond the site of the ventricular lead fracture. In addition, scarring and calcification were present at the region between the clavicle and first rib. Despite these difficulties, both leads were removed without apparent complications.

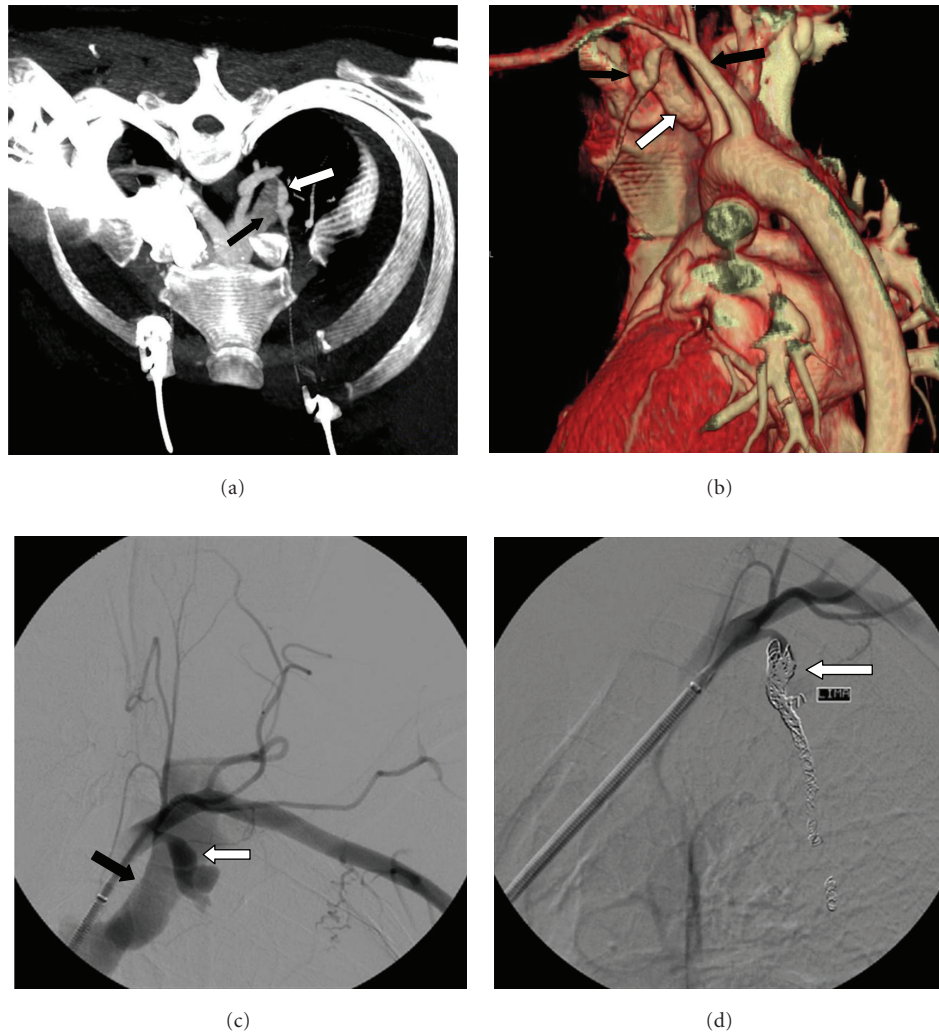


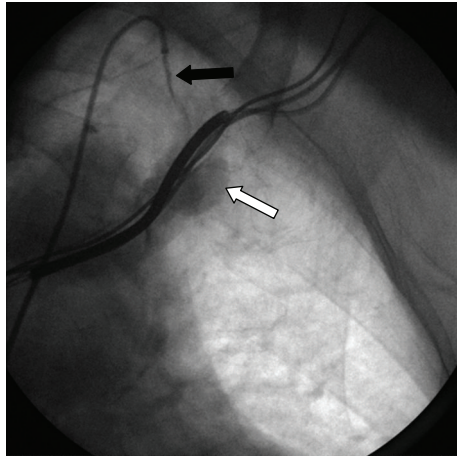
FIGURE 1: (a) Volume-rendered image showing aneurysmal dilatation of the LIMA (white arrow) fistulized with the left brachiocephalic vein (black arrow). (b) Three-dimensional reconstructed images show aneurysmal dilatation of the LIMA (small black arrow) near its origin from the subclavian artery (large black arrow) and its relationship with the left subclavian and brachiocephalic vein (white arrow). (c) Selective arteriogram of the subclavian artery demonstrating aneurysmal dilatation of proximal LIMA (white arrow) and fistulization with the left brachiocephalic vein (black arrow). (d) Successful coil embolization of LIMA (arrow) showing closure of AVF.

At followup, an asymptomatic continuous murmur was noticed over the left prepectoral region. A computed tomographic angiogram (CTA) showed an aneurysmal dilatation of the left IMA fistulized with the brachiocephalic vein (Figures 1(a) and 1(b)). Invasive angiography confirmed the presence of a fistula between the IMA and brachiocephalic vein. She underwent successful coil embolization of the IMA and aneurysm (Figures 1(c) and 1(d)).

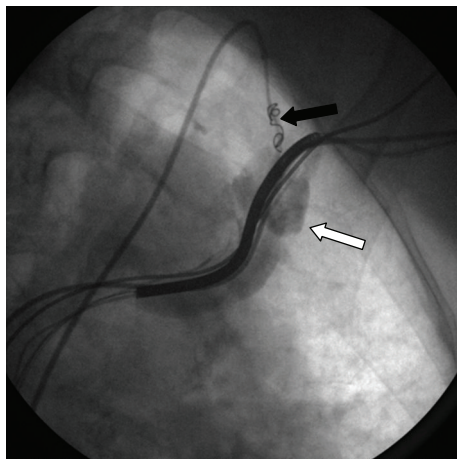
3. Case 2

An 84-year-old female with history of nonischemic dilated cardiomyopathy, high degree AV block, and previously implanted biventricular defibrillator presented for generator exchange and left ventricular (LV) lead revision for failure to capture.

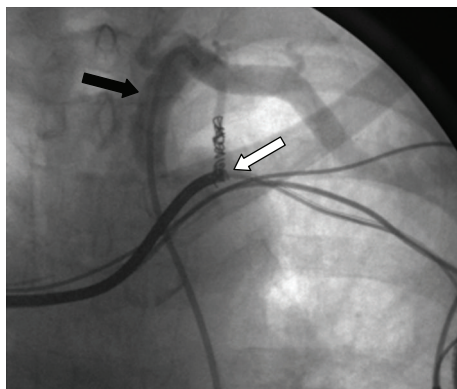
The LV lead was extracted by manual traction and replaced with a new lead with acceptable capture thresholds. Given her pacemaker dependence, a defibrillator lead on advisory for increased risk of fracture (Sprint Fidelis, Medtronic Corporation, Minneapolis, MN) was also replaced. This lead was extracted using a 14 F excimer laser sheath and locking stylet. The main obstacle to extraction was at the site of an acute angulation of the lead as it coursed between the clavicle and first rib. As in the prior case, the method of original lead insertion was by subclavian venous puncture. The following morning, a continuous murmur was noticed in the second left intercostal space. Transthoracic echo showed a small pericardial effusion but otherwise unchanged from a previous study. Angiography was performed showing a large pseudoaneurysm as well as an AV fistula joining the LIMA to the proximal subclavian vein (Figure 2(a)).



(a)



(b)



(c)

FIGURE 2: Case 2 arteriograms of the LIMA fistula with the proximal subclavian vein. Initial angiogram (a), during coil deployment (b), and final angiogram (c) showing successful closure of the AVF. (white arrows, subclavian/brachiocephalic venous system; black arrows, subclavian artery and IMA).

Despite multiple injections, the distal IMA could not be identified perhaps due to avulsion or damage, eliminating the option of placing a covered stent. Subsequently, a total of 4 coils were deployed in the proximal portion of the LIMA (Figure 2(b)). Angiogram at completion demonstrated minimal persistent flow. A week after intervention, a repeat LIMA angiogram demonstrated closure of the AV fistula (Figure 2(c)).

4. Discussion

These cases of injury to the IMA as a result of lead extraction highlight several important points. First, they illustrate that smaller branch arteries such as the IMA are vulnerable to injury and fistulization. The IMA may be particularly vulnerable due to its location. A common “problem area” that resists advancement of extraction sheaths around leads is at the region between the clavicle and first rib (Figure 3). This region is prone to cause crush damage to leads and frequently has fibrosis and calcification. Further, both cases involved leads originally inserted via subclavian vein puncture. This insertion method can cause relatively acute insertion angles at this site. These acute bends may allow extraction sheaths (in this case, laser sheaths) to deviate from their coaxial alignment increasing the risk of perforation of the venous wall and adjacent structures. Cephalic or axillary vein approaches, when feasible, may potentially decrease the risk of this complication during lead extraction.

Secondly, the clinical presentations of these arterial injuries were subtle. However, the finding of a continuous murmur in the region of the extraction site in both cases led to the proper diagnosis. This suggests that auscultation around the surgical region should be part of the evaluation after lead extraction. As in our case, the time between arterial injury and diagnosis varied widely. There is similar variation among other reports for non-IMA injury related to extraction [7, 8, 10, 11].

Finally, these cases illustrate successful evaluation and treatment of branch-artery injury. Unlike AV fistulas associated with inadvertent arterial puncture during device implantation, iatrogenic AV fistulas following lead extraction more closely resemble traumatic injury and should be evaluated and treated promptly. Traumatic vascular injuries can lead to rapid clinical deterioration, and mortality rates range from 5–30%. Delay in diagnosis and treatment increases the mortality from 2 to 4% in stable patients and from 15 to 32% in hemodynamically unstable patients [12, 13].

Endovascular approaches have been successfully used in the treatment of traumatic arterial injuries including AV fistulae and pseudoaneurysms following lead extractions. Several covered stents have been used including the Wall-graft, the Corvita, and the Jostent peripheral stent graft [14, 15]. In cases involving smaller branch arteries such as the IMA whose arterial supply can be safely sacrificed, coil embolization is another alternative.

The rapid expansion of implanted device extraction procedures in the US warrants close attention to all potential complications. In this series, we report injury and

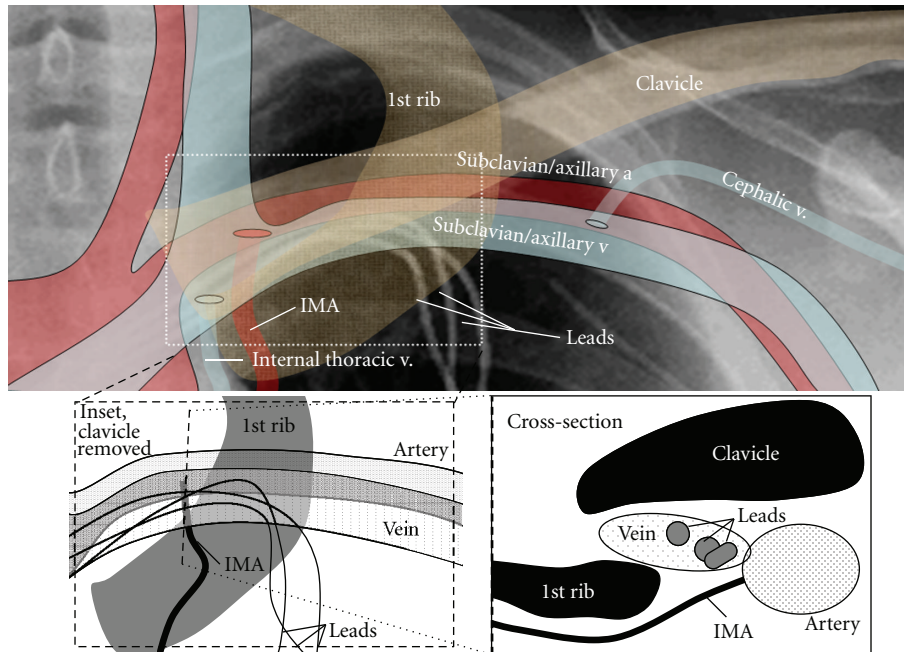


FIGURE 3: The relationship of the clavicle, first rib, IMA, and subclavian vessels is shown. A common “problem area” for extraction is the region of intersection of the clavicle and first rib (dashed white box). This region is a common site of lead insertion and can have significant fibrosis, calcification, and lead angulation (inset panel). Lead angulation is a main reason for extraction sheaths to deviate from their coaxial course and thus cause trauma to adjacent structures. A cross-section schematic at the point of IMA takeoff from the subclavian artery reveals its proximity to the adjacent vein and its potential for trauma (right lower panel).

fistulization of the IMA to adjacent veins and their successful treatment. Due to the absence of symptoms, this type of complication may go unrecognized for long periods. Routine careful auscultation around prior extraction sites is an important aid in diagnosis of this potentially harmful complication.

References

- [1] B. L. Wilkoff, C. J. Love, C. L. Byrd et al., “Transvenous lead extraction: heart rhythm society expert consensus on facilities, training, indications, and patient management. This document was endorsed by the American Heart Association (AHA),” *Heart Rhythm*, vol. 6, no. 7, pp. 1085–1104, 2009.
- [2] O. Wazni, L. M. Epstein, R. G. Carrillo et al., “Lead extraction in the contemporary setting: the LEXICON study. An observational retrospective study of consecutive laser lead extractions,” *Journal of the American College of Cardiology*, vol. 55, no. 6, pp. 579–586, 2010.
- [3] H. J. Smith, N. E. Fearnot, C. L. Byrd, B. L. Wilkoff, C. J. Love, and T. D. Sellers, “Five-years experience with intravascular lead extraction,” *Pacing and Clinical Electrophysiology*, vol. 17, no. 11, pp. 2016–2020, 1994.
- [4] M. A. Lloyd, D. L. Hayes, and D. R. Holmes Jr., “Extraction of the electronics accufix 330-801 atrial lead: the mayo clinic experience,” *Mayo Clinic Proceedings*, vol. 71, no. 3, pp. 230–234, 1996.
- [5] B. L. Wilkoff, C. L. Byrd, C. J. Love et al., “Pacemaker lead extraction with the laser sheath: results of the pacing lead extraction with the excimer sheath (PLEXES) trial,” *Journal of the American College of Cardiology*, vol. 33, no. 6, pp. 1671–1676, 1999.
- [6] R. L. Cirillo Jr. and A. B. Fontaine, “Iatrogenic brachiocephalic arteriovenous fistula: description of a fatal complication after cardiac pacemaker lead extraction,” *Journal of Vascular and Interventional Radiology*, vol. 9, no. 6, pp. 1029–1030, 1998.
- [7] N. H. Kumins, J. C. Tober, C. J. Love et al., “Arteriovenous fistulae complicating cardiac pacemaker lead extraction: recognition, evaluation, and management,” *Journal of Vascular Surgery*, vol. 32, no. 6, pp. 1225–1228, 2000.
- [8] P. Kang and D. B. Nunez Jr., “Arteriovenous fistula following pacemaker lead removal: CT diagnosis,” *Emergency Radiology*, vol. 10, no. 1, pp. 40–42, 2003.
- [9] F. A. Bracke, B. van Gelder, and A. Meijer, “Arteriovenous fistula after injury of the left internal mammary artery during extraction of pacemaker leads with a laser sheath,” *Pacing and Clinical Electrophysiology*, vol. 22, no. 5, pp. 833–834, 1999.
- [10] F. Milla, C. A. Mack, and L. N. Girardi, “Arteriovenous fistula after laser-assisted pacemaker lead extraction,” *Annals of Thoracic Surgery*, vol. 81, no. 6, pp. 2304–2306, 2006.
- [11] W. Alayadhi, S. Wang, and R. G. Williams, “Arteriovenous fistula after laser-assisted extraction of an implantable defibrillator lead,” *Interactive Cardiovascular and Thoracic Surgery*, vol. 8, no. 2, pp. 243–244, 2009.
- [12] C. Mavroudis, A. J. Roon, C. C. Baker, and A. N. Thomas, “Management of acute cervicothoracic vascular injuries,” *Journal of Thoracic and Cardiovascular Surgery*, vol. 80, no. 3, pp. 342–349, 1980.

- [13] M. Bladergroen, R. Brockman, G. Luna, T. Kohler, and K. Johansen, "A twelve-year survey of cervicothoracic vascular injuries," *American Journal of Surgery*, vol. 157, no. 5, pp. 483–486, 1989.
- [14] J. S. Lawton, M. R. Moon, J. A. Curci et al., "Management of arterial injuries caused by laser extraction of indwelling venous pacemaker and defibrillator leads," *Pacing and Clinical Electrophysiology*, vol. 29, no. 8, pp. 917–920, 2006.
- [15] K. Katsanos, T. Sabharwal, T. Carrell, R. Dourado, and A. Adam, "Peripheral endografts for the treatment of traumatic arterial injuries," *Emergency Radiology*, vol. 16, no. 3, pp. 175–184, 2009.