

# One-stage cochlear implantation via a facial recess approach in children with otitis media with effusion

Qing-Qing Hao<sup>a,1</sup>, Yan Yan<sup>a,b,1</sup>, Wei Ren<sup>a,b</sup>, Guang-Yu Xu<sup>a</sup>, Ri-Yuan Liu<sup>a</sup>, Jia-Nan Li<sup>a</sup>, Li Sun<sup>a</sup>,  
Qing-Shan Jiao<sup>a</sup>, Hui Zhao<sup>a,b,\*</sup>, Shi-Ming Yang<sup>a</sup>

<sup>a</sup> Department of Otolaryngology Head & Neck Surgery, PLA General Hospital, Beijing, 100853, China

<sup>b</sup> Department of Otolaryngology Head & Neck Surgery, Hainan Branch of PLA General Hospital, Sanya, 572000, China

## Abstract

**Objective:** To investigate surgical indications, operative techniques, complications and auditory and speech rehabilitation for cochlear implant (CI) in children with otitis media with effusion (OME).

**Material and methods:** This is a retrospective review of records of 24 children with bilateral profound sensorineural hearing loss and OME who were implanted during January 2011 to November 2014 in the Department of Otorhinolaryngology and Head and Neck Surgery at the PLA Hospital, using one-stage implantation via the facial recess approach and round window insertion. The incus was removed in 8 cases during the implantation procedure. Local infiltration of dexamethasone and adrenaline in the middle ear was also performed. Postoperative complications were examined. Preoperative and postoperative questionnaires including Categories of Auditory Performance (CAP), Speech Intelligibility Rating (SIR), and the Meaningful Auditory Integration Scale (MAIS) were collected.

**Results:** All electrodes were implanted successfully without any immediate or delayed complications. Inflammatory changes of middle ear mucosa with effusion were noted in all implanted ears. The scores of post-implant CAP and SIR increased significantly in all 24 cases ( $t = -25.95$  and  $-14.09$ , respectively for CAP and SIR,  $p < 0.05$ ).

**Conclusions:** One-stage CI via the facial recess approach with round window insertion is safe and effective in cochlear implant candidates with OME, as seen in the 24 children in our study who achieved improved auditory performance and speech intelligibility after CI.

Copyright © 2015, PLA General Hospital Department of Otolaryngology Head and Neck Surgery. Production and hosting by Elsevier (Singapore) Pte Ltd. This is an open access article under the CC BY-NC-ND license (<http://creativecommons.org/licenses/by-nc-nd/4.0/>).

**Keywords:** Cochlear implantation; Otitis media with effusion; Incus removal

## 1. Introduction

Cochlear implant (CI) is one of the most significant treatments to help restore auditory function in patients with severe to profound sensorineural hearing loss. It has become a relatively safe procedure via the well-standardized transmastoid

approach. One of the previously established contraindications for cochlea implant is chronic middle ear inflammation due to concerns of increased risk of intracranial infection and/or device extrusion (Olgun et al., 2005; Achiques et al., 2010). Recently there is mounting new evidence indicating that cochlear implants can be safely performed in patients with chronic otitis media or atelectasis (Chen et al., 2009; Sampaio et al., 2011; Migirov et al., 2006). Otitis media with effusion (OME), also called serous otitis media, is a very common childhood disease. The reported incidence is as high as 20% among children, with a peak around ages one to two years (Migirov et al., 2006; Moriniere et al., 1998; American Academy of Family Physicians et al., 2004). Cochlear implants in pediatric patients, especially those younger than 2

\* Corresponding author. Department of Otolaryngology Head & Neck Surgery, PLA General Hospital, Beijing, 100853, China.

E-mail addresses: [cleanorhao@139.com](mailto:cleanorhao@139.com) (Q.-Q. Hao), [huizhao@yeah.net](mailto:huizhao@yeah.net) (H. Zhao).

Peer review under responsibility of PLA General Hospital Department of Otolaryngology Head and Neck Surgery.

<sup>1</sup> Equal contribution.

years of age, have become increasingly common. Clinicians are often confronted with OME in the expanding population of cochlear implant candidates. Accordingly, this study aims to report our experiences with cochlear implantation in children with OME.

## 2. Material and methods

A retrospective review of 24 children (ages 11 months to 5.2 years) who underwent cochlear implantation in an ear with active OME was conducted between January 2011 to November 2014 in the Department of Otorhinolaryngology and Head and Neck Surgery, PLA Hospital, China. Study protocol was approved by the hospital's Institutional Review Board. All the 24 subjects were under 6 years of age without any residual hearing when admitted to our department as cochlear implant candidates. The candidates received a comprehensive preoperative radiological evaluation. Their radiologic findings showed middle ear and mastoid opacification with intact ossicles, indicating the presence of OME. Otoscopy found no evidence of tympanic membrane perforation. After audiological assessment, the 24 candidates were all diagnosed with bilateral profound sensorineural hearing loss without any residue hearing. All the operations were performed by the same experienced surgical team in our department. The demographic data, etiology of deafness, and surgical techniques were retrieved from medical records and summarized in Table 1.

Based on how the incus was handled, the subjects were divided into Group 1 (incus left in place,  $n = 16$ ) and Group 2 (incus removed,  $n = 8$ ).

At follow ups, complications, and auditory and speech rehabilitation outcomes were reviewed. Complications included wound infection, meningitis or other intracranial infections, cerebrospinal fluid otorrhea, post-implant perforation of tympanic membrane, device extrusion and recurrence of OME. To assess post-implant auditory function and speech recognition, a prospective questionnaire was constructed including questions from Categories of Auditory Performance (CAP) (Archbold et al., 1998), Speech Intelligibility Rating (SIR) (Allen et al., 2001) and the Meaningful Auditory Integration Scale (MAIS or infant toddler-MAIS) (Robbins et al., 1991). The composite questionnaires were administered through interviews with the parents by an audiologist. All the subjects reported daily use of the CI and attending speech therapy programs.

## 3. Surgical techniques

Based on preoperative imaging and intraoperative finding, all subjects were determined to have active OME in the implant ear at the time of CI operation. To pursue an early hearing and speech rehabilitation, all the children in our study received one-stage cochlear implant operations (one patient had an adenoidectomy procedure done 3 months before CI).

All cochlear implantations in this study were performed via the facial recess approach with round window insertion under general anesthesia. Following a retroauricular incision, approximately 3 cm in length, an intact canal wall mastoidectomy and transantrum posterior tympanotomy were

Table 1  
Demographic and clinical details of the 24 children.

Case	Gender	Age at implantation	Cause of deafness	Group	Implanted side	Cochlear device
1	Male	1 year 7 months	CHL	1	Left	24Contour
2	Female	2 years 8 months	LVAS	1	Right	Sonata
3	Female	2 years 8 months	LVAS	1	Right	C40+
4	Male	2 years 4 months	CHL	1	Right	C40+
5	Male	1 year 9 months	CHL	1	Right	C40+
6	Male	3 years 5 months	CHL	1	Right	C40+
7	Male	1 year 7 months	CHL	1	Right	Sonata
8	Male	1 year 5 months	LVAS	1	Right	24Contour
9	Male	1 year 3 months	CHL	1	Right	Freedom
10	Female	2 years 6 months	LVAS&MM	1	Right	24K
11	Female	2 years 5 months	CHL	1	Left	Freedom
12	Female	2 years 1 months	MM	1	Right	24Contour
13	Male	4 years 5 months	CHL	1	Right	Sonata
14	Female	11 months	CHL	1	Right	Sonata
15	Female	2 years 7 months	LVAS	1	Left	24Contour
16	Male	1 year 4 months	CHL	1	Right	Concerto
17	Male	1 year 7 months	LVAS	2	Right	24Contour
18	Male	1 year 8 months	CHL	2	Right	HiRes 90K
19	Female	3 years 10 months	CHL	2	Right	Freedom
20	Male	4 years 10 months	LVAS	2	Left	Freedom
21	Male	2 years 7 months	CHL	2	Right	Freedom
22	Female	5 years 2 months	LVAS	2	Left	Freedom
23	Male	1 year 7 months	MM	2	Left	Sonata
24	Female	2 years 1 months	CHL	2	Left	Freedom

CHL: Congenital Hearing Loss; LVAS: Large Vestibular Aqueduct Syndrome; MM: Mondini Malformation; Group1: Facial Recess Approach Implantation; Group2: Facial Recess Approach Implantation with Incus Removal.

Table 2  
CI characteristics and auditory speech performance scores of the 24 children.

Case	Age at follow-up	Length of deafness (month)	Length of CI use (month)	CAP		SIR		MAIS <sup>a</sup>
				Pre	Post	Pre	Post	
<i>Group1: Facial Recess Approach Implantation</i>								
1	5 years 5 months	19	44	0	7	1	5	37
2	5 years 9 months	32	35	1	6	1	4	35
3	5 years 6 months	32	33	1	6	1	4	34
4	5 years 2 months	28	33	0	6	1	4	34
5	4 years 7 months	21	33	0	5	1	4	33
6	6 years 3 months	41	33	0	5	1	4	37
7	4 years 4 months	19	22	0	5	1	3	33
8	3 years 1 months	17	19	0	4	1	3	30
9	3 years 9 months	15	29	0	5	1	3	33
10	4 years 11 months	30	28	0	5	1	4	35
11	4 years 9 months	29	27	0	5	1	4	35
12	4 years 2 months	25	24	0	5	1	3	30
13	6 years 5 months	53	23	1	5	1	3	37
14	2 years 7 months	11	19	0	4	1	4	30
15	4 years 1 months	31	17	1	5	1	3	31
16	2 years 2 months	16	9	0	3	1	2	28
<i>Group2: Facial Recess Approach Implantation with Incus Removal</i>								
17	4 years 2 months	19	30	1	5	1	4	34
18	4 years 2 months	20	29	0	5	1	4	33
19	6 years 2 months	46	27	0	6	1	4	36
20	7 years 2 months	24	25	2	6		5	38
21	4 years 11 months	31	26	0	5	1	4	36
22	7 years 4 months	20	25	4	7		5	38
23	3 years 6 months	19	22	0	5	1	3	33
24	3 years 10 months	25	20	0	5	1	3	32

<sup>a</sup> Use the IT-MAIS questionnaire if the subject is under 3-year old.

completed. The mastoid antrum was enlarged for full visualization of the short process of the incus. The facial recess was identified and enlarged to approach the round window niche. Intraoperatively, edematous mucosa with effusion was noticed in the middle ear, confirming active serous otitis media. The middle ear and mastoid cavity were drained and irrigated with dexamethasone (1 mL of 5 mg/mL dexamethasone in normal saline solution, Shandong Xinhua Pharmaceutical Company Limited) and epinephrine (0.3 mL of 1 mg/mL, 1:10,000, Beijing YOKON).

For cases in Group 2, the incudostapedial joint was separated and the incus removed, followed by expansion of the mastoid antrum by drilling the posterior bony buttress between the facial recess and fossa incudis for insertion of the electrode array in a straight line through the round window membrane.

In all cases, an anchoring well was drilled in the cranium for placement of the internal receiver-stimulator. The overhang of round window niche was removed using a diamond burr (0.5–1 mm) form maximum exposure of the round window membrane. Cochleostomy was finished anteroinferiorly from the round window membrane into the basal turn of the cochlea. The electrode array was inserted carefully into the scala tympani following the curvature of the cochlea and the cochleostomy was sealed by small pieces of temporalis fascia. The retroauricular incision was closed in layered sutures. Absorbable sutures and mastoid dressing was applied in all cases.

#### 4. Statistical analysis

Statistical analysis was performed with the SPSS16.0 software. Pre- and post-implant CAP and SIR scores were compared with self-paired T-test, following usual conditions of application. Significance was set at  $P < 0.05$ .

#### 5. Results

After the receiver-stimulator was placed, intraoperative neural response telemetry (NRT) responded well in all 24 children, which confirmed appropriate placement of the electrode array in the cochlea. Five days after implantation, an X-ray in Stenvers projection was performed in all cases, which also confirmed appropriate positions of the electrode array.

The average follow up was 27 months, ranging from 10 months to 3 years 9 months, during which time none of the subjects experienced any immediate or delayed complications. No recurrence of OME was detected in both groups after the CI surgery.

The questionnaire surveys, composed of questions from CAP, SIR and MAIS (or IT-MAIS) are shown in Table 2.

Table 3 lists the age at implantation, age at follow up, length of deafness, length of CI use, pre-and post-implant auditory and speech performance scores.

The preoperative and postoperative CAP scores were  $0.46 \pm 0.93$  and  $5.21 \pm 0.88$ , respectively. The preoperative and postoperative SIR scores were  $1.17 \pm 0.57$  and

Table 3

Mean, standard deviation (S.D.) and median of characteristics of CI use and pre- and post-implant scores of MAIS or IT-MAIS, CAP and SIR.

Items	Mean $\pm$ S.D.	Median
Age at Implantation (month)	29.12 $\pm$ 13.79	26.50
Age at Follow-up (month)	57.08 $\pm$ 16.02	56.00
Length of Deafness (month)	25.96 $\pm$ 10.07	24.50
Length of CI Use (month)	26.75 $\pm$ 7.22	27.00
MAIS or IT-MAIS <sup>a</sup>	33.88 $\pm$ 2.79	38.00
CAP		
Pre-implant	0.46 $\pm$ 0.93	0.00
Post-implant	5.21 $\pm$ 0.88	5.00
SIR		
Pre-implant	1.17 $\pm$ 0.57	1.00
Post-implant	3.71 $\pm$ 0.75	4.00

<sup>a</sup> Use the IT-MAIS questionnaire if the subject is under 3-year old.

3.71  $\pm$  0.75, respectively. For both CAP and SIR in both Groups 1 and 2, postoperative scores were higher than preoperative scores ( $t = -25.95$  and  $-14.09$ , respectively,  $p < 0.01$ ) (Fig. 1). Given the difference in the number of cases between Group 1 and Group 2, scores of MAIS or IT-MAIS, CAP and SIR were not compared between the two groups.

## 6. Discussion

Middle ear infection can spread via a cochlear implant electrode into the labyrinth and even intracranial space to cause post-operative infection, meningitis or fatal intracranial complications (Melton and Backous, 2011; Vincenti et al., 2014; Luntz et al., 2004; Barañano et al., 2010; Sun et al., 2014). The presence of chronic and recurrent inflammation in mastoid and middle ear cavities is considered a risk factor for cochlear implant electrode impairment and/or extrusion (Luntz et al., 2004; Barañano et al., 2010). Additionally, effusion and bleeding from inflamed middle ear mucosa can obscure the operative field and challenge even the most experienced surgeons intraoperatively (Vincenti et al., 2014; Luntz et al., 2004; Barañano et al., 2010; Sun et al., 2014; Wong et al., 2014). Based on these considerations, the current recommendation for cochlear implant candidates is to treat chronic otitis media with effusion before CI surgery.

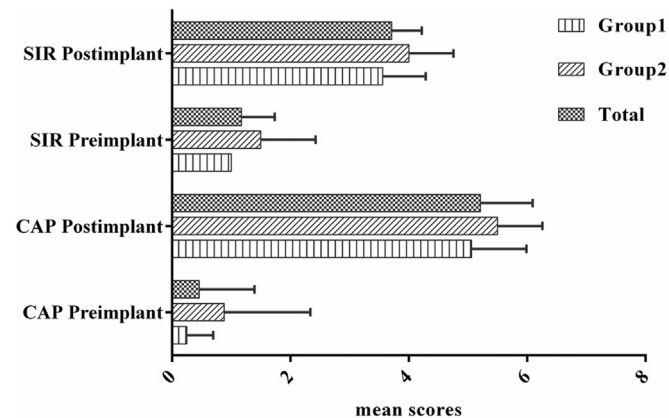


Fig. 1. The comparison between preimplant and postimplant of the mean scores for CAP and SIR.

The standard treatment of OME includes use of intranasal corticosteroids for a limited time and myringotomy with or without insertion of ventilating tubes (Olgun et al., 2005; American Academy of Family Physicians et al., 2004). Treatment of underlying eustachian tube dysfunction, including adenoidectomy and tonsillectomy, are often required in persistent or recurrent cases (American Academy of Family Physicians et al., 2004; Xenellis et al., 2008). With improvement of surgical techniques, one stage cochlear implantation has become feasible in patients with OME, albeit with a higher rate of complications (Chen et al., 2009).

With the goal to improve surgical techniques and to reduce complications for CI patients with active OME, we developed a new technique that involved incus removal after opening the facial recess, via the classical posterior tympanotomy and facial recess approach. We hypothesized that removing incus would contribute to enlargement of tympanic volume, thus improving ventilation of the middle ear. Migirov et al. (2006) reported that performing mastoidectomy during cochlear implantation had no influence on natural history of otitis media with effusion. The reason may be that aeration and gas composition of the middle ear depend to a great extent on the function of mastoid and middle ear mucosa (Sade et al., 1995). With incus removal in conjunction with mastoidectomy, the volume of tympanic cavity will be enlarged further without excessive impairment of middle ear mucosa.

During postoperative follow-up in our study, all electrodes were activated successfully without any immediate or delayed complications. Furthermore, all the implanted devices functioned normally and all 24 children achieved improved auditory performance and speech intelligibility.

## 7. Conclusions

In our study, one-stage operation via the facial recess approach with round window insertion proved to be safe and effective in cochlear implant candidates with active OME. No immediate or delayed complications were encountered in our patients with or without incus removal. Postoperative follow-up findings showed improvement of auditory function and speech intelligibility in all 24 children. Based on this study, we propose incus removal in cochlear implant candidates with OME via the classic facial recess approach with round window insertion to avoid staged procedures and gain early rehabilitation of audition and speech.

## Acknowledgments

We thank all the patients and their families for their participation and cooperation in this study. This work was supported by grants from the National Basic Research Program of China (973 Program) (#2012CB967900; 2011CBA01000), the National Natural Science Foundation of China (NSFC #81271082) and we acknowledged the grants of the National Key Basic Research Program of China (973 Program), No. 2014CB943003.

## References

- Achiques, M.T., Morant, A., Munoz, N., et al., 2010. Cochlear implant complications and failures. *Acta Otorrinolaringol. Esp.* 61 (6), 412–417.
- Allen, C., Nikolopoulos, T.P., Dyar, D., et al., 2001. Reliability of a rating scale form measuring speech intelligibility after pediatric cochlear implantation. *Otol. Neurotol.* 22 (5), 631–633.
- American Academy of Family Physicians, American Academy of Otolaryngology-Head and Neck Surgery, American Academy of Pediatrics Subcommittee on Otitis Media With Effusion, 2004. Otitis media with effusion. *Pediatrics* 113 (5), 1412–1429.
- Archbold, S., Lutman, M.E., Nikolopoulos, T.P., 1998. Categories of auditory performance: inter-user reliability. *Br. J. Audiol.* 32 (1), 7–12.
- Barañano, C.F., Sweitzer, R.S., Mahalak, M.L., et al., 2010. The management of myringotomy tubes in pediatric cochlear implant recipients. *Arch. Otolaryngol. Head. Neck Surg.* 136, 557–560.
- Chen, Z., Yu, D., Wu, Y., et al., 2009. Indications and common surgical approaches for cochlear implantation in China. *ORL J. Otorhinolaryngol. Rel Spec.* 71 (4), 187–191.
- Luntz, M., Teszler, C.B., Shpak, T., 2004. Cochlear implantation in children with otitis media: second stage of a long-term prospective study. *Int. J. Pediatr. Otorhinolaryngol.* 68, 273–280.
- Melton, M.F., Backous, D.D., 2011. Preventing complications in pediatric cochlear implantation. *Curr. Opin. Otolaryngol. Head. Neck Surg.* 19, 358–362.
- Migirov, L., Amir, A., Kronenberg, J., 2006. The influence of mastoidectomy on natural history of secretory otitis media in cochlear implant children. *ORL J. Otorhinolaryngol. Rel Spec.* 68 (3), 156–158.
- Moriniere, S., Soin, C., Lescanne, E., et al., 1998. Epidemiology of otitis media with effusion. *Rev. Prat.* 8, 838–842.
- Olgun, L., Batman, C., Gultekin, G., et al., 2005. Cochlear implantation in chronic otitis media. *J. Laryngol. Otol.* 119 (12), 946–949.
- Robbins, A.M., Renshaw, J.J., Berry, S.W., 1991. Evaluating meaningful auditory integration in profoundly hearing-impaired children. *Am. J. Otol.* 12 (Suppl), 144–150.
- Sade, J., Luntz, M., Levy, D., 1995. Middle ear gas composition and middle ear aeration. *Ann. Otol. Rhinol. Laryngol.* 104, 369–373.
- Sampaio, A.L., Araujo, M.F., Oliveira, C.A., 2011. New criteria of indication and selection of patients to cochlear implant. *Int. J. Otolaryngol.* 573968.
- Sun, J.Q., Sun, J.W., Hou, X.Y., 2014. Cochlear implantation with round window insertion in children with otitis media with effusion. *ORL J. Otorhinolaryngol. Rel Spec.* 76 (1), 13–18.
- Vincenti, V., Pasanisi, E., Bacciu, A., et al., 2014. Cochlear implantation in chronic otitis media and previous middle ear surgery: 20 years of experience. *Acta Otorhinolaryngol. Ital.* 34 (4), 272–277.
- Wong, M.C., Shipp, D.B., Nedzelski, J.M., et al., 2014. Cochlear implantation in patients with chronic suppurative otitis media. *Otol. Neurotol.* 35 (5), 810–814.
- Xenellis, J., Nikolopoulos, T.P., Marangoudakis, P., et al., 2008. Cochlear implantation in atelectasis and chronic otitis media: long-term follow-up. *Otol. Neurotol.* 29 (4), 499–501.