

Received: 2021.03.19

Accepted: 2021.06.25

Available online: 2021.07.06

Published: 2021.08.16

# Premenarchal Adolescent Female Ovarian Torsion: A Case of Delayed Diagnosis

## Authors' Contribution:

Study Design A  
Data Collection B  
Statistical Analysis C  
Data Interpretation D  
Manuscript Preparation E  
Literature Search F  
Funds Collection G

ABDE 1 **Maram Aljohani**  
DEF 2 **Muna Aljahany**  
BDE 1 **Sarah Yousif Elbasheer**  
EF 2 **Maha Bandar AboWadaan**  
DE 1 **Osama Kentab**

1 Department of Emergency Medicine, King Abdullah Bin Abdulaziz University Hospital, Princess Nourah Bint Abdulrahman University, Riyadh, Saudi Arabia  
2 Department of Clinical Sciences, College of Medicine, Princess Nourah Bint Abdulrahman University, Riyadh, Saudi Arabia

**Corresponding Author:** Muna Aljahany, e-mail: [msaljahany@pnu.edu.sa](mailto:msaljahany@pnu.edu.sa)

**Conflict of interest:** None declared

**Financial support:** This research was funded by the Deanship of Scientific Research at Princess Nourah Bint Abdulrahman University, Riyadh, Saudi Arabia, through the Fast-Track Research Funding Program

**Patient:** Female, 11-year-old  
**Final Diagnosis:** Ovarian  
**Symptoms:** Abdominal • pain  
**Medication:** —  
**Clinical Procedure:** —  
**Specialty:** Surgery

**Objective:** Mistake in diagnosis


**Background:** Ovarian torsion is a rare surgical emergency in premenarchal girls. Early diagnosis and surgical detorsion are required to restore blood flow and limit tissue damage.

**Case Report:** Here, we present a case of ovarian torsion and appendicitis in an 11-year-old premenarchal girl who presented to our emergency room with a 4-day history of right iliac fossa pain, limping, and fever. Upon initial evaluation in our hospital, her vital signs were stable and clinical examination revealed abdominal guarding and right lower quadrant rebound tenderness with positive Rovsing's sign. Abdominal ultrasound and computed tomography scans showed adnexal cysts and torsion, an inflamed appendix, and free fluid in the abdomen. Intraoperative findings included a twisted gangrenous ovary and an edematous appendix. The patient underwent emergency laparoscopic oophorectomy and appendectomy.

**Conclusions:** This case demonstrates that reactive appendicitis can occur secondary to inflammation of adjacent structures such as the ovary.

**Keywords:** Adolescent • Appendicitis • Ovary

**Full-text PDF:** <https://www.amjcaserep.com/abstract/index/idArt/932245>




1516



—



2



16



## Background

Ovarian torsion is defined as a rare gynecologic emergency occurring as the ovary twists on its ligamentous support, which obstructs the blood flow to the ovaries. There is no specific diagnosis of this condition in the form of clinical presentation in pediatric cases. Moreover, there might be inconsistency or equivocality in diagnostic imaging through computed tomography, magnetic resonance imaging, and Doppler ultrasound [1]. The occurrence of ovarian torsion is rare among children and adolescents; however, it is important to consider pediatric females with abdominal pain.

Approximately 2 out of 10 000 pediatric and adolescent populations are affected by this disease, which constitutes 15% of all torsion cases [2]. The occurrence of torsion is observed among pre-and post-menarchal girls.

Adnexal torsion can affect otherwise healthy ovaries, known as torsion of the normal adnexa, or pathologic adnexa, which typically contains ovarian or para-ovarian cysts. Among the pediatric and adolescent populations, most of the torsion cases (40-84%) develop because of some ovarian pathology, whereas other cases demonstrate torsion of normal adnexa [3,4]. It is expected that torsion in post-menarchal teens is linked with functional ovarian cysts like the cysts of the corpus luteum [5].

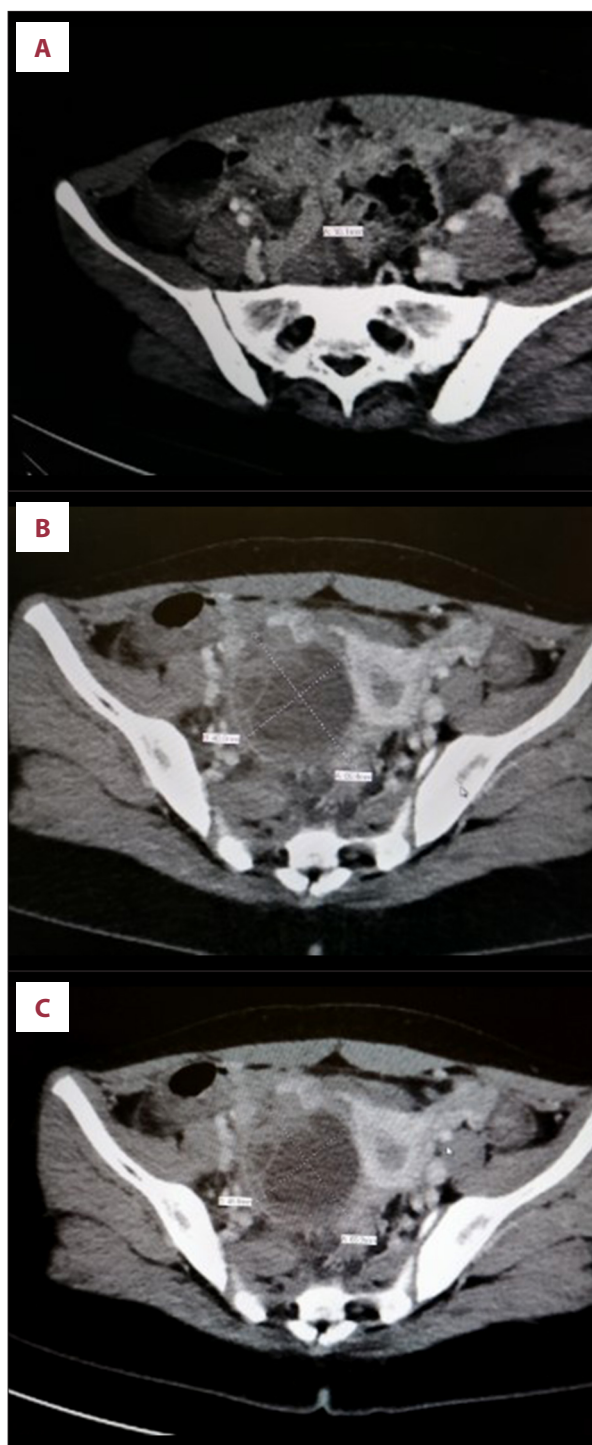The risk of recurrent torsion is associated with the underlying pathology that causes torsion. Previous studies have shown that 60% of the recurrence rate in pre-and post-menarchal females is associated with normal adnexa [6,7]. Moreover, these cases present a chance of preventing recurrent torsion by ovarian fixation of the ipsilateral and bilateral adnexa [8].

Here, we describe an uncommon case of a delayed diagnosis of ovarian torsion complicated by reactive appendicitis.

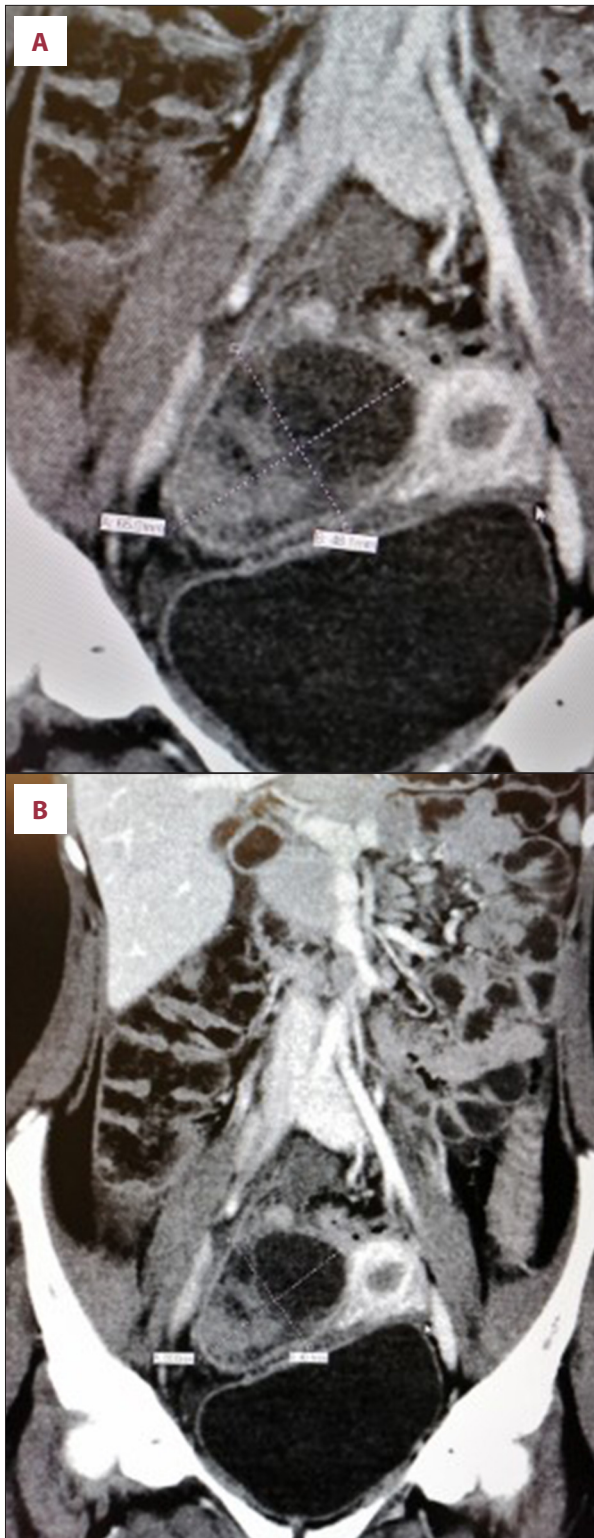
## Case Report

An 11-year-old pre-pubertal girl with no past medical or surgical history presented to our ED with a 4-day history of right iliac fossa pain and limping associated with fever. Before this, she presented to the ED of another hospital on 2 occasions and was discharged after being diagnosed with suspected gastroenteritis or early acute appendicitis. Physical examination of the abdomen revealed guarding and right lower quadrant rebound tenderness with positive Rovsing's sign and Dunphy's sign. The laboratory results showed a white blood cell count of  $12.79 \times 10^9/L$  with 65.9% neutrophils.

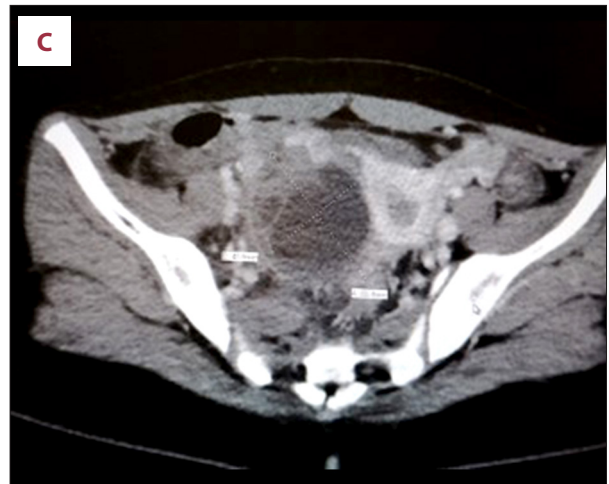
Abdominal ultrasound suggested an ovarian torsion (right ovarian cyst of 4.5×4 cm) with a minimal amount of free fluid



**Figure 1.** Coronal view of the abdominal and pelvic CT with intravenous contrast showing (A) an appendix with a thickened enhancing edematous wall in the right iliac fossa measuring about 10 mm in diameter; (B) moderate free fluid in the right iliac fossa, hepatorenal pouch, and pelvic region; (C) right adnexal cystic structure with septation, hyperdense component, and thickened wall, measuring about 6.5×4.8 cm.



in the pouch of Douglas. As the appendix was not visualized, she underwent a CT scan with intravenous contrast. This revealed an appendix with a thickened enhancing edematous wall in the right iliac fossa extending medially with its tip



**Figure 2.** Axial view of the abdominal and pelvic CT with intravenous contrast showing (A) an appendix with thickened enhancing edematous wall in the right iliac fossa measuring about 10 mm in diameter; (B) moderate free fluid in the right iliac fossa, hepatorenal pouch, and pelvic region; (C) right adnexal cystic structure with septation, hyperdense component, and thickened wall, measuring about 6.5×4.8 cm.

lying adjacent to the anterolateral aspect of the right ovarian complex cyst. The inflamed appendix measured about 10 mm in diameter and was associated with stranding and haziness of the mesenteric fat planes and moderate free fluid in the right iliac fossa, hepatorenal pouch, and pelvic region, suggestive of acute appendicitis with possible rupture. The right adnexa showed a cystic structure with septation and a hyperdense component as well as a thickened wall, measuring approximately 6.5×4.8 cm with endometrial fluid (Figures 1, 2).

The patient underwent laparoscopic oophorectomy of the right ovary and appendectomy. Intraoperatively, there was a hemorrhagic twisted ovarian torsion.

The wound was closed in layers using Vicryl 3/0 for the sheath and Vicryl rapid 4/0 for the skin. The wound was covered and the Foley catheter was removed. The total blood loss was 10 mL and the patient did not require a blood transfusion. The appendix and hemorrhagic torsion were sent for pathological analysis. Histopathological examination revealed marked congested and non-viable tissue with hemorrhagic infarction, and no residual ovarian tissue, cyst, or malignancy. The appendix was inflamed distally with full-thickness necrosis at the tip. The patient recovered without complications.

#### Ethical consideration

Consent was obtained from the parents of the patient before continuing with this case study.

## Discussion

An infrequent cause of abdominal pain arises as the result of ovarian torsion among the pediatric female population. There is a rare occurrence of ovarian torsion with concomitant appendicitis. Physical exam ultrasonography, radiographs, and computed tomography are used as a diagnostic modality for these patients [9]. The outcomes seem to be good in patients who undergo appendectomy and oophorectomy with or without a salpingectomy. A cystic ovarian lesion is present in 5 out of 7 cases, while 1 out of 7 cases present with ovarian neoplasm in pathologic analysis. The present case is unique, with no identification of coexisting ovarian pathology.

Previous studies have shown that sonography and computed tomography are widely used for the diagnosis of ovarian torsion [10,11]. The major ultrasonic signs of the development of ovarian torsion include multiple follicles in cortical portions of the ovary and pelvic masses that may be with or without fluid in the pouch of Douglas [12]. In the present case, there was no flow to the torsed ovary observed through duplex imaging. It is possible to differentiate between appendicitis and ovarian torsion through ultrasonography with color Doppler. The 2 main issues highlighted by the present case study are that reactive appendicitis can occur secondary to inflammation of adjacent structures such as the ovary, and that adnexal torsion should be considered in the differential diagnosis of reactive appendicitis, and a surgeon skilled in managing both conditions should be consulted.

A similar case study by Al-Turki [13] described a delayed diagnosis of ovarian torsion in a patient presenting with vomiting and sudden onset of right iliac fossa pain. On initial examination, the patient was tender in the right iliac fossa but without rebound tenderness; therefore, an initial diagnosis of appendicitis was made. However, after 17 hours of delay, this case was successfully managed with detorsion of the ovary after clinical imaging revealed a normal appendix. This case demonstrated the overlapping clinical features of appendicitis and ovarian torsion.

Another cause of a reproductive-age woman was presented by Callen et al [14], who presented with a history of subacute lower abdominal pain that became worse with physical activity, and a low-grade fever. Ultrasound revealed an edematous ovary but ovarian torsion was considered unlikely. However, magnetic resonance imaging (MRI) confirmed a twisted vascular pedicle and demonstrated a markedly dilated, hyper-enhancing appendix with extensive inflammatory changes involving the surrounding peritoneal fat as well as the small and large bowel. Abdominal examination revealed minimal periumbilical tenderness without any guarding or rebound tenderness. She consented to diagnostic laparoscopy

for possible appendectomy; however, the intraoperative assessment revealed features of chronic appendicitis with dense adhesions precluding safe appendectomy. The ovary was edematous due to inflammation from chronic appendicitis without any torsion or ovarian mass. In conclusion, this was ovarian edema due to adjacent appendicitis [14].

A rare case of pediatric ovarian torsion in a premenarchal 13-year-old girl was reported by Rajwani and Mahomed [15]. This case presented with engorged massive edematous and hemorrhagic ovarian torsion treated with salpingo-oophorectomy. This case was similar to our own in having a clinical presentation with features of acute appendicitis and similar histopathology results.

Adnexal torsion is most common among women aged 20-30 years [16]. Even though adnexal torsion is rare in premenarchal girls [15], it should be ruled out in patients presenting with signs and symptoms of an acute abdomen, such as those with suspected renal colic and acute appendicitis. Distinguishing between these 2 clinical entities may be challenging due to the overlapping signs and symptoms; therefore, ultrasound should be obtained to confirm the clinical diagnosis and prevent misdiagnosis. According to a previous study [13], young girls presenting with lower abdominal pain should undergo an ultrasound to rule out adnexal torsion and prevent potentially irreversible damage to the ovaries. In our case, ovarian torsion was evident on ultrasound; however, a previous study reported that ultrasound was insufficient to detect ovarian torsion in a woman of reproductive age [14]. However, our patient also underwent a CT scan to confirm the diagnosis, which highlights the need for further research to evaluate whether ultrasound should always be complemented by more detailed imaging modalities such as CT or MRI.

The coincidence of ovarian pathology with appendicitis is rare; however, it can require surgery in some pediatric female patients. It is often possible to secure the torsioned ovary, but there is a need to perform ovarian sparing whenever possible. The present case reveals that ovarian torsion accompanied with appendicitis often requires salpingo-oophorectomy along with an appendectomy.

## Conclusions

Ovarian torsion in pediatric patients has a similar clinical presentation and may be treated by laparoscopy in most cases. This present case study showed that reactive appendicitis can occur secondary to inflammation of adjacent structures such as the ovary. It is shown that there is an increased risk of torsion recurrence among premenarchal girls with torsion involving normal adnexa that should be followed accordingly. This case

highlights the need for further studies to evaluate the sensitivity and specificity of ultrasound alone in detecting complicated adnexal torsion in adolescent girls.

#### **Name of Department and Institution Where Work Was Done**

Emergency Department, King Abdullah bin Abdulaziz University Hospital, Riyadh, Saudi Arabia.

#### **References:**

1. Ochsner TJ, Roos JA, Johnson AS, Henderson JL. Ovarian torsion in a three-year-old girl. *J Emerg Med.* 2010;38:e27-30
2. Piper HG, Oltmann SC, Xu L, et al. Ovarian torsion: diagnosis of inclusion mandates earlier intervention. *J Pediatr Surg.* 2012;47:2071-76
3. Oltmann SC, Fischer A, Barber R, et al. Cannot exclude torsion – a 15-year review. *J Pediatr Surg.* 2009;44:1212-17
4. Smorgick N, Melcer Y, Sarig-Meth T, et al. High risk of recurrent torsion in premenarchal girls with torsion of the normal adnexa. *Fertil Steril.* 2016;105:1561-65
5. Breech LL, Hillard PJ. Adnexal torsion in pediatric and adolescent girls. *Curr Opin Obstet Gynecol.* 2005;17:483-89
6. Pansky M, Smorgick N, Herman A, et al. Torsion of normal adnexa in post-menarchal women and risk of recurrence. *Obstet Gynecol.* 2007;109:355-59
7. Hyttel TE, Bak GS, Larsen SB, Løkkegaard EC. Re-torsion of the ovaries. *Acta Obstet Gynecol Scand.* 2015;94:236-44
8. Aziz D, Davis V, Allen L, Langer JC. Ovarian torsion in children: Is oophorectomy necessary? *J Pediatr Surg.* 2004;39:750-53
9. Krupińska E, Klimanek-Syngnet M, Chilarski A. [Rare coexistence of phlegmonous appendicitis and tumor of a twisted left ovary.] *Ginekol Pol.* 2003;74:307-11 [in Polish]
10. Cass DL, Hawkins E, Brandt ML, et al. Surgery for ovarian masses in infants, children, and adolescents: 102 consecutive patients treated in a 15-year period. *J Pediatr Surg.* 2001;36:693-99
11. Kokoska ER, Keller MS, Weber TR. Acute ovarian torsion in children. *Am J Surg.* 2000;180:462-65
12. Hoey BA, Stawicki SP, Hoff WS, et al. Ovarian torsion associated with appendicitis in a 5-year-old girl: A case report and review of the literature. *J Pediatr Surg.* 2005;40:e17-20
13. Al-Turki H. Late presentation of ovarian torsion. *Bahrain Med Bull.* 202;136:267-28
14. Callen AL, Illangasekare T, Poder L. Massive ovarian edema, due to adjacent appendicitis. *Emerg Radiol.* 2017;24:215-18
15. Rajwani KM, Mahomed A. Pediatric ovarian torsion: An uncommon clinical entity. *Clin Case Rep.* 2015;3:193-94
16. Houry D, Abbot JT. Ovarian torsion: A fifteen year review. *Ann Emerg Med.* 2001;38:156-59

#### **Conflicts of interest**

None.

#### **Declaration of Figures Authenticity**

All figures submitted have been created by the authors who confirm that the images are original with no duplication and have not been previously published in whole or in part.