


ORIGINAL ARTICLE

Increased incidence of rhino-orbital mucormycosis in an educational therapeutic hospital during the COVID-19 pandemic in western Iran: An observational study

Manouchehr Avatef Fazeli¹ | Leila Rezaei² | Etrat Javadirad³ | Khosro Iranfar¹ | Abbas Khosravi² | Javad Amini Saman⁴ | Pardis Poursabbagh¹ | Mohammad Rasoul Ghadami^{1,5} | Mohammad Mehdi Parandin² | Amrollah Dehghani¹ | Touraj Ahmadi Jouybari⁶ | Behzad Mahdavian⁷ | Nastaran Eivazi¹ | Sohbat rezaei¹ | Alireza Rezaei¹ | Bashir Emami⁸ | Mohadeseh Haqgou¹ | Arezoo Bozorgomid⁹  | Babak Sayad^{9,7}

¹Department of Otorhinolaryngology, School of Medicine, Kermanshah University of Medical Sciences, Kermanshah, Iran

²Department of Ophthalmology, School of Medicine, Kermanshah University of Medical Sciences, Kermanshah, Iran

³Department of Pathology, School of Medicine, Kermanshah University of Medical Sciences, Kermanshah, Iran

⁴Department of Anesthesiology, School of Medicine, Kermanshah University of Medical Sciences, Kermanshah, Iran

⁵Sleep Disorders Research Center, Kermanshah University of Medical Sciences, Kermanshah, Iran

⁶Department of Internal Medicine, School of Medicine, Kermanshah University of Medical Sciences, Kermanshah, Iran

⁷Department of Infectious Disease, School of Medicine, Kermanshah University of Medical Sciences, Kermanshah, Iran

⁸Imam Khomeini and Mohamad Kermanshahi Clinical Research Development Unit, Kermanshah University of Medical Sciences, Kermanshah, Iran

⁹Infectious Diseases Research Center, Health Institute, Kermanshah University of Medical Sciences, Kermanshah, Iran

Correspondence

Arezoo Bozorgomid, Babak Sayad, Infectious Diseases Research Center, Health Institute, Kermanshah University of Medical Sciences, Kermanshah, Iran. Emails: Arezoobozorgomid@yahoo.com; babaksayad@kums.ac.ir

Abstract

Background: COVID-19 patients, especially the patients requiring hospitalisation, have a high risk of several complications such as opportunistic bacterial and fungal infections. Mucormycosis is a rare and opportunistic fungal infection that mainly affects diabetic and immunocompromised patients. An increase has been observed in the number of rhino-orbital mucormycosis in patients with COVID-19 admitted to Imam Khomeini Hospital, Kermanshah, Iran, since October 2020. This is a report of the frequency, risk factors, clinical manifestations, treatment and prognosis of COVID-19 associated with mucormycosis infection.

Methods: The medical records of COVID-19 patients with rhino-orbital mucormycosis who were diagnosed in an educational therapeutic hospital in Kermanshah, west of Iran were surveyed. Several parameters were analysed including demographic, clinical, therapeutic and laboratory characteristics.

Results: Twelve patients with COVID-19-associated rhino-orbital mucormycosis were identified from 12 October to 18 November 2020. All cases reported as proven mucormycosis had a history of hospitalisation due to COVID-19. Comorbidities mainly included diabetes mellitus (83.33%) and hypertension (58.33%). Seventy-five per cent of patients received corticosteroids for COVID-19 treatment. The sites of involvement were rhino-sino-orbital (83%) and rhino-sino (17%). Amphotericin B/liposomal amphotericin B alone or in combination with surgical debridement or orbital exenteration was used as the first-line therapy. The overall mortality rate was 66.7% (8/12).

Conclusions: We found a high incidence of mucormycosis among COVID-19 patients. Diabetes mellitus and corticosteroid use were the dominant predisposing factor of mucormycosis. Mucormycosis is a life-threatening and opportunistic infection;

Funding information

No financial support was provided relevant to this article.

therefore, physicians should know the signs and symptoms of the disease so that a timely diagnosis and therapy can be performed.

KEYWORDS

co-infection, COVID-19, Iran, mucormycosis, SARS-CoV-2

1 | INTRODUCTION

A novel coronavirus known as severe acute respiratory syndrome coronavirus 2 (SARS-CoV-2, also called COVID-19) emerged in Wuhan, China, in December 2019, which spread rapidly across the world. Although COVID-19 associated mortality mainly occurs in older age groups (>65) and in patients with underlying diseases,¹ fungal co-infection remains as a life-threatening condition for these patients.² COVID-19 patients are susceptible to opportunistic fungal infections due to undefined pharmacological treatment, intensive care units (ICU) hospitalisation, need for invasive or noninvasive ventilation and administration of broad-spectrum antibiotics, corticosteroid use or pre-existing conditions.³ A review study found bacterial/fungal co-infection in 62/806 (8%) of COVID-19 patients.⁴ Available guidelines for prevention and control of COVID-19 mainly focus on the prevention and management of disease spread, and little attention is paid to bacterial and fungal infections.

Mucormycosis is a rare but serious infection caused by fungi in the order Mucorales, particularly *Rhizopus* and *Mucor* species while another includes *Apophysomyces*, *Rhizomucor*, *Cunninghamella*, *Lichtheimia*, *Cokeromyces* and *Saksenaea*.⁵ They release their spores and are easily aerosolised and dispersed in the environment. The predisposing factors for developing mucormycosis include uncontrolled diabetes mellitus, haematologic malignancies, immunosuppression, solid organ and bone marrow transplantation, long-term treatment with corticosteroids, and extensive burns or major trauma.⁶ Due to its high mortality and morbidity, early diagnosis and treatment are crucial.⁷ However, mucormycosis is rare, even among individuals with the highest risk. Recently, a few studies from different countries have reported COVID-19-associated mucormycosis infection.^{8,9}

Since the diagnosis of the first COVID-19 case in Iran on 10 March 2020, the number of confirmed cases has increased to 1.7 million and 61,300 patients have died (as of 15 March 2021). Iran has experienced one of the worst COVID-19 outbreaks in the world, and the emergence of COVID-19 may be one of the biggest challenges of the century for the society and healthcare system and social in Iran. Despite promising preventive measures, the third wave of infection occurred in early September 2020 in Iran, which subsided down after four difficult months in the late 2020. During the third wave of the disease, an increase was observed in rhino-orbital mucormycosis cases in Imam Khomeini Hospital, Kermanshah, Iran. This is a report of the frequency and predisposing factors, clinical manifestations, treatment and prognosis of rhino-orbital mucormycosis in COVID-19 patients.

2 | METHODS

A retrospective observational study was conducted on all rhino-orbital mucormycosis patients with a previous history of COVID-19 infection at Imam Khomeini Hospital, Kermanshah, Iran, during a two-month period from 12 October to 18 November 2020. This hospital is only referral centre for ophthalmology and ears, nose and throat (ENT) care in Kermanshah Province. Patients from different parts of the province are mostly referred to this hospital for the diagnosis and treatment of ophthalmology and ENT diseases.

According to guidelines issued by the WHO, COVID-19 patients were classified as suspect, probable or confirmed. Briefly, the suspected case of COVID-19 is defined as having symptoms such as fever, cough or acute respiratory illness. Probable case defined as a suspected case plus chest imaging showing findings of COVID-19 disease. Confirmed cases defined as individuals with a positive real-time RT-PCR test or nucleic acid sequencing for the SARS-CoV-2 virus based on patients' a nasopharyngeal swab samples and/or a compatible chest CT scan. Our study included all patients diagnosed with COVID-19 who received treatment related to the COVID-19. The medical records of patients referred to the hospital were reviewed to find patients who suffered from rhino-orbital mucormycosis and/or underwent surgical operation. Data including demographic characteristics, laboratory data, imaging findings, operative reports, COVID-19 treatment, morbidity and mortality were collected from the medical records of the patients. Diagnosis of mucormycosis was first made based on history, clinical assessment and imaging. Then, according to the revised definitions of invasive fungal disease (IFD) of the European Organization for Research and Treatment of Cancer/Mycosis Study Group (EORTC/MSG), a diagnosis of mucormycosis was proved when histopathologic and/or direct microscopic examination of the sterile specimen showed non-septate, ribbon-like, wide hyphae with right-angle branching (Figure 1).¹⁰

The IBM® SPSS® statistical software version 24.0 (SPSS Inc) was used for data analysis. Quantitative variables are presented as mean \pm standard deviation (SD), and qualitative variables such as gender, comorbidities, mortality, and complications are expressed as number and percentage.

3 | RESULTS

During the study period, rhino-orbital mucormycosis was clinically diagnosed in 14 patients, of whom two were excluded from the study due to their critical condition that made it impossible to

perform an imaging or a tissue biopsy for histopathological confirmation of mucormycosis. The patients presented with following signs and symptoms: headache, facial cellulitis, maxillary sinusitis, rhinorrhea, periorbital and retro-orbital pain, proptosis, restriction of eye movements, loss of vision, etc (Figure 2A-C). Demographic and clinical characteristics of the patients are presented in Table 1. The mean age of the patients with COVID-19-associated

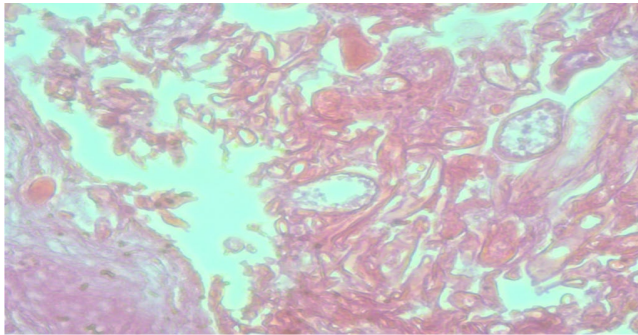


FIGURE 1 Histopathology section showing rectangular-shaped aseptate hyphae (haematoxylin and eosin stain $\times 100$)

rhino-orbital mucormycosis was 62.08 ± 11.75 years (median age: 60, IQR: 12, range: 46–87), and the majority of the patients were female (58.33%). The most common underlying condition was diabetes (83.33%) followed by hypertension (58.33%), ischaemic heart disease (33.33%) and chronic kidney disease (16.66%).

Our four patients developed acute-onset diabetes during SARS-CoV-2 infection. The sites of involvement were rhino-sino-orbital (83%) and rhino-sino (17%). All cases reported as proven mucormycosis had a history of hospitalisation due to COVID-19. Seventy-five per cent of patients received corticosteroids for COVID-19 treatment (detailed information on COVID-19 care was not available for cases 2, 3 and 7). The mean time from COVID-19 to colonisation was 25.66 ± 12.84 days. Amphotericin B/liposomal amphotericin B alone or in combination with surgical debridement or orbital exenteration was used as the first-line therapy (Figure 2D–F). The mean time from admission to beginning the antifungal therapy was 1.9 ± 1.7 days (range from 1 to 6 days). Paranasal sinuses-computed tomography (PNS-CT) scans were obtained for all patients, and magnetic resonance imaging (MRI) was done when orbital or intracranial involvement was suspected. Of our patient, 50% (6/12) had raised levels of lactate dehydrogenase. Laboratory findings of the COVID-19 patients with rhino-orbital mucormycosis on admission are presented

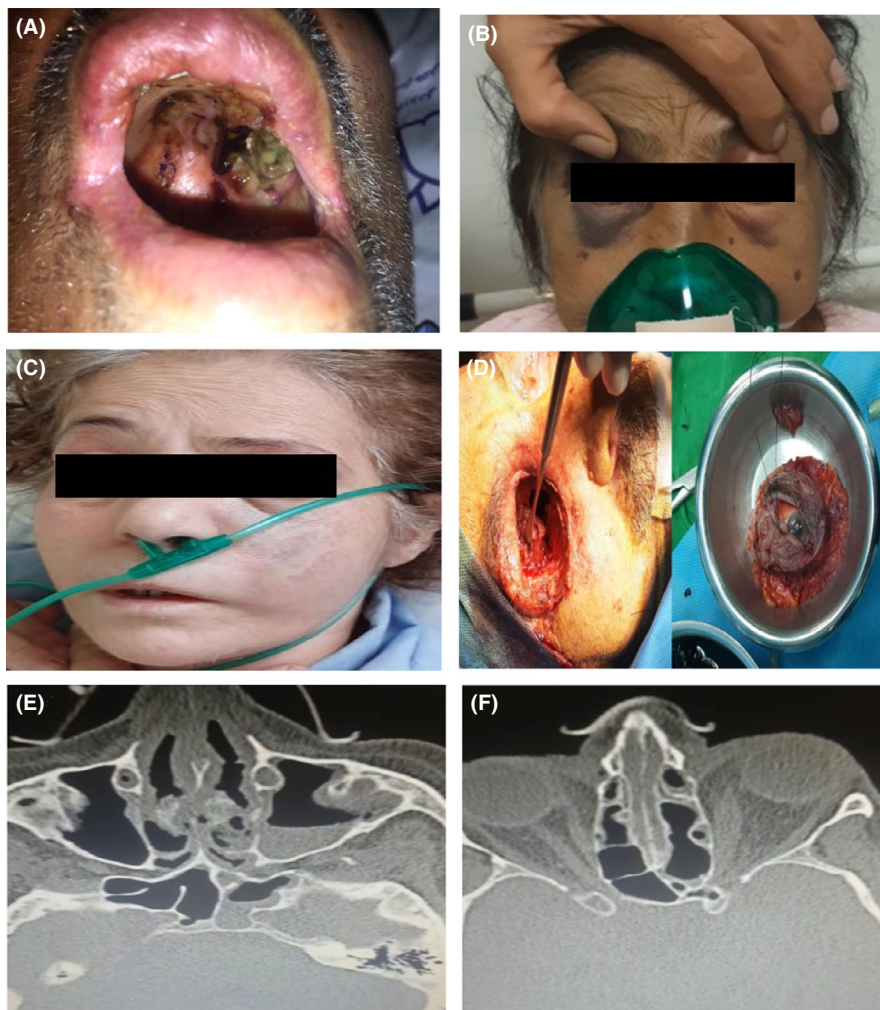


FIGURE 2 Clinical presentations and CT scan images of mucormycosis in COVID-19 patients. A Necrotic of plate. B and C Conjunctival chemosis, proptosis and periorbital oedema of left eye. D Orbital exenteration for preventing spread to the CNS. E CT scan image showing the involvement of paranasal sinuses. F CT scan image showing the involvement of left eye

in Table 2. The overall mortality rate of COVID-19 patients with rhino-orbital mucormycosis was 66.7% (8 out of 12 cases).

4 | DISCUSSION

Although the prevalence of bacterial or fungal co-infections in COVID-19 patients has been reported in many studies, our knowledge of mucormycosis secondary infection among patients with COVID-19 is limited. Ahmadikia et al¹¹ recently reviewed eight cases of COVID-associated mucormycosis. Also, Moorthy et al⁸ in a multi-centric study reported 18 patients of COVID-associated mucormycosis in India. During our 2 months study, 12 patients with COVID-19-associated rhino-orbital mucormycosis were identified upon histopathological confirmation and they all had a history of hospitalisation due to COVID-19. According to Iran's national guideline for SARS-CoV-2, only patients with moderate to severe COVID-19 (oxygen saturation (SaO₂) of 93% or less in the ambient air and/or an absolute lymphocyte count of <1100/ μ l) were admitted to the hospital.

The patients in the present study were slightly older (mean age \pm SD: 62.08 \pm 11.75 years) compared to COVID-19 patients with mucormycosis in a systematic review of the literature.⁹ The mean age 61.6 years, 51.7 years and 45 years reported in different studies.^{12–14} Our findings are not surprising since older individuals are more susceptible to SARS-CoV-2 and have a higher risk of hospitalisation.¹⁵

The majority of the cases in this study were female, which was consistent with a study by Dolatabadi et al¹⁶ However, Ahmadikia et al¹¹ also studied COVID-19 associated with mucormycosis infection and found different results. Although the prevalence of symptomatic COVID-19 is higher in men than in women, Iranian females have a higher prevalence of diabetes than men,^{17,18} which could be a major predisposing factor for mucormycosis.

In the present study, the main risk factor associated with rhino-orbital mucormycosis infection was steroid therapy for COVID-19 (such as dexamethasone, prednisolone or hydrocortisone) as 75% patients received dexamethasone for COVID-19 treatment (detailed information on COVID-19 care was not available for cases 2, 3 and 7). Dysregulated and excessive cytokine storm is a major cause of acute respiratory distress, multiple organ failure and thromboembolic disease, which seriously threatens the life of the patients with COVID-19.¹⁹ Corticosteroids have unique advantages in inhibiting a broad range of inflammatory responses²⁰; hence, they may be useful for suppressing the cytokine storm in critically ill patients. The results of the RECOVERY trial showed that a moderate dose of dexamethasone (6 mg daily for 10 days) than the usual care reduced mortality in patients with COVID-19 requiring invasive mechanical ventilation (29.3% vs. 41.4%; rate ratio, 0.64; 95% CI 0.51 to 0.81) as well as the patients using oxygen (23.3% vs. 26.2%; rate ratio, 0.82; 95% CI 0.72 to 0.94).²¹ Considering these findings and similar reports,²² physicians tend to use dexamethasone to treat critically ill patients. Although the benefits of corticosteroid use have been reported in hospitalised patients with severe COVID-19 infection,

chronic corticosteroid use is known to be a risk factor for invasive fungal infection due to hyperglycaemia and dysfunction of monocytes and neutrophils.²³ Therefore, corticosteroid therapy could be regarded as a double-edged sword in infectious diseases. They should be used with caution in patients with COVID-19, especially in subjects who regularly use corticosteroids for chronic diseases or have underlying diseases.

The results confirmed the predisposing role of diabetes as a risk factor for rhino-orbital mucormycosis such that 10 of the 12 patients (83.33%) were diabetic. This finding was consistent with the results of study by Vaezi et al²⁴ who reviewed 98 mucormycosis cases from Iran between 1990 and 2015 and found diabetes in 47.9% and solid organ or bone marrow transplantation in 22.4% of the cases. Recent reports from South India and Mexico have indicated that diabetes was the most prominent underlying disease in mucormycosis cases.^{25,26} Interestingly, four patients developed acute-onset diabetes during SARS-CoV-2 infection in the present study. Previous studies have shown that glucocorticoids lead to the onset of diabetes. In addition, they also cause glucose intolerance and hypertriglyceridaemia.²⁷ On the other hand, there is increasing evidence that COVID-19 can induce new-onset diabetes mellitus in some subjects without predisposing factors for impaired glucose metabolism.²⁸

It is important to note that climate conditions may affect the spread of mucormycosis, which could be related to higher concentrations of fungal spores in the autumn whereas the lowest concentrations are seen in the summer. A review of 208 mucormycosis cases in Iran showed that the highest incidence of infection was during September to November, which is in agreement with the present report.¹⁶

According to Mugge et al,²⁹ the mean time from the diagnosis of a haematological malignancy to mucor colonisation is approximately 9.8 months in children. However, the mean time from diagnosis of COVID-19 to infection colonisation was shorter in the present study, which could be due to other predisposing factors besides profound immunosuppression, for example, uncontrolled hyperglycaemia, overt diabetes mellitus and/or diabetic ketoacidosis.

In this study, the sites of involvement were rhino-sino-orbital (83%) and rhino-sino (17%). A literature review of COVID-19-associated mucormycosis found that rhino-orbito-cerebral mucormycosis was the most common presentation.¹¹ The involvement of sinuses seems to be mainly documented in diabetic patients.³⁰ The mortality rate was as high as 66.7% in the present study. Previous studies have drawn different conclusions with regard to the underlying predisposing conditions and different anatomic sites; for example, lower mortality rates have been reported in localised sinus or skin infections.^{24,31} Moreover, there are reports of the effectiveness of surgical interventions in reducing the mortality of mucormycosis.³¹ In the present study, all rhino-orbital mucormycosis cases received high dose amphotericin B in combination with debridement of the sinuses. Four cases also underwent orbital exenteration. It should be noted that in patients with severe mucormycosis, amphotericin B treatment and an aggressive surgical approach do not guarantee survival.

TABLE 1 Characteristics of patients co-infected with mucormycosis and coronavirus disease 2019 (COVID-19)

Cases	Age/ sex	Comorbidities	Diagnosis of COVID-19		Anti-viral/ immunomodulator treatment for COVID-19	In-hospital corticosteroid treatment for COVID-19	Antibiotic treatment for COVID-19	ICU administration due to COVID-19
			PCR	CT scan				
1	F/59	Asthma, DM, HTN	Negative	NA	Interferon beta-1a, sofosbuvir + daclatasvir, remdesivir	DEX(QID) (8 mg for 4 days), mPSL (500 mg daily for 4 days), subsequent, mPSL(BD) (500 mg for 4 days)	NO	Yes
2*	M/64	IHD, guillain-barré syndrome	Positive	Positive	NA	NA	NA	NA
3*	M/65	New onset DM, HTN, IHD	Negative	Positive	NA	NA	NA	NA
4	F/67	New onset DM, asthma, rheumatoid arthritis, hypothyroidism	Positive	Positive	Remdesivir, sofosbuvir + daclatasvir, interferon beta-1a	DEX (BD) (8 mg for 5 days), DEX(TDS) (8 mg for 6 days)	Meropenem, vancomycin	Intubation
5	F/79	IHD	Positive	Positive	No	First admission: DEX (BD) (4 mg for 4 days) second admission: PSL (40 mg daily for 4 days)	Vancomyci, meropenem	No

Duration from COVID-19 to mucormycosis	Duration from symptom to admission (days)	Clinical finding	Radiological findings	Site of infection	Mycological criteria		Antifungal / surgical therapy	Duration of admission (days)	Outcome
					Smear	Pathology			
30	3	Ocular symptoms: periorbital and retro-orbital pain, restriction of eye movements and rapid vision loss, proptosis General symptoms: headache, lethargy Facial symptoms: - Nasal symptoms: rhinorrhea and epistaxis	CT Scan: pereorbital edema, protrusion of the eye globe, soft-tissue thickness along the paranasal sinuses (pansinusitis)	Rhino-sino-orbital	■	■	Debridement (1 time), FESS, amphotericin B liposomal	3	Died
50	3	General symptoms: headache, lethargy Facial symptoms: numbness Nasal symptoms: rhinorrhea	CT Scan: soft-tissue thickness along the paranasal sinuses, sinus opacification	Rhino-sino	■	■	Debridement (5 times), FESS, amphotericin B liposomal	28	Alive
15	3	Ocular symptoms: periorbital and retro-orbital pain, proptosis, restriction of eye movements and rapid vision loss	CT Scan: soft-tissue thickness along the paranasal sinuses (maxillary, ethmoid, sphenoid), orbital fat stranding, increasing the thickness of the extraocular muscles	Rhino-sino-orbital	■	■	Debridement (5 times), exenteration eye right, amphotericin B liposomal	14	Died
18	1	Ocular symptoms: periorbital and retro-orbital pain, proptosis, restriction of eye movements and rapid vision loss General symptoms: headache, lethargy Facial symptoms: numbness Nasal symptoms: rhinorrhea	CT Scan: soft-tissue thickness along the paranasal sinuses (maxillary, ethmoid, sphenoid), increase in thickness in the left rectus medial muscle	Rhino-sino-orbital	■	■	Debridement (1 time), FESS, amphotericin B liposomal	3	Died
29	3	Ocular symptoms: periorbital and retro-orbital pain, proptosis, eyelid edema, restriction of eye movements and rapid vision loss General symptoms: headache, lethargy Facial symptoms: numbness Nasal symptoms: rhinorrhea	CT Scan: soft-tissue thickness along the paranasal sinuses (maxillary, ethmoid, sphenoid)	Rhino-sino-orbital	■	■	Debridement (1 time), amphotericin B liposomal	3	Died

(Continues)

TABLE 1 (Continued)

Cases	Age/ sex	Comorbidities	Diagnosis of COVID-19		Anti-viral/ immunomodulator treatment for COVID-19	In-hospital corticosteroid treatment for COVID-19	Antibiotic treatment for COVID-19	ICU administration due to COVID-19
			PCR	CT scan				
6	F/58	New onset DM, HTN	Positive	Positive	Remdesivir, sofosbuvir + daclatasvir, Interferon beta-1a	DEX (BD) (8 mg for 6 days)	Imipenem, vancomycin	No
7	F/61	Controlled DM	Positive	Positive	NA	NA	NA	No
8	F/46	DM, HTN	Positive	Positive	Remdesivir, sofosbuvir+daclatasvir, interferon beta-1a	DEX (BD) (8 mg for 6 days)	Ceftriaxone	No
9	M/87	Controlled DM, HTN	Negative	Positive	Sofosbuvir+daclatasvir, Interferon beta-1a	DEX (the dosage is not available)	Imipenem, vancomycin, ceftriaxone	No

Duration from COVID-19 to mucormycosis	Duration from symptom to admission (days)	Clinical finding	Radiological findings	Site of infection	Mycological criteria		Antifungal / surgical therapy	Duration of admission (days)	Outcome
					Smear	Pathology			
8	1	Ocular symptoms: periorbital and retro-orbital pain, restriction of eye movements, rapid vision loss General symptoms: headache Facial symptoms: numbness Nasal symptoms: rhinorrhea	CT Scan: soft-tissue thickness along the paranasal sinuses (maxillary, ethmoid, sphenoid)	Rhino-sino-orbital	■	■	Debridement (1 time), exenteration eye, amphotericin B liposomal	15	Alive
14	7	Ocular symptoms: periorbital and retro-orbital pain, restriction of eye movements and rapid vision loss General symptoms: headache, lethargy Facial symptoms: numbness Nasal symptoms: rhinorrhea	CT Scan: soft-tissue thickness along the paranasal sinuses (maxillary, ethmoid, sphenoid) MRI: cavernous and selatorcia dilatation, which suggests cavernous sinus thrombosis	Rhino-sino-orbital	■	■	Debridement (2 times), amphotericin B	18	Died
16	6	Ocular symptoms: periorbital and retro-orbital pain, restriction of eye movements and rapid vision loss General symptoms: headache, lethargy Facial symptoms: numbness weakness Nasal symptoms: rhinorrhea	CT Scan: soft-tissue thickness along the paranasal sinuses (maxillary, ethmoid, sphenoid)	Rhino-sino-orbital	■	■	Debridement(2 times), FESS, amphotericin B liposomal	30	Died
30	4	Ocular symptoms: periorbital and retro-orbital pain, restriction of eye movements and rapid vision loss General symptoms: headache, lethargy Facial symptoms: numbness weakness Nasal symptoms: rhinorrhea, epistaxis	CT Scan: soft-tissue thickness along the maxillary sinuses, left eye proptosis, hazines and stranding in retrobulbar space	Rhino-sino-orbital	■	■	Debridement (1 time), FESS, exenteration eye left, amphotericin B liposomal	11	Died

(Continues)

TABLE 1 (Continued)

Cases	Age/ sex	Comorbidities	Diagnosis of COVID-19		Anti-viral/ immunomodulator treatment for COVID-19	In-hospital corticosteroid treatment for COVID-19	Antibiotic treatment for COVID-19	ICU administration due to COVID-19
			PCR	CT scan				
10**	F/54	DM, kidney transplantation, CKD, HTN	Positive	NA	Interferon beta-1a, intravenous immunoglobulin	First admission: DEX (4 mg daily for 4 days), PSL (100 mg daily for 4 days), second admission: DEX (BD) (4 mg for 6 days), DEX(BD) (8 mg for 6 days), mPSL(QID) (300 mg for 7 days)	Imipenem, amphotricin B, vancomycin, metronidazole, azithromycin	No
11	M/57	DM	Positive	Positive	Favipiravir, sofosbuvir+daclatasvir	DEX(BD) (8 mg for 3 days), subsequent, DEX (BD) (24 mg for 4 days), DEX (BD) (16 mg for 2 days)	Amphotricin B	No
12	M/48	DM, IHD, CKD, HTN	Positive	Positive	Interferon beta-1a, remdesivir, sofosbuvir+daclatasvir	DEX (TDS) (8 mg for 3 days), subsequent, DEX (BD) (8 mg for 4 days), mPSL(500 mg daily for 3 days)	Colchicin, linezolid	Yes

Abbreviations: F, female; M, male; DM, diabetes mellitus; HTN, hypertension; IHD, ischemic heart disease; CKD, chronic kidney disease; FESS, functional endoscopic sinus surgery; DEX, dexamethason; mPSL, methylprednisolone; NA, not available.

*Cases 2 and 3 were hospitalized due to COVID-19 in Tehran and Ilam provinces, respectively, and received COVID-19 treatment there.;

**The patient received prednisolone, tacrolimus and mycophenolic acid for renal transplantation.

Although we found an increase in LDH level (6 out of 12 cases), we think it is a non-specific finding in COVID-19 patients with rhino-orbital mucormycosis. We know that the increase in LDH indicates damage to a number of different tissues; therefore, it can be considered as the effect of the inflammatory response on tissue damage associated with mucormycosis.³² Serum LDH also has been identified as a potential biomarker for the activity and severity of COVID-19.³³

This study had several limitations including lack of culture for mucor due to insufficient laboratory biosafety conditions and the potential risk SARS-CoV-2 spread and a short follow-up period. In addition, some patients were referred to our hospital for diagnosing the cause of the disease and detailed information on COVID-19 care was not available.

5 | CONCLUSIONS

We found a high incidence of mucormycosis among COVID-19 patients in our province. We also hypothesise that the actual number of the cases of COVID-19-associated mucormycosis is higher than the published cases and this disease may be underestimated due to the difficulties in diagnosis and non-specific symptoms as two of the patients received COVID-19 treatment in other provinces. Physicians should know the signs and symptoms of the disease so that a timely diagnosis and therapy can be performed. It is necessary to carefully check the blood sugar levels of patients during and after hospitalisation due to COVID-19 and actively monitor the possibility of palate and nasal infection in all of hospitalised COVID-19 patients, especially

Duration from COVID-19 to mucormycosis	Duration from symptom to admission (days)	Clinical finding	Radiological findings	Site of infection	Mycological criteria		Antifungal / surgical therapy	Duration of admission (days)	Outcome
					Smear	Pathology			
45	1	Ocular symptoms: periorbital and retro-orbital pain, restriction of eye movements and slowly vision loss, ptosis General symptoms: headache Facial symptoms: - Nasal symptoms: -	CT Scan: soft-tissue thickness along the paranasal sinuses (pansinusitis) MRI: pansinusitis, a subprismatic abscess near the left papillary lamina that extends into the orbital space, causing compression of the medial rectus muscle	Rhino-sino-orbital	■	■	Debridement (3 times), FESS, amphotericin B liposomal	2	Alive
33	2	Ocular symptoms: - General symptoms: - Facial symptoms: - Nasal symptoms: rhinorrhea, epistaxis	MRI: soft-tissue thickness along the paranasal sinuses (maxillary, ethmoid, sphenoid)	Rhino-sino	■	■	Debridement (4 times), amphotericin B	22	Alive
20	10	Ocular symptoms: periorbital and retro-orbital pain, restriction of eye movements, rapid vision loss General symptoms: headache, lethargy Facial symptoms: numbness, weakness Nasal symptoms: rhinorrhea	CT Scan: soft-tissue thickness along the maxillary sinuses, left eye proptosis, haziness and stranding in retrobulbar space	Rhino-sino-orbital	■	■	Debridement (2 times), FESS, exenteration eye left, amphotericin B liposomal	10	Died

high-risk patients. It is also important to educate patient to identify the early signs and symptoms of rhino-orbital mucormycosis.

ETHICS APPROVAL AND CONSENT TO PARTICIPATE

The protocol was approved by the Kermanshah University of Medical Sciences Ethics Committee [IR.KUMS.REC.1399.1180].

ACKNOWLEDGEMENTS

The authors would like to thank clinical Research Development Unit of Imam Khomeini, Mohammad Kermanshahi and Farabi Hospital, Kermanshah University of Medical Sciences, Kermanshah, Iran, for their support, cooperation and assistance throughout the period of study. We also extend our thanks to the Clinical Research

Development Center of Imam Reza Hospital affiliated to Kermanshah University of Medical Sciences, Kermanshah, Iran, for their kind help.

CONFLICT OF INTEREST

The authors declare that they have no conflict of interest.

AUTHOR CONTRIBUTION

Manoochehr Avatef-Fazeli: Conceptualization (equal); Data curation (equal); Investigation (equal); Methodology (equal); Project administration (equal); Resources (equal); Supervision (equal); Validation (equal); Visualization (equal). **Leila Rezaeia:** Conceptualization (equal); Data curation (equal); Investigation (equal); Methodology (equal); Project administration (equal); Resources (equal); Supervision (equal); Validation

Measure	Reference range	
White-cell count (WBC) × 10 ³ /ml	4–10	10.25 ± 7.0
Lymphocyte × 10 ³ /ml	0.8–4.8	0.97
Neutrophils × 10 ³ /ml	1.8–7.7	7.54
Haemoglobin (HB), g/dl	12–17	11.35 ± 2.25
Serum glutamic-oxaloacetic transaminase, (SGOT), U/L	5–45	22.12 ± 9.65
Serum glutamic-pyruvic transaminase (SGPT), U/L	5–45	27.00 ± 8.58
Alkaline phosphatase (ALP), U/L	80–306	267.62 ± 114.53
Creatinine (Cr), mg/dl	0.6–1.6	2.44 ± 2.29
Lactate dehydrogenase (LDH), U/L	<450	759.86 ± 391.13
Blood sugar (BS), mg/dl		316.10 ± 198.13
Erythrocyte sedimentation rate (ESR), mm/h	0–20	52.57 ± 30.69

TABLE 2 Laboratory findings of COVID-19 patients with mucormycosis on admission

(equal); Visualization (equal). **Etrat Javadirad**: Methodology (equal). **Khosro Iranfar**: Data curation (equal). **Mohamadmehti Parandin**: Data curation (equal); Investigation (equal). **Amrollah Dehghani**: Data curation (equal); Investigation (equal). **Abbas Khosravi**: Data curation (equal). **Javad Amini Saman**: Supervision (equal). **Pardis Poursabbagh**: Data curation (equal). **Touraj Ahmadi Jouybari**: Data curation (equal); Investigation (equal). **Mohammad Rasool Ghadami**: Data curation (equal); Writing-review & editing (equal). **Behzad Mahdavian**: Data curation (equal); Investigation (equal). **Nastaran Eivazi**: Data curation (equal); Methodology (equal). **Sohbat Rezaei**: Data curation (equal); Investigation (equal). **Alireza Rezaei**: Data curation (equal); Investigation (equal). **Bashir Emami**: Data curation (equal). **Arezoo Bozorgomid**: Data curation (equal); Formal analysis (equal); Writing-original draft (equal); Writing-review & editing (equal). **Babak Sayad**: Investigation (equal); Project administration (equal); Supervision (equal); Writing-review & editing (equal).

AUTHOR CONTRIBUTION

AB, AK, PP and R. G. contributed to acquisition of data, draft the article and agree to be accountable for all aspects of the work related to its accuracy or integrity. MAF, L. R., E. J., K. I., MMP, AD, JAS, TAJ, BM, NE, SR, MH, BS and B. E. contributed to acquisition of clinical data, agreed to be accountable for all aspects of the work related to its accuracy or integrity and reviewed the manuscript critically for important intellectual content. AB, BS, MAF and L. R. contributed to analysis and interpretation of data and agreed to be accountable for all aspects of the work related to its accuracy or integrity. MAF, L.R and B. S. made substantial contributions to conception and design of the study, given final approval of the version to be published and agreed to be accountable for all aspects of the work related to its accuracy or integrity.

ORCID

Arezoo Bozorgomid  <https://orcid.org/0000-0003-2093-9317>

REFERENCES

- Sayad B, Khodarahmi R, Najafi F, et al. Efficacy and safety of sofosbuvir/velpatasvir versus the standard of care in adults hospitalized with COVID-19: a single-centre, randomized controlled trial. *J Antimicrob Chemother.* 2021;dkab152. <https://doi.org/10.1093/jac/dkab152>
- Song G, Liang G, Liu W. Fungal co-infections associated with global COVID-19 pandemic: a clinical and diagnostic perspective from China. *Mycopathologia.* 2020;185(4):1-8.
- Gangneux JP, Bougnoux ME, Dannaoui E, Cornet M, Zahar JR. Invasive fungal diseases during COVID-19: we should be prepared. *J Mycol Med.* 2020;30(2):100971.
- Rawson TM, Moore LS, Zhu N, et al. Bacterial and fungal coinfection in individuals with coronavirus: a rapid review to support COVID-19 antimicrobial prescribing. *Clin Infect Dis.* 2020;71(9):2459-2468. <https://doi.org/10.1093/cid/cia530>
- Hernández JL, Mucormycosis BCJ. [Updated 2020 Jun 26]. In: *StatPearls [Internet]*. Treasure Island (FL): StatPearls Publishing; 2021 Jan. Available from: <https://www.ncbi.nlm.nih.gov/books/NBK544364/>
- Petrikos G, Skiada A, Lortholary O, et al. Epidemiology and clinical manifestations of mucormycosis. *Clin Infect Dis.* 2012;54(Suppl. 1):S23-34. <https://doi.org/10.1093/cid/cir866>
- Skiada A, Lass-Floerl C, Klimko N, et al. Challenges in the diagnosis and treatment of mucormycosis. *Med Mycol.* 2018;56(suppl_1):S93-S101. <https://doi.org/10.1093/mmy/myx101>
- Moorthy A, Gaikwad R, Krishna S, et al. SARS-CoV-2, uncontrolled diabetes and corticosteroids—an unholy trinity in invasive fungal infections of the maxillofacial region? a retrospective, multi-centric analysis. *J Maxillofac Oral Surg.* 2021;1-8. <https://doi.org/10.1007/s12663-021-01532-1>
- Garg D, Muthu V, Sehgal IS, et al. Coronavirus disease (Covid-19) associated mucormycosis (CAM): case report and systematic review of literature. *Mycopathologia.* 2021;186(2):289-298. <https://doi.org/10.1007/s11046-021-00528-2>
- Donnelly JP, Chen SC, Kauffman CA, et al. Revision and update of the consensus definitions of invasive fungal disease from the European Organization for Research and Treatment of Cancer and the Mycoses Study Group Education and Research Consortium. *Clin Infect Dis.* 2020;71(6):1367-1376. <https://doi.org/10.1093/cid/ciz1008>
- Ahmadikia K, Hashemi SJ, Khodavaisy S, et al. The double-edged sword of systemic corticosteroid therapy in viral pneumonia: a case report and comparative review of influenza associated mucormycosis versus COVID-19 associated mucormycosis. *Mycoses.* 2021. <https://doi.org/10.1111/myc.13256>
- Samareh R, Gharebaghi N, Zayer S. Evaluation of 30 cases of mucormycosis at a university hospital in Iran. *Mycoses.* 2017;60(7):426-432. <https://doi.org/10.1111/myc.12614>

13. Kontoyiannis DP, Yang H, Song J, et al. Prevalence, clinical and economic burden of mucormycosis-related hospitalizations in the United States: a retrospective study. *BMC Infect Dis*. 2016;16(1):730. <https://doi.org/10.1186/s12879-016-2023-z>
14. Bonifaz A, Tirado-Sánchez A, Hernández-Medel ML, et al. Mucormycosis at a tertiary-care center in Mexico. a 35-year retrospective study of 214 cases. *Mycoses*. 2021;64(4):372-380.
15. Kalantari H, Tabrizi AHH, Foroohi F. Determination of COVID-19 prevalence with regards to age range of patients referring to the hospitals located in western Tehran. *Iran. Gene Rep*. 2020;21:100910. <https://doi.org/10.1016/j.genrep.2020.100910>
16. Dolatabadi S, Ahmadi B, Rezaei-Matehkolaei A, et al. Mucormycosis in Iran: a six-year retrospective experience. *J Mycol Med*. 2018;28(2):269-273. <https://doi.org/10.1016/j.mycmed.2018.02.014>
17. Mirzaei M, Rahmaninan M, Mirzaei M, Nadjarzadeh A. Epidemiology of diabetes mellitus, pre-diabetes, undiagnosed and uncontrolled diabetes in Central Iran: results from Yazd health study. *BMC Public Health*. 2020;20(1):166. <https://doi.org/10.1186/s12889-020-8267-y>
18. Esteghamati A, Larijani B, Aghajani MH, et al. Diabetes in Iran: prospective analysis from first nationwide diabetes report of national program for prevention and control of diabetes (NPPCD-2016). *Sci Rep*. 2017;7(1):13461. <https://doi.org/10.1038/s41598-017-13379-z>
19. Castelli V, Cimini A, Ferri C. Cytokine storm in COVID-19: "when you come out of the storm, you won't be the same person who walked in". *Front Immunol*. 2020;11:2132. <https://doi.org/10.3389/fimmu.2020.02132>
20. Liberman AC, Budziński ML, Sokn C, et al. Regulatory and mechanistic actions of glucocorticoids on T and inflammatory cells. *Front Endocrinol (Lausanne)*. 2018;9:235. <https://doi.org/10.3389/fendo.2018.00235>
21. Group RC. Dexamethasone in hospitalized patients with Covid-19—preliminary report. *N Engl J Med*. 2021;384(8):693-704. <https://doi.org/10.1056/NEJMoa2021436>
22. Wang Y, Jiang W, He Q, et al. *Early, Low-Dose and Short-Term Application Of Corticosteroid Treatment In Patients With Severe Covid-19 Pneumonia: Single-Center Experience From Wuhan*. MedRxiv: China; 2020.
23. Jeong W, Keighley C, Wolfe R, et al. The epidemiology and clinical manifestations of mucormycosis: a systematic review and meta-analysis of case reports. *Clin Microbiol Infect*. 2019;25(1):26-34. <https://doi.org/10.1016/j.cmi.2018.07.011>
24. Vaezi A, Moazeni M, Rahimi MT, de Hoog S, Badali H. Mucormycosis in Iran: a systematic review. *Mycoses*. 2016;59(7):402-415. <https://doi.org/10.1111/myc.12474>
25. Patel A, Kaur H, Xess I, et al. A multicentre observational study on the epidemiology, risk factors, management and outcomes of mucormycosis in India. *Clin Microbiol Infect*. 2020;26(7):944.e9-944.e15. <https://doi.org/10.1016/j.cmi.2019.11.021>
26. Corzo-León DE, Chora-Hernández LD, Rodríguez-Zulueta AP, Walsh TJ. Diabetes mellitus as the major risk factor for mucormycosis in Mexico: epidemiology, diagnosis, and outcomes of reported cases. *Med Mycol*. 2018;56(1):29-43. <https://doi.org/10.1093/mmy/myx017>
27. Alessi J, De Oliveira GB, Schaan BD, Telo GH. Dexamethasone in the era of COVID-19: friend or foe? an essay on the effects of dexamethasone and the potential risks of its inadvertent use in patients with diabetes. *Diabetol Metab Syndr*. 2020;12:80. <https://doi.org/10.1186/s13098-020-00583-7>
28. Papachristou S, Stamatou I, Stoian AP, Papanas N. New-onset diabetes in COVID-19: time to frame its fearful symmetry. *Diabetes Ther*. 2021;12(2):461-464. <https://doi.org/10.1007/s13300-020-00988-7>
29. Muggeo P, Calore E, Decembrino N, et al. Invasive mucormycosis in children with cancer: a retrospective study from the Infection working group of italian pediatric hematology oncology association. *Mycoses*. 2019;62(2):165-170. <https://doi.org/10.1111/myc.12862>
30. Chakrabarti A, Das A, Mandal J, et al. The rising trend of invasive zygomycosis in patients with uncontrolled diabetes mellitus. *Med Mycol*. 2006;44(4):335-342. <https://doi.org/10.1080/13693780500464930>
31. Cornely OA, Alastruey-Izquierdo A, Arenz D, et al. Global guideline for the diagnosis and management of mucormycosis: an initiative of the European confederation of medical mycology in cooperation with the mycoses study group education and research consortium. *Lancet Infect Dis*. 2019;19(12):e405-e421. [https://doi.org/10.1016/S1473-3099\(19\)30312-3](https://doi.org/10.1016/S1473-3099(19)30312-3)
32. Belic S, Page L, Lazariotou M, et al. Comparative analysis of inflammatory cytokine release and alveolar epithelial barrier invasion in a transwell® bilayer model of mucormycosis. *Front Microbiol*. 2019;9:3204. <https://doi.org/10.3389/fmicb.2018.03204>
33. Martha JW, Wibowo A, Pranata R. Prognostic value of elevated lactate dehydrogenase in patients with COVID-19: a systematic review and meta-analysis. *Postgrad Med J*. 2021;postgradmedj-2020-139542. <https://doi.org/10.1136/postgradmedj-2020-139542>

How to cite this article: Avatef Fazeli M, Rezaei L, Javadirad E, et al. Increased incidence of rhino-orbital mucormycosis in an educational therapeutic hospital during the COVID-19 pandemic in western Iran: An observational study. *Mycoses*. 2021;64:1366-1377. <https://doi.org/10.1111/myc.13351>