

This article is licensed under the Creative Commons Attribution-NonCommercial 4.0 International License (CC BY-NC) (<http://www.karger.com/Services/OpenAccessLicense>). Usage and distribution for commercial purposes requires written permission.

Case Report

Implantation of a Multifocal Toric Intraocular Lens after Radial Keratotomy and Cross-Linking with Hyperopia and Astigmatism Residues: A Case Report

Raffaele Nuzzi Francesca Monteu Federico Tridico

Institute of Ophthalmology, Department of Surgical Sciences, University of Turin, Turin, Italy

Keywords

Hyperopic shift · Astigmatism · Radial keratotomy · Cross-linking · Multifocal toric intraocular lens

Abstract

Radial keratotomy is a refractive surgical technique, widely used in the 80s and early 90s to correct myopia and astigmatism, but now overcome by more recent laser techniques. Important consequences, often in patients with more than 45 years of age, are progressive hyperopic shift and/or an increase in corneal astigmatism, whose main cause seems to be an increase in the curvature radius of the central portion of the cornea. This seems to be due to radial keratotomy incisions – with the consequent need for cross-linking – intraocular pressure, and corneal biomechanical parameters. The authors propose phacoemulsification with a customized multifocal toric intraocular lens implantation to correct the induced shift and hyperopic astigmatism. A decent postoperative visual acuity was observed with good patient satisfaction. A specific protocol must be applied to optimize the correct diagnosis, presurgical evaluation and postsurgical outcomes that are to be maintained over time, without regressions.

© 2017 The Author(s)
Published by S. Karger AG, Basel

KARGER

Prof. Raffaele Nuzzi
Institute of Ophthalmology, Department of Surgical Sciences
University of Turin, Via Juvarra 19
IT–10100 Turin (Italy)
E-Mail prof.nuzzi_raffaele@hotmail.it

Introduction

Radial keratotomy (RK) is a refractive surgical technique, consisting of penetrating anterior corneal incisions (whose direction coincides with the one of the imaginary radius originating from the corneal circumference) performed leaving intact the central area for a diameter of at least 3 mm. This technique has been used extensively in the 80s and early 90s to correct myopia and astigmatism, but, at the present day, it has been supplanted by laser techniques. Main complications include central corneal perforation, astigmatism onset, reduced visual acuity, or – in case of patients achieving a proper refractive correction – fluctuation of visual acuity, reduced contrast sensitivity, changes in mesopic vision, unreliability of tonometric measurements, the possibility of intraocular lenses (IOLs) power calculation errors, a progressive hyperopic shift and/or an increase in corneal astigmatism.

Most of the hyperopic shifts occur, according to the literature, in patients aged more than 45–50 years, primarily in those whose post-RK refraction tended towards emmetropy. The main cause seems to be an increase in the central corneal curvature radius, with a consequent reduction in the central curvature, in addition to a reduction in the peripheral curvature radius. Clinical signs of decreased corneal rigidity include visual acuity fluctuations, increased susceptibility to corneal trauma, and risk of corneal incision ruptures during cataract surgery. The main contribution to this process is given by the same RK incisions, intraocular pressure and corneal biomechanical parameters, including its resistance to deformation under load. After an RK, the hyperopic shift is mainly due to an intraocular pressure increase and reduced corneal rigidity. In these conditions, the risk of glaucoma development is not tied to changes at the level of the lamina cribrosa, but to corneal changes. Patients undergoing RK and progressive hyperopia should be considered at increased risk of glaucoma [1, 2].

The purpose of this study was to describe the possible use of a customized toric IOL for the management of a hyperopic shift due to RK and cross-linking (associated with astigmatism), discussing its indications, limitations, and prospects in clinical practice.

Materials and Methods

We report the case of a 46-year-old man, who has come to our attention for cataract evaluation. He had good health conditions and a history of RK with 16 incisions performed in 1991, when he was 22 years old, for moderate myopia, followed by cross-linking after 1 year. Biometric and topographic data prior to refractive surgery and cross-linking were not available since the patient could not provide any previous documentation. The best-corrected visual acuity in the right eye was 6–7/10 with +3.25 D sph +4.50 D cyl 20°, while the one for the left eye was 6/10 with +3.75 D sph +4.00 D cyl 140°. Intraocular pressure in the right eye was 18 mm Hg (G), while the one in the left eye was 17 mm Hg (G). At the time of the clinical evaluation, the lens in the right eye presented anterior cortical opacities and nuclear sclerosis, while the left eye suffered from anterior cortical opacities, nuclear sclerosis, and posterior subcapsular cataract. We performed corneal OCT, corneal topography, and corneal pachymetry at 8 a.m. (OD 538 µm, OS 535 µm), 1 p.m. (OD 536 µm, 530 µm OS), and 5 p.m. (OD 540 µm, OS 520 µm), the Schirmer test, pupillometry, ultrasound and optical bi-

ometry, and orthoptic evaluation. Topographic values are shown in [Figure 1](#). Finally, ocular biometric values were determined by optical biometry with Zeiss IOL Master, using both SRK/T and Holladay1 formulas for IOL calculation (no significant differences in IOL power have been identified using different formulas). Afterwards, the patient underwent binocular phacoemulsification with implantation of a custom multifocal IOL (FIL611PVT produced by Soleko, Ltd., Rome, Italy).

Results

Visual outcomes are summarized in [Table 1](#). Postoperative topographic values are shown in [Figure 2](#). The first day after surgery, distance visual acuity in the left eye was 10/10 with +2 D cyl 120° and near visual acuity was Jaeger II without additional correction. The left eye's intraocular pressure was 16 mm Hg (G). Seven days after surgery, the OS distance visual acuity was 10/10 with +2 D cyl 120°, while near visual acuity was Jaeger II without additional correction and the intraocular pressure was 14 mm Hg (G). Thirty days after surgery, the OS visual acuity was 10/10 without correction for far, Jaeger I without additional correction for near.

Two months later, surgery was also performed in the right eye. The first day after surgery, distance visual acuity was 9/10 with +1 D sph +1 D cyl 180°, Jaeger I for close-up distance with a spherical correction of +2 D. Intraocular pressure was 14 mm Hg (G). Seven days after surgery, the visual acuity was 10/10 for far with +1 D sph, Jaeger II for near without correction, while the intraocular pressure was 16 mm Hg (G). Thirty days after surgery, visual acuity was 10/10 without correction for far and Jaeger I for near without correction.

Thirteen months after surgery, visual performance was unchanged in both eyes. Subjectively and in relation to vision quality, the patient did not complain about any inconvenience during the whole follow-up period.

Discussion

With regard to visual acuity correction in patients undergoing RK with hyperopic shift and presbyopia, a possible and well-tolerated solution is represented by the implantation of multifocal IOLs, as reported by Kim et al. [3] and Gupta et al. [4].

The preoperative evaluation in the field of cataract surgery in patients undergoing RK is more complicated, because it is easier to overestimate the corneal refractive power and thus underestimate the power of the lens. The keratometry data obtained from corneal topography is less precise, with flat corneas in the central zone and curvier in the peripheral areas. The keratometry analyzes an annular region around the central portion of the cornea, overestimating the actual refractive power [5, 6]. Thus, repeated keratometric measurements, at different times, are necessary and a comparison of objective measurement methods (Pentacam topography and keratometry of the IOL Master) must be performed in order to reduce the error by obtaining a value that is as repeatable as possible. The best formula for IOL calculation was not detected, since both the SRK/T and Holladay1 have not shown marked superiority. The algorithm for the post-RK IOL calculation used by the online calculator of the

American Society for Cataract and Refractive Surgery may be useful for IOL calculation in these patients [7], but its application cannot be extended to toric multifocal IOLs (which are useful in correcting astigmatic defect and provide greater postoperative spectacle independence). In our case, we evaluated both keratometry values obtained with Pentacam corneal topography and those obtained with IOL Master: in all these cases, repeated tests must be carried out until the best statistical and repeatable values are achieved. In the preoperative assessment (especially if it is not possible to retrieve biometric data prior to refractive surgery), biometric and topographic measurements should be repeated 2–3 times/week at different times of the day (morning and noon/afternoon) until concordant results (stable for 3 consecutive examinations, like in our case). Measurements can be performed with less frequency (1–2 times/week) if stability of values is found early. Given that, the use of a personalized multifocal toric IOL, designed in accordance with patients' ocular characteristics, can be useful in order to avoid future corneal procedures for astigmatism correction and provide higher postoperative spectacle independence. Moreover, a heavy molecular weight viscoelastic should be utilized in order to prevent corneal stress and preserve the endothelial layer.

Conclusions

The management of this particular case with the implantation of a customized toric multifocal IOL was well tolerated and has achieved good results, without regressions. The need for more invasive procedures such as penetrating keratoplasty was also averted. In fact, in these cases, a deep anterior lamellar keratoplasty cannot be applied, and the only remaining solution, with the aim of decreasing the risk of important postsurgical astigmatism, is penetrating keratoplasty with a “mushroom” profile, which is, however, associated with a higher risk of perforation during surgery.

A specific protocol remains to be designed in order to optimize proper ophthalmological diagnosis, therapy with soft/hard/gas-permeable contact lenses, in-depth preoperative evaluation, and postoperative visual result which must be maintained over time, averting regressions. Given that, the application of personalized multifocal toric IOL can still be considered as an alternative and promising prospective in the management of these particular patients, in order to achieve the best refractive results.

Statement of Ethics

Informed consent for the procedure reported in this case report has been obtained from the subject of this study, in written form. Our Institution stated that no formal ethical approval was needed for this case report.

Disclosure Statement

The authors declare that there is no conflict of interest involved in the realization of the manuscript.

References

- 1 Avetisov SE, Antonov AA, Vostrukhin SV: Progressive hyperopic shift after radial keratotomy: possible causes. *Vestn Oftalmol* 2015;2:13–18.
- 2 Cho BJ, Shin JY, Yu HG: Complications of pathologic myopia. *Eye Contact Lens* 2016;42:9–15.
- 3 Kim KH, Seok KW, Kim WS: Multifocal intraocular lens results in correcting presbyopia in eyes after radial keratotomy. *Eye Contact Lens* 2015, Epub ahead of print.
- 4 Gupta I, Oakey Z, Ahmed F, Ambati BK: Spectacle independence after cataract extraction in post-radial keratotomy patients using hybrid monovision with ReSTOR® multifocal and TECNIS® monofocal intraocular lenses. *Case Rep Ophthalmol* 2014;5:157–161.
- 5 Frings A, Hold V, Steinwender G, El-Shabrawi Y, Ardjomand N: Use of true net power in intraocular lens power calculations in eyes with prior myopic laser refractive surgery. *Int Ophthalmol* 2014;34:1091–1096.
- 6 Li Y, Liu Y, Chen Y, Li M, Long L: Cataract surgery and intraocular lens power calculation after radial keratotomy: analysis of 8 cases. *Nan Fang Yi Ke Da Xue Xue Bao* 2015;35:1043–1044.
- 7 IOL calculator for eyes with prior RK. <http://iolcalc.ascrs.org/wbfrmCalculator3.aspx> (accessed March 5, 2017).

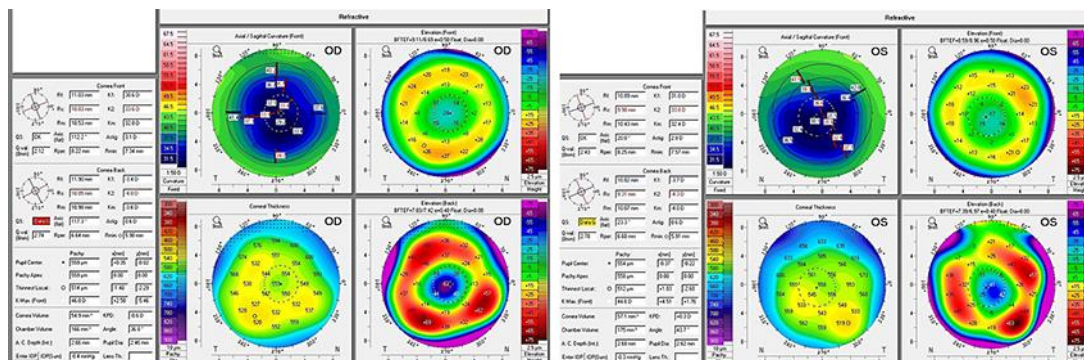


Fig. 1. Preoperative stable refractive topography with Oculus Pentacam. OD, right eye; OS, left eye.

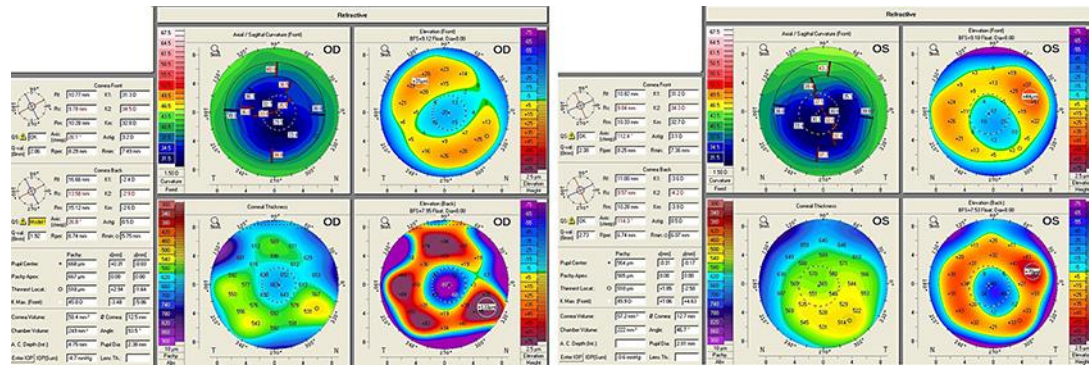


Fig. 2. Refractive topography with Oculus Pentacam 12 months after surgery. OD, right eye; OS, left eye.

Table 1. Postoperative visual outcomes (correction required to achieve best-corrected vision)

		Postoperative visual acuity					
		1 day	7 days	30 days	3 months	6 months	1 year
Right eye	Distance visual acuity (decimals)	9/10 (+1 D sph +1 D cyl 180°)	10/10 (+1 sph D)	10/10	10/10	10/10	10/10
	Near visual acuity (Jaeger)	Jaeger I (+2 D sph)	Jaeger II	Jaeger I	Jaeger I	Jaeger I	Jaeger I
Left eye	Distance visual acuity (decimals)	10/10 (+2 D cyl 120°)	10/10 (+2 D cyl 120°)	10/10	10/10	10/10	10/10
	Near visual acuity (Jaeger)	Jaeger II	Jaeger II	Jaeger I	Jaeger I	Jaeger I	Jaeger I