

Neurofibromatosis type 1 with tarsal conjunctiva thickening

A case report

Joo Young Kim, MD, Mee Yon Lee, MD, PhD, Young Chun Lee, MD, PhD, Hye-Young Shin, MD, PhD*

Abstract

Rationale: We report a rare case of neurofibroma in the form of tarsal conjunctival thickening of the eyelid in patients with neurofibromatosis type 1 (NF1), common ocular complications of which are Lisch nodules, choroidal nodules, and optic nerve glioma.

Patient concerns: A 46-year-old female patient was diagnosed with neurofibroma after biopsy and removal of 2 lumbar level intradural masses 15 years ago. She was being monitored without recurrence. When the patient visited our hospital, multiple iris Lisch nodules were found in both her eyes with ill-defined, diffuse thickening in the upper eyelid tarsal conjunctiva of the right eye.

Diagnosis: Neurofibroma was diagnosed by incisional biopsy and immunohistochemistry of the tarsal conjunctiva.

Interventions: The patient of the present case did not undergo any additional surgical treatment because tarsal conjunctiva thickening caused little functional problem.

Outcomes: The patient has only been regularly examined for changes in size of neurofibroma, and there was no change in size over a 12-month period.

Lessons: Neurofibroma should be considered as a differential diagnosis if a patient diagnosed with NF1 shows tarsal conjunctiva thickening.

Abbreviations: MRI = magnetic resonance image, NF1 = neurofibromatosis type 1, NIR = near-infrared reflectance, OCT = optical coherence tomography.

Keywords: Lisch nodule, neurofibroma, neurofibromatosis type 1, tarsal conjunctiva

1. Introduction

Neurofibromatosis type 1 (NF1, von Recklinghausen disease), an autosomal dominant inherited disorder caused by a heterozygous mutation of NF1 gene on chromosome 17, has a morbidity rate of 1/3000 to 1/5000. Its clinical manifestations vary from person to person. Symptoms of multiple neurofibroma (café au lait spot, freckles in the axillary or inguinal regions, pigmentary iris hamartoma (Lisch nodule), optic nerve glioma, and various types of bone abnormality) are common. Sometimes they accompany fatal symptoms such as malignant peripheral nerve sheath tumor,

brain tumor, and vasculopathy that can destroy main arteries of brain and heart.^[1]

This report presents a rare case of eyelid neurofibroma diagnosed by incisional biopsy of an ill-defined diffuse tarsal conjunctiva thickening in a patient diagnosed with NF1. Patient has provided informed consent for publication of the case.

2. Case reports

A 46-year-old Asian female patient presented with low back pain 15 years ago. A spinal magnetic resonance image (MRI) revealed 2 intradural masses at L3, L4, and L5 levels. After she was diagnosed with neurofibroma by biopsy, she underwent tumor resection (Fig. 1). She had multiple subcutaneous neurofibromas and café au lait spot, and her father and sister were diagnosed with NF1. The patient satisfied more than 2 diagnosis criteria of NF1. However, she did not receive any ophthalmologic examination at that time.

Fifteen years later, she went to an ophthalmology clinic for a regular checkup. Her visual acuity was 20/20 for each eye, and the intraocular pressure was normal. There was ill-defined, diffuse tarsal conjunctiva thickening in the upper eyelid of the right eye (Fig. 2). A large number of Lisch nodules were found in both eyes (Fig. 3). Optical coherence tomography (OCT) images of the choroid showed multiple bright patchy regions typical of NF1 (Fig. 4). Orbit MRI revealed no specific findings, including the optic nerve.

Editor: N/A.

The authors report no conflicts of interest

Department of Ophthalmology, Uijeongbu St Mary's Hospital, College of Medicine, The Catholic University of Korea, Seoul, Korea.

* Correspondence: Hye-Young Shin, Department of Ophthalmology, Uijeongbu St Mary's Hospital, College of Medicine, The Catholic University of Korea, #271 Cheonbo-ro, Uijeongbu-si, Gyeonggi-do, Korea (e-mail: antares78@empal.com).

Copyright © 2019 the Author(s). Published by Wolters Kluwer Health, Inc. This is an open access article distributed under the terms of the Creative Commons Attribution-Non Commercial-No Derivatives License 4.0 (CCBY-NC-ND), where it is permissible to download and share the work provided it is properly cited. The work cannot be changed in any way or used commercially without permission from the journal.

Medicine (2019) 98:31(e16699)

Received: 31 March 2019 / Received in final form: 13 June 2019 / Accepted: 10 July 2019

<http://dx.doi.org/10.1097/MD.00000000000016699>

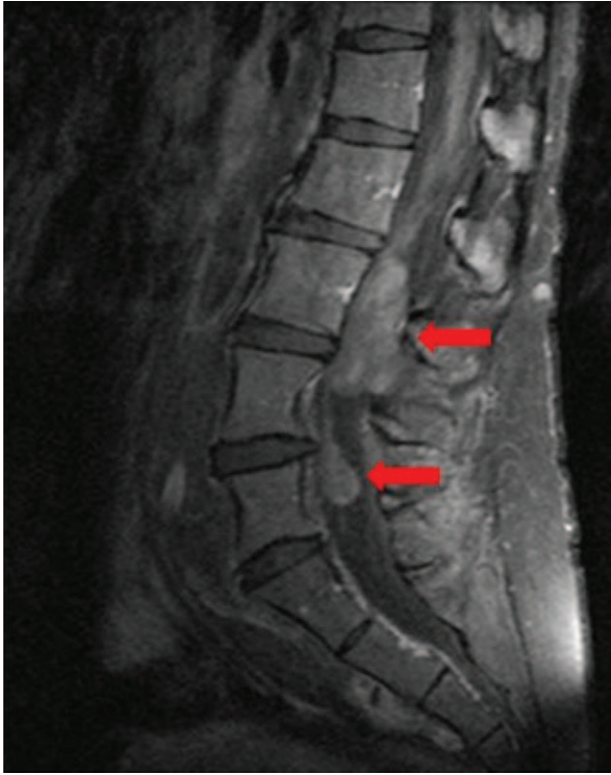

Figure 1. Sagittal T1-weighted contrast spinal magnetic resonance image showing 2 heterogeneously enhancing intradural masses at the L3, L4, and L5 levels. The upper one measures about 46 × 19mm, and the lower one measures about 18 × 12mm. These 2 masses were diagnosed as neurofibroma through biopsy. They were removed by surgery.

An incisional biopsy was conducted for the upper lid tarsal conjunctiva of the right eye under a local anesthesia. Postoperative hematoxylin and eosin staining revealed that the tumor was composed of benign-looking, wavy nuclei, and spindle-shaped cells with eosinophilic cytoplasm, and immunohistochemical staining with S-100 protein demonstrated an intense positive result (Fig. 5). Based on these findings, the patient was diagnosed with neurofibroma.

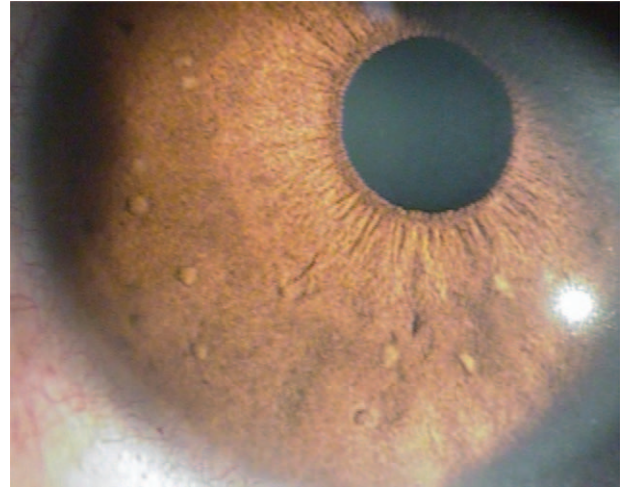


Figure 3. Clinical photographs showing a lot of Lisch nodules in the right eye.

The patient of the present case did not undergo any additional surgical treatment because tarsal conjunctiva thickening caused little functional problem. She has only been regularly examined for changes in size of neurofibroma, and there was no change in size over a 12-month period.

3. Discussion

Neurofibroma is a benign peripheral nerve sheath tumor arising from nonmyelinated Schwann cells or perineural fibroblasts or both.^[2] The most common ocular symptom is the occurrence of Lisch nodules also called iris hamartoma. Sometimes they can appear in a trabecular meshwork.^[1,3] Patients with NF1 are required to be examined regularly by an ophthalmologist because the ciliary body may show thickening. There may be signs of angle invasion by neurofibroma or Lisch nodules.^[4]

Despite not being included in the diagnostic criteria for NF1, numerous choroidal alterations are common in NF1. Choroidal alterations such as choroidal nodules are undetectable by fundus biomicroscopic examination or fluorescein angiography. More recently, the use of near-infrared reflectance (NIR) image, OCT,

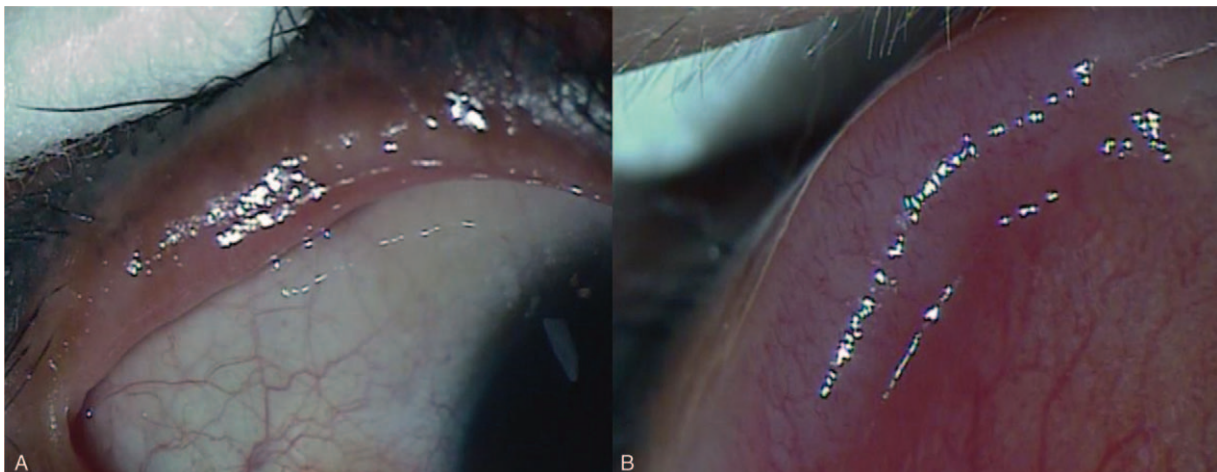


Figure 2. Clinical photographs showing ill-defined diffuse thickening lesion in the right upper tarsal conjunctiva (A, B).

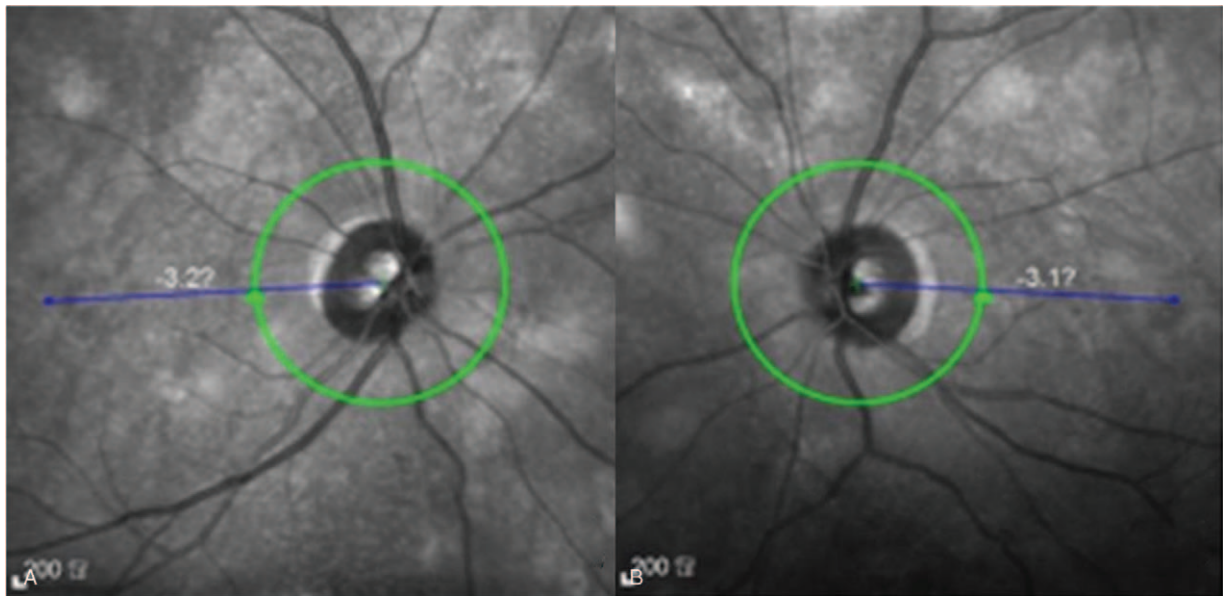


Figure 4. Optical coherence tomography images (using a near-infrared light source) of the choroid showing multiple bright patchy regions typical of neurofibromatosis type 1. (A) Right eye. (B) Left eye.

and indocyanine green angiography has improved the ability to evaluate choroidal alterations. One study has reported that about 82% of patients with NF1 have choroidal alterations.^[4,5]

Eyelid neurofibroma usually has a clinical manifestation similar to that of chalazion. Thus, it is often mistaken for chalazion.^[6,7] This is the 1st report of an eyelid neurofibroma appearing as an ill-defined diffuse tarsal conjunctiva thickening that shows clinical manifestation different from chalazion.

Eyelid tumors are basically diagnosed by histopathologic examination and immunohistochemistry to distinguish them from other malignant eyelid tumors.^[6–8] Neurofibroma is characterized by ill-defined cells with eosinophilic cytoplasm and wavy or comma-shaped nuclei within collagen fibers in hematoxylin and eosin staining. In addition, S-100 protein is generally positive in immunohistochemistry staining.^[2] If S-100

protein is positive in an eyelid tumor, schwannoma, and neurofibroma should be considered as differential diagnosis. However, in the case of schwannoma, spindle-shaped cells with Antoni type A or Antoni type B patterns should be observed in hematoxylin and eosin staining.^[2,9] This did not match with histopathologic finding of the present case. The patient was diagnosed with neurofibroma because she was diagnosed with NF1 by satisfying its diagnostic criteria 15 years ago. Biopsy of the ill-defined, diffuse tarsal conjunctival thickening showed result suitable for neurofibroma.

Most treatments for NF1 are symptomatic. Tumors that cause cosmetic or functional problems should be surgically removed. However, completely removing it is difficult because neurofibroma is deeply infiltrated. If it is not removed completely, the risk of recurrence increases. Radiation therapy is not recommended

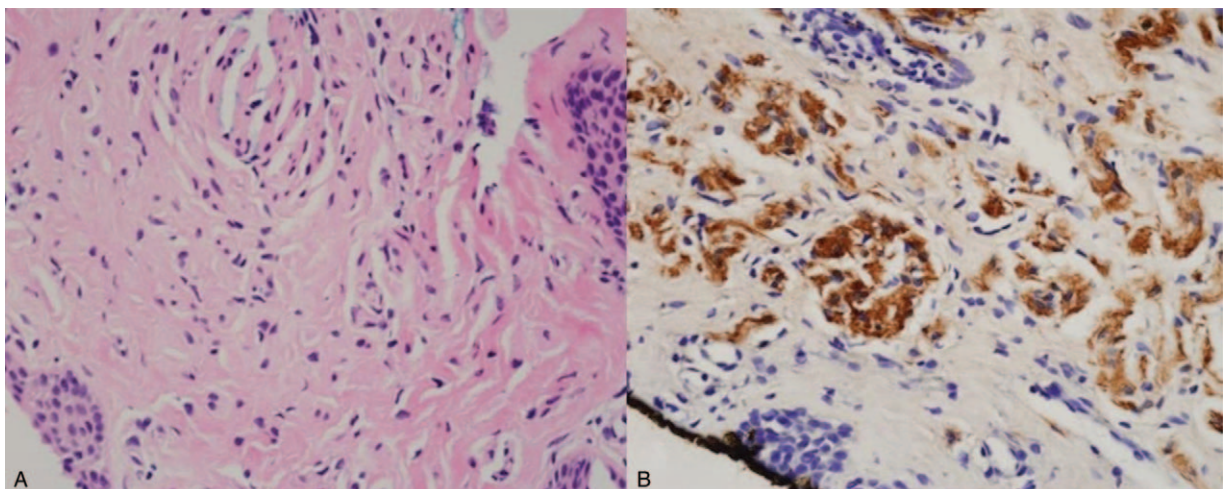


Figure 5. Histopathologic findings of thickened right upper tarsal conjunctiva. (A) Tumor was composed of benign-looking, wavy nuclei, and spindle-shaped cells with eosinophilic cytoplasm (hematoxylin-eosin, $\times 200$). (B) Tumor cells show intense positive immunohistochemical staining with S-100 protein (S-100, $\times 200$).

because of potential for conversion into malignant peripheral nerve sheath tumor.^[1,3,8,10]

In the present case, the patient who was diagnosed with NF1 due to intradural masses 15 years ago had no recurrence for 15 years. She underwent a biopsy for a tarsal conjunctiva thickening and was diagnosed with neurofibroma. In the case of a patient diagnosed with NF1, neurofibroma should be considered as a differential diagnosis even if the patient presents with atypical symptoms of neurofibroma, such as a diffuse thickening of the tarsal conjunctiva.

Author contributions

Supervision: Mee Yon Lee, Young Chun Lee.

Writing – original draft: Joo Young Kim.

Writing – review & editing: Hye-Young Shin.

References

- [1] Jett K, Friedman JM. Clinical and genetic aspects of neurofibromatosis 1. *Genet Med* 2010;12:1–1.
- [2] Calonje JE, Brenn T, McKee P, et al. *McKee's Pathology of the Skin*, 4th ed, Vol 2. Philadelphia: Elsevier Saunders; 2012. 1289.
- [3] Dimitrova V, Yordanova I, Pavlova V, et al. A case of neurofibromatosis 1. *J IMAB* 2010;63:63–7.
- [4] Abdolrahimzadeh B, Piraino DC, Albanese G, et al. Neurofibromatosis: an update of ophthalmic characteristics and applications of optical coherence tomography. *Clin Ophthalmol* 2016;10:851–60.
- [5] Viola F, Villani E, Natacci F, et al. Choroidal abnormalities detected by near-infrared reflectance imaging as a new diagnostic criterion for neurofibromatosis 1. *Ophthalmology* 2012;119:369–75.
- [6] Poonam NS, Alam MS, Das D, et al. Solitary eyelid neurofibroma presenting as tarsal cyst: report of a case and review of literature. *Am J Ophthalmol Case Rep* 2018;10:71–3.
- [7] Shibata N, Kitagawa K, Noda M, et al. Solitary neurofibroma without neurofibromatosis in the superior tarsal plate simulating a chalazion. *Graefes Arch Clin Exp Ophthalmol* 2012;50:309–10.
- [8] Lee KH, Park JW, Yoon KC. A case of neurofibromatosis of the orbit and ocular surface. *J Korean Ophthalmol Soc* 2007;48:1276–80.
- [9] Lee KW, Lee MJ, Kim NJ, et al. A case of eyelid schwannoma. *J Korean Ophthalmol Soc* 2009;50:290–3.
- [10] Kang YS, Choi W, Kim GE, et al. Solitary neurofibroma occurred on the eyelid margin without neurofibromatosis: a case report. *J Korean Ophthalmol Soc* 2017;58:222–5.