



Persistent fever after pacemaker lead extraction



Maria Carmo Pereira Nunes ^{a,*}, Túlio Pinho Navarro ^a, Mariana de Braga Lima Carvalho ^a,
Nicole de Paula Aarão Faleiro Maia ^b, Ricardo Jayme Procópio ^a,
Teresa Cristina Abreu Ferrari ^a

^a Hospital das Clínicas, School of Medicine of the Universidade Federal de Minas Gerais, Belo Horizonte, MG, Brazil

^b Faculdade de Ciências Médicas de Minas Gerais (FCMMG), Belo Horizonte, MG, Brazil

ARTICLE INFO

Article history:

Received 8 March 2016

Received in revised form

18 July 2016

Accepted 18 August 2016

Available online 20 August 2016

Keywords:

Endocarditis

Bloodstream infection

Foreign body

Pacing

Lead extraction

ABSTRACT

The implant indication of cardiac electronic devices continues to expand; therefore, we have observed increasing complications related to their removal. We describe the case of a patient who presented with prolonged bloodstream infection after having undergone removal of a pacemaker. After extensive workup for fever of unknown origin and antibiotic therapy without any improvement, it was possible to demonstrate a foreign body in the right subclavian vein and superior vena cava corresponding to the distal part of the right ventricular lead. Endovascular removal of the foreign body and prolonged antibiotic administration was followed by complete resolution of the clinical picture. We ascribed the difficulty in diagnosing the source of the infection especially to the lack of local manifestations.

Copyright © 2016, Indian Heart Rhythm Society. Production and hosting by Elsevier B.V. This is an open access article under the CC BY-NC-ND license (<http://creativecommons.org/licenses/by-nc-nd/4.0/>).

1. Introduction

The intravenous insertion and removal of intracardiac devices are subject to complications [1]. We report here a case of prolonged fever post infected pacemaker (PM) and lead extraction, with late diagnosis of a retained lead in the right subclavian vein and superior vena cava, whose removal resulted in clinical resolution.

1.1. Case report

A 49-year-old man underwent removal of a PM due to infective endocarditis. In this procedure, the electrodes were left in place and the PM was implanted on the contralateral site. After 2 weeks, the patient was readmitted with sepsis related to the cardiac device, which was completely removed followed by the implantation of an epicardial PM. Lead extraction was performed percutaneously using locking stylets and polypropylene telescopic dilator sheaths.

As the patient continued to have fever, he was referred to the

University Hospital, Federal University of Minas Gerais, Belo Horizonte, Brazil, which is a tertiary care center. Extensive workup for fever of unknown origin did not clarify the cause of the fever, which remained in spite of the use of different antibiotics including agents to cover *Enterococcus* sp that was isolated from the blood cultures. One month after admission, the fever persisted unchanged. A vascular duplex scan was performed and showed the presence of an endovascular foreign body in the right subclavian vein and superior vena cava associated with thrombus. The diagnosis was confirmed by computed tomography (CT) (Fig. 1). The patient underwent endovascular removal of the foreign body, which was identified as the distal part of the right ventricular lead, measuring about 10cm long. After the procedure, he presented clinical and laboratory improvement consistent with complete resolution of the infection, and was discharged from the hospital after completing 28 days of antibiotic therapy guided by blood culture.

2. Discussion

From the last decades, the indications for implant of cardiac electronic devices continue to expand. As a result, we have observed increasing complications related to the removal of these devices [1]. In spite of the evolution of the extraction techniques from simple traction to extraction with dilators, powered sheaths

* Corresponding author. Department of Internal Medicine, School of Medicine, Universidade Federal de Minas Gerais, Av. Professor Alfredo Balena 190, 30130 -100, Belo Horizonte, MG, Brazil.

E-mail address: mcarmo@waymail.com.br (M.C.P. Nunes).

Peer review under responsibility of Indian Heart Rhythm Society.

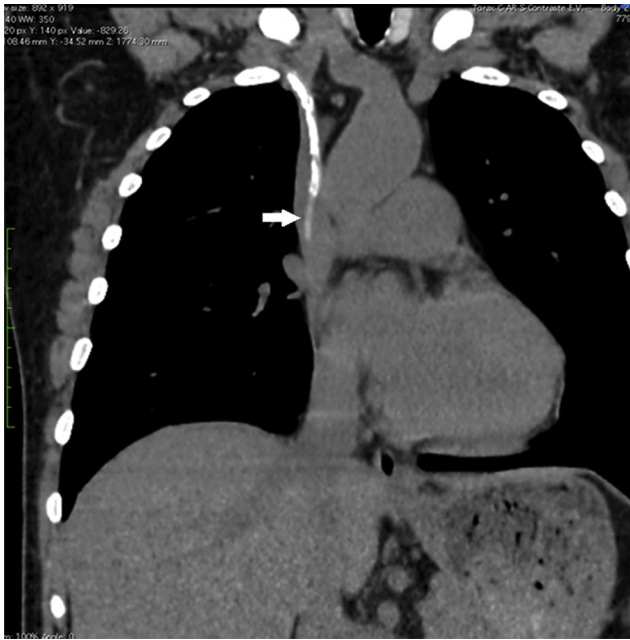


Fig. 1. Computed tomography showing a foreign body (arrow) in the right subclavian vein and superior vena cava that was retained after percutaneous lead extraction.

and laser assistance, percutaneous removal of the device leads is still associated with morbidity and mortality, though in a small proportion of cases [1,2].

The more frequent indications for cardiac device extraction are lead dysfunction, pocket infection and systemic infection, and the rate of successful lead remove is over 94% [1,3,4]. Procedural-related major complications include death, cardiac and/or vascular avulsion, pulmonary embolism, stroke, and pacing system-related infection of a previously non-infected site. Pericardial effusion or hemothorax, hematoma at the surgical site, arm swelling or vein thrombosis, migration of lead fragment without any sequelae, and blood loss during surgery requiring blood transfusion are considered minor complications of lead extraction. Death within 30 days from the extraction is also included among the outcomes of lead extraction procedures [2]. Our patient developed blood stream infection due to the persistence of the retained the distal part after percutaneous lead extraction coating

cable of the PM associated with thrombus formation in the right subclavian vein and superior vena cava, which may be considered a major complication of lead extraction.

As the lead extraction was performed in a low volume center, we hypothesized whether this fact could have contributed to the development of the complication. This possibility is reinforced by the results of a recent meta-analysis, in which the outcome of lead extraction was evaluated according to the center experience based on the volume of procedures carried out (low, medium, and high volume centers), demonstrating that procedure volume is a major determinant of outcomes of transvenous lead extraction [2].

The diagnosis of the cause of the infection presented by our patient was challenging especially because of the lack of local manifestations. The absence of these manifestations also contributed to overlooking the foreign body on imaging methods initially. Indeed, we noticed the foreign body on CT scan only after the result of the vascular duplex scan.

We conclude that a retained foreign body should be considered in the differential diagnosis of persistent fever after removing a PM system. Endovascular treatment is an effective therapeutic option. Moreover, our case illustrates two major learning points. Firstly, it reinforces the need of examining the extracted material after lead extraction; so that any missing fragment/coating can be identified and looked for. Secondly, it shows the importance of having a detailed scheme of analysis of the imaging methods. Vascular Doppler and chest CT are part of the basic work up for such cases; thus, a proper scheme of analysis of their results would have allowed diagnosing the presence of a retained foreign body at an earlier stage in our patient.

References

- [1] Gomes S, Cranney G, Bennett M, Li A, Giles R. Twenty-year experience of transvenous lead extraction at a single centre. *Europa : european pacing, arrhythmias, and cardiac electrophysiology. J Work Groups Cardiac Pacing, Arrhythm Cardiac Cell Electrophysiol Eur Soc Cardiol* 2014;16(9):1350–5.
- [2] Di Monaco A, Pelargonio G, Narducci ML, Manzoli L, Boccia S, Flacco ME, et al. Safety of transvenous lead extraction according to centre volume: a systematic review and meta-analysis. *Europace* 2014;16(10):1496–507.
- [3] Polewczyk A, Jachec W, Janion M, Podlaski R, Kutarski A. Lead-dependent infective endocarditis: the role of factors predisposing to its development in an analysis of 414 clinical cases. *Pacing and clinical electrophysiology. PACE* 2015;38(7):846–56.
- [4] Brunner MP, Cronin EM, Duarte VE, Yu C, Tarakji KG, Martin DO, et al. Clinical predictors of adverse patient outcomes in an experience of more than 5000 chronic endovascular pacemaker and defibrillator lead extractions. *Heart Rhythm* 2014;11(5):799–805.