

# Differential Expression of Growth Factor Receptors and Membrane-Bound Tumor Markers for Imaging in Male and Female Breast Cancer

Jeroen F. Vermeulen<sup>1</sup>, Robert Kornegoor<sup>1</sup>, Elsken van der Wall<sup>2</sup>, Petra van der Groep<sup>1,2</sup>, Paul J. van Diest<sup>1\*</sup>

**1** Department of Pathology, University Medical Center Utrecht, Utrecht, The Netherlands, **2** Division of Internal Medicine and Dermatology, University Medical Center Utrecht, Utrecht, The Netherlands

## Abstract

**Introduction:** Male breast cancer accounts for 0.5–1% of all breast cancers and is generally diagnosed at higher stage than female breast cancers and therefore might benefit from earlier detection and targeted therapy. Except for HER2 and EGFR, little is known about expression of growth factor receptors in male breast cancer. We therefore investigated expression profiles of growth factor receptors and membrane-bound tumor markers in male breast cancer and gynecomastia, in comparison with female breast cancer.

**Methods:** Tissue microarrays containing 133 male breast cancer and 32 gynecomastia cases were stained by immunohistochemistry for a panel of membrane-bound targets and compared with data on 266 female breast cancers.

**Results:** Growth factor receptors were variably expressed in 4.5% (MET) up to 38.5% (IGF1-R) of male breast cancers. Compared to female breast cancer, IGF1-R and carbonic anhydrase 12 (CAXII) were more frequently and CD44v6, MET and FGFR2 less frequently expressed in male breast cancer. Expression of EGFR, HER2, CAIX, and GLUT1 was not significantly different between male and female breast cancer. Further, 48.1% of male breast cancers expressed at least one and 18.0% expressed multiple growth factor receptors. Since individual membrane receptors are expressed in only half of male breast cancers, a panel of membrane markers will be required for molecular imaging strategies to reach sensitivity. A potential panel of markers for molecular imaging, consisting of EGFR, IGF1-R, FGFR2, CD44v6, CAXII, GLUT1, and CD44v6 was positive in 77% of male breast cancers, comparable to female breast cancers.

**Conclusions:** Expression patterns of growth factor receptors and hypoxia membrane proteins in male breast cancer are different from female breast cancer. For molecular imaging strategies, a putative panel consisting of markers for EGFR, IGF1-R, FGFR2, GLUT1, CAXII, CD44v6 was positive in 77% of cases and might be considered for development of molecular tracers for male breast cancer.

**Citation:** Vermeulen JF, Kornegoor R, van der Wall E, van der Groep P, van Diest PJ (2013) Differential Expression of Growth Factor Receptors and Membrane-Bound Tumor Markers for Imaging in Male and Female Breast Cancer. PLoS ONE 8(1): e53353. doi:10.1371/journal.pone.0053353

**Editor:** Gayle E. Woloschak, Northwestern University Feinberg School of Medicine, United States of America

**Received:** August 20, 2012; **Accepted:** November 30, 2012; **Published:** January 4, 2013

**Copyright:** © 2013 Vermeulen et al. This is an open-access article distributed under the terms of the Creative Commons Attribution License, which permits unrestricted use, distribution, and reproduction in any medium, provided the original author and source are credited.

**Funding:** This work was supported by an unrestricted research grant of AEGON Inc. and by the MAMmary carcinoma MOlecular imaging for diagnostics and Therapeutics (MAMMOTH) project of the Dutch Center for Translational Molecular Medicine. The funders had no role in study design, data collection and analysis, decision to publish, or preparation of the manuscript.

**Competing Interests:** The authors have read the journal's policy and have the following conflict: an unrestricted educational research grant from AEGON Inc. This does not alter the authors' adherence to all the PLOS ONE policies on sharing data and materials.

\* E-mail: p.j.vandiest@umcutrecht.nl

## Introduction

Breast cancer in males is a rare disease, accounting for 0.5–1% of all breast cancer cases [1,2]. Male breast cancer patients generally present at higher age than female breast cancer patients and at a higher stage including more frequently lymph node metastases [1,3,4]. Furthermore, molecular subtypes of male breast cancer are differently distributed than female breast cancer, the most predominant subtype in male being Luminal A followed by Luminal B. HER2-driven subtypes have not been observed [5–7]. Conflicting data exist whether triple negative/basal-like breast cancers occur in male breast cancer, but at least it is infrequent [6–8].

With regard to potential druggable targets, knowledge on the expression of individual tumor markers is limited and variable. Estrogen Receptor  $\alpha$  (ER $\alpha$ ) and progesterone receptor (PR) expression in male breast cancer is present in around 90% of patients [4], which makes them eligible for adjuvant therapy using tamoxifen and aromatase inhibitors. HER2 expression in male ranges between 0–45% of cases in different studies [5–7,9–11], but current consensus in recent studies shows that HER2 expression in male breast cancer is seen in no more than 3–7% of cases. The epidermal growth factor receptor (EGFR) is the only other growth factor receptor for which expression data is available in male breast cancer, suggesting that EGFR is expressed in 12–76% of cases [6,7,9,11,12].

Nowadays, antibody-based molecular therapies have been developed for e.g. HER2 [13,14] and EGFR [15,16] and molecular therapies for other growth factor receptors are still investigational. In addition to being therapeutic targets, growth factor receptors might be useful for molecular imaging [17–19]. Molecular imaging using optical near-infrared fluorescent probes has advantages compared to mammography alone, because probes can be conjugated to antibodies, antibody fragments or peptides which increases the specificity of the signal [20]. Further, near-infrared fluorescently labeled antibodies can be used for image-guided surgery, thereby enhancing radical resection of breast cancer and lymph node metastases [21–23]. We recently described that in addition to growth factor receptors, hypoxia upregulated proteins (carbonic anhydrase IX (CAIX) and XII (CAXII), and GLUT1) and CD44 variants might be useful for molecular imaging of female breast cancer [24]. Because fluorescently labeled antibodies and antibody-fragments are not easily internalized, ER $\alpha$  and PR are not considered for optical imaging strategies. Selection of potential antibody-based agents for detection and therapy of male breast cancer is labor intensive and costly. Furthermore, the expression of membrane markers in male breast cancer is unknown.

Since male breast cancer patients have more frequently lymph node metastases, molecular imaging may be of benefit for males to assess stage of disease and monitor disease progression or response to therapy. In the present study, we therefore investigated by immunohistochemistry the expression of growth factor receptors and membrane markers in male breast cancer and compared the results with those we observed in female breast cancer and gynecomastia, in order to find a panel of potential markers for therapy and molecular imaging of male breast cancer.

## Materials and Methods

### Patients

The origin and composition of the male breast cancer study population was described before [7]. Female breast cancer cases from 2003–2007 were derived from the archive of the Department of Pathology University Medical Center Utrecht, Utrecht, The Netherlands as described before [25]. The study population comprised 133 cases of male and 266 cases of female invasive breast cancer. For all cases haematoxylin and eosin (HE) slides were reviewed by two experienced observers (PJVd, RK) to confirm the diagnosis and to characterize the tumor. Histological grade was assessed according to the modified Bloom and Richardson score [26], and mitotic activity index (MAI) was assessed as described before [27]. Clinicopathological characteristics of all male and female breast cancer cases are shown in Table 1.

In addition, 32 gynecomastia cases from 2000–2010 were retrieved from the archives of the Department of Pathology of the University Medical Center Utrecht. Original HE slides were reviewed by two observers (PJVd, RK) to confirm the diagnosis, and to subtype gynecomastia (florid, intermediate, fibrous) as described before [28]. Tissue microarrays were constructed as described by Kornegoor et al. [7,28]. Since we are using archival pathology material which does not interfere with patient care and does not involve physical involvement of the patient, no ethical approval is required according to Dutch legislation [29]. Use of anonymous or coded left over material for scientific purposes is part of the standard treatment contract with patients and therefore informed consent procedure was not required according to our institutional medical ethical review board, this has also been described by van Diest [30].

**Table 1.** Clinicopathological characteristics of male and female breast cancer.

Feature	Grouping	Male	Female	p-value
		N (%)	N (%)	
Age (years)	Mean	66	59	
	Range	32–89	28 to 88	<0.001
Histological type	Invasive ductal cancer	121 (91.0)	211 (79.3)	
	Invasive lobular cancer	3 (2.3)	25 (9.4)	
	Others	9 (6.8)	30 (11.3)	0.008
Tumor size (cm)	≤2	73 (54.9)	130 (48.9)	
	>2 and ≤5	54 (40.6)	113 (42.5)	
	>5	2 (1.5)	21 (7.9)	
	Not available	4 (3.0)	2 (0.7)	0.030
Histological grade	1	32 (24.1)	45 (16.9)	
	2	54 (40.6)	100 (37.6)	
	3	47 (35.3)	121 (45.5)	0.094
Lymph node status	Negative *	51 (38.3)	119 (44.7)	
	Positive **	60 (45.2)	132 (49.6)	
	Not available	22 (16.5)	15 (5.7)	0.797
Mitotic index #	≤12	76 (57.1)	132 (49.6)	
	≥13	57 (42.9)	134 (50.4)	0.156
ER $\alpha$ †	Negative	8 (6.0)	53 (19.9)	
	Positive	125 (94.0)	213 (80.1)	<0.001
PR †	Negative	43 (32.3)	89 (33.5)	
	Positive	90 (67.7)	177 (66.5)	0.802

#: per 2 mm<sup>2</sup>;

\*: negative = N0 or N0(i+);

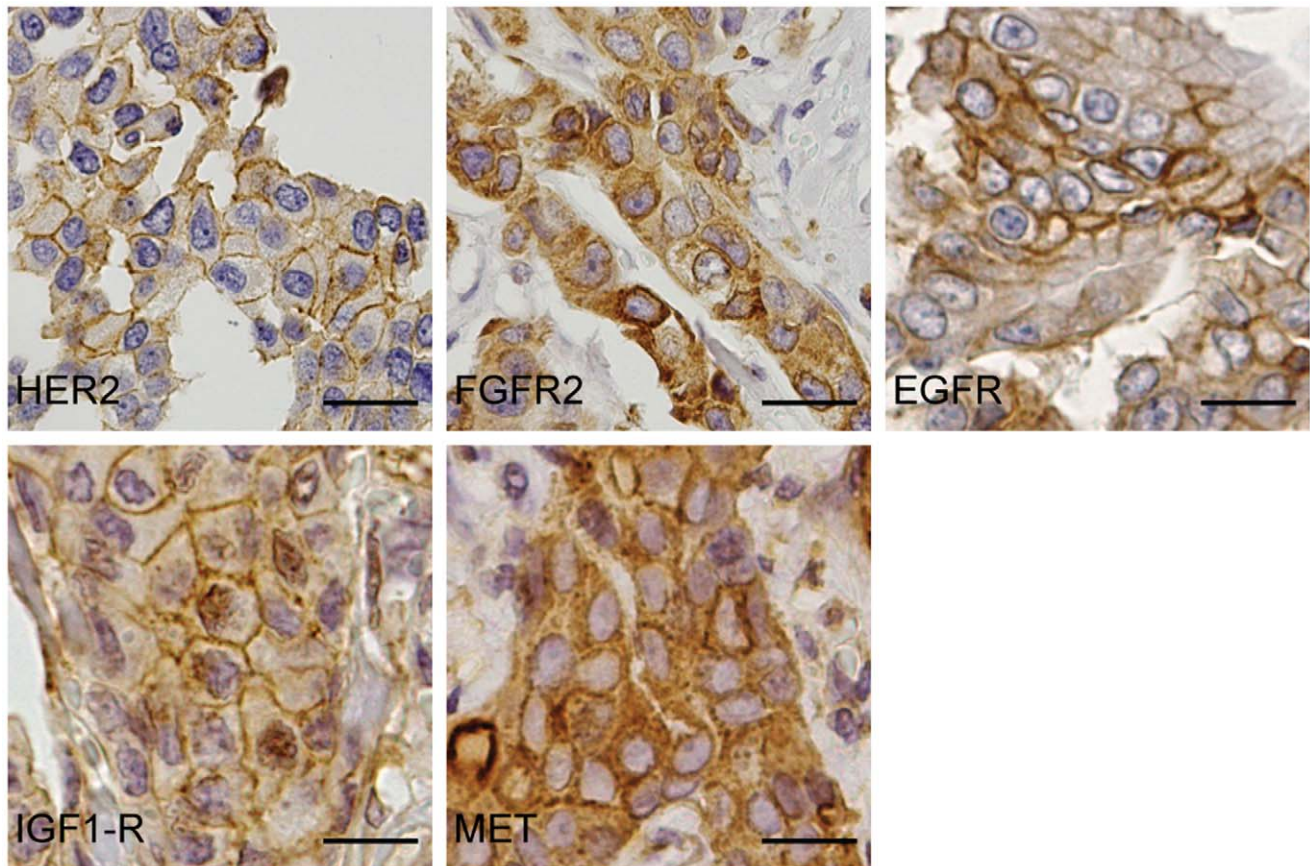
\*\*: positive = ≥N1mi (according to TNM 7<sup>th</sup> edition, 2010);

†: positive = ≥10% nuclear staining.

doi:10.1371/journal.pone.0053353.t001

### Immunohistochemistry

Immunohistochemistry was carried out on 4  $\mu$ m thick sections for a panel of growth factor receptors. After deparaffination and rehydration, endogenous peroxidase activity was blocked for 15 min in a buffer solution pH5.8 containing 0.3% hydrogen peroxide. After antigen retrieval, i.e. boiling for 20 min in 10 mM citrate pH6.0 (for progesterone receptor (PR), Hepatocyte growth factor receptor (MET), Fibroblast growth factor receptor 2 (FGFR2), CD44v6, CAXII, carbonic anhydrase 9 (CAIX), and GLUT1), or Tris/EDTA pH9.0 (estrogen receptor  $\alpha$  (ER $\alpha$ ), HER2, and Insulin-like Growth Factor-1 receptor (IGF1-R)) or Prot K (0.15 mg/ml) for 5 min at room temperature (EGFR), a cooling off period of 30 min preceded the primary antibody incubation. ER $\alpha$  (clone ID5, DAKO, Glostrup Denmark) 1:200; PR (clone PgR636, DAKO) 1:100; HER2 (SP3, Neomarkers, Duiven, The Netherlands) 1:100; IGF1-R (NB110-87052, Novus Biologicals, Cambridge, UK) 1:400; FGFR2 (M01, clone 1G3, Abnova, Heidelberg, Germany) 1:800; CD44v6 (clone VFF18, BMS125, Bender MedSystems, Austria) 1:500; GLUT1 (A3536, DAKO) 1:200; CAXII (HPA008773, Sigma Aldrich, Zwijndrecht, The Netherlands) 1:200; CAIX (ab15086, Abcam, Cambridge, UK) 1:1,000 were incubated for 1 h at room temperature. Primary antibodies against EGFR (clone 31G7, Zymed, Invitrogen) 1:30; MET (18-2257, Zymed, Invitrogen) 1:100 were incubated overnight at 4°C. All primary antibodies were diluted in PBS containing 1% BSA.



**Figure 1. Expression of growth factor receptors in male breast cancer.** Expression of HER2, FGFR2, EGFR, IGF1-R, and MET in representative cases of male breast cancer. Size bars equal 20  $\mu$ m. doi:10.1371/journal.pone.0053353.g001

The signal was amplified using Brightvision poly-HRP anti-mouse, rabbit, rat (DPVO-HRP, Immunologic, Duiven, The Netherlands) or the Novolink kit (Leica, Rijswijk, The Netherlands) (in the case of EGFR) and developed with diaminobenzidine, followed by counterstaining with haematoxylin, dehydration in alcohol and mounting.

#### Scoring of Immunohistochemistry

All stainings were compared to normal breast tissue (obtained from female patients that underwent mastectomy) and scored as positive when a clear membrane staining (2+ or 3+) was observed, except for HER2 where only a score of 3+ was considered positive. All scoring was done by JFV, RK and PJvD who were blinded to patient characteristics and results of other stainings. Expression data for the female breast cancers and for the hypoxia proteins in male breast cancer were derived from our previous studies [24,31].

#### Statistics

Statistical analysis was performed using IBM SPSS Statistics version 18.0 (SPSS Inc., Chicago, IL, USA). Associations between categorical variables were examined using the Pearson's Chi-square test and associations between continuous variables using Student's T-test. Logistic regression was used to correct for differences in ER $\alpha$  expression, tumor size ( $\leq 2$  cm vs.  $> 2$  cm), age ( $< 60$  years vs.  $\geq 60$  years), and histological type (ductal vs. lobular/other histological type) between male and female breast

cancers. P-values  $< 0.05$  were considered to be statistically significant.

#### Results

In our study population of 133 cases of male breast cancer, we found 4 cases (3.0%) expressing HER2, 15 cases (11.4%) EGFR, 6 cases (4.5%) MET, 16 cases (12.1%) FGFR2, and 50 cases (38.5%) IGF1-R (Table 2). Representative cases of male breast cancer are shown in Figure 1. CD44v6, CAIX, CAXII, and GLUT1 were expressed in 44 cases (33.3%), 9 cases (6.8%), 36 cases (27.1%), and 41 cases (31.3%) of male breast cancers, respectively.

#### Membrane Protein Expression in Male Breast Cancer Compared to Female Breast Cancer

Compared to female breast cancer, IGF1-R was more frequently expressed in male breast cancer ( $p < 0.001$ ), while MET and FGFR2 were less frequently expressed (both  $p < 0.001$ ; Table 2) in male breast cancer. Expression of EGFR and HER2 was not significantly different between male and female breast cancer. Moreover, expression of any growth factor receptor was present in 64 cases (48.1%) of male breast cancer and in 147 cases (55.3%) of female breast cancer ( $p = 0.178$ ). Further, expression rate of CD44v6 was significantly lower ( $p < 0.001$ ) and of CAXII significantly higher ( $p = 0.001$ ) in male compared to female breast cancer. However, expression rates of the hypoxia markers CAIX and GLUT1 were not significantly different between male and



**Table 2.** Expression of membrane markers in male and female invasive breast cancer.

Feature	Male	Female	Logistic regression*		
	N (%)	N (%)	p-value	OR	95% CI
IGF1-R					
Negative	80 (61.5)	219 (84.6)			
Positive	50 (38.5)	40 (15.4)	<0.001	3.317	1.948–5.647
HER2					
Negative	129 (97.0)	246 (92.5)			
Positive	4 (3.0)	20 (7.5)	0.316	0.555	0.175–1.754
EGFR					
Negative	117 (88.6)	226 (85.6)			
Positive	15 (11.4)	38 (14.4)	0.329	1.494	0.667–3.347
MET					
Negative	126 (95.5)	206 (78.0)			
Positive	6 (4.5)	58 (22.0)	<0.001	0.194	0.079–0.473
FGFR2					
Negative	116 (87.9)	195 (76.5)			
Positive	16 (12.1)	60 (23.5)	0.001	0.331	0.174–0.628
CD44v6					
Negative	88 (66.7)	93 (35.2)			
Positive	44 (33.3)	171 (64.8)	<0.001	0.269	0.168–0.432
GLUT1					
Negative	90 (68.7)	175 (72.6)			
Positive	41 (31.3)	66 (27.4)	0.164	1.439	0.862–2.401
CAIX					
Negative	123 (93.2)	215 (88.5)			
Positive	9 (6.8)	28 (11.5)	0.865	0.924	0.372–2.297
CAXII					
Negative	97 (72.9)	238 (90.8)			
Positive	36 (27.1)	24 (9.2)	0.001	2.753	1.501–5.049

\*Correction for age, histology, ER $\alpha$  expression, and tumor size, Confidence Interval (CI), Odds Ratio (OR). OR >1 indicates higher expression in male. doi:10.1371/journal.pone.0053353.t002

female breast cancer ( $p=0.865$  and  $p=0.164$ , respectively) (Table 2).

We found that co-expression of growth factor receptors was equally frequent in male (18.0%) and female (20.7%) breast cancer ( $p=0.178$ ). As shown in Table 3, co-expression of IGF1-R with other growth factor receptors was comparable between male (15.7%) and female breast cancer (13.6%) ( $p=0.187$ ). Furthermore, co-expression of EGFR with HER2 was similar in male (2.3%) and female (3.0%) breast cancer ( $p=0.665$ ), while co-expression rates for MET with EGFR and MET with FGFR2 were higher in female than in male breast cancer (4.5% vs. 0.0%,  $p=0.013$ ) and (5.6% vs. 0.8%,  $p=0.019$ ), respectively. Simultaneous expression of more than 3 growth factor receptors was found in 2.3% of male and 4.1% of female breast cancer cases ( $p=0.336$ ).

### Clinicopathological Correlations of Membrane Marker Expression

Like in female breast cancer, expression of HER2 in male breast cancer correlated with high histological grade ( $p=0.023$ ) and tumor-size ( $p<0.001$ ). In contrast to female breast cancer, expression of EGFR, GLUT1, and CAIX in male breast cancer did not correlate with any clinicopathological feature. Expression of IGF1-R, MET, FGFR2, and CD44v6 was not correlated to clinicopathological features in both male and female breast cancer. Nevertheless, expression of HER2, MET, EGFR, GLUT1, and CAIX was, as expected, significantly associated with loss of ER $\alpha$  and PR expression in female breast cancer ( $p<0.001$ ,  $p=0.027$ ,  $p<0.001$ ,  $p<0.001$ ,  $p<0.001$  respectively), whereas FGFR2 and CAXII were associated with ER $\alpha$  and PR expression ( $p=0.003$  and  $p=0.016$ ; Table 4). In male breast cancer, only expression of EGFR was significantly associated with loss of ER $\alpha$  and PR expression, probably due to a limited number of ER $\alpha$  and PR negative male breast cancer cases.

### Towards a Panel of Potential Membrane Markers for Molecular Imaging

From the previous results it became clear that all growth factor receptors are too infrequently expressed in male breast cancer to serve as individual targets for molecular imaging strategies, meaning that a panel of growth factor receptors supplemented

**Table 3.** Co-expression of growth factor receptors in male and female breast cancer.

Growth factor receptor	Co-expression with:			
	FGFR2 N (%)	MET N (%)	EGFR N (%)	HER2 N (%)
IGF1-R				
male	8 (6.0)	3 (2.3)	8 (6.0)	2 (1.5)
female	13 (4.9)	13 (4.9)	6 (2.3)	5 (1.9)
HER2				
male	1 (0.8)	1 (0.8)	3 (2.3)	
female	5 (1.8)	8 (3.0)	8 (3.0)	
EGFR				
male	3 (2.3)	0 (0.0)		
female	3 (1.1)	12 (4.5)		
MET				
male	1 (0.8)			
female	15 (5.6)			

doi:10.1371/journal.pone.0053353.t003

**Table 4.** Membrane marker expression in relation to hormone receptor expression.

Feature	Male			Female		
	ER $\alpha$ /PR positive	ER $\alpha$ /PR negative	p-value	ER $\alpha$ /PR positive	ER $\alpha$ /PR negative	p-value
	N (%)	N (%)		N (%)	N (%)	
<b>IGF1-R</b>						
Negative	76 (60.8)	4 (80.0)	0.387	177 (83.5)	42 (89.4)	0.314
Positive	49 (39.2)	1 (20.0)		35 (16.5)	5 (10.6)	
<b>HER2</b>						
Negative	124 (96.9)	5 (100.0)	0.688	207 (95.0)	39 (81.3)	<b>&lt;0.001</b>
Positive	4 (3.1)	0 (0.0)		11 (5.0)	9 (18.7)	
<b>EGFR</b>						
Negative	114 (89.8)	3 (60.0)	<b>0.040</b>	208 (96.3)	18 (37.5)	<b>&lt;0.001</b>
Positive	13 (10.2)	2 (40.0)		8 (3.7)	30 (62.5)	
<b>MET</b>						
Negative	121 (95.3)	5 (100.0)	0.619	175 (80.6)	31 (66.0)	<b>0.027</b>
Positive	6 (4.7)	0 (0.0)		42 (19.4)	16 (34.0)	
<b>FGFR2</b>						
Negative	111 (87.4)	5 (100.0)	0.397	152 (72.7)	43 (93.5)	<b>0.003</b>
Positive	16 (12.6)	0 (0.0)		57 (27.3)	3 (6.5)	
<b>GLUT1</b>						
Negative	85 (67.5)	5 (100.0)		155 (79.1)	19 (43.2)	
Positive	41 (32.5)	0 (0.0)	0.124	41 (20.9)	25 (56.8)	<b>&lt;0.001</b>
<b>CAIX</b>						
Negative	118 (92.9)	5 (100.0)		189 (95.5)	25 (56.8)	
Positive	9 (7.1)	0 (0.0)	0.537	9 (4.5)	19 (43.2)	<b>&lt;0.001</b>
<b>CAXII</b>						
Negative	92 (71.9)	5 (100.0)		190 (88.8)	47 (100.0)	
Positive	36 (28.1)	0 (0.0)	0.165	24 (11.2)	0 (0.0)	<b>0.016</b>
<b>CD44v6</b>						
Negative	83 (65.4)	5 (100.0)		77 (35.8)	16 (33.3)	
Positive	44 (34.6)	0 (0.0)	0.107	138 (64.2)	32 (66.7)	0.745

doi:10.1371/journal.pone.0053353.t004

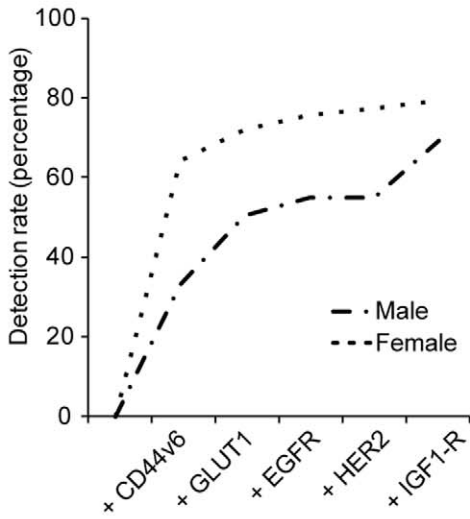
with membrane-bound tumor markers is required to obtain a sufficient detection rate like in female breast cancer [24]. Our previously proposed panel consisting of CD44v6, EGFR, HER2, IGF1-R, and GLUT1 for imaging of female breast cancer was significantly less sensitive for imaging of male breast cancer (female breast cancer 79.3% vs. male breast cancer 69.1%,  $p = 0.025$ ; Figure 2A). Inclusion of FGFR2 increased the difference in detection rate between male and female breast cancer (detection rate of female breast cancer 85.0% vs. male breast cancer 72.9%,  $p = 0.004$ ). However, inclusion of CAXII resulted in the optimal detection rate possible for male breast cancer (76.7%, Figure 2B). Because the panel of membrane markers mainly consists of growth factor receptors and hypoxia markers, we investigated whether high grade male breast cancers are more frequently detected than low grade cancers. The sensitivity of a combination of growth factor receptors, supplemented with hypoxia markers, and CD44v6 was independent of histological grade, tumor size, lymph node status, or age (Figure 2C).

#### Specificity of a Panel of Potential Membrane Markers in Male Breast Cancer

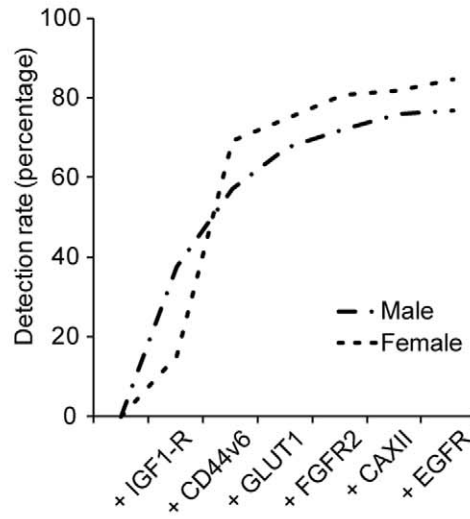
Since male breast cancer is often diagnosed together with gynecomastia, although gynecomastia is not an obligate precursor of male breast cancer [28], we examined whether the expression of the selected membrane markers was specific for male breast cancer. We found that expression patterns in gynecomastia were largely comparable with normal female breast tissue; i.e. no expression of HER2, EGFR, MET, GLUT1 and CAIX detectable. However, we observed FGFR2 expression in 3 cases (9.4%), IGF1-R expression in 1 case (3.1%), and a clear membranous staining of CAXII in 2 cases (6.3%). Gynecomastia was positive for CD44v6 (predominant staining of the myoepithelium) in all cases like normal female breast epithelium, which is probably not influencing the sensitivity of detection as we previously stated [24]. No difference in expression between the subtypes of gynecomastia was observed.

In summary, the expression of growth factor receptors in male and female breast cancer differs. However for molecular imaging strategies, the most optimal panel of potential membrane proteins for imaging of male breast cancer was similar to female breast

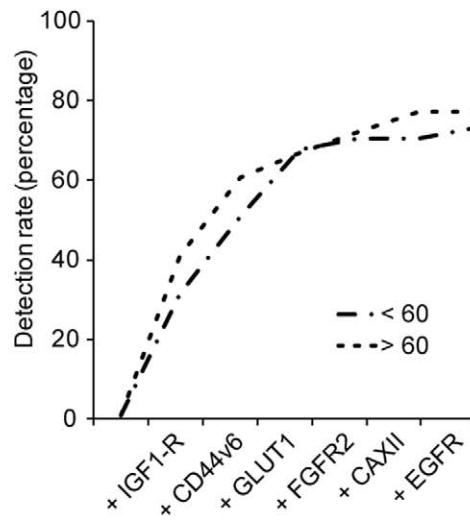
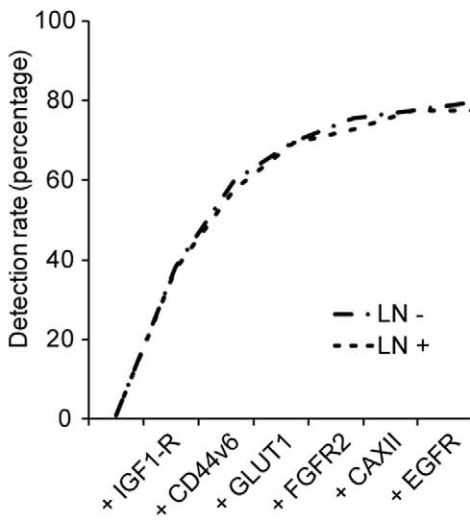
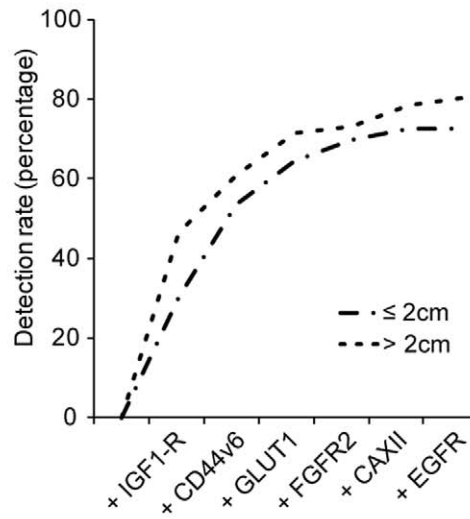
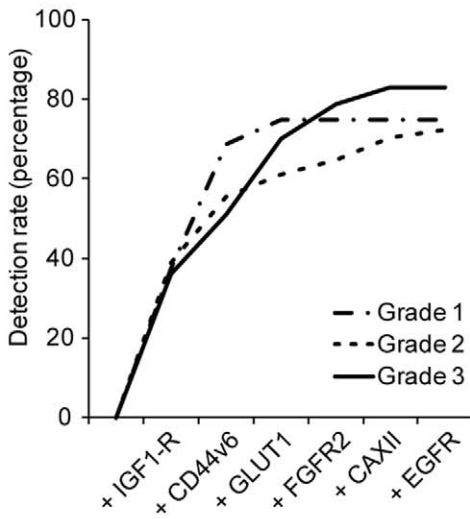
**A**



**B**



**C**



**Figure 2. Potential detection rate of a panel of membrane markers for molecular imaging.** Detection rate was calculated by the fraction of positive cases over the total population, taking into account that cancers can express multiple markers. A. Detection rate of the previously described panel in male and female breast cancer. B. The optimal combination of markers to detect male breast cancer. C. The detection rate of the panel in relation to clinicopathological features of male breast cancer. doi:10.1371/journal.pone.0053353.g002

cancer. Therefore a panel composed of IGF-1R, CD44v6, GLUT1, CAXII, FGFR2, and EGFR might be suitable for molecular imaging of male breast cancer.

## Discussion

The aim of this study was to identify the expression patterns of growth factor receptors in male breast cancer, and to determine whether growth factor receptors are suitable candidates for imaging strategies in male breast cancer patients. In addition, these markers could be potential candidates for targeted therapy in the near future next to hormonal therapy using tamoxifen and aromatase inhibitors. In order to determine the expression patterns we stained tissue microarrays containing 133 clinical specimens of male breast cancer by immunohistochemistry and compared it with 266 clinical specimens of female breast cancers and 32 cases of gynecomastia.

We found that expression of IGF1-R was present in 38.5%, FGFR2 in 12.1%, EGFR in 11.4%, HER2 in 3.0%, and MET in 4.5% of male breast cancers. Compared to female breast cancer, IGF1-R expression was higher and MET and FGFR2 expression lower in male breast cancer. In total, half of male breast cancers expressed one of the selected receptors. Furthermore, we found that 18.0% of male breast cancer patients expressed more than one growth factor receptor. The most predominant combination was IGF1-R with EGFR or FGFR2 expression.

The expression rates of HER2 and EGFR in male breast cancer were comparable with recent findings [5–7,10], but other data for IGF1-R and MET in the male breast cancer literature are unavailable. Since MET expression is more prevalent in non-luminal female breast cancer, it seemed likely that MET expression in male breast cancer would be low (4.5%), because only 6% of male breast cancers was non-luminal type. IGF1-R expression was found in almost 40% of male breast cancers, suggesting that IGF1-R might be the driving growth factor receptor in male breast cancer. As described by the study of Peyrat et al [32] and Stoll [33], IGF1-R expression is related to ER $\alpha$  positivity, since almost all male breast cancers are ER $\alpha$  positive, high IGF1-R expression was expected. Further, FGFR2 expression in female breast cancer was highly correlated with ER $\alpha$ , PR expression and low grade [34], and with cancers in patients with a BRCA2 mutation [35]. Given that BRCA2 mutations are more

frequent in male breast cancer [36,37], FGFR2 levels were expected to be higher in male than in female breast cancer. However, in our study population FGFR2 expression in male breast cancer was two-fold lower than in female breast cancer.

When only growth factor receptors are used for molecular imaging, the sensitivity would be low (48.1%), however the specificity (as compared to gynecomastia) would be high. Due to low sensitivity, expression patterns of hypoxia markers and CD44v6 were studied in male breast cancer. We found that the ER $\alpha$  and hypoxia associated marker CAXII was more frequently expressed in male compared to female breast cancer. This could not be explained by ER $\alpha$  expression or a different regulation of the hypoxia response, because expression of CAIX and GLUT1 was not significantly different in male and female breast cancer [38,39]. Therefore, gender specific differences e.g. hormonal balances probably play a role. Finally, we found that the expression of CD44v6 was significantly lower in male breast cancer than in female breast cancer, although no differential expression was seen between normal female breast tissue and gynecomastia, as judged by extensive staining of the myoepithelial cells. The underlying mechanism and clinical consequences of low CD44v6 in male breast cancer remains to be elucidated.

In conclusion, we found that expression of individual growth factor receptors (IGF1-R, FGFR2, and MET) and CD44v6, CAXII in male breast cancer is different compared to female breast cancer. However, when used as a panel of markers for molecular imaging strategies, the potential detection rate is similar for male and female breast cancer. This implies that membrane targets for molecular imaging of female breast cancer can also be used for detecting male breast cancer. The feasibility of molecular imaging (and therapy) of male breast cancer requires further study, but the present study thereby serves as a starting point for development of a set of antibody-based therapeutics and molecular tracers for male breast cancer.

## Author Contributions

Conceived and designed the experiments: JFV RK PJVD. Performed the experiments: JFV RK. Analyzed the data: JFV RK EVDW PVDG PJVD. Contributed reagents/materials/analysis tools: EVDW PVDG. Wrote the paper: JFV PJVD.

## References

- Miao H, Verkooijen HM, Chia KS, Bouchardy C, Pukkala E, et al. (2011) Incidence and outcome of male breast cancer: an international population-based study. *J Clin Oncol* 29: 4381–4386.
- Anderson WF, Jatoi I, Tse J, Rosenberg PS (2010) Male breast cancer: a population-based comparison with female breast cancer. *J Clin Oncol* 28: 232–239.
- Fentiman IS, Fourquet A, Hortobagyi GN (2006) Male breast cancer. *Lancet* 367: 595–604.
- Giordano SH, Cohen DS, Buzdar AU, Perkins G, Hortobagyi GN (2004) Breast carcinoma in men: a population-based study. *Cancer* 101: 51–57.
- Shaaban AM, Ball GR, Brannan RA, Cserni G, Di Benedetto A, et al. (2012) A comparative biomarker study of 514 matched cases of male and female breast cancer reveals gender-specific biological differences. *Breast Cancer Res Treat* 133: 949–958.
- Ge Y, Sneige N, Eltorky MA, Wang Z, Lin E, et al. (2009) Immunohistochemical characterization of subtypes of male breast carcinoma. *Breast Cancer Res* 11: R28.
- Kornegeer R, Verschuur-Maes AH, Buerger H, Hogenes MC, de Bruin PC, et al. (2012) Molecular subtyping of male breast cancer by immunohistochemistry. *Mod Pathol* 25: 398–404.
- Ciocca V, Bombonati A, Gatalica Z, Di Pasquale M, Milos A, et al. (2006) Cytokeratin profiles of male breast cancers. *Histopathology* 49: 365–370.
- Moore J, Friedman MI, Gansler T, Gramlich TL, Derose PB, et al. (1998) Prognostic indicators in male breast carcinoma. *Breast J* 4: 261–269.
- Foerster R, Foerster FG, Wulff V, Schubotz B, Baaske D, et al. (2011) Matched-pair analysis of patients with female and male breast cancer: a comparative analysis. *BMC Cancer* 11: 335.
- Willsher PC, Leach IH, Ellis IO, Bell JA, Elston CW, et al. (1997) Male breast cancer: pathological and immunohistochemical features. *Anticancer Res* 17: 2335–2338.
- Fox SB, Rogers S, Day CA, Underwood JC (1992) Oestrogen receptor and epidermal growth factor receptor expression in male breast carcinoma. *J Pathol* 166: 13–18.

13. Pivrot X, Bedairia N, Thiery-Vuillemin A, Espie M, Marty M (2011) Combining molecular targeted therapies: clinical experience. *Anticancer Drugs* 22: 701–710.
14. Valachis A, Mauri D, Polyzos NP, Chlouverakis G, Mavroudis D, et al. (2011) Trastuzumab combined to neoadjuvant chemotherapy in patients with HER2-positive breast cancer: a systematic review and meta-analysis. *Breast* 20: 485–490.
15. Garrett CR, Eng C (2011) Cetuximab in the treatment of patients with colorectal cancer. *Expert Opin Biol Ther* 11: 937–949.
16. Brockstein BE (2011) Management of recurrent head and neck cancer: recent progress and future directions. *Drugs* 71: 1551–1559.
17. Sampath L, Kwon S, Ke S, Wang W, Schiff R, et al. (2007) Dual-labeled trastuzumab-based imaging agent for the detection of human epidermal growth factor receptor 2 overexpression in breast cancer. *J Nucl Med* 48: 1501–1510.
18. Lee SB, Hassan M, Fisher R, Chertov O, Chernomordik V, et al. (2008) Affibody molecules for in vivo characterization of HER2-positive tumors by near-infrared imaging. *Clin Cancer Res* 14: 3840–3849.
19. Gee MS, Upadhyay R, Bergquist H, Alencar H, Reynolds F, et al. (2008) Human breast cancer tumor models: molecular imaging of drug susceptibility and dosing during HER2/neu-targeted therapy. *Radiology* 248: 925–935.
20. Pleijhuis RG, Graafland M, de Vries J, Bart J, de Jong JS, et al. (2009) Obtaining adequate surgical margins in breast-conserving therapy for patients with early-stage breast cancer: current modalities and future directions. *Ann Surg Oncol* 16: 2717–2730.
21. Pleijhuis RG, Langhout GC, Helfrich W, Themelis G, Sarantopoulos A, et al. (2011) Near-infrared fluorescence (NIRF) imaging in breast-conserving surgery: assessing intraoperative techniques in tissue-simulating breast phantoms. *Eur J Surg Oncol* 37: 32–39.
22. Hirche C, Murawa D, Mohr Z, Kneif S, Hunerbein M (2010) ICG fluorescence-guided sentinel node biopsy for axillary nodal staging in breast cancer. *Breast Cancer Res Treat* 121: 373–378.
23. Crane LM, Themelis G, Arts HJ, Buddingh KT, Brouwers AH, et al. (2011) Intraoperative near-infrared fluorescence imaging for sentinel lymph node detection in vulvar cancer: first clinical results. *Gynecol Oncol* 120: 291–295.
24. Vermeulen JF, van Brussel AS, van der Groep P, Morsink FH, Bult P, et al. (2012) Immunophenotyping invasive breast cancer: paving the road for molecular imaging. *BMC Cancer* 12: 240.
25. Vermeulen JF, van de Ven RA, Ercan C, van der Groep P, van der Wall E, et al. (2012) Nuclear Kaiso expression is associated with high grade and triple-negative invasive breast cancer. *PLoS One* 7: e37864.
26. Elston CW, Ellis IO (1991) Pathological prognostic factors in breast cancer. I. The value of histological grade in breast cancer: experience from a large study with long-term follow-up. *Histopathology* 19: 403–410.
27. van der Groep P, Bouter A, van der Zanden R, Siccama I, Menko FH, et al. (2006) Distinction between hereditary and sporadic breast cancer on the basis of clinicopathological data. *J Clin Pathol* 59: 611–617.
28. Kornegoor R, Verschuur-Maes AH, Buerger H, van Diest PJ (2012) The 3-layered ductal epithelium in gynecomastia. *Am J Surg Pathol* 36: 762–768.
29. CCMO website: Central Committee on Research involving Human Subjects (Centrale Commissie Mensgebonden Onderzoek) (text in Dutch). Available: <http://www.ccmo-online.nl/main.asp?pid=10&sid=30&ssid=51>. Accessed: 2012 Oct 1.
30. van Diest PJ (2002) No consent should be needed for using leftover body material for scientific purposes. *For. BMJ* 325: 648–651.
31. Kornegoor R, Verschuur-Maes AH, Buerger H, Hogenes MC, de Bruin PC, et al. (2012) Fibrotic focus and hypoxia in male breast cancer. *Mod Pathol* 25: 1397–1404.
32. Peyrat JP, Bonnetterre J, Beuscart R, Djiane J, Demaille A (1988) Insulin-like growth factor 1 receptors in human breast cancer and their relation to estradiol and progesterone receptors. *Cancer Res* 48: 6429–6433.
33. Stoll BA (2002) Oestrogen/insulin-like growth factor-I receptor interaction in early breast cancer: clinical implications. *Ann Oncol* 13: 191–196.
34. Garcia-Closas M, Hall P, Nevanlinna H, Pooley K, Morrison J, et al. (2008) Heterogeneity of breast cancer associations with five susceptibility loci by clinical and pathological characteristics. *PLoS Genet* 4: e1000054.
35. Bane AL, Pinnaduwa D, Colby S, Reedijk M, Egan SE, et al. (2009) Expression profiling of familial breast cancers demonstrates higher expression of FGFR2 in BRCA2-associated tumors. *Breast Cancer Res Treat* 117: 183–191.
36. Gethins M (2012) Breast cancer in men. *J Natl Cancer Inst* 104: 436–438.
37. Evans DG, Susnerwala I, Dawson J, Woodward E, Maher ER, et al. (2010) Risk of breast cancer in male BRCA2 carriers. *J Med Genet* 47: 710–711.
38. Barnett DH, Sheng S, Charn TH, Waheed A, Sly WS, et al. (2008) Estrogen receptor regulation of carbonic anhydrase XII through a distal enhancer in breast cancer. *Cancer Res* 68: 3505–3515.
39. Wykoff CC, Beasley N, Watson PH, Campo L, Chia SK, et al. (2001) Expression of the hypoxia-inducible and tumor-associated carbonic anhydrases in ductal carcinoma in situ of the breast. *Am J Pathol* 158: 1011–1019.