

**Case report**

## Cat scratch disease in Medellín, Colombia

Antonio Macías<sup>1</sup>, Carlos Aguirre<sup>2</sup>, Alberto Bustamante<sup>2</sup>, Carlos Garcés<sup>2</sup>, Valentina Echeverri<sup>3</sup> and Alejandro Díaz<sup>4,\*</sup>

<sup>1</sup>Universidad de Antioquia, Medellín, Colombia, <sup>2</sup>Pediatrics Department, School of Medicine, Universidad de Antioquia, Medellín, Colombia, <sup>3</sup>Pathology Department, Universidad de Antioquia, Medellín, Colombia and <sup>4</sup>Universidad CES, Medellín, Colombia

\*Correspondence address. Universidad CES, Carrera 25 # 10-40, Universidad CES, Medellín 0500100, Colombia. Tel: +57-4-3214492; E-mail: alejodiaz81@gmail.com

Received 9 April 2014; revised 27 April 2014; accepted 1 May 2014

Cat scratch disease (CSD) is the most common zoonosis transmitted by household animals. There is limited data on the epidemiology and clinical presentation of this disease in Colombia. The typical presentation includes subacute or chronic lymph node infection following inoculation of *Bartonella henselae* bacilli through a cat scratch. Cats have a *B. henselae* seroprevalence as high as 90%. Here, we report the case of a preschool boy from a rural area of Antioquia, Colombia, who presented with chronic lymphadenopathy in the right axilla. Other important infectious etiologies were ruled out, and confirmation was made with the Warthin Starry stain of a lymph node biopsy. We also discuss the most important aspects of the diagnosis, treatment and prevention of the disease.

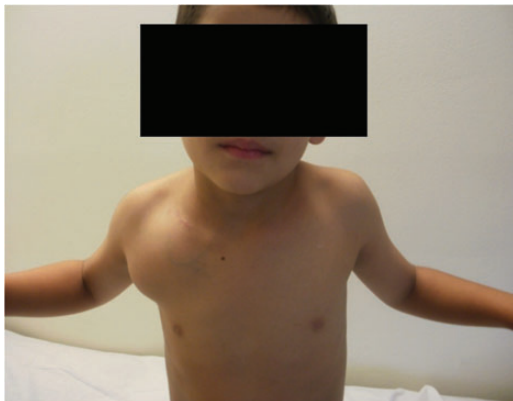### INTRODUCTION

Cat scratch disease (CSD) is a frequent worldwide zoonosis, with ~25 000 cases reported annually in the USA [1]. There is very little information of the disease in Colombia, due to the lack of readily available diagnostic tests and the scarce medical research related to the disease. We report a typical case of CSD to increase awareness of this clinical entity, especially in regions of the world where other endemic infectious diseases that present with enlarged lymphadenopathies are considered first in the initial workup [2, 3].

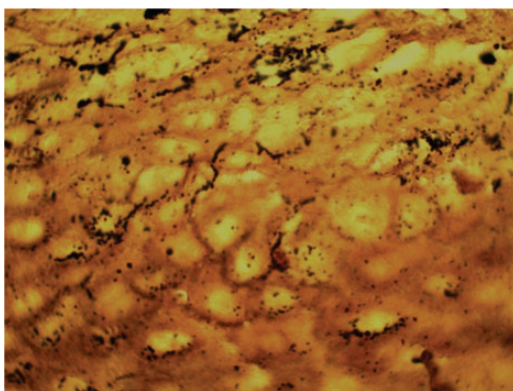
### CASE REPORT

A 6-year-old boy from a rural area came in to the hospital with a chief complaint of a right axillary mass with progressive growth for 1 month. He denied inflammatory signs or pain, but had limitation in abduction of the right upper limb. Initially he was diagnosed with pyogenic adenitis and treated with cephalexin, without much improvement. He also complained of other enlarged lymph nodes in the neck and inguinal regions with spontaneous resolution and intermittent articular pain of the wrists, ankles and knees. His past medical history was unremarkable and his immunizations were up to date. He had frequent contact with cattle and raw milk, but not

with cats. He denied any previous sick contacts. On his first medical evaluation, a neck ultrasound showed multiple enlarged lymph nodes; therefore, a diagnostic lymph node biopsy was done. Chronic granulomatous inflammation was reported; however, special staining of the specimen was not performed due to local administrative issues. Upon admission to our hospital he appeared well with normal vital signs. He had small palpable lymph nodes in the posterior cervical chain and in the right supraclavicular region. In the right axillae he had a well-defined, round lymph node, 4 cm in diameter, without inflammatory changes (Fig. 1). The rest of the physical examination was normal. Laboratory workup included a normal CBC, acute phase reactants, renal and liver function tests within normal limits and negative antinuclear antibodies. Chest X-ray and abdominal ultrasound were normal. However, chest CT showed multiple lymphadenopathies in the right axillae. Tuberculin skin test and gastric aspirates for acid fast bacilli staining and *Mycobacterium tuberculosis* cultures were all negative. Serologies for Cytomegalovirus, *Toxoplasma gondii*, Epstein–Barr virus, *Brucella* and HIV were also nonreactive. A new biopsy from the right supraclavicular lymphadenopathy was performed. Histopathology reported liquefaction necrosis with evidence of bacilli compatible with *Bartonella* spp on Warthin Starry staining (Fig. 2). AFB, silver methenamine and PAS staining



**Figure 1:** Lymph node conglomerate over the right axillary region.



**Figure 2:** Warthin Starry staining showing bacilli compatible with *Bartonella* spp. (Black structures).

were all negative. Other studies were not performed because these are not available locally. A diagnosis of CSD was made and the patient was discharged and treated with azithromycin for 5 days. One month later he returned with a significant decrease in lymph nodes, without new symptoms and without fistulous tracts.

## DISCUSSION

CSD is caused by *Bartonella henselae*. This bacterium also produces bacillary angiomatosis and peliosis, especially in HIV and immunosuppressed patients. Other important species within the genera are *B. bacilliformis* that produces Carrion's disease, and *B. Quintana*, the causative agent of Trench fever [1].

Cats are the natural reservoir of *B. henselae*. Seroprevalence varies between 13 and 90%. Kittens are more prone to carry the infection due to a higher probability of being bacteremic. Humans are infected through biting, licking or scratching by the cats. The cat flea (*Ctenocephalides felis*) is the vector for horizontal transmission from cat to cat, and its bite can also infect humans. Having a history of a traumatic contact with a cat is identifiable in 90% of patients with CSD. Once inoculated, *B. henselae* initiates a local inflammatory process

within regional lymph nodes producing persistent subacute or chronic enlargement with or without systemic symptoms [4–6]. The incubation period usually is 7–12 days. The average time between the primary lesion and the lymphadenopathy is 5–50 days, with a mean of 12 days [1]. CSD begins with a primary vesicle or papule in the inoculation site that last 1–3 weeks. Thereafter, patients develop low-grade fever, fatigue and malaise and a regional ipsilateral lymphadenopathy. Lymph nodes are swollen, tender and may eventually suppurate. Generalized involvement is less frequent (<20%) [1, 4]. When inoculation occurs close to the eye, a granulomatous conjunctivitis with preauricular ipsilateral lymphadenopathy occurs and it is known as Parinaud's Syndrome [7]. Clinical involvement other than the lymph nodes is less common. Musculoskeletal symptoms (myalgia, arthralgia, arthritis) occur in 10% of patients. Blood dissemination is rare but can cause prolonged fever, uveitis, neuroretinitis, aseptic meningitis, hepatitis, hepatosplenic abscesses, pneumonia and endocarditis [1, 4].

Accurate diagnosis requires three of five criteria: compatible signs and symptoms, microbiology (serology or culture), epidemiological contact (history of contact with cats or fleas), histopathology (Mainly acellular necrotic areas, epithelioid histiocytes and giant multinucleated cells or visualization of bacilli in Warthin Starry staining) or a positive polymerase chain reaction (PCR) based test [1, 8]. Our patient had a compatible clinical picture and a positive Warthin Starry staining. As mentioned before, serology, cultures and PCR are not readily available in Colombia [2, 3].

Differential diagnosis includes infectious diseases such as tuberculosis or nontuberculous mycobacterial infections, syphilis, histoplasmosis, endemic mycoses (such as paracoccidioidomycosis), sporotrichosis, infectious mononucleosis, toxoplasmosis and HIV.

Treatment of CSD is mostly symptomatic because it is usually self-limited [9]. Antibiotics accelerate recovery and are recommended in very symptomatic patients, with severe or disseminated disease. *B. henselae* is susceptible in vitro to multiple antibiotics, however there is limited information about which is the best option. The results of one randomized controlled trial support the use of oral azithromycin for 5 days [10]. In the most severe forms of the disease or in immunocompromised patients, a combination of trimethoprim sulfamethoxazole with rifampin or gentamicin, a fluoroquinolone or a third-generation cephalosporin have shown to be effective [4].

Prevention includes avoiding contact with kittens and stray cats, including biting or clawing and controlling fleas in domestic cats. In case of injuries, immediate washing with water and soap is advised. Antibiotic prophylaxis after exposure or routine screening of infected cats is not routinely recommended [1, 4].

## CONFLICT OF INTEREST

None declared.

## REFERENCES

1. American Academy of Pediatrics. Cat scratch disease (*Bartonella henselae*). In: En Pickering LA, ed. *Red Book 2012 Report of the Committee on Infectious Diseases*, 29th ed. Elk Grove Village, IL: American Academy of Pediatrics, 2012, 269–271.
2. Forero JF, Perez MC, Cerquera FM. Imaging manifestations in systemic cat scratch disease: case report. *Rev Colomb Radiol*. 2011;**22**:3125–3129.
3. Daza W, Mora D. *Caso clínico No. 2: Enfermedad por arañazo de gato*. Bogota: Unidad de gastroenterología, hepatología y nutrición, 2009. (Internet). [Cited February 2, 2014]. Available in [http://www.gastronutriped.com/files/publicaciones/publicacion\\_97.pdf](http://www.gastronutriped.com/files/publicaciones/publicacion_97.pdf)
4. Klotz SA, Ianas V, Elliott SP. Cat-scratch disease. *Am Fam Physician*. 2011;**83**:152–155.
5. Chomel BB, Abbot RC, Kasten RW, *et al*. *Bartonella henselae* prevalence in domestic cats in California: Risk factors and association between bacteremia and antibody titers. *J Clin Microbiol*. 1995;**33**:2445–2450.
6. Jackson LA, Perkins BA, Wenger JD. Cat scratch disease in the United States: An analysis of three national databases. *Am J Public Health*. 1993;**83**:1707–1711.
7. Biancardi AL, Land Curi AL. Cat. Scratch disease. *Ocul Immunol Inflam*. 2014;**22**:148–154.
8. Vermeulen MJ, Diederer BM, Verbakel H, Peeters MF. Low sensitivity of *Bartonella henselae* PCR in serum samples of patients with cat scratch disease lymphadenitis. *J Med Microbiol*. 2008;**57**:1049–1050.
9. Rolain JM, Brouqui P, Koehler JE, Maquina C, Dolan MJ, Raoult D. Recommendations for treatment of human infections caused by *Bartonella* species. *Antimicrob Agents Chemother*. 2004;**48**:1921–1933.
10. Bass JW, Freitas BD, Sisier CL, *et al*. Prospective randomized double-blind placebo-controlled evaluation of azithromycin for treatment of cat scratch disease. *Pediatr Infect Dis J*. 1998;**17**:447–452.