

Received: 2017.09.26  
Accepted: 2017.10.10  
Published: 2017.10.26

# Transient Elastography (FibroScan) Performs Better Than Non-Invasive Markers in Assessing Liver Fibrosis and Cirrhosis in Autoimmune Hepatitis Patients

Authors' Contribution:  
Study Design A  
Data Collection B  
Statistical Analysis C  
Data Interpretation D  
Manuscript Preparation E  
Literature Search F  
Funds Collection G

ABCDE 1,2 **Liwei Guo**  
CD 3 **Lei Zheng**  
CD 1,2 **Liyang Hu**  
CD 3 **Huanhuan Zhou**  
DEFG 4 **Lifei Yu**  
AFG 1,2 **Weifeng Liang**

1 State Key Laboratory for Diagnosis and Treatment of Infectious Diseases, Collaborative Innovation Center for Diagnosis and Treatment of Infectious Diseases, The First Affiliated Hospital, College of Medicine, Zhejiang University, Hangzhou, Zhejiang, P.R. China  
2 Shengzhou People's Hospital, Shengzhou Branch of The First Affiliated Hospital of Zhejiang University, Shengzhou, Zhejiang, P.R. China  
3 Institute of Cancer Research, Zhejiang Cancer Hospital, Hangzhou, Zhejiang, P.R. China  
4 Department of Infectious Diseases, Hangzhou First People's Hospital, Nanjing Medical University, Hangzhou, Zhejiang, P.R. China

**Corresponding Authors:** Weifeng Liang, e-mail: 11518295@zju.edu.cn; Lifei Yu, e-mail: yulifei1981@sina.com

**Source of support:** This study was supported by the National Science and Technology Major Project of the Ministry of Science and Technology of China (2017ZX10203202, 2017ZX10203202-003, 2014ZX10004006, 2013ZX10002005), and the Social Development Project of Hangzhou Technology Bureau (20160533B11)

**Background:** Autoimmune hepatitis (AIH) is an immune-mediated chronic liver disease that can lead to severe fibrosis and cirrhosis. Transient elastography (TE, FibroScan) can assess the fibrotic stages of chronic liver diseases by liver stiffness measurement (LSM). Studies on the diagnostic accuracy of FibroScan for the detection of fibrosis in AIH patients are still limited.





**Material/Methods:** This study enrolled 108 AIH patients who underwent liver biopsies. Using the METAVIR scoring system as the reference, Spearman's rank correlation was performed to explore the relationship between the markers and stages of fibrosis. The area under the receiver operating characteristic curve (AUROC) was used to evaluate the diagnostic accuracy. The optimal LSM cut-off values for predicting the stages of fibrosis were calculated.

**Results:** LSM was superior to other non-invasive markers in differentiating the stages of fibrosis in AIH patients. AUROC value of LSM was 0.885 for stage F2, 0.897 for stage F3, and 0.878 for stage F4. The optimal LSM cut-off value was 6.27 kPa for stage F2, 8.18 kPa for F3, and 12.67 kPa for F4.

**Conclusions:** FibroScan is a valuable non-invasive method for the evaluation of liver fibrosis of AIH patients.

**MeSH Keywords:** **Diagnosis • Hepatitis, Autoimmune • Liver Cirrhosis**

**Full-text PDF:** <https://www.medscimonit.com/abstract/index/idArt/907300>

 2296  5  4  38



## Background

Autoimmune hepatitis (AIH) is a chronic immune-mediated liver inflammatory disease which is characterized by interface hepatitis, responsiveness to steroids, autoantibody production, elevated transaminase levels, and hypergammaglobulinemia [1,2]. AIH can result in cirrhosis, hepatic carcinoma, hepatic failure, and death [3–5]. According to the International Autoimmune Hepatitis Group (IAIHG), the diagnosis of AIH is based on the combination of biochemical, immunological, and histological features, and the exclusion of viral hepatitis [6].

Liver biopsy is considered the criterion standard for evaluation of fibrosis [7]. Guidelines recommend biopsy in patients with AIH to establish diagnosis and to make further treatment decisions [8,9]. The long duration of inflammatory activity leads to liver fibrosis [1]. The extent of fibrosis can be used to assess the response to treatment. Biochemical markers can reflect the therapeutic response during treatment, but they cannot reflect the severity of liver fibrosis. However, despite it being considered the criterion standard, liver biopsy has not been widely accepted by patients because of its limitations, which include bleeding and expense [10], which make it difficult to use liver biopsy as a routine method to diagnose and monitor fibrosis and cirrhosis [11].

Many non-invasive markers for assessing liver fibrosis and cirrhosis have been applied in clinical practice [12], including the aspartate transaminase-to-platelet ratio index (APRI), the fibrosis index based on 4 factors (FIB-4), the aspartate aminotransferase (AST)/alanine aminotransferase (ALT) ratio (AAR), and the AAR/platelet ratio index (AARPRI) [13]. These indices are easy and cheap to obtain, as they measure routine serum markers such as age, platelet counts, and serum ALT and AST concentrations. These non-invasive markers can detect cirrhosis in chronic viral hepatitis and nonalcoholic fatty liver disease (NAFLD) [14,15]; however, their ability to detect the early liver fibrosis stages and cirrhosis of AIH patients is still uncertain.

Transient elastography (TE; FibroScan, Echosens, France) is a novel technology to diagnose liver fibrosis, which is based on the assessment of liver stiffness measurement (LSM) using ultrasound and low-frequency elastic waves [16–18]. FibroScan has high sensitivity, specificity, and accuracy in detecting cirrhosis [19,20]. Many studies have assessed the diagnostic performance and accuracy of FibroScan in detecting cirrhosis, with specificity and sensitivity being reported to approach 90% [21]. In viral hepatitis patients, FibroScan performs better than other non-invasive indices, including APRI and FIB-4, in assessment of the stage of fibrosis [22,23]. Recent studies suggested that LSM is significantly associated stage of liver fibrosis, and performs better than non-invasive markers in patients with AIH [24,25]. However, there are few studies on the

diagnostic performance and accuracy of FibroScan in detecting fibrosis in AIH patients.

Therefore, we performed this study to evaluate the diagnostic accuracy and validity of FibroScan in AIH patients.

## Material and Methods

### Patients

This retrospective analysis included all patients with AIH who were admitted to the State Key Laboratory for Diagnosis and Treatment of Infectious Diseases at the First Affiliated Hospital, College of Medicine, Zhejiang University, between October 2012 and July 2017. The diagnoses of probable and definite AIH were in line with the criteria defined by the International Autoimmune Hepatitis Group (IAIHG) [6].

Data on all patients with AIH who underwent liver biopsy and the FibroScan test were reviewed and included. We excluded all patients with hepatitis B or C virus infection, excessive alcohol consumption, primary biliary cirrhosis (PBC), drug-induced liver disease, primary sclerosing cholangitis (PSC), hepatocellular carcinoma, decompensated cirrhosis, human immunodeficiency virus infection, hereditary metabolic liver disease, severe systemic diseases, or BMI >40 kg/m.

### Liver biopsy

Liver biopsies were performed using the 16 G transfixion pin of more than 1.5 cm in length, with 6 or more available portal tracts under ultrasonographic guidance. Histological inflammation and fibrosis in individual biopsy samples had been assessed by experienced pathologists using the METAVIR scoring system [21]. The grades of hepatic inflammatory activity were: A0, none; A1, mild; A2, moderate; and A3, severe. Liver fibrosis was ranked into 5 stages: F0, no fibrosis; F1, portal fibrosis without septa; F2, portal fibrosis with rare septa; F3, numerous septa without cirrhosis; and F4, cirrhosis [26].

### Liver stiffness measurement by transient elastography

LSM was performed by TE with FibroScan and a 3.5 MHz ultrasound transducer M probe (Echosens, Paris, France) within 3 days of a patient's liver biopsy, according to the manufacturer's instructions [27]. LSM by TE was performed on an area of the right hepatic lobe at least 6 cm in thickness with the absence of major blood vessels and the gallbladder. Only procedures with 10 validated measurements and a success rate greater than 60% were considered as reliable. Results are expressed in kilopascals (kPa), with the median value being used to represent the LSM [27].

**Table 1.** Characteristics of the patients with AIH.

Characteristic	Value (N=108)
Age (years)	46.54±11.73
Gender, n (%)	
Male	20 (18.53)
Female	88 (81.47)
BMI	23.52±6.52
ALT (U/L)	146.51±137.74
AST (U/L)	115.38±91.11
GGT (U/L)	235.36±230.65
AKP (U/L)	192.90±192.87
TBIL (µmol/L)	41.56±52.75
Albumin (g/L)	39.23±5.21
PLT (10 <sup>9</sup> /L)	175.81±63.56
APRI	1.25 (0.75–2.21)
FIB-4	2.34 (1.44–3.75)
AAR	0.86 (0.64–1.14)
AARPRI	0.80 (0.51–1.16)
Autoantibodies positive, n (%)	87 (80.56)
Serum IgG level (g/L)	17.12±5.48
Serum IgM level (g/L)	1.65±1.05
Liver biopsy	
Hepatic inflammatory activity (n)	
0	0
1	22
2	43
3	43
Fibrosis stage (n)	
0	10
1	20
2	24
3	30
4	24
LSM value (kPa)	10.54±6.36

**Clinical measurements**

The following parameters were reviewed: AST, ALT, albumin, gamma-glutamyl transpeptidase (GGT), alkaline phosphatase

**Table 2.** Correlations between noninvasive fibrosis tests and METAVIR fibrosis stages in AIH patients.

Markers	Spearman's r	P value
APRI	0.300	0.002
FIB-4	0.274	0.004
AAR	-0.090	0.356
AARPRI	0.046	0.638
LSM	0.760	<0.001

(AKP), platelets, total bilirubin (TB), serum immunoglobulin completes (IgG, IgM), autoantibodies, and c-reactive protein (CRP). All parameters were measured on the day of liver biopsy. APRI, FIB-4, AAR, and AARPRI were calculated by the following formulas:

$$\begin{aligned} \text{APRI} &= (\text{AST}/\text{ULN of AST})/\text{platelet count (10}^9/\text{L)} \times 100 [28] \\ \text{FIB-4} &= (\text{age} \times \text{AST})/(\text{platelet count (10}^9/\text{L)} \times (\text{ALT})^{1/2}) [29] \\ \text{AAR} &= \text{AST}/\text{ALT ratio [25]} \\ \text{AARPRI} &= \text{AAR}/(\text{platelet count (10}^9/\text{L)}/150) [30]. \end{aligned}$$

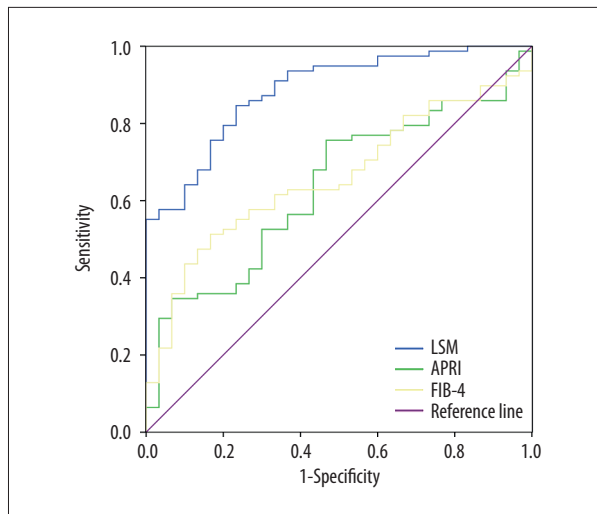
**Statistical analysis**

Continuous data are expressed as mean ± standard deviation or median, depending on the normality of the data. We selected Spearman's rank correlation test to explore the correlation between the markers and the grades of fibrosis. The diagnostic accuracies of LSM, APRI, FIB-4, AAR, and AARPRI were estimated using the area under the receiver operating characteristic curve (AUROC). For fibrosis of F2–4, the optimal cut-off values were selected as the maximal Youden index, which is the sum of the sensitivity and specificity. Positive predictive value (PPV) and negative predictive value (NPV) were also calculated to evaluate the clinical utility according to the ROC curves. AUROCs were compared using MedCalc Statistical Software 16.1 (MedCalc Software bvba, Ostend, Belgium), with all other statistical analyses performed using SPSS for Windows release 20.0 (SPSS Inc., Chicago, IL, USA). A P value <0.05 was considered statistically significant.

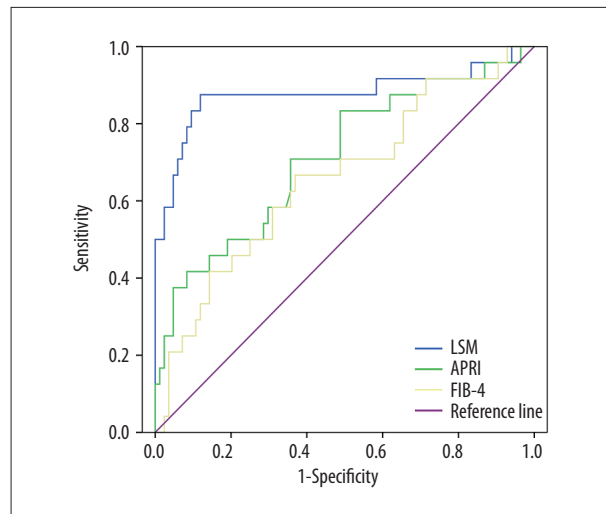
**Results**

**Characteristics of included AIH patients**

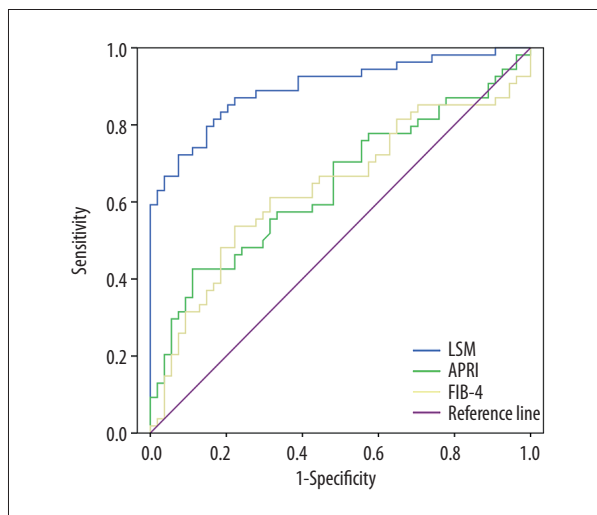
A total of 108 patients with a mean age of 46.54 years were included in this study. The prevalence of autoantibodies was 81.47%. According to the criteria of the simplified scoring system proposed by IAIHG, the 24 patients who had a score of 6 were diagnosed as probable AIH, and the 84 patients who had a score ≥7 were diagnosed as definite AIH. The mean LSM was 10.54 kPa (Table 1).



**Figure 1.** ROCs of LSM, APRI, and FIB-4 to detect fibrosis stage F2.



**Figure 3.** ROCs of LSM, APRI, and FIB-4 to detect fibrosis stage F4.



**Figure 2.** ROCs of LSM, APRI, and FIB-4 to detect fibrosis stage F3.

### Correlation between non-invasive fibrosis tests and METAVIR fibrosis stages in AIH patients

Table 2 showed the analyses of the correlations between non-invasive fibrosis markers and METAVIR fibrosis stages. In the total patient group, the stages of liver fibrosis were correlated with LSM, APRI, and FIB-4, but not with AAR or AARPRI.

### Comparison of LSM with non-invasive markers for the diagnosis of fibrosis

ROCs evaluating the abilities of LSM, APRI, and FIB-4 to detect fibrosis stages F2–4 are shown in Figures 1–3, respectively. In AIH patients, LSM had a higher AUROC than APRI and FIB-4 in the prediction of significant fibrosis, severe fibrosis,

and cirrhosis. However, the AUROCs of APRI and FIB-4 were not significantly different (Table 3).

### Correlation between LSM and clinical measurements

The Spearman's rank correlation test showed there was a statically significant positive association between LSM and the stages of fibrosis. LSM values were not affected by age, BMI, ALT, AST, GGT, AKP, TB, IgG, IgM, or degree of inflammatory activity (Table 4).

### Relationship between LSM and histological fibrosis stages

LSM was closely associated with the stage of fibrosis. The mean LSM values for fibrosis stages F0–F4 were  $4.848 \pm 1.126$ ,  $6.051 \pm 1.421$ ,  $7.271 \pm 1.926$ ,  $11.473 \pm 4.457$ , and  $18.774 \pm 6.526$  kPa, respectively. It was obvious that patients with a higher fibrosis stage had a higher LSM value (Figure 4).

### Diagnostic accuracy of LSM in detecting liver fibrosis

The optimal LSM cut-off values for liver fibrosis stages were 6.27 kPa for significant fibrosis, 8.18 kPa for severe fibrosis, and 12.67 kPa for cirrhosis with the highest Youden index (Table 5).

## Discussion

Liver fibrosis is a reflection of the severity and duration of liver damage in chronic hepatitis. Cirrhosis is the advanced stage of chronic liver diseases, being the result of increased production and decreased destruction of the extracellular matrix [31]. Liver cirrhosis is clinically relevant for chronic liver diseases patients because it is an important factor in the evaluation

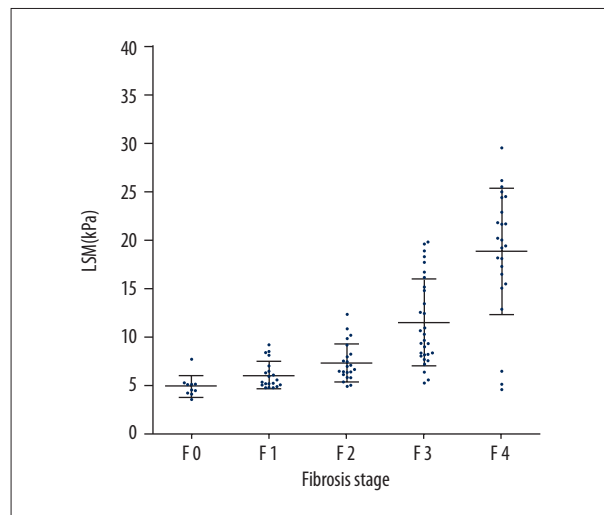
**Table 3.** Comparison of area under the receiver operating characteristic curve for LSM, APRI, and FIB-4 in detection of fibrosis stages F2–4.

AUROC (95% CI)	F ≥F2	F ≥F3	F4
LSM	0.885 (0.820–0.949)	0.897 (0.836–0.957)	0.878 (0.772–0.984)
APRI	0.635 (0.524–0.745)	0.645 (0.540–0.749)	0.713 (0.589–0.836)
FIB-4	0.659 (0.555–0.763)	0.636 (0.529–0.743)	0.658 (0.530–0.786)
LSM vs. APRI	P<0.0001	P<0.0001	P=0.0256
LSM vs. FIB-4	P=0.0001	P<0.0001	P=0.0018
APRI vs. FIB-4	P=0.5793	P=0.8376	P=0.3113

**Table 4.** Correlations between LSM and clinical measurements.

Clinical measurements	Spearman's r	P value
Age	0.137	0.156
ALT	0.069	0.480
AST	0.158	0.102
GGT	0.039	0.691
AKP	0.060	0.539
TBIL	0.071	0.462
Albumin	–0.135	0.165
CRP	0.002	0.985
PLT	–0.185	0.055
IgG	0.014	0.884
IgM	0.064	0.508
Hepatic inflammatory activity degree	–0.001	0.995
Histological fibrosis stage	0.760	<0.0001

of disease progression, therapy response, and their long-term outcomes [32]. Liver biopsy is considered the criterion standard for determination of the stages of fibrosis in chronic liver diseases; however, it is difficult to perform or repeat in clinical practice [33]. Several non-invasive markers have been applied in clinical practice to evaluate the stage of fibrosis in liver diseases [22,34]. In recent years, FibroScan has been thoroughly investigated and has been shown to successfully detect fibrosis in chronic hepatitis [23–25]. Furthermore, it was reported that LSM was significantly correlated with the stages of liver fibrosis in AIH patients [19,20]. A review indicated that LSM has a sensitivity of 70–79% and specificity of 79–84% for a fibrosis stage ≥F2, and sensitivity and specificity for cirrhosis of 83–87% and 89–95%, respectively [29]. Compared with many other chronic liver diseases, including chronic viral hepatitis, the prevalence of AIH is very low. The value of FibroScan in AIH



**Figure 4.** LSM of each fibrosis stage.

has been less thoroughly investigated than in other chronic liver diseases. In the present study, we investigated whether FibroScan can reliably quantify liver fibrosis stages in AIH patients. We found that LSM had a strong correlation with liver fibrosis stage, and was superior to other non-invasive markers in AIH patients.

As reported, FibroScan has a reliable diagnostic value in CHB and CHC patients compared with other non-invasive markers in combination with routine clinical parameters, and LSM can improve assessment of the stage of fibrosis in clinical practice [35]. In the present study, APRI, FIB-4, and LSM showed a statistically significant positive association with the stage of fibrosis in AIH patients. However, it suggested that AAR and AARPRI are not correlated with the stage of fibrosis. The present study indicated that the diagnostic performance of LSM for assessing different fibrosis stages in AIH patients was better than that of APRI and FIB-4. The AUROCs of LSM in the detection of significant fibrosis (≥F2), severe fibrosis (≥F3), and cirrhosis (F4) were 0.885, 0.897, and 0.878, respectively. The AUROCs of APRI were 0.635 in the detection for significant fibrosis, 0.645 for severe fibrosis, and 0.713 for cirrhosis. The AUROCs of FIB-4 in detection

**Table 5.** Diagnostic accuracy of LSM in the detection of liver fibrosis in AIH patients.

Marker	Cut-off	Sensitivity	Specificity	PPV	NPV
LSM					
≥F2	6.27	0.846	0.767	0.904	0.657
≥F3	8.18	0.796	0.852	0.843	0.807
F4	12.67	0.875	0.881	0.963	0.668
APRI					
≥F2	0.88	0.756	0.533	0.808	0.457
≥F3	2.13	0.426	0.889	0.793	0.608
F4	1.50	0.708	0.643	0.874	0.386
FIB-4					
≥F2	2.90	0.513	0.833	0.889	0.397
≥F3	3.21	0.237	0.778	0.516	0.505
F4	2.72	0.667	0.631	0.864	0.351

of the different fibrosis stages were all below 0.7, which means that APRI and FIB-4 have low diagnostic values for the detection of significant fibrosis, severe fibrosis, and cirrhosis. The liver fibrosis stages did not correlate with AAR and AARPRI, and the diagnostic performances and accuracies of APRI and FIB-4 were worse than the results of studies reported in the literature. This may be a result of the high ALT levels in the present study. In previous studies, CHB/CHC patients who had an ALT level more than 2 times their ULN were excluded. In the present study, the mean ALT was 146.51 U/L, which is much higher. Consistent with reported studies, the present results indicate that LSM is superior to APRI and FIB-4 in detecting liver fibrosis and in differentiating fibrosis stages.

It has been reported that the optimal cut-off values for significant fibrosis (≥F2), severe fibrosis (≥F3), and cirrhosis (F4) in CHB patients are 7.8, 8.2, and 11.6 kPa, respectively, and that in CHC patients they are 6.8, 8.6, and 14.5 kPa, respectively [36,37]. The optimal cut-off values for fibrosis stages F2–4 in the present study were 6.27, 8.18, and 12.67 kPa, respectively. Recently, a study focusing on the diagnostic value of LSM in AIH patients demonstrated similar cut-off values, with LSM cut-off values of 6.45 kPa for F2, 8.75 kPa for F3, and 12.5 kPa for F4 [23]. The cut-off values in AIH patients are not the same as those in CHB/CHC patients; the liver disease should be considered when using LSM to detect fibrosis.

It is known that hepatitis inflammatory activity, which is usually reflected by increased serum ALT, can increase the results of LSM, and the ALT flare and hepatic inflammation contribute to LSM and may reduce the diagnostic performance of LSM [38]. In the present study, we used Spearman's rank correlation tests to identify the clinical parameters that influence LSM; the results

suggested that none of the parameters examined in this study, including ALT levels and hepatic inflammation, affect the accuracy of LSM in the detection of fibrosis in AIH patients.

Long-term treatment with corticosteroids alone or in combination with azathioprine is proposed when the AIH diagnosis is established. The effect of treatment on the diagnostic performance of LSM has been studied, but the results are still inconsistent. Hartl reported that, to differentiate patients with cirrhosis, FibroScan has a better performance for AIH patients who received longer treatment vs. shorter duration or treatment-naïve patients [24]. However, Olympia et al., in a study that included 18 treated and 35 treatment-naïve AIH patients, a similar result could not be demonstrated. In the present study, all patients included were treatment-naïve AIH patients; therefore, we could not investigate these effects [25].

This study had several limitations, including its retrospective design, and the enrollment of patients from a single center may have introduced selection biases. The number of patients was quite small, which may have led to statistical bias when evaluating the diagnostic performance of LSM. Non-invasive fibrosis markers have limited diagnostic value in differentiating the stages of fibrosis in AIH patients. Large-scale, prospective, multi-center studies are needed to validate the diagnostic values of LSM.

## Conclusions

In conclusion, LSM showed good diagnostic performance and accuracy in the detection of fibrosis in AIH patients. FibroScan is a valuable non-invasive detection method for use in differentiating of fibrosis stages.

**Conflicts of interest**

None.

**References:**

- Manns MP, Lohse AW, Vergani D: Autoimmune hepatitis – Update 2015. *J Hepatol*, 2015; 62: S100–11
- Czaja AJ, Manns MP: Advances in the diagnosis, pathogenesis, and management of autoimmune hepatitis. *Gastroenterology*, 2010; 139: 58–72.e54
- Lohse AW, Mieli-Vergani G: Autoimmune hepatitis. *J Hepatol*, 2011; 55: 171–82
- Shibuki T, Otsuka T, Isoda H et al: Seropositivity and titers of anti-smooth muscle actin antibody are associated with relapse of Type 1 autoimmune hepatitis. *Med Sci Monit*, 2017; 23: 4028–33
- Gharibpoor A, Mansourghanaei F, Sadeghi M et al: Innumerable liver masses in a patient with autoimmune hepatitis and primary sclerosing cholangitis overlap syndrome. *Am J Case Rep*, 2017; 18: 131–35
- Hennes EM, Zeniya M, Czaja AJ et al: Simplified criteria for the diagnosis of autoimmune hepatitis. *Hepatology (Baltimore, Md.)*, 2008; 48: 169–76
- Lindor KD, Bru C, Jorgensen RA et al: The role of ultrasonography and automatic-needle biopsy in outpatient percutaneous liver biopsy. *Hepatology (Baltimore, Md.)*, 1996; 23: 1079–83
- Manns MP, Czaja AJ, Gorham JD et al: Diagnosis and management of autoimmune hepatitis. *Hepatology (Baltimore, Md.)*, 2010; 51: 2193–213
- European Association for the Study of the Liver: Autoimmune hepatitis. *J Hepatol*, 2015; 63: 971–1004
- Takyar V, Etzion O, Heller T et al: Complications of percutaneous liver biopsy with Klatskin needles: A 36-year single-centre experience. *Aliment Pharmacol Ther*, 2017; 45: 744–53
- Rockey DC, Caldwell SH, Goodman ZD et al: Liver biopsy. *Hepatology*, 2009; 49: 1017–44
- Kim WR, Berg T, Asselah T et al: Evaluation of APRI and FIB-4 scoring systems for non-invasive assessment of hepatic fibrosis in chronic hepatitis B patients. *J Hepatol*, 2016; 64: 773–80
- Vallet-Pichard A, Mallet V, Nalpas B et al: FIB-4: An inexpensive and accurate marker of fibrosis in HCV infection. comparison with liver biopsy and fibrotest. *Hepatology (Baltimore, Md.)*, 2007; 46: 32–36
- Wai CT, Greenon JK, Fontana RJ et al: A simple noninvasive index can predict both significant fibrosis and cirrhosis in patients with chronic hepatitis C. *Hepatology*, 2003; 38(2): 518–26
- Sterling RK, Lissen E, Clumeck N et al: Development of a simple noninvasive index to predict significant fibrosis in patients with HIV/HCV coinfection. *Hepatology*, 2006; 43: 1317–25
- Friedrich-Rust M, Poynard T, Castera L: Critical comparison of elastography methods to assess chronic liver disease. *Nat Rev Gastroenterol Hepatol*, 2016; 13: 402–11
- Horváth G: New non-invasive tool for assessment of liver fibrosis: Transient elastography. *Orvosi Hetilap*, 2011, 152(22): 860–65
- Stättermayer AF, Eder M, Beinhardt S et al: Value of transient elastography (Fibroscan®) in patients with autoimmune hepatitis on immunosuppressive treatment. *J Hepatol*, 2016; 64(2): S425
- Dai T, Jia S, Hao M et al: Transient elastography with serum hepatitis B surface antigen enhances liver fibrosis detection. *Med Sci Monit*, 2016; 22: 2878–85
- Sandrin L, Fourquet B, Hasquenoph JM et al: Transient elastography: A new noninvasive method for assessment of hepatic fibrosis. *Ultrasound Med Biol*, 2003; 29: 1705–13
- Huang R, Jiang N, Yang R et al: Fibroscan improves the diagnosis sensitivity of liver fibrosis in patients with chronic hepatitis B. *Exp Ther Med*, 2016; 11: 1673–77
- Li Y, Cai Q, Zhang Y et al: Development of algorithms based on serum markers and transient elastography for detecting significant fibrosis and cirrhosis in chronic hepatitis B patients: Significant reduction in liver biopsy. *Hepatol Res*, 2016; 46: 1367–79
- Xu Q, Sheng L, Bao H et al: Evaluation of transient elastography in assessing liver fibrosis in patients with autoimmune hepatitis. *J Gastroenterol Hepatol*, 2017; 32: 639–44
- Hartl J, Denzer U, Ehlken H et al: Transient elastography in autoimmune hepatitis: Timing determines the impact of inflammation and fibrosis. *J Hepatol*, 2016; 65: 769–75
- E Anastasiou O, Büchter M1, A Baba H et al: Performance and utility of transient elastography and non-invasive markers of liver fibrosis in patients with autoimmune hepatitis: A single centre experience. *Hepat Mon*, 2016; 16: e40737
- Bedossa P, Poynard T: An algorithm for the grading of activity in chronic hepatitis C. The METAVIR Cooperative Study Group. *Hepatology (Baltimore, Md.)*, 1996; 24: 289–93
- Kim JH, Kim MN, Han KH, Kim SU: Clinical application of transient elastography in patients with chronic viral hepatitis receiving antiviral treatment. *Liver Int*, 2015; 35: 1103–15
- El Serafy MA, Kassem AM, Omar H et al: APRI test and hyaluronic acid as non-invasive diagnostic tools for post HCV liver fibrosis: Systematic review and meta-analysis. *Arab J Gastroenterol*, 2017; 18: 51–57
- Parikh P, Ryan JD, Tsochatzis EA: Fibrosis assessment in patients with chronic hepatitis B virus (HBV) infection. *Ann Transl Med*, 2017; 5: 40
- Mansoor S, Collyer E, Alkhoufi N: A comprehensive review of noninvasive liver fibrosis tests in pediatric nonalcoholic fatty liver disease. *Curr Gastroenterol Rep*, 2015; 17: 23
- Lee YA, Wallace MC, Friedman SL: Pathobiology of liver fibrosis: A translational success story. *Gut*, 2015; 64: 830–41
- Jung YK and Yim HJ: Reversal of liver cirrhosis: Current evidence and expectations. *Korean J Intern Med*, 2017; 32: 213–28
- Mani H and Kleiner DE: Liver biopsy findings in chronic hepatitis B. *Hepatology (Baltimore, Md.)*, 2009; 49: S61–71
- Wong S, Huynh D, Zhang F, Nguyen NQ: Use of aspartate aminotransferase to platelet ratio to reduce the need for FibroScan in the evaluation of liver fibrosis. *World J Hepatol*, 2017; 9: 791–96
- Poynard T, Munteanu M, Luckina E et al: Liver fibrosis evaluation using real-time shear wave elastography: Applicability and diagnostic performance using methods without a gold standard. *J Hepatol*, 2013; 58: 928–35
- Seo YS, Kim MY, Kim SU et al: Accuracy of transient elastography in assessing liver fibrosis in chronic viral hepatitis: A multicentre, retrospective study. *Liver Int*, 2015; 35: 2246–55
- Chon YE, Choi EH, Song KJ et al: Performance of transient elastography for the staging of liver fibrosis in patients with chronic hepatitis B: A meta-analysis. *PLoS One*, 2012; 7: e44930
- Wong GL: Update of liver fibrosis and steatosis with transient elastography (Fibroscan). *Gastroenterol Rep (Oxf)*, 2013; 1: 19–26