

Contents lists available at [ScienceDirect](http://www.sciencedirect.com)

## International Journal of Surgery Case Reports

journal homepage: [www.casereports.com](http://www.casereports.com)

## Excision of the urachal remnant using the abdominal wall-lift laparoscopy: A case report

Kosuke Kobayashi<sup>a,\*</sup>, Kazuhito Sasaki<sup>a</sup>, Tatsuo Iijima<sup>b</sup>, Fuyo Yoshimi<sup>a</sup>, Hideo Nagai<sup>a</sup><sup>a</sup> Department of Surgery, Ibaraki Prefectural Central Hospital & Cancer Center 6528 Koibuchi, Kasama, Ibaraki 309-1793, Japan<sup>b</sup> Department of Diagnostic Pathology, Ibaraki Prefectural Central Hospital & Cancer Center 6528 Koibuchi, Kasama, Ibaraki 309-1793, Japan

## ARTICLE INFO

## Article history:

Received 25 December 2015

Received in revised form 23 March 2016

Accepted 23 March 2016

Available online 26 March 2016

## Keywords:

Urachal remnant

Laparoscopic

Abdominal wall lift

## ABSTRACT

**INTRODUCTION:** Here, we report the surgical excision of the urachal remnant using the abdominal wall-lift laparoscopy with a camera port in the umbilicus, combined with a small Pfannenstiel incision to optimally treat the bladder apex.

**PRESENTATION OF CASE:** A 21-year-old woman presented with periumbilical discharge and pain on urination. Contrast enhanced CT and MRI showed an abscess in the umbilical region that was connected to the bladder via a long tube-like structure. It was diagnosed as an infected urachal sinus. Partial excision of the umbilical fossa followed by dissection of the urachal remnant was easily performed using the abdominal wall-lift laparoscopy from the umbilicus down to the bladder without pneumoperitoneum or additional trocar placement. A Pfannenstiel incision was made above the pubis to get access to the junction between the urachal remnant and the bladder. Under direct vision, we succeeded in accurately dividing the remnant tract, and we adequately closed the bladder opening with absorbable sutures. This method has the advantage of easily closing peritoneal defects after excision of the urachal remnant with direct sutures under a laparoscopic view from the umbilicus. Cosmetic satisfaction was obtained postoperatively.

**DISCUSSION AND CONCLUSION:** Urachal sinus excision using the abdominal wall-lift laparoscopy seems to surpass the previously reported methods in term of safety, cosmetics, and adequacy of surgical procedures.

© 2016 The Authors. Published by Elsevier Ltd. on behalf of IJS Publishing Group Ltd. This is an open access article under the CC BY-NC-ND license (<http://creativecommons.org/licenses/by-nc-nd/4.0/>).

## 1. Introduction

Congenital anomalies of the urachal remnant range from a diverticulum to a sinus or a patent urachal remnant extended from the bladder up to the umbilical fossa. The latter anomaly often induces inflammation along the tract and/or urine leakage from the umbilicus. The principal treatment of an urachal remnant is the complete resection of the whole tract. This requires a long mid-line skin incision in the lower abdomen, which inevitably causes a major cosmetic disadvantage of a conspicuous scar formation.

To alleviate this drawback, laparoscopic excision of the urachal remnant was first demonstrated in 1992 by Neufung et al. [1], and since then several trials of laparoscopic surgery to correct the urachal anomaly have been reported [2–10]. However, the techniques, including port placement arrangements and division and suture of the bladder, have not yet been standardized. Furthermore, the method of closing the bladder opening after resection of the remnant tract is still controversial. Some authors maintain the use-

fulness of a stapler under laparoscopic view to close the bladder apex, a technique which contradicts the opinion of urologists who argue that absorbable sutures should be used to minimize the risk of urolithiasis.

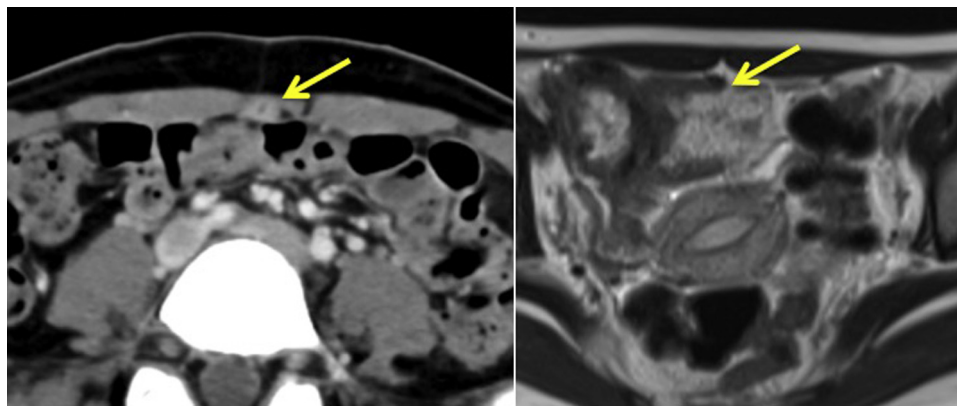
Here, we review our experience of excising the urachal remnant using the abdominal wall-lift laparoscopy. This method provides for the relatively free use of conventional instruments and techniques and eliminates pneumoperitoneum- or CO<sub>2</sub>-related complications [11]. For optimal incision and closure of the bladder apex, we added a Pfannenstiel incision above the pubis.

## 2. Case report

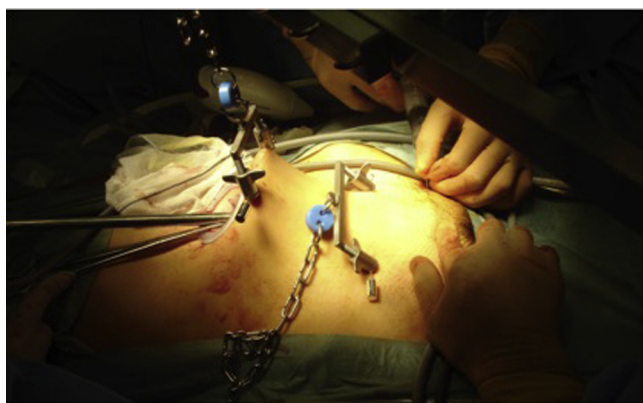A 21-year-old previously healthy woman was referred to our hospital with complaints of periumbilical discharge and pain on urination. She had a lean physique with body mass index of 17 [42.6 kg/(1.58 m)<sup>2</sup>]. A physical examination found purulent discharge from the bottom of the umbilicus and a reddish tinge to the surrounding skin. Abdominal computed tomography(CT) and magnetic resonance imaging(MRI) revealed an abscess in the umbilical region that was connected to the bladder via a long band, in part via a long tube-like structure(Fig. 1). The diagnosis of an infected urachal sinus was made. After treatment with antibiotics

\* Corresponding author at: Ibaraki Prefectural Central Hospital & Cancer Center 6528 Koibuchi, Kasama, Ibaraki 309-1793, Japan.

E-mail address: [kobayashik-sur@h.u-tokyo.ac.jp](mailto:kobayashik-sur@h.u-tokyo.ac.jp) (K. Kobayashi).



**Fig. 1.** Abdominal computed tomography and MRI/An abscess in the umbilical region that was connected to the bladder via a long band, in part via a long tube-like structure (arrow).



**Fig. 2.** surgical incisions and abdominal wall-lift/A 15 mm infra-umbilical incision and a 6 cm Pfannenstiel incision, two wires were placed for wall-lift.

and anti-inflammatory drugs, an elective laparoscopic surgery was performed.

### 2.1. Materials and surgical technique

Under general anesthesia, the patient was placed in a leg-open position and a transurethral Foley catheter was inserted. The surgeon and camera surgeon stood on the left side of the patient with the monitor in a caudal position relative to the patient. Through a 15 mm infra-umbilical incision, the subcutaneous tissue and the anterior layer of the rectus fascia were dissected in a T-shape. The umbilical edge of the urachal remnant was circumcised from the umbilical base. The urachal remnant was then continuously dissected distally as far as possible in the preperitoneal space.

A small-sized LapProtector™ (Hakko, Nagano, Tokyo) was inserted through the umbilical incision into the preperitoneal space. For the abdominal wall-lift, two wires were placed subcutaneously and pulled upward, 2 cm below the umbilicus and halfway between the umbilicus and the pubis, respectively (Fig. 2). A rigid, straight-viewing laparoscope was inserted via the LapProtector™. The urachal remnant was dissected toward the bladder mainly with a bipolar sealing device (LigaSure™)(COVIDIEN, MN). The dissection was mostly performed in the preperitoneal space and sometimes in the abdominal cavity.

A 6 cm Pfannenstiel incision was added 2 cm above the pubis to get access to the conjunction of the urachal remnant to the bladder. After the bladder was filled with 300 ml of saline through the Foley catheter, a bladder cuff including the urachal insertion was excised along with the whole urachal sinus. The opening at the bladder

apex was closed with absorbable sutures (4-0 Vicryl™)(Johnson & Johnson, NJ) under direct vision.

The peritoneal defects were closed with several running sutures under a laparoscopic view from the umbilical incision (Fig. 3). Seprafilm™ (Kaken Pharmaceutical, Tokyo, Japan) was placed under the sutured peritoneum to prevent adhesion. Finally, an umbilicoplasty was performed with the assistance of a plastic surgeon. A drain tube was not inserted.

#### 2.1.1. Pathological findings

The sinus had a lumen lined mostly with transitional and columnar epithelia. The lumen near the umbilicus was covered with stratified squamous cells. Inflammatory cell infiltration was mild and no abscess formation was found. These findings were pathomorphologically compatible with the urachal sinus. No neoplastic lesions were observed (Fig. 4).

#### 2.1.2. Postoperative treatment

The patient had an uneventful recovery and was discharged seven days after surgery. The patient had no complaints of symptoms 18 months postoperatively and was satisfied with the cosmetic results. The umbilical-incision scar was hardly visible and the Pfannenstiel incision was concealed by regrowth of pubic hair.

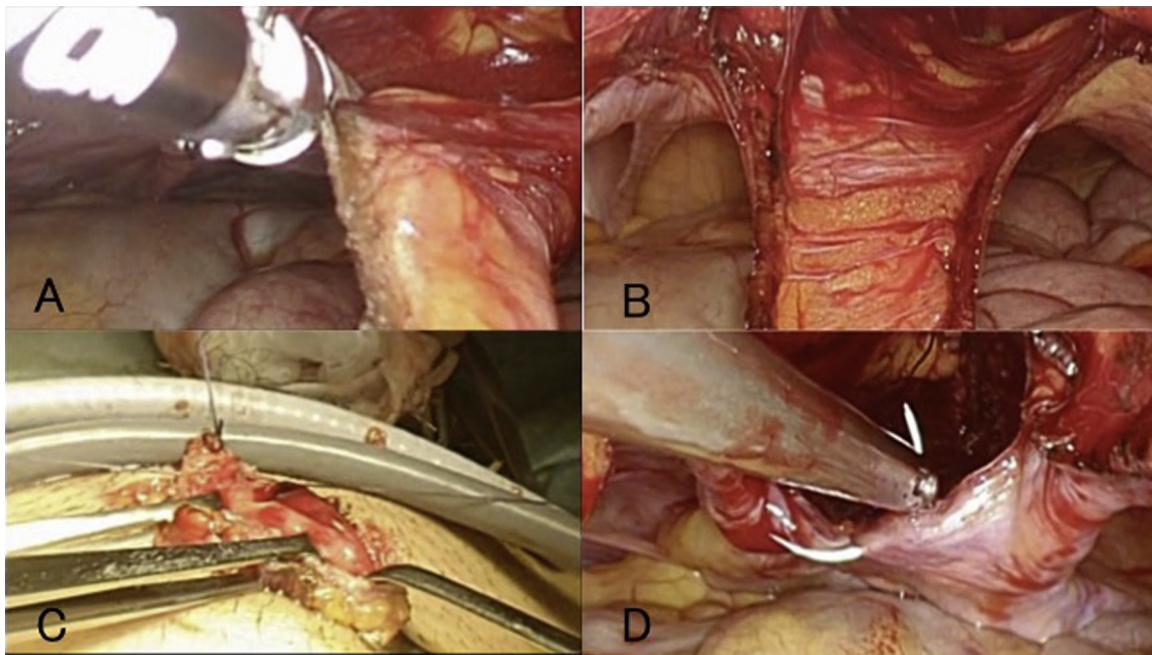
## 3. Discussion

The urachal remnant is a rare congenital anomaly with an incidence of 1:300,000 in infants and 1:5000 in adults [12]. Infection can occur as a common complication of the urachal remnant, and urachal carcinomas have also been reported [13,14].

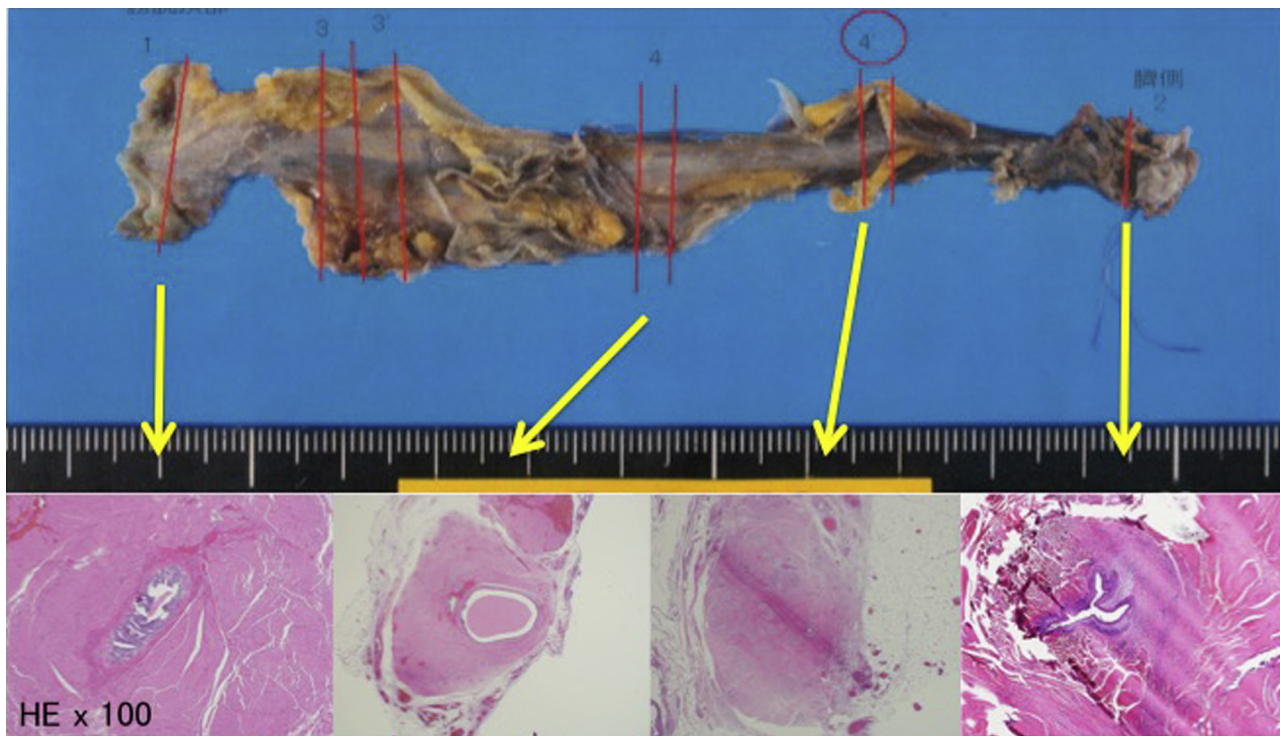
Until recently, excision of the urachal remnant was performed by a laparotomy with a long skin incision from the umbilicus to the suprapubic area [12,15]. After the description of a laparoscopic resection of the urachal remnant by Neufang et al. [1] in 1992, several more reports on laparoscopic techniques have been published [2–10]. A laparoscopic resection of the urachal remnant has been suggested to be technically feasible and minimally invasive. It has also been suggested that a laparoscopic procedure provides better cosmesis, thus contributing to the quality of life of young female patients in particular.

According to earlier reports, laparoscopic management of the urachal remnant seems to be safe and relatively easy, but attention should be made to the following points.

First, various port placement arrangements have been proposed. Before the advent of single-port laparoscopic surgery, a camera port and other trocars were placed away from the umbilicus, and a 30° oblique laparoscope was used to observe the lesion in the anterior



**Fig. 3.** laparoscopic view from the umbilical incision/The dissection was mostly performed in the preperitoneal space and sometimes in the abdominal cavity (A, B). Pfannenstiel incision was added to get access to the conjunction of the urachal remnant to the bladder (C). The peritoneal defects were closed with several running sutures (D).



**Fig. 4.** Pathological findings/The sinus had a lumen lined mostly with transitional and columnar epithelia. The lumen near the umbilicus was covered with stratified squamous cells. Inflammatory cell infiltration was mild and no abscess formation was found. These findings were pathomorphologically compatible with the urachal sinus.

abdominal wall [2]. In the current case, we used the abdominal wall-lift laparoscopy to get a good view of the preperitoneal space with a camera port at the umbilicus. In this way we could insert a straight-viewing laparoscope and some additional manipulating instruments without the need for additional trocars.

Second, an incomplete resection of the remnant may lead to recurrent infections. In this sense, complete excision is essential

although the edge of the bladder has an ill-defined border. Furthermore, the technique chosen to close the bladder opening after resection of the remnant tract (stapler or absorbable sutures) is also important and has consequences for possible urolithiasis. For precise detection and division of the bladder junction followed by meticulous suturing of the bladder opening, we suggest that surgeons make an additional incision above the pubis, as described in

the present case. The Pfannenstiel incision that we used provides a good view of the operative field as well as an excellent cosmetic outcome.

Third, peritoneal defects can occur during excision of the urachal remnant even with a preperitoneal approach. These defects must be closed to prevent adhesive ileus. It is generally difficult to repair anterior peritoneal defects by a laparoscopic surgery. But the direct sutures from the umbilical incision are easily done under a laparoscopic view with an abdominal wall-lift. The combined use of a bio-absorptive adhesion-preventive film may be of some help to prevent intestinal obstruction after surgery.

#### 4. Conclusion

In conclusion, we propose that the abdominal wall-lift technique is a promising surgical option for patients with a symptomatic urachal remnant, in terms of optimal procedures and satisfactory cosmetic results.

#### Conflict of interest

None declared.

#### Source of funding

None.

#### Ethical approval

Because of the case report, the ethics committee was not held.

#### Consent

Written informed consent was obtained from the patient for publication of this case and any accompanying images.

#### Author contribution

K.K. conceived of this case presentation and drafted the manuscript. S.K., T.I., F.Y., and H.N. participated in the treatment of this case. All authors read and approved the final manuscript.

#### Acknowledgments

The authors have no conflict of interest to declare. All authors have read and approved the final manuscript. Written informed consent was obtained from the patient for publication of this report.

#### Appendix A. Supplementary data

Supplementary data associated with this article can be found, in the online version, at <http://dx.doi.org/10.1016/j.ijscr.2016.03.037>

#### References

- [1] T. Neufang, F.E. Ludtke, G. Lepsien, laparoscopic excision of an urachal fistula—a new therapy for a rare disorder, *Minim. Invasive Ther. Allied Technol.* 1 (3) (1992) 245–249.
- [2] M. Patrzyk, A. Glitsch, A. Schreiber, W. von Bernstorff, C.D. Heidecke, Single-incision laparoscopic surgery as an option for the laparoscopic resection of an urachal fistula: first description of the surgical technique, *Surg. Endosc.* 24 (9) (2010) 2339–2342.
- [3] R. Baier, B. Rumstadt, Laparoscopic resection of urachal fistula, *Surg. Laparosc. Endosc. Percutan. Technol.* 21 (2011) 295–296, United States.
- [4] M. Araki, T. Saika, D. Araki, Y. Kobayashi, S. Uehara, T. Watanabe, et al., Laparoscopic management of complicated urachal remnants in adults, *World J. Urol.* 30 (5) (2012) 647–650.
- [5] M. Castanheira de Oliveira, F. Vila, R. Versos, D. Araujo, A. Fraga, Laparoscopic treatment of urachal remnants, *Actas Urol. Esp.* 36 (2012) 320–324, Spain: 2011 AEU. Published by Elsevier Espana.
- [6] T. Iida, G. Kawa, N. Takizawa, T. Kawabata, Y. Komai, H. Kinoshita, et al., Laparoendoscopic single-site surgery for urachal remnants, *Asian J. Endosc. Surg.* 5 (2) (2012) 100–102.
- [7] F. Sato, T. Shin, H. Yuki, M. Liang, T. Ando, K. Mori, et al., Umbilical laparoendoscopic single-site technique for complete excision of urachal remnant, *J. Laparoendosc. Adv. Surg. Tech. A* 22 (9) (2012) 899–903.
- [8] H.J. Jeong, D.Y. Han, W.A. Kwon, Laparoscopic management of complicated urachal remnants, *Chonnam Med. J.* 49 (1) (2013) 43–47.
- [9] N. Niwa, H. Yanaihara, Y. Nakahira, F. Hanashima, M. Horinaga, H. Asakura, Laparoscopic excision of infected urachal remnant: a case report, *Nihon Hinyokika Gakkai Zasshi* 104 (1) (2013) 12–16.
- [10] M. Patrzyk, L. Wilhelm, K. Ludwig, C.D. Heidecke, W. von Bernstorff, Improved laparoscopic treatment of symptomatic urachal anomalies, *World J. Urol.* 31 (6) (2013) 1475–1481.
- [11] H. Nagai, Y. Kondo, T. Yasuda, K. Kasahara, K. Kanazawa, An abdominal wall-lift method of laparoscopic cholecystectomy without peritoneal insufflation, *Surg. Laparosc. Endosc.* 3 (3) (1993) 175–179.
- [12] S.M. Berman, B.M. Tolia, E. Laor, R.E. Reid, S.P. Schweizerhof, S.Z. Freed, Urachal remnants in adults, *Urology* 31 (1) (1988) 17–21.
- [13] A.B. Paul, C.R. Hunt, J.M. Harney, J.P. Jenkins, R.F. McMahon, Stage 0 mucinous adenocarcinoma in situ of the urachus, *J. Clin. Pathol.* 51 (6) (1998) 483–484.
- [14] A. Gopalan, D.S. Sharp, S.W. Fine, S.K. Tickoo, H.W. Herr, V.E. Reuter, et al., Urachal carcinoma: a clinicopathologic analysis of 24 cases with outcome correlation, *Am. J. Surg. Pathol.* 33 (5) (2009) 659–668.
- [15] M. Blichert-Toft, O.V. Nielsen, Diseases of the urachus simulating intra-abdominal disorders, *Am. J. Surg.* 122 (1971) 123–128, United States.

#### Open Access

This article is published Open Access at [sciendo.com](http://sciendo.com). It is distributed under the [IJSCR Supplemental terms and conditions](#), which permits unrestricted non commercial use, distribution, and reproduction in any medium, provided the original authors and source are credited.