

Testicular Seminoma Presenting as Gastrointestinal Bleeding: A Rare Cause of Metastatic Disease in the Stomach

Maria Azevedo Silva^a Carina Leal^a André Ruge^a Alexandra Fernandes^a
Maria Fernanda Cunha^b Helena Vasconcelos^a

^aDepartment of Gastroenterology, Centro Hospitalar de Leiria, Leiria, Portugal; ^bDepartment of Pathology, Centro Hospitalar de Leiria, Leiria, Portugal

Keywords

Testicular seminoma · Gastric metastases · Gastrointestinal bleeding

Abstract

Introduction: Gastric metastases are quite infrequent. When arising from testicular germ cell tumors, gastric metastases are usually associated with nonseminomas. **Case Report:** A 45-year-old man presented with upper gastrointestinal bleeding, severe anemia, and elevated lactate dehydrogenase. Endoscopy revealed three atypical-looking gastric ulcers. Abdominal computed tomography showed an extensive heterogeneous retroperitoneal mass and a smaller one in the pelvis. Biopsies of both the ulcers and the retroperitoneal mass revealed a highly proliferative neoplasia of unknown origin. While the diagnostic work up was taking place, the patient complained of a testicular mass which was resected, after suspicious findings in the ultrasound. Histopathologic findings revealed a testicular seminoma. Revision of previous biopsies was compatible with metastatic seminoma to the stomach and the retroperitoneum. **Discussion/Conclusion:** Gastric metastasis arising from testicular seminoma is quite infrequent and usually diagnosed after the primary tumor is known. We report a rare case of a testicular seminoma presenting as upper gastrointestinal

bleeding due to gastric metastases. This case highlights the importance of detailed anamnesis and physical examination in the differential diagnosis of atypical gastric ulcers with initial inconclusive work up and emphasizes an unusual manifestation of a germ cell malignancy.

© 2022 The Author(s).
Published by S. Karger AG, Basel

Manifestação inaugural de seminoma testicular como hemorragia digestiva: uma causa rara de metastização gástrica

Palavras-chave

Seminoma testicular · Metastização gástrica · Hemorragia digestiva

Resumo

Introdução: As metástases gástricas são bastante infrequentes. Quando são secundárias a tumores testiculares, geralmente as metástases gástricas associam-se a não-seminomas. **Caso Clínico:** Um homem de 45 anos recorreu ao serviço de urgência por quadro de hemorragia digestiva alta, tendo-se detetado uma anemia grave e elevação da lactato desidrogenase. A endoscopia revelou

três úlceras gástricas de aspeto atípico. A tomografia computadorizada abdominal mostrou uma extensa massa heterogénea retroperitoneal e outra de menores dimensões na cavidade pélvica. Foram realizadas biópsias das úlceras gástricas e da massa retroperitoneal, sendo compatíveis com uma neoplasia altamente proliferativa de origem indeterminada. Durante a investigação etiológica, o doente referiu a deteção de uma massa testicular. Esta foi ressecada após a realização de ecografia com achados suspeitos. A histologia fez o diagnóstico de um seminoma testicular. A revisão das biópsias prévias foi compatível com metastização gástrica e retroperitoneal do seminoma. **Discussão/Conclusão:** A metastização gástrica com origem em seminomas do testículo é infrequente e geralmente é detetada após o diagnóstico do tumor primário. Apresenta-se um caso raro de manifestação inaugural de um seminoma testicular como hemorragia digestiva alta devido a metástases gástricas. Este caso evidencia a importância de uma anamnese e um exame objetivo detalhados no diagnóstico diferencial de úlceras gástricas atípicas com investigação inicial negativa, salientando também uma manifestação infrequente de uma neoplasia de células germinativas.

© 2022 The Author(s).
Published by S. Karger AG, Basel

Introduction

Gastric metastases from solid primary malignancies are rare findings, usually diagnosed in a setting of a known advanced primary tumor, more frequently lung and breast cancers [1]. They present more often as solitary le-

sions with submucosal endoscopic appearance [2]. Metastases in the gastric mucosa are even rarer, with a reported incidence of 0.2–0.7% among patients with non-hematologic malignancies in postmortem studies [3].

Testicular germ cell tumors metastasize to the gastrointestinal tract in about 5% of cases, most of these evolving in the small intestine and manifesting as bowel obstruction or, less frequently, as gastrointestinal bleeding [4]. They are classified as seminomas and nonseminomas. Seminomas are the least likely testicular tumor to metastasize to the gastrointestinal tract, with an incidence of 1% in a 486-post-mortem-cases study [4]. We report a rare case of a previously undiagnosed testicular seminoma presenting as upper gastrointestinal bleeding due to multiple metastases to the gastric mucosa.

Case Report

A 45-year-old man without past medical history was admitted to the emergency room with weight loss (11% of total body weight in 2 months), asthenia, and fever, followed by melaena. The initial work up revealed a severe normocytic normochromic anemia (hemoglobin at 4.1 g/dL, normal range [NR]: 13.0–17.7) and markedly elevated lactate dehydrogenase (2,231 U/L, NR: 100–247). Upper endoscopy showed three atypical-looking ulcers in the greater curvature of the gastric body, one of which with a visible vessel successfully submitted to endoscopic hemostasis with two through-the-scope clips after diluted adrenalin injection (1:10,000) in and around the ulcer base (shown in Fig. 1). Biopsies of the ulcers were performed. Abdominal computed tomography revealed an extensive heterogeneous retroperitoneal mass with a diameter of 15 cm, causing inferior vena cava stenosis, and a right pelvic mass with a diameter of 10 cm (shown in Fig. 2). The laboratory evaluation was notable for neuron-specific enolase of 168.5 ng/mL (NR: < 12.5). Prostate-specific antigen, carcinoembryonic antigen, alpha-fetoprotein, cancer antigens 19-9 and 72-4, immunoglobulin levels, protein

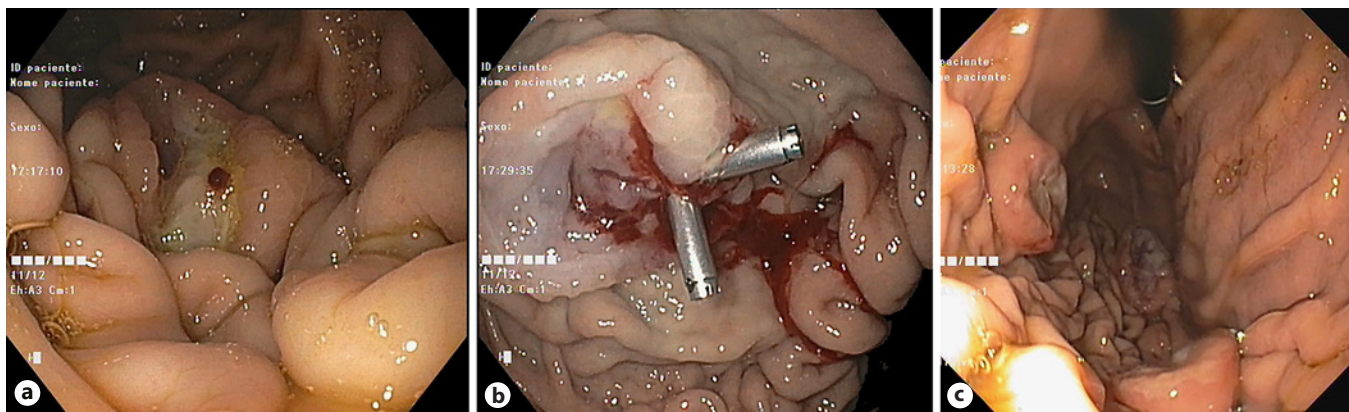


Fig. 1. Atypical “volcano-like” gastric ulcers. **a, b** One of the ulcers with a visible vessel that was submitted to endoscopic hemostasis. **c** Four-week re-evaluation with repeated biopsies.

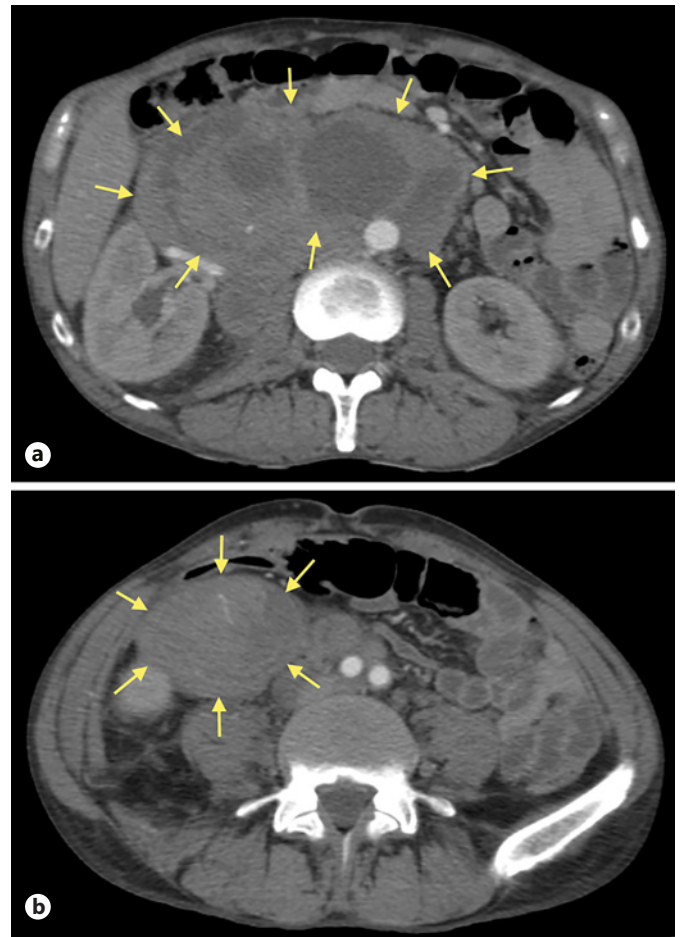
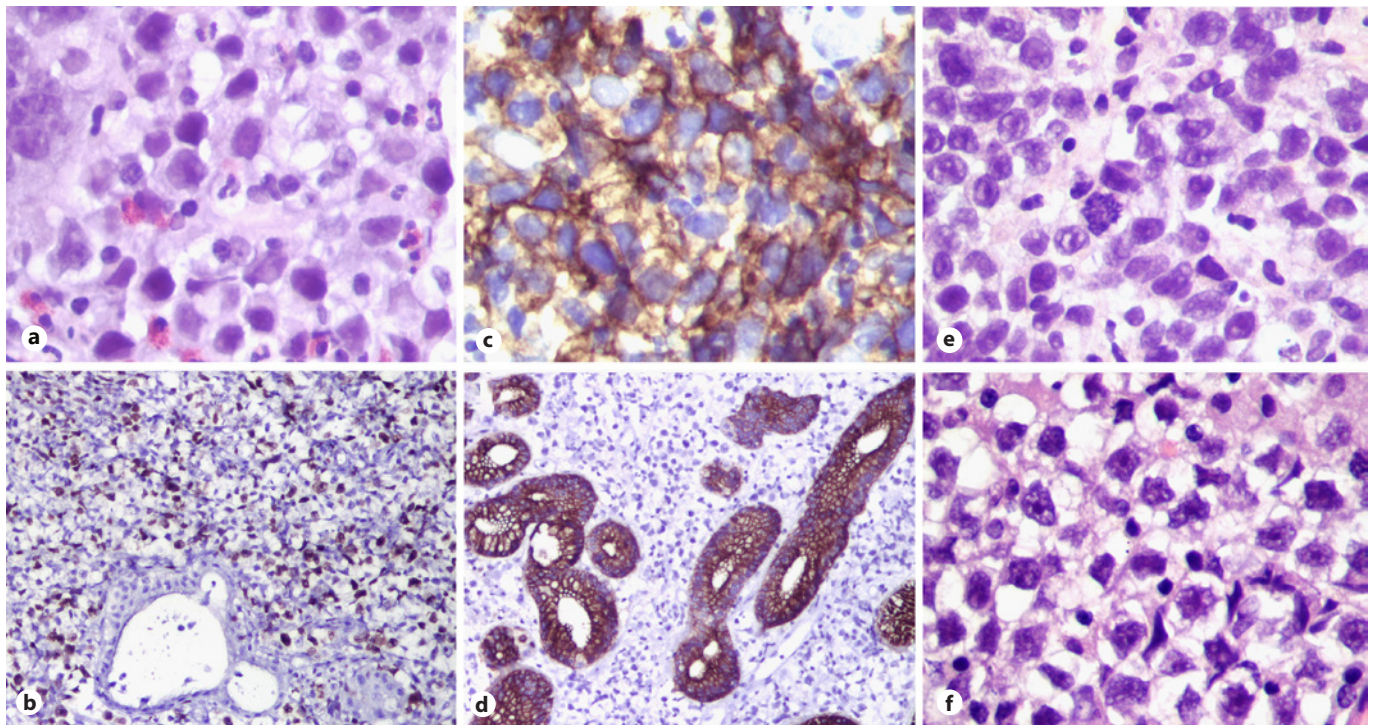


Fig. 2. Abdominal computed tomography findings. **a** An extensive heterogeneous retroperitoneal mass with a diameter of 15 cm. **b** A right pelvic mass with a diameter of 10 cm.

Fig. 3. Histologic findings: gastric biopsies revealing large cells with big hyperchromatic nuclei and prominent nucleoli, independent from the gastric glandular component (**a**, hematoxylin and eosin, $\times 400$), with high proliferation index (Ki-67, **b**, $\times 100$), positivity for CD117 (**c**, $\times 400$), and negativity for cytokeratins (**d**, $\times 100$). Identical findings in the retroperitoneal mass biopsy (**e**, $\times 400$) and in the testicular tumor specimen (**f**, $\times 400$).



electrophoresis, immunophenotyping of peripheral blood and human immunodeficiency virus serology were negative. Gastric ulcers' biopsies revealed a highly proliferative neoplasia of unknown origin, dissociated from the gastric glandular component, with immunohistochemical positivity for cluster of differentiation (CD) 56, CD117, CD68, CD10, and CD99 and negativity for cytokeratins, CD3, CD5, CD20, CD23, B-cell lymphoma 2, B-cell lymphoma 6, cyclin D1, melan-A, myeloperoxidase, and neuroendocrine markers (shown in Fig. 3a–d). The retroperitoneal mass biopsy showed an undifferentiated neoplastic proliferation with similar histologic findings and immunohistochemical profile (shown in Fig. 3e). The remaining study performed over the following weeks was unremarkable, including head, neck, chest, and lumbar/dorsal spine computed tomography; prostatic ultrasound; and colonoscopy. One month after the initial presentation, upper endoscopy was repeated under deep sedation. Similar findings were observed (shown in Fig. 1), and multiple biopsies of the ulcers were taken. At this point, the patient complained of an enlarged right hemiscrotum suggestive of a testicular tumor in testicular ultrasound. A radical orchiectomy was performed. Histopathologic findings were compatible with a pure testicular seminoma (shown in Fig. 3f), with tunica albuginea and spermatic cord invasion. Revision of both gastric and retroperitoneal biopsies was compatible with metastatic seminoma. Further laboratory study revealed an elevated β -human chorionic gonadotropin (29.4 IU/L, NR: < 0.5) and persistently normal alpha-fetoprotein. With an IIC stage (T3N3M1bS2) [5], the patient underwent chemotherapy with bleomycin, etoposide, and platinum. Because of an incomplete response of the retroperitoneal mass, not resectable due to vascular adhesions, the patient is undergoing radiotherapy. There was no hemorrhagic recurrence.

Discussion/Conclusion

Metastatic involvement of the stomach arising from testicular germ cell tumors is rare and usually detected after the primary tumor is diagnosed [1]. We report a case in which the first presentation was gastrointestinal bleeding arising from gastric metastases. The multiplicity of gastric lesions with mucosal involvement, suggesting a hematogenous route, is an even rarer finding [3].

Contrary to our case, most germ cell tumors with gastric metastasis have a nonseminoma component [6]. There are few reported cases of pure seminoma presenting at diagnosis with gastric metastases, both with and without macroscopic retroperitoneal ganglia involvement [7–9]. Most of these cases report a single gastric metastasis and some are associated with other visceral organ metastases, unlike our patient.

This case highlights the importance of the differential diagnosis of malignant gastric ulcers. The hypothesis of a germ cell tumor should be considered in cases where biopsies reveal a poorly differentiated neoplasm, particularly in young men with severe anemia. In our particular case, since a retroperitoneal mass was diagnosed at admission, a germ cell tumor should have been considered earlier in the diag-

nostic work up. The marked elevation of lactate dehydrogenase was in accordance with this hypothesis. Direct questioning about scrotal swelling, genital examination, dosing of the tumor marker β -human chorionic gonadotropin, and a low threshold for the performance of a testicular ultrasound would have been crucial for a prompt diagnosis. In addition, an early second opinion from a more specialized pathologist would have been appropriate.

A prompt diagnosis is of particular importance in the setting of a testicular seminoma, in which the presence of metastatic disease does not preclude a curative approach. In fact, all seminomas are categorized as having good or intermediate prognosis. In our case, the presence of nonpulmonary visceral metastases warrants an intermediate prognosis, with 88% 5-year survival rate [10]. However, lactate dehydrogenase elevation was recently redefined as an independent adverse prognostic marker [10], and there are insufficient data to predict the outcome in the infrequent scenario of gastric involvement by metastatic disease.

In conclusion, we report a rare initial presentation of testicular seminoma as gastrointestinal bleeding due to gastric metastases, emphasizing one of the unusual manifestations of germ cell malignancies and highlighting the importance of detailed anamnesis and physical examination in the differential diagnosis of atypical gastric ulcers.

Statement of Ethics

All procedures performed were in accordance with both the ethical standards of the Institutional Research Committee and the World Medical Association Declaration of Helsinki. Written informed consent was obtained from the patient for the publication of this case report, including images.

Conflict of Interest Statement

The authors have no conflicts of interest to declare.

Funding Sources

The authors did not receive financial support.

Author Contributions

Analysis of the case and reviewing of the literature: Maria Azevedo Silva, Carina Leal, and André Ruge; drafting of the article: Maria Azevedo Silva; critical revision of the article for important intellectual content: Alexandra Fernandes and Maria Fernanda Cunha; and final approval of the article: Helena Vasconcelos.

References

- 1 De Palma GD, Masone S, Rega M, Simeoli I, Donisi M, Addeo P, et al. Metastatic tumors to the stomach: clinical and endoscopic features. *World J Gastroenterol*. 2006 Dec; 12(45):7326–8.
- 2 Kim GH, Ahn JY, Jung HY, Park YS, Kim MJ, Choi KD, et al. Clinical and endoscopic features of metastatic tumors in the stomach. *Gut Liver*. 2015 Sep;9(5):615–22.
- 3 Green LK. Hematogenous metastases to the stomach. A review of 67 cases. *Cancer*. 1990 Apr;65(7):15962–600.
- 4 Chait MM, Kurtz RC, Hajdu SI. Gastrointestinal tract metastasis in patients with germ-cell tumor of the testis. *Am J Dig Dis*. 1978 Oct;23(10):925–8.
- 5 Amin MB, Edge SB, Greene FL. *AJCC cancer staging manual*. 8th ed. Springer International Publishing; 2017.
- 6 Lauro S, Righini R, Onesti CE, Pucci E, Bramini A, Marchetti P. Gastric metastases from testicular cancer: case report and review of literature. *J Gastrointest Cancer*. 2014 Dec; 45(Suppl 1):22–4.
- 7 Pollheimer VS, Gurakuqi GC, Pollheimer MJ, Beham-Schmid C, Langner C. Testicular seminoma presenting with gastric metastasis. *Gastrointest Endosc*. 2008 Apr;67(4):726–7; discussion 727.
- 8 McLaren A, Baxter MA, Katbeh T, Lynch V, Fullarton G, White J. Metastatic seminoma with isolated gastric metastases: a case report. *Scott Med J*. 2019 Nov;64(4):133–7.
- 9 Yuan R, Zhou C, Meneghetti V, Lavoie JM, Kollmannsberger C, Wang G. Seminoma presenting as a solitary metastasis in gastric mucosa with regressed testicular mass. *Urol Case Rep*. 2020 Dec;29:101083.
- 10 Beyer J, Collette L, Sauvé N, Daugaard G, Feldman DR, Tandstad T, et al. Survival and new prognosticators in metastatic seminoma: results from the IGCCCG-update consortium. *J Clin Oncol*. 2021 May;39(14):1553–62.