

Case Report

Open Access

Melanosis intestini: case report

Anna Batistatou*, John Panelos and Niki J Agnantis

Address: Department of Pathology, University of Ioannina Medical School, Ioannina, Greece

Email: Anna Batistatou* - abatista@cc.uoi.gr; John Panelos - nagnanti@cc.uoi.gr; Niki J Agnantis - nagnanti@cc.uoi.gr

* Corresponding author

Published: 31 March 2006

Received: 26 January 2006

Diagnostic Pathology 2006, 1:3 doi:10.1186/1746-1596-1-3

Accepted: 31 March 2006

This article is available from: <http://www.diagnosticpathology.org/content/1/1/3>

© 2006 Batistatou et al; licensee BioMed Central Ltd.

This is an Open Access article distributed under the terms of the Creative Commons Attribution License (<http://creativecommons.org/licenses/by/2.0>), which permits unrestricted use, distribution, and reproduction in any medium, provided the original work is properly cited.

Abstract

The term melanosis in the gastrointestinal tract refers to the accumulation of pigment deposits in the mucosa. Melanosis of the colon is not uncommon and has been associated with certain conditions, however melanosis of the small intestine is extremely rare. Herein, we describe a case in which we observed melanosis not only in the colon, but in the terminal ileum as well, associated with the use of anthraceneline laxatives. The clinical significance of this condition is not clear, however Gastroenterologists and Pathologists should be aware of its existence.

Background

The term melanosis coli was initially proposed by Virchow [2]. "Melanosis" is a Greek word denoting any condition characterized by abnormal dark coloration of skin or mucosa. Melanosis, by definition, can be due not only to the deposition of melanin, but of other dark-pigmented granules, such as hemosiderin, lipofuskin, lipofuskin-like pigment or ferrum sulfate as well [1,3]. Therefore the recently proposed term "pseudomelanosis", which means a "fake melanosis", and is used for dark colouring of a mucosa due to deposition of pigment other than melanin, is probably not appropriate.

Case presentation

A 74-year-old man presented complaining of abdominal cramps and bloating. He had a long history of constipation and extensive use of anthraceneline laxatives. Endoscopic examination followed with no remarkable findings and multiple biopsies were taken and sent to the Pathology laboratory for histological evaluation. On microscopic examination, abundant pigment-containing macrophages were noted at the lamina propria of the colon biopsies (Figure 1). Interestingly similar macrophages were seen in the lamina propria of the terminal

ileum, particularly at the tips of the villi (Figure 2). Prussian blue stain was negative, indicating that the pigment

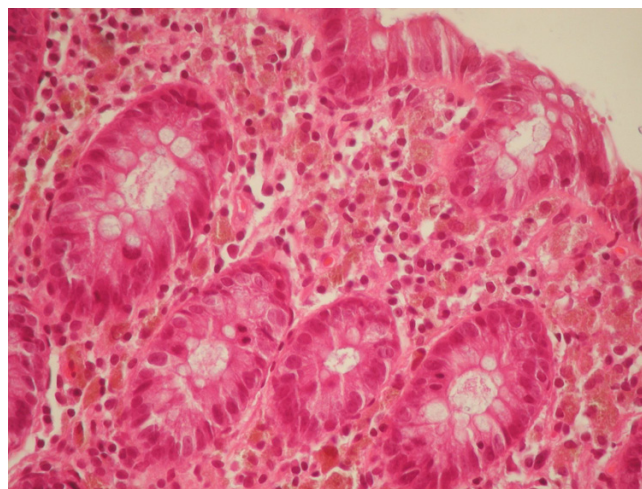


Figure 1
Colonic mucosa. Note the abundant pigment-containing macrophages in the lamina propria (haematoxylin and eosin stain, X400).

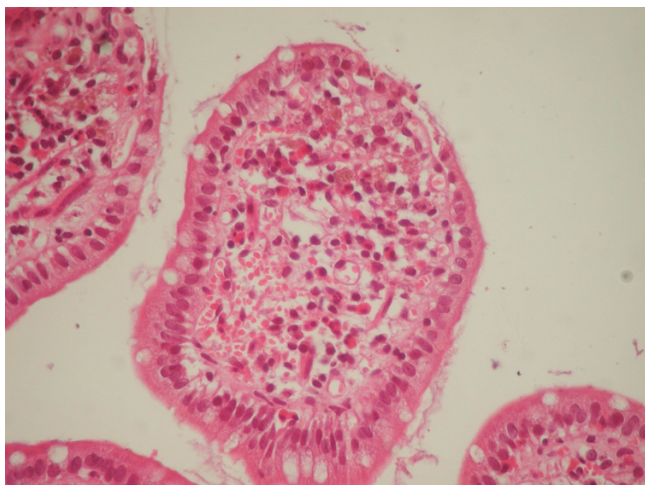


Figure 2
Ileal mucosa. There are fewer, but conspicuous pigment containing macrophages in the lamina propria, particularly at the tips of the villi (haematoxylin and eosin stain, X400).

was not haemosiderin. In addition, the cytoplasm of the pigment-laden macrophages was weakly positive to Periodic Acid-Schiff stain (PAS), but the pigment granules were negative. Based on the histological findings, the diagnosis of melanosin coli was made [3]. A note was added commenting on the appearance of the same findings in the terminal ileum.

Discussion

Melanosin of the colon is not uncommon and has been associated with the ingestion of anthraceneline laxatives, although it can be observed in patients without such history [3]. Melanosin of the small intestine is an extremely rare finding with only a few cases described in the literature [1,2,4]. Melanosin of the duodenum has been associated with several conditions such as chronic renal failure, gastrointestinal bleeding, ingestion of drugs, or folic acid deficiency [1,2]. There is only one reported case of melanosin of the jejunum, possibly due to ferrous-sulfate administration and vitamin deficiencies [2], and very few cases of melanosin in the ileum [2,4]. In the majority of these cases, the pigment was characterized as hemosiderin and/or lipofuscin. In our case the location and morphological characteristics of the pigment were identical in the ileum and the colon, and presumably were due to the long-term ingestion of anthraceneline. The clinical significance of this condition is not clear, however Gastroenterologists and Pathologists should be aware of its existence.

Competing interests

The author(s) declare that they have no competing interests.

Authors' contributions

AB, JP and NJA have been involved in conceiving the manuscript. AB and JP have been involved in the literature search and in drafting the manuscript. All authors read and approved the final manuscript.

References

1. Banai J, Fenyvesi A, Gonda G, Petö I: **Melanosin jejunum**. *Gastrointestinal Endoscopy* 1997, **45**:834-840.
2. Ghadially FN, Walley VM: **Melanosin of the gastrointestinal tract**. *Histopathology* 1994, **25**:197-207.
3. Rosai J: *Rosai and Ackerman's Surgical Pathology* 9th edition. Mosby, New York; 2004.
4. Won KH, Ramchand S: **Melanosin of the ileum**. *Am J Dig Dis* 1970, **15**:57.

Publish with **BioMed Central** and every scientist can read your work free of charge

"BioMed Central will be the most significant development for disseminating the results of biomedical research in our lifetime."

Sir Paul Nurse, Cancer Research UK

Your research papers will be:

- available free of charge to the entire biomedical community
- peer reviewed and published immediately upon acceptance
- cited in PubMed and archived on PubMed Central
- yours — you keep the copyright

Submit your manuscript here:
http://www.biomedcentral.com/info/publishing_adv.asp

