

Correspondence

Uraemia-associated cardiovascular and lung injury

Sir,

Dr Yuan recently reported the interesting case of a 23-year-old dialysis patient with extensive calcifications, including lung calcifications [1]. We similarly encountered a young patient who had developed severe lung calcifications, which proved reversible after intensifying the dialysis regimen and optimization of the calcium–phosphate regulation.

This patient is a 29-year-old woman with a history of end-stage renal disease (ESRD) due to primary focal segmental glomerulosclerosis. She had recently started haemodialysis three times weekly for 3 h via a central venous catheter. Because of progressive dyspnoea, a chest X-ray was performed which showed extensive nodular opacities in both lungs (Figure 1A). Chest computed tomography revealed ground-glass nodules with a centrilobular distribution and consolidations with a heterogeneous aspect suggestive of calcium deposition (Figure 2). In the clinical context of ESRD, severely deregulated calcium–phosphate homeostasis (serum phosphorus 3.55 mmol/L (11.0 mg/dL); parathyroid hormone 170 pmol/L (1600 pg/mL)) and after exclusion of other plausible explanations, these lesions were considered ESRD-related lung calcifications.

We therefore increased the dialysis dose by multiple interventions and improved calcium–phosphate homeostasis. Dialysis duration and frequency were increased to 4 h, four times weekly. Furthermore, an arteriovenous fistula was created and low-flux haemodialysis was changed to haemodiafiltration. In addition, her calcium–phosphate regulation was optimized by medication and compliance counselling. In the next year, her weekly K_t/V increased from 3.45 to

9.3 and her calcium–phosphate regulation improved. The dyspnoea disappeared and the chest X-ray showed a significant reduction in pulmonary calcifications (Figure 1B).

Lung calcification is a frequent complication of ESRD, found at postmortem examination in up to 80% of the

patients with ESRD [2]. Pulmonary calcifications can be divided into metastatic pulmonary calcifications (MPC), dystrophic calcifications and calcific uraemic arteriopathy (CUA). Dystrophic calcification refers to hydroxyapatite crystal formation in previously damaged tissue and is not specifically associated with ESRD. CUA, also known as calciphylaxis, involves hydroxyapatite crystal formation in small vessels which results in tissue ischaemia and necrosis in reaction to tissue damage or inflammation. In contrast, MPC manifests without ischaemic or necrotic changes, consists of amorphous whitlockite instead of hydroxyapatite, and is not related to an inciting event [2–4]. Both CUA and MPC are well-known complications of ESRD. Although the chest computed tomography pictures suspected of MPC, we could not rule out the co-existence of CUA.

Therapy for both CUA and MPC includes optimization of the calcium–phosphate regulation and increasing dialysis doses [4]. Although the reports on reversible lung calcifications are limited, our case demonstrates the potential reversibility of pulmonary calcifications by improving dialysis and drug treatment.

Conflict of interest statement. None declared.

Department of Nephrology and Hypertension, UMC Utrecht, Utrecht, Netherlands

Femke M. Molenaar
Maarten B. Rookmaaker
Alferso C. Abrahams

Correspondence and offprint requests to: Femke Molenaar;
E-mail: f.m.molenaar@umcutrecht.nl

References

1. Yuan Z, Li W, Ye X. Uremia-associated cardiovascular and lung injury. *Clin Kidney J* 2012; 5: 281–282
2. Bernard B, McFarlane P, Moid F *et al.* Pulmonary vascular calcification in a nocturnal hemodialysis patient. *Clin Nephrol* 2012; 77: 231–236

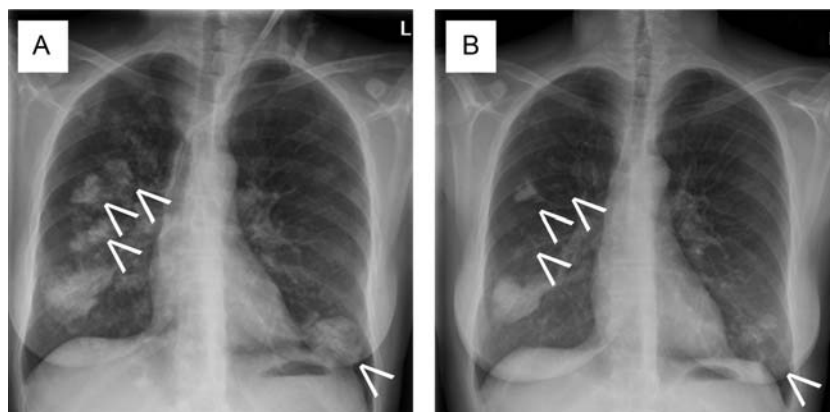


Fig. 1. Chest X-rays. Diffuse nodular opacities can be seen in both lungs (A; arrows). One year after intensifying the dialysis regimen and optimization of the calcium–phosphate regulation, a significant reduction of the opacities can be seen (B).

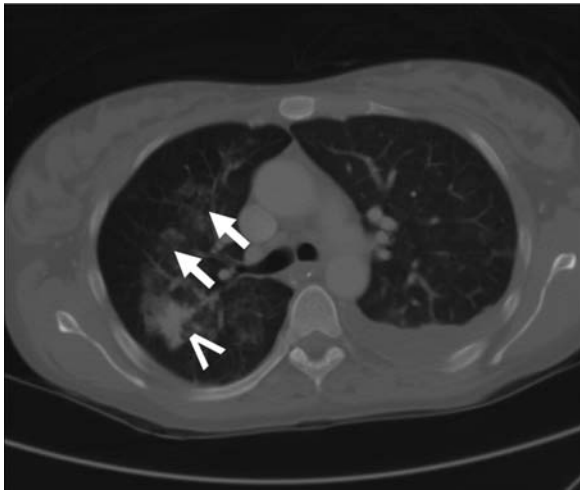


Fig. 2. Chest computed tomography shows centrilobular ground-glass nodules (arrows) and consolidations with a heterogeneous aspect (open arrows).

3. Li YJ, Tian YC, Chen YC *et al.* Fulminant pulmonary calciphylaxis and metastatic calcification causing acute respiratory failure in a uremic patient. *Am J Kidney Dis* 2006; 47: e47–e53
4. Eggert CH, Albright RC. Metastatic pulmonary calcification in a dialysis patient: case report and a review. *Hemodial Int* 2006; 10 (Suppl 2): S51–S55

doi: 10.1093/ckj/sfs093

Reply

We thank Molenaar *et al.* for their interest in our article. We also reported an interesting case of uraemia-associated cardiovascular and lung injury. However, the current materials do not convince me of regression of pulmonary calcification after intensification of haemodialysis treatment.

Numerous complications related to the respiratory system occur in patients with chronic renal disease, such as pulmonary oedema, tuberculosis, pulmonary calcification, pulmonary embolism and so on.

Pulmonary calcification can usually be detected with computed tomography, most often demonstrating small nodular opacities with hyper-attenuation and sharp edge, which may coalesce into larger infiltrates. In this case, however, the chest CT image shows centrilobular ground-glass nodules (GGNs) which disappeared after one year by intensifying the dialysis regimen. Why do you diagnose these GGNs as calcification, and not other pulmonary disorders, such as pulmonary oedema?

Conflict of interest statement. None declared.

Department of Radiology, Fudan University
Shanghai Cancer Center, Shanghai, People's
Republic of China Yuan Zheng

Correspondence and offprint requests to: Z. Yuan;
E-mail: Yuanzheng0404@163.com

doi: 10.1093/ckj/sfs094