


## CASE REPORT

# Primary cardiac angiosarcoma directly invading the right lung: An autopsy report

Takumi Kiwaki<sup>1</sup>  | Akira Ishihara<sup>2,3</sup> | Takanori Toyama<sup>4</sup> | Hiroaki Kusaka<sup>5</sup> | Hiroaki Kataoka<sup>1</sup>

<sup>1</sup>Section of Oncopathology and Regenerative Biology, Department of Pathology, Faculty of Medicine, University of Miyazaki, Miyazaki, Japan

<sup>2</sup>Department of Pathology, Miyazaki Prefectural Nobeoka Hospital, Nobeoka, Japan

<sup>3</sup>Department of Pathology, Junwakai Memorial Hospital, Miyazaki, Japan

<sup>4</sup>Department of Internal Medicine, Miyazaki Prefectural Nobeoka Hospital, Nobeoka, Japan

<sup>5</sup>Department of Cardiovascular Medicine, Miyazaki Prefectural Nobeoka Hospital, Nobeoka, Japan

## Correspondence

Takumi Kiwaki, Section of Oncopathology and Regenerative Biology, Department of Pathology, Faculty of Medicine, University of Miyazaki, 5200, Kihara, Kiyotake, Miyazaki 889-1692, Japan.  
Email: takumi\_kiwaki@med.miyazaki-u.ac.jp

## Funding information

No funding to declare

## Abstract

We presented a difficult-to-diagnose case of cardiac angiosarcoma. The patient presented pericardial effusion, but cytology of the effusion was negative. Because cytological detection of angiosarcoma cells is difficult, a possibility of malignancy should not be excluded with negative cytological examination. Biopsy of cardiac mass is the best way for diagnosis.

## KEYWORDS

angiosarcoma, autopsy, cardiac malignancy, cardiac tumor, primary cardiac angiosarcoma

## 1 | INTRODUCTION

Tumors of the heart are rare, the majority of which are metastatic tumors.<sup>1</sup> Primary cardiac tumors are extremely rare, accounting for only 0.0017%–0.19% of unselected patients at autopsy.<sup>2</sup> Seventy-five percent of them are benign neoplasms and the remainders malignant. Myxomas are by far the most common benign cardiac tumors.<sup>3</sup> As for malignant tumors arising primarily in the heart, angiosarcomas are one of the most common types.<sup>4,5</sup> Primary cardiac angiosarcoma (PCA) originates

in vascular endothelial cells and commonly arises in the right atrial wall.<sup>5,6</sup> It exhibits a poor prognosis despite surgical treatment, chemotherapy, and radiotherapy.<sup>1</sup> Here, we present a case of PCA that was diagnosed for the first time at autopsy.

## 2 | CASE REPORT

A 60-year-old previously healthy Japanese man was referred to our hospital for evaluation of anemia and pericardial

This is an open access article under the terms of the Creative Commons Attribution-NonCommercial-NoDerivs License, which permits use and distribution in any medium, provided the original work is properly cited, the use is non-commercial and no modifications or adaptations are made.

© 2021 The Authors. *Clinical Case Reports* published by John Wiley & Sons Ltd.

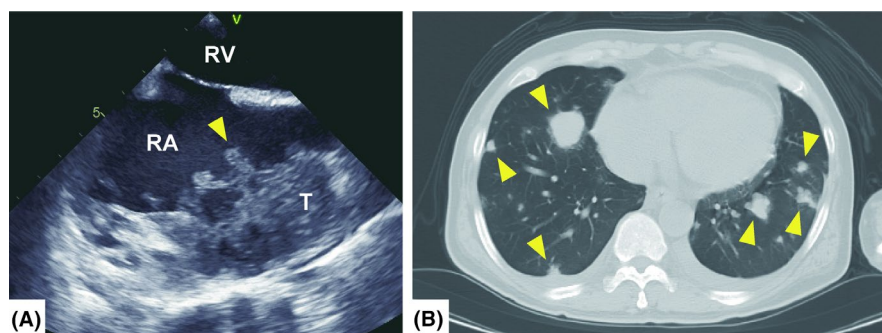
effusion 13 months before his death. The patient presented with no apparent symptoms at that time. No apparent tumor lesion was detectable with echocardiography and computed tomography (CT). Pericardiocentesis was performed, and 1500 ml of sanguineous pericardial effusion was obtained. Cytological evaluation of the effusion demonstrated lymphoplasmacytic and histiocytic infiltration and existence of mesothelial cells; however, no atypical cells could be identified, and the etiology of the effusion was undefined. The patient ignored follow-up visit appointments, but returned 6 months later to the hospital with dyspnea, bloody sputum, edema, and anorexia. He was hospitalized for diagnosis and treatment. A blood examination showed severe anemia (red blood cells,  $1.64 \times 10^6/\mu\text{l}$ ; hemoglobin, 3.3 g/dl), and transesophageal echocardiography revealed a  $1.5 \times 1$  cm-sized mass in the right atrium (Figure 1A). Tumor markers ( $\alpha$ -fetoprotein, carcinoembryonic antigen, carbohydrate antigen 19–9, protein induced by vitamin K absence of antagonist-II, cytokeratin 19 fragment, pro-gastrin releasing peptide, and soluble interleukin-2 receptor) were within normal ranges. CT disclosed multiple nodules in the lungs (Figure 1B) and the liver. A transbronchial biopsy of the lung mass was performed, but the biopsied specimen did not contain any atypical cells. Biopsy of the cardiac mass was not performed. Hematological malignancies were suspected because of progressive anemia and the presence of human T-cell leukemia virus type 1 antibodies. The patient was treated with THP-COP (pirarubicin, cyclophosphamide, vincristine, and prednisolone) and mogamulizumab under the provisional diagnosis of adult T-cell leukemia/lymphoma. Nevertheless, the patient's general condition worsened progressively. The anemia and edema continued to progress, and the pleural effusion increased. The patient died of respiratory failure 13 months after his initial admission to the hospital.

The patient was autopsied 8 hours after his death. The heart adhered to the pericardium (Figure 2A), and the pericardial cavity contained 130 ml of sanguineous pericardial effusion. In the right atrium, a dark red colored, approximately  $7 \times 4$ -cm-sized multilobulated tumor arose from the

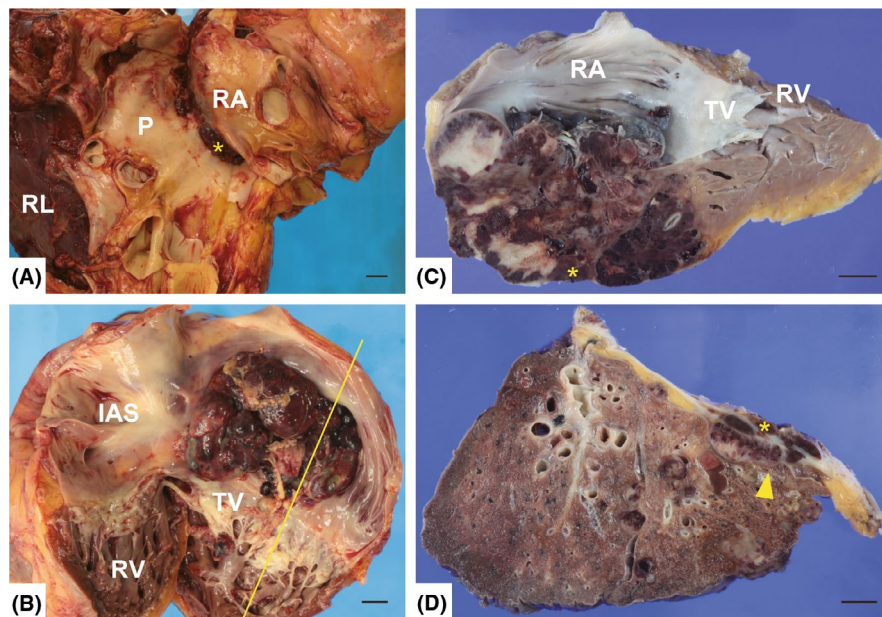
atrial wall and filled the dilated atrial lumen (Figure 2B). The cut surface of the tumor was sanguineous and solid, intermingled with necrotized and calcified foci (Figure 2C). The muscular layer of the right atrial wall was completely replaced by the tumor. The tumor penetrated the pericardium and directly invaded the right lung (Figure 2D). Histologically, the tumor consisted of atypical cells with oval- to spindle-shaped nuclei, which formed vague capillary channels containing red blood cells (Figure 3A). Tumor cells protruded into the atrial cavity, forming papillary structures (Figure 3B). Exfoliated clusters of tumor cells were also observed in the atrium. The tumor cells were immunoreactive for vimentin, CD31 (Figure 3C), and FLI1 (Figure 3D) but were negative for podoplanin (D2-40 antibody). The Ki-67 labeling index of the tumor cells was 7.4%. Therefore, we diagnosed the lesion as an angiosarcoma. Although several abnormalities of *MYC*, *CIC*, *PTPRB*, *PLCG1*, and *ROSI-GOPC/FIG* have been identified in angiosarcoma,<sup>7,8</sup> we could not perform genetic screening of this tumor. The tumor cells penetrated the pericardium and visceral pleura of the right lung and directly invaded the pulmonary parenchyma. Multiple metastases were identified in the lungs, liver, spleen, jejunum, and skin. In the jejunum, the metastatic nodule resulted in intussusception. In the bilateral lungs, tumor emboli were formed in the pulmonary arteries, and intra-alveolar hemorrhage and bronchopneumonia were present. The central nervous system was not examined.

### 3 | DISCUSSION

Making diagnoses of cardiac tumors is sometimes difficult because of its extremely low incidence. The differential diagnosis of cardiac tumors includes many types of primary cardiac tumors such as myxoma, rhabdomyoma, fibroma, angiosarcoma, rhabdomyosarcoma, and lymphoma.<sup>3</sup> For diagnosis, echocardiography, cardiac CT, magnetic resonance imaging, and fluorodeoxyglucose-positron emission tomography are known as useful imaging modalities.<sup>9</sup> Surgical biopsy of cardiac masses or metastatic lesion is also meaningful to



**FIGURE 1** A, Transesophageal echocardiogram of the heart tumor. A  $1.5 \times 1$  cm-sized mass was observed in the right atrium. A papillary structure was also discovered (yellow arrowhead). T, tumor; RA, right atrium; RV, right ventricle. B, Chest CT. Multiple nodules suggesting metastases were observed in the bilateral lungs (yellow arrowheads)



**FIGURE 2** Macroscopic examination of the autopsy. A, The heart adhered to the pericardium. The right atrial tumor was connected to the pericardium (yellow asterisk). RA, right atrium; RL, right lung; P, pericardium. B, A dark red colored tumor was observed in the right atrium. The specimen was cut along the yellow line. IAS, interatrial septum; TV, tricuspid valve; RV, right ventricle. C, Cut surface of the heart tumor. D, Cut surface of the right lung. The tumor invaded the pleura and the lung parenchyma. The visceral pleura was penetrated by the tumor cells in the yellow arrowhead portion. Multiple metastases were also identified. Portions indicated by yellow asterisks of Figure 2C,D are connected to each other, and the portions correspond to the yellow asterisks in Figure 2A. Bars, 1 cm

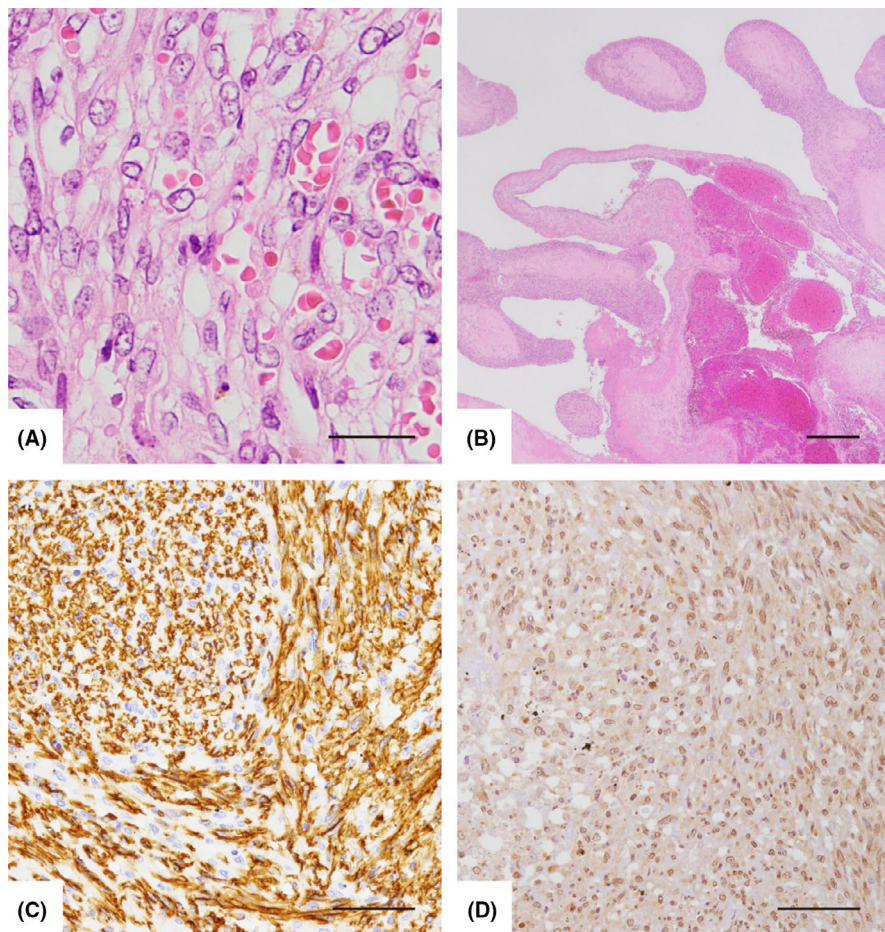
establish pathological diagnosis of cardiac tumors. Whereas we were unable to perform histological examination because of poor patient's general condition, we want to emphasize that cardiac or pericardial biopsy is the best way to make diagnosis of PCA. Since pericardial effusion is a part of common symptoms of PCA patients, cytology of the pericardial effusion might be an important tool for the diagnosis of PCA. However, as seen in our patient, the detection of angiosarcoma cells is difficult with pericardial fluid cytology. Indeed, Kupsky et al<sup>10</sup> reported that pericardial fluid cytology could not detect malignant cells in all PCA cases (15 cases) who underwent pericardiocentesis. Hence, when one encounters a patient with unexplained pericardial effusion, the possibility of malignancies including PCA should not be excluded, even with a “negative” result of the pericardial effusion cytology.

Given the low frequency of PCA and a relatively higher incidence of metastatic cardiac tumor, diagnosis of cardiac angiosarcoma as the primary lesion is sometimes challenging. In the current case, we encountered this difficulty as the patient had multiple tumor nodules in the liver, spleen, and skin. Besides the heart, angiosarcomas can arise in the soft tissue, breast, liver, bone, spleen, or other visceral organs.<sup>11</sup> Furthermore, the incidence of angiosarcoma in the cutaneous soft tissue, liver, or spleen is higher than that in the heart.<sup>11</sup> In this regard, Cunha-Silva et al<sup>12</sup> suggested the following factors to evaluate whether the cardiac angiosarcoma is primary or not: (1) patient's age and lifestyle history, (2) number of lesions (ie, single or multiple) in the heart, and (3) location of

the lesion in the heart. In addition, while cardiac metastasis of liver angiosarcoma is rare, the liver is a common metastatic site of PCA.<sup>12</sup> In the current case, the patient had no history of exposure to thorium oxide, vinyl chloride, arsenic, or anabolic steroids, all of which are risk factors for hepatic angiosarcoma. Moreover, the cardiac lesion was single, and the hepatic lesions were multiple. The cardiac lesion located in the right atrium, the most common site for PCA. These findings strongly suggest that the cardiac angiosarcoma in this case was PCA, though the diagnosis of primary localization of angiosarcoma may still be debatable. Since there is no direct evidence indicating the cardiac angiosarcoma is primary lesion, we had to establish diagnosis using above mentioned rejection method and this is a limitation of this case report.

Pericardial extension of the tumor was observed in 71% of 17 cases of PCA,<sup>10</sup> and cardiac rupture due to PCA has also been reported.<sup>13</sup> However, to the best of our knowledge, a case of PCA with direct lung invasion has not been described previously. In the current case, the tumor penetrated the pericardium and invaded the lung. However, neither fatal cardiac tamponade nor rupture occurred in this case. Although the incidence of lung invasion may be low, it may be meaningful for the clinical management of PCA to recognize the possibility of lung invasion.

Prognosis of PCA is still not favorable and there is little progress regarding treatment of PCA in recent years, because of its rarity. If the tumor is localized, surgical resection is



**FIGURE 3** Histological and immunohistochemical findings of the autopsy specimen. A, and B, H&E staining of the heart tumor. A, Atypical tumor cells with vascular formation were observed. Bar, 50  $\mu$ m B, The tumor cells with a papillary structure protruded into the atrial cavity. Bar, 1 mm C, CD31 and D, FLI1 immunostaining revealed vascular differentiation of the tumor cells. Bar, 100  $\mu$ m

the most effective treatment for PCA.<sup>14</sup> Chemotherapy and radiation therapy are the alternative options. Chemotherapy regimen containing doxorubicin and ifosfamide has been commonly utilized, and anthracycline-containing regimen has been also used.<sup>15</sup> Tyrosine kinase inhibitors, which inhibit vascular endothelial growth factor signaling pathway, are reported to be useful for angiosarcoma therapy<sup>16</sup>; however, further research is still required for the improvement of PCA therapy.

In conclusion, we presented an autopsy case of PCA that directly invaded the right lung. Although PCA is an extremely rare disease, it should be included in the differential diagnosis of a cardiac mass with pericardial effusion.

#### ACKNOWLEDGEMENTS

None.

#### CONFLICT OF INTEREST

None declared.

#### AUTHOR CONTRIBUTIONS

TK performed autopsy and drafted the manuscript. AI performed autopsy and edited the manuscript. TT and H Kusaka treated the patient and reviewed the manuscript. H Kataoka supervised autopsy diagnosis and manuscript preparation.

#### ETHICAL APPROVAL

This study was conducted in accordance with the Declaration of Helsinki of 1975. Written informed consent was obtained from the patient's family.

#### DATA AVAILABILITY STATEMENT

The data that support the findings of this study are available from the corresponding author upon reasonable request.

#### ORCID

Takumi Kiwaki  <https://orcid.org/0000-0002-6931-8055>

#### REFERENCES

1. Butany J, Nair V, Naseemuddin A, Nair GM, Catton C, Yau T. Cardiac tumours: diagnosis and management. *Lancet Oncol*. 2005;6(4):219-228.
2. Reynen K. Cardiac myxomas. *N Engl J Med*. 1995;333(24):1610-1617.
3. Silverman NA. Primary cardiac tumors. *Ann Surg*. 1980;191(2):127-138.
4. Chen TW, Loong HH, Srikanthan A, et al. Primary cardiac sarcomas: a multi-national retrospective review. *Cancer Med*. 2018;8(1):104-110.
5. Neuville A, Collin F, Bruneval P, et al. Intimal sarcoma is the most frequent primary cardiac sarcoma: clinicopathologic and molecular retrospective analysis of 100 primary cardiac sarcomas. *Am J Surg Pathol*. 2014;38(4):461-469.

6. Leduc C, Jenkins SM, Sukov WR, Rustin JG, Maleszewski JJ. Cardiac angiosarcoma: histopathologic, immunohistochemical, and cytogenetic analysis of 10 cases. *Hum Pathol*. 2017;60:199-207.
7. Habeeb O, Rubin BP. The molecular diagnostics of vascular neoplasms. *Surg Pathol Clin*. 2019;12(1):35-49.
8. Marks EI, Pamarthy S, Dizon D, et al. ROS1-GOPC/FIG: a novel gene fusion in hepatic angiosarcoma. *Oncotarget*. 2019;10(2):245-251.
9. Joshi M, Kumar S, Noshirwani A, Harky A. The current management of cardiac tumours: a comprehensive literature review. *Braz J Cardiovasc Surg*. 2020;35(5):770-780.
10. Kupsky DF, Newman DB, Kumar G, Maleszewski JJ, Edwards WD, Klarich KW. Echocardiographic features of cardiac angiosarcomas: the mayo clinic experience (1976–2013). *Echocardiogr Mt Kisco N*. 2016;33(2):186-192.
11. Young RJ, Brown NJ, Reed MW, Hughes D, Woll PJ. Angiosarcoma. *Lancet Oncol*. 2010;11(10):983-991.
12. Cunha-Silva M, de Mazo DFC, Gomes ILC, et al. Multiple hepatic metastases of cardiac angiosarcoma. *Autopsy Case Rep*. 2018;8(4):e2018048.
13. Kim J, Da Nam B, Hwang JH, et al. Primary cardiac angiosarcoma with right atrial wall rupture. *Medicine*. 2019;98(14):e15020.
14. Bobby Y, Amine M, Edward YC, et al. Surgery for tumors of the heart. *Semin Thorac Cardiovasc Surg*. 2018;30(4):385-397.
15. Brittany LS, Monika L, Rashmi C. Current clinical management of primary cardiac sarcoma. *Expert Rev Anticancer Ther*. 2020;20(1):45-51.
16. Jun C, Jiale W, Chiyu H, Meiyu F. Angiosarcoma: a review of diagnosis and current treatment. *Am J Cancer Res*. 2019;9(11):2303-2313.

**How to cite this article:** Kiwaki T, Ishihara A, Toyama T, Kusaka H, Kataoka H. Primary cardiac angiosarcoma directly invading the right lung: An autopsy report. *Clin Case Rep*. 2021;9:e04582. <https://doi.org/10.1002/ccr3.4582>