

Bone Morphogenetic Protein in the Repair of Cerebrospinal Fluid Leak after Transsphenoidal Surgery

Abstract

Background: Recurrent cerebrospinal fluid (CSF) leak carries significant morbidity. We sought to demonstrate that bone morphogenetic protein (BMP) use is effective and safe for the repair of recurrent CSF leak after a transsphenoidal pituitary tumor resection (TSPTR). **Materials and Methods:** We reviewed charts and radiographic data of consecutive patients who underwent BMP repair of recurrent CSF leak after TSPTR from January 2010 to June 2015 and who failed previous multilayer closure. We detailed the technique for constructing and placing a BMP-DuraGen patch for the repair. The primary variables include postoperative computed tomography/magnetic resonance imaging (CT/MRI) evidence of ectopic bone growth or inflammation, newly diagnosed systemic neoplasm within 1 year, and recurrent CSF leak. Secondary outcome is the length of stay after BMP repair. All patients were followed up radiographically and through phone interview. **Results:** Four patients underwent BMP repair of recurrent CSF leak after TSPTR. The average postoperative CT/MRI interval was 22 months. Postoperative CT/MRI revealed no ectopic bone formation or inflammatory changes around the site of BMP application. There was no recurrence of CSF leak or newly diagnosed neoplasm from both chart review and phone interview. **Conclusions:** We demonstrate that the use of BMP is a safe and an effective treatment in the repair of recurrent CSF leaks after TSPTR.

Keywords: Bone morphogenetic protein, recurrent cerebrospinal fluid leak, pituitary, transsphenoidal

Introduction

Cerebrospinal fluid (CSF) leak carries a significant morbidity and mortality risk. One of the most serious consequences associated with an unrepaired CSF leak is the development of meningitis with some reporting an incidence of 19%.^[1,2] Often, a CSF leak complicates an endonasal transsphenoidal surgery for a pituitary mass resection which has become a common neurosurgical approach.^[3] The incidence of CSF leak ranges anywhere from 1.5% to 4.2% and is caused by a tear in the arachnoid membrane.^[4] Most CSF leaks heal within 7–10 days with conservative treatment including bed rest and reduction of activities that increase intracranial pressure (ICP) such as sneezing, coughing, or any other type of straining.^[4] Placement of a lumbar drain can be used to further decrease ICP and diminish the CSF flow pressure at the surgical site. In cases where such treatments fail, more

aggressive measures may be necessary to accomplish repair.

Various methods have been described to repair a CSF leak following endonasal transsphenoidal surgery without a unanimously accepted technique.^[5] When a surgeon encounters a CSF leak during the transsphenoidal operation, it is recommended that an attempt is made to repair it. This is commonly done by placing a free flap, such as a fascia lata or an abdominal fat graft with a lumbar drain. This technique works well in small CSF leaks. More recent techniques such as creating vascularized endonasal flaps have been developed and are applied in high-flow CSF leaks; however, this technique may not be appropriate for patients who underwent previous nasal surgery and is no more effective than standard graft repair in defects <1 cm.^[6,7]

Bone morphogenetic proteins (BMPs) belong to a superfamily of proteins known

Dejan Slavnic¹,
Richard Floyd Cook¹,
Matthew Bahoura²,
Gijong Paik²,
Doris WL Tong^{1,2},
Clifford M.
Houseman^{1,2},
Ryan J. Barrett^{1,2},
Teck-Mun Soo^{1,2}

¹Department of Surgery,
Providence-Providence Park
Hospitals, College of Human
Medicine, Michigan State
University, East Lansing,
²Michigan Spine and Brain
Surgeons, Providence-
Providence Park Hospitals,
Southfield, Michigan, USA

Address for correspondence:
Dr. Dejan Slavnic,
16001 West 9 Mile Road,
Southfield, MI 48075, USA.
E-mail: dejanslavnic82@gmail.
com

Access this article online

Website: www.asianjns.org

DOI: 10.4103/ajns.AJNS_130_18

Quick Response Code:



How to cite this article: Slavnic D, Cook RF, Bahoura M, Paik G, Tong DW, Houseman CM, et al. Bone morphogenetic protein in the repair of cerebrospinal fluid leak after transsphenoidal surgery. Asian J Neurosurg 2019;14:607-11.

This is an open access journal, and articles are distributed under the terms of the Creative Commons Attribution-NonCommercial-ShareAlike 4.0 License, which allows others to remix, tweak, and build upon the work non-commercially, as long as appropriate credit is given and the new creations are licensed under the identical terms.

For reprints contact: reprints@medknow.com

as transforming growth factor.^[8] Their osteogenesis function was first discovered in the 1960s. Since then, BMPs were associated with complications such as ectopic bone growth, osteolysis, and systemic neoplasms.^[9,10] In clinical studies, the application of BMP demonstrated consistent osteoinduction which resulted in the “off-label” use of BMP in more than 85% of various spinal fusions.^[11-14] Huang *et al.* were able to show that recombinant human BMP (rhBMP)-2 created an increased inflammatory state in histological tissue sections and systemic blood samples of rats who had subcutaneously implanted BMP.^[15] We postulate that these proinflammatory properties of BMP lead to increased healing rates by scarring and closure of the CSF fistula.

Our institution has a significant focus on spine and over the years, on many occasions, we have successfully repaired complicated recurrent spinal CSF leaks with a BMP construct similar to what we described in this article.^[16] We extrapolate that BMP can be used to safely repair recurrent complicated CSF leaks after endonasal transsphenoidal surgery for pituitary mass resection when there is failure to control the leak with standard techniques. To the best of our knowledge, there have been no articles published on the use of BMP for CSF leak repair.

Materials and Methods

After obtaining approval from the Institutional Review Board, we reviewed clinical and radiographic data of consecutive patients who underwent BMP repair for recurrent CSF leak during January 2010 to June 2015. All patients in the study failed previous multilayer closure attempts. Radiographic and electronic medical records from the primary hospital, the private clinic, and regional hospitals were reviewed. No patient was excluded from the study. All postoperative computed tomography/magnetic resonance imaging (CT/MRI) of the brain and postoperative clinic visit notes were reviewed. Patients were also contacted by phone to confirm the absence of any subsequent neoplasm or abnormal nasal discharge.

Primary outcome variables we included were postoperative CT/MRI evidence of ectopic bone growth or inflammation, newly diagnosed systemic neoplasm within 1 year, and recurrence of CSF leak. Secondary outcome collected is the length of stay (LOS) after the BMP repair. The patients were followed periodically and underwent imaging studies after the BMP CSF repair.

Surgical technique and clinical management

Using either the operating microscope or the endoscope, the origin of the CSF leak was identified. The dura was reconstructed with a layer of 0.5–1 cm square of DuraGen that was placed inside the sella and rested on the edges of the bony and dural defects. Then, the absorbable collagen

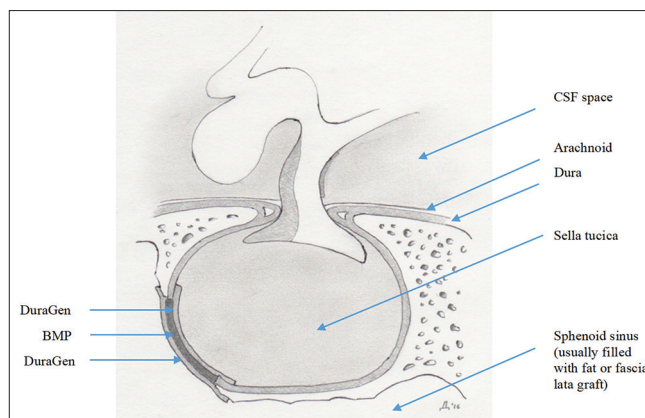


Figure 1: Placement of DuraGen-bone morphogenetic protein-DuraGen “sandwich” for recurrent cerebrospinal fluid leak

sponge in the extra-extra small BMP kit (part number 7510050, 0.7 cc) was soaked with 1.05 mg rhBMP-2 and cut in half before it was inserted on top of the DuraGen followed by placement of another layer of DuraGen to form a “sandwich” [Figure 1]. The sphenoid sinus was then filled with either fat or fascia lata graft, and finally, either DuraSeal or Tisseel were applied to close the opening in the sphenoid sinus. A lumbar drain was used in each case.

Results

Three females and one male for a total of four patients underwent BMP repair of recurrent CSF leak after transsphenoidal pituitary resection of macroadenomas [Table 1]. Patients’ age ranged from 38 to 83. All patients underwent at least two multilayer CSF repair attempts with an average of three attempts per patient [Table 2]. All patients underwent standard approach for the pituitary tumor resection. None of the patients suffered from hydrocephalus or endocrinal imbalance before the tumor resection. The surgical indication for all patients was visual disturbances.

The average number of days with the lumbar drain *in situ* before and after the definitive BMP repair was 3.5 days and 6 days, respectively [Table 3]. The LOS after the repair ranged from 11 to 12 days. No patient developed complications such as meningitis from the use of lumbar drain [Table 4]. Long-term follow-up was conducted and described in Table 5. Postoperative CT/MRI revealed no ectopic bone formation or inflammatory changes around the site of BMP application. There was no recurrence of CSF leak or newly diagnosed neoplasm from both chart review and phone interview.

Discussion

Since the advent of the endonasal transsphenoidal approach for the pituitary surgery, the morbidity and mortality have been significantly reduced.^[17] One of the more common complications with this technique is

Table 1: Patient and procedure characteristics

| | Age | Gender | Size of mass | Resection approach | Standard or extended approach | Surgical indication |
|--------|-----|--------|-----------------|-----------------------------|-------------------------------|---------------------|
| Case 1 | 38 | Female | 2.8 cm × 2.6 cm | Microscopic transsphenoidal | Standard | Visual disturbance |
| Case 2 | 58 | Female | 4 cm × 3 cm | Microscopic transsphenoidal | Standard | Visual disturbance |
| Case 3 | 83 | Male | 2.1 cm × 2 cm | Endoscopic transsphenoidal | Standard | Visual disturbance |
| Case 4 | 59 | Female | 1.2 cm × 0.8 cm | Microscopic transsphenoidal | Standard | Visual disturbance |

Table 2: Cerebrospinal fluid repair - approach and materials

| | Repair 1 | | Repair 2 | | Repair 3 | | Repair 4 | |
|--------|-----------------------------|------------------------------|-----------------------------|--|-----------------------------|---|-----------------------------|---|
| | Approach | Materials | Approach | Materials | Approach | Materials | Approach | Materials |
| Case 1 | Microscopic transsphenoidal | DuraGen, bone, DuraSeal | Lumbar drain placement | | Microscopic transsphenoidal | DuraGen, abdominal fat graft, Tisseel | Microscopic transsphenoidal | Fascia lata graft, fat graft, BMP, DuraGen, Tisseel |
| Case 2 | Microscopic transsphenoidal | DuraGen, cartilage, DuraSeal | Endoscopic transsphenoidal | Abdominal fat graft, cartilage, DuraSeal | Endoscopic transsphenoidal | Abdominal fat graft, Surgicel, DuraSeal | Microscopic transsphenoidal | Abdominal fat graft, BMP, DuraGen |
| Case 3 | Endoscopic transsphenoidal | DuraGen, Evicel | Endoscopic transsphenoidal | DuraSeal, BMP, DuraGen | | | | |
| Case 4 | Microscopic transsphenoidal | DuraGen, DuraSeal | Microscopic transsphenoidal | DuraSeal, BMP, DuraGen | | | | |

BMP – Bone morphogenetic protein

Table 3: Defect and repair characteristics

| | Dura defect size | CSF leak flow rate | Number of CSF leak repairs | Pedicle nasoseptal flap (Y/N) | Lumbar drain before BMP repair (Y/N) | Duration of lumbar drain before CSF repair (days) | Lumbar drain after BMP CSF repair (Y/N) | Duration of lumbar drain after BMP repair (days) |
|--------|------------------|--------------------|----------------------------|-------------------------------|--------------------------------------|---|---|--|
| Case 1 | <1 mm | High flow | 4 | N | Y | 5 days | Y | 5 |
| Case 2 | <1 mm | Low flow | 4 | N | Y | 5 days | Y | 7 |
| Case 3 | <1 mm | High flow | 2 | N | Y | 5 days | Y | 7 |
| Case 4 | <1 mm | Low flow | 2 | N | Y | 2 days | Y | 5 |

BMP – Bone morphogenetic protein; CSF – Cerebrospinal fluid; Y – Yes; N – No

Table 4: Patient outcomes

| | LOS after BMP CSF repair (d) | Lumbar drain complications | CSF leak-related complications |
|--------|------------------------------|----------------------------|--------------------------------|
| Case 1 | 11 | None | None |
| Case 2 | 11 | None | None |
| Case 3 | 12 | None | None |
| Case 4 | 12 | None | None |

BMP – Bone morphogenetic protein; CSF – Cerebrospinal fluid; LOS – Length of stay

CSF leak, often caused by aggressive surgical resection. Methods of repairing the leak include placement of a lumbar drain, a free flap commonly in the form of fat or fascia lata graft, or reconstructing the defect with a vascularized endonasal flap.^[18,6] The incidence of CSF leak with or without a vascularized nasoseptal flap has been reported between 1.5% and 4.2%.^[1,4] CSF leak rates can be decreased by the use of a vascularized nasoseptal flap on exposure. However, the majority of small defects (<1 cm) caused by iatrogenic injury resulting in CSF leak are reliably repaired with minimal difference between methods or materials used.^[7] Further, the use of

vascularized nasoseptal flaps is not without complications, with postoperative CSF leak rates approaching 5% and overall complications reaching 30%.^[19-21] For these reasons, exposure and preparation of a vascularized nasoseptal flap by ENT or the operating neurosurgeon are not always deemed necessary in a primary first-time transsphenoidal surgery.^[19-21]

The use of fat grafts, fascia lata, and sealants such as DuraSeal has been routinely used in transsphenoidal surgery for closures and revisions. In each of our cases, the appearance of the CSF leak under microscopic examination revealed a generalized leaking around graft materials with no clear or obvious defect in the previous repair before revision with BMP. In all cases, a lumbar drain was used before the revision with BMP and after the revisions using BMP. While the use of lumbar drain can confound the evaluation of the effectiveness of the BMP repair, its use is part of the treatment in actual practice. Moreover, the use of lumbar drain did not lead to any complications in our patients. Therefore, the use of lumbar drain is an important element regarding generalizability. No corticosteroids were used in any of the patients in the

Table 5: Clinical and radiographic outcomes

| | Phone interview follow-up interval after BMP CSF leak repair (m) | Clinic visit follow-up interval after BMP CSF leak repair (m) | Recurrent CSF leak (Y/N) | Newly diagnosed neoplasm (Y/N) | Last radiographic interval after BMP CSF leak repair (months) | Radiographic imaging (CT/MRI) | Any abnormality (extraneous bone growth, inflammation, osteolysis) |
|--------|--|---|--------------------------|--------------------------------|---|-------------------------------|--|
| Case 1 | 91 | 23 | N | N | 73 | MRI with/without contrast | No |
| Case 2 | 37 | 9 | N | N | 8 | MRI with/without contrast | No |
| Case 3 | 25 | 3 | N | N | 8 | CT without contrast | No |
| Case 4 | 37 | 1 | N | N | 1 | CT without contrast | No |

BMP – Bone morphogenetic protein; CSF – Cerebrospinal fluid; MRI – Magnetic resonance imaging; CT– Computed tomography; Y – Yes; N – No

perioperative or postoperative time periods which may have hindered inflammation and healing with or without BMP.^[22]

Conclusion

In recent years, there have been reports of several complications associated with the use of BMP, including ectopic bone formation, osteolysis, and malignancies with higher dose formulations.^[9,10] However, in our case series, we demonstrated that the use of BMP can be a safe and effective treatment in the repair of recurrent CSF leaks after transsphenoidal pituitary mass resection. Some of the limitations of our study are the small sample size and the need for continuous on-going follow-up to monitor for complications such as neoplasms which may take many years to develop. BMPs are intensely studied molecules with a multitude of functions. However, more research is needed to completely understand their properties in the setting of surgical injury, healing, and repair.

Financial support and sponsorship

Nil.

Conflicts of interest

There are no conflicts of interest.

References

- Daudia A, Biswas D, Jones NS. Risk of meningitis with cerebrospinal fluid rhinorrhea. *Ann Otol Rhinol Laryngol* 2007;116:902-5.
- Sudhakar N, Ray A, Vafidis JA. Complications after trans-sphenoidal surgery: Our experience and a review of the literature. *Br J Neurosurg* 2004;18:507-12.
- Lobo B, Heng A, Barkhoudarian G, Griffiths CF, Kelly DF. The expanding role of the endonasal endoscopic approach in pituitary and skull base surgery: A 2014 perspective. *Surg Neurol Int* 2015;6:82.
- Elgamal EA. CSF rhinorrhoea after transsphenoidal surgery. *J Neurosurg* 2007;5(1). Available from: <http://www.ipub.com/IJNS/5/1/5147>. [Last accessed on 2016 Oct 21].
- Tamasauskas A, Sinkunas K, Draf W, Deltuva V, Matukevicius A, Rastenyte D, et al. Management of cerebrospinal fluid leak after surgical removal of pituitary adenomas. *Medicina (Kaunas)* 2008;44:302-7.
- Reyes C, Mason E, Solares CA. Panorama of reconstruction of skull base defects: From traditional open to endonasal endoscopic approaches, from free grafts to microvascular flaps. *Int Arch Otorhinolaryngol* 2014;18:S179-86.
- Harvey RJ, Parmar P, Sacks R, Zanation AM. Endoscopic skull base reconstruction of large dural defects: A systematic review of published evidence. *Laryngoscope* 2012;122:452-9.
- Urist MR. Bone: Formation by autoinduction. *Science* 1965;150:893-9.
- Cahill KS, McCormick PC, Levi AD. A comprehensive assessment of the risk of bone morphogenetic protein use in spinal fusion surgery and postoperative cancer diagnosis. *J Neurosurg Spine* 2015;23:86-93.
- Carragee EJ, Hurwitz EL, Weiner BK. A critical review of recombinant human bone morphogenetic protein-2 trials in spinal surgery: Emerging safety concerns and lessons learned. *Spine J* 2011;11:471-91.
- Guppy KH, Harris J, Chen J, Paxton EW, Bernbeck JA. Reoperation rates for symptomatic nonunions in posterior cervicothoracic fusions with and without bone morphogenetic protein in a cohort of 450 patients. *J Neurosurg Spine* 2016;25:309-17.
- Hofstetter CP, Hofer AS, Levi AD. Exploratory meta-analysis on dose-related efficacy and morbidity of bone morphogenetic protein in spinal arthrodesis surgery. *J Neurosurg Spine* 2016;24:457-75.
- Louie PK, Hassanzadeh H, Singh K. Epidemiologic trends in the utilization, demographics, and cost of bone morphogenetic protein in spinal fusions. *Curr Rev Musculoskelet Med* 2014;7:177-81.
- Wang RN, Green J, Wang Z, Deng Y, Qiao M, Peabody M, et al. Bone morphogenetic protein (BMP) signaling in development and human diseases. *Genes Dis* 2014;1:87-105.
- Huang RL, Yuan Y, Tu J, Zou GM, Li Q. Exaggerated inflammatory environment decreases BMP-2/ACS-induced ectopic bone mass in a rat model: Implications for clinical use of BMP-2. *Osteoarthritis Cartilage* 2014;22:1186-96.
- Slavnic D, Tong D, Claus C, Barrett R. Use of Bone Morphogenetic Protein in the Repair of Lumbar Cerebrospinal Fluid Leak. Southfield, Michigan: Unpublished Manuscript; 2018.
- Gandhi CD, Post KD. Historical movements in transsphenoidal surgery. *Neurosurg Focus* 2001;11:E7.

18. Kim GG, Hang AX, Mitchell CA, Zanation AM. Pedicled extranasal flaps in skull base reconstruction. *Adv Otorhinolaryngol* 2013;74:71-80.
19. Hadad G, Bassagasteguy L, Carrau RL, Mataza JC, Kassam A, Snyderman CH, *et al.* A novel reconstructive technique after endoscopic expanded endonasal approaches: Vascular pedicle nasoseptal flap. *Laryngoscope* 2006;116:1882-6.
20. Dolci RLL, Miyake MM, Tateno DA, Cançado NA, Campos CAC, Dos Santos ARL, *et al.* Postoperative otorhinolaryngologic complications in transnasal endoscopic surgery to access the skull base. *Braz J Otorhinolaryngol* 2017;83:349-55.
21. Soudry E, Psaltis AJ, Lee KH, Vaezafshar R, Nayak JV, Hwang PH, *et al.* Complications associated with the pedicled nasoseptal flap for skull base reconstruction. *Laryngoscope* 2015;125:80-5.
22. Epstein NE. Complications due to the use of BMP/INFUSE in spine surgery: The evidence continues to mount. *Surg Neurol Int* 2013;4:S343-52.