

CT-guided percutaneous transthoracic needle biopsy for paramediastinal and nonparamediastinal lung lesions

Diagnostic yield and complications in 1484 patients

Ye Wang, MD^{a,b}, Faming Jiang, MD^a, Xiaobo Tan, MD^b, Panwen Tian, MD^{a,b,*}

Abstract

Computed tomography-guided percutaneous transthoracic needle biopsy (PTNB) is used for identifying paramediastinal lung lesions that cannot be diagnosed by bronchoscopy, but the diagnostic performance and complication rate are unreported.

This retrospective study was approved by the institutional review board committee. A total of 1484 patients who underwent PTNB between April 2012 and April 2015 were enrolled. The cohort was divided into a paramediastinal (n=195) and a nonparamediastinal group (n=1289) based on lesion location. Diagnostic yield for malignancy and complication rates were analyzed in both groups. Univariate and multivariate logistic regression analysis was used to determine independent risk factors for hemoptysis complication in the paramediastinal group.

Percutaneous transthoracic needle biopsy showed 95.6% (109/114) sensitivity and 100% (77/77) specificity for the diagnosis of lesions in the paramediastinal group, with similar accuracy (95.4%, 186/195) to that in the nonparamediastinal group (94.7%, 1221/1289; $P=0.699$). Compared with PTNB for nonparamediastinal lesions, PTNB for paramediastinal lesions demonstrated a comparable pneumothorax rate (8.21% vs 8.69%; $P=0.823$) and hemothorax rate (2.56% vs 1.47%; $P=0.261$), and a higher hemoptysis rate (28.2% vs 19.4%; $P=0.005$). Among 6 defined paramediastinal regions, the overall complication rate was the highest in the posterior region (42.4%) and the lowest in the paraventricular region (13.6%). Multivariate analysis revealed that lesion size of 2 to 3 cm (odds ratio [OR] 3.22), intrapulmonary length of needle path >2 cm (OR 8.85), and proximal to pulmonary artery (OR 10.33) were independent risk factors for hemoptysis in the paramediastinal group.

Computed tomography-guided PTNB can diagnose paramediastinal lesions with high yield and acceptable complication rates. Given higher rate of hemoptysis in PTNB for paramediastinal lesions, more attention should be paid in cases with high risks.

Abbreviations: CT = computed tomography, NPV = negative predictive value, PPV = positive predictive value, PTNB = percutaneous transthoracic needle biopsy, OR = odds ratio, CACT = C-arm computed tomography, EBUS = endobronchial ultrasound, ENB = electromagnetic navigation bronchoscopy, VATS = video-assisted thoracoscopic surgery.

Keywords: complications, diagnostic yield, needle biopsy, nonparamediastinal lesion, paramediastinal lesion

1. Introduction

Percutaneous transthoracic needle biopsy (PTNB) is a well-established method for diagnosing lung lesions with high yield and

a low complication rate.^[1–5] Compared with bronchoscopy, the most frequently used lung biopsy procedure, PTNB, is advantageous in diagnosing peripheral lung lesions for its high accuracy and safety.^[6,7] With guidance of computed tomography (CT) fluoroscopy, PTNB leads to >90% overall diagnostic accuracy, even for small lesions ≤1 cm in diameter.^[1,2,8–15] PTNB could achieve diagnosis of lesions located in almost any region of the lungs without an apparent so-called “blind area.” However, it is believed that lesions located beneath the ribs, scapula, or subclavicular vessels, and also those proximal to the diaphragm, increase the difficulty of performing PTNB.^[15,16] The influences of location of lesions on diagnostic accuracy and complication rate of PTNB have been reported in several previous studies.^[13–18]

Many disorders, such as lung squamous carcinomas, are usually located in paramediastinal regions or hilar regions, where lung biopsies are performed, preferably by bronchoscopy. CT-guided PTNB provides an alternative choice when a definite diagnosis cannot be made. Two previous studies reported that the diagnostic yield of PTNB diminished significantly in central regions, and biopsy of central lesions was more often associated with pneumothorax, whereas lesions near the hilar region were more susceptible to hemorrhagic complications or pneumothorax.^[17,18] However, these studies were limited by small sample sizes and employed different definitions of the

Editor: Levent Dalar.

YW and FJ contributed equally to this manuscript and shared joint first authorship.

The authors declare no conflicts of interest.

^a Department of Respiratory and Critical Care Medicine, ^b Lung Cancer Treatment Center, West China Hospital, Sichuan University, Chengdu, Sichuan Province, China.

* Correspondence: Panwen Tian, Department of Respiratory and Critical Care Medicine, Lung Cancer Treatment Center, West China Hospital, Sichuan University, #37 GuoXue Xiang, Chengdu, Sichuan Province 610041, China (e-mail: mrascend@163.com).

Copyright © 2016 the Author(s). Published by Wolters Kluwer Health, Inc. All rights reserved.

This is an open access article distributed under the Creative Commons Attribution-NoDerivatives License 4.0, which allows for redistribution, commercial and non-commercial, as long as it is passed along unchanged and in whole, with credit to the author.

Medicine (2016) 95:31(e4460)

Received: 16 April 2016 / Received in final form: 22 June 2016 / Accepted: 10 July 2016

<http://dx.doi.org/10.1097/MD.0000000000004460>

central region. The diagnostic accuracy and safety of PTNB for lung lesions near the hilum or mediastinum has barely been studied.

In this study, we retrospectively investigated the diagnostic performance and complications of CT-guided PTNB for paramediastinal lung lesions and compared the results with those for nonparamediastinal lesions. In addition, we analyzed the risk factors of hemoptysis, and assessed the feasibility of the procedure in different subdivided paramediastinal region.

2. Materials and methods

This retrospective study was approved by the Institutional Review Board Committee of Sichuan University (Approval number: 2015–189). Patient informed consent requirements were waived.

2.1. Patients and definitions

Patients were enrolled if they underwent CT-guided PTNB in the Department of Respiratory and Critical Care Medicine of the West China Hospital at Sichuan University between Apr 1, 2012 and April 30, 2015. Patients with mediastinal or pleural biopsy or lack of final diagnosis were excluded. For patients who underwent re-biopsy, only the results from the first PTNB were analyzed. Based on lesion location, the patients were divided into paramediastinal and nonparamediastinal groups. A paramediastinal lesion was defined as a lesion possessing an exterior margin ≤ 3 cm from the nearest mediastinum. Lesions not fitting this definition were classified as nonparamediastinal (Fig. 1). We adopt this definition based on the clinical experiences while performing needle biopsy: A needle insertion at 3 cm or less near the mediastinum likely confers high risk of injury to large vessels and other organs.

Of 1716 potentially eligible patients, 232 were excluded because of mediastinal or pleural biopsies ($n=138$) and lack of final diagnosis ($n=94$). Lack of final diagnosis was defined as one of the following reasons: the lesion was diagnosed as nonspecific inflammation and remained stable in size, but the follow-up period was less than 2 years ($n=23$); the results of biopsy were indeterminate and the patients were lost to follow-up ($n=71$). These 94 cases were excluded from the study because a final diagnosis could not be confirmed despite the fact that the needle biopsies were successfully performed. Finally, data from 1484 consecutive patients (910 males, 574 females; mean age 56.0 ± 12.7 years; age range 9–88 years) were included.

According to the definition, 195 patients were assigned to the paramediastinal group (111 males, 84 females; mean age 50.5 ± 14.6 years; age range 26–88 years), and the remaining 1289 patients were assigned to the nonparamediastinal group (799 males, 490 females; mean age 56.4 ± 12.5 years; age range 9–84 years). There were no significant differences between the 2 groups in terms of age ($P=0.242$) or sex composition ($P=0.176$).

Based on anatomic location, we further divided the paramediastinal region into 6 subdivisions: region 1, referred to as the apical region, is located superior to the horizontal plane of the manubrium sterni; region 2, referred to as the posterior region, is located lateral to the posterior mediastinum; region 3, referred to as the right anterior region, is located anterior to the right hilum; region 4, referred to as the para-aortic arch region, is located superior and anterior to the left hilum, near the aortic arch; region 5, referred to as the right parahilar region, is located near the right hilum; and region 6, referred to as the paraventricular region, is located near the ventricles. The lesion locations in the paramediastinal group were distributed among the 6 paramediastinal regions as follows: region 1, $n=16$; region 2, $n=66$; region 3, $n=49$; region 4, $n=38$; region 5, $n=4$; and region 6, $n=22$.

2.2. Biopsy procedures

Percutaneous transthoracic needle biopsies were performed by 2 physicians (YW and PWT, with 8 years of experience in respiratory medicine and 3 years of experiences with CT-guided PTNB, respectively), together with a technician and a nurse. The procedure was conducted under CT guidance (SOMATOM Definition AS+64; Siemens, Germany). Either automatic (Mn1816, C1816B, BARD, NJ) or semiautomatic (QCS-18-15-20T, Cook, Bloomington, IN) coaxial cutting needles were used.

The patients were asked to adopt an appropriate position, and a reference needle was placed near each puncture point. CT scanning was performed with a 5-mm slice thickness (or thinner for select small lesions). After sterilization and local anesthesia, an introducer needle was inserted stepwise into the lesion. Whenever possible, we avoided passing the needles through interlobular fissures and prevented them from contacting visible bronchi and vessels. After adjusting and confirming the position of the introducer needle, a cutting needle was inserted into the lesion via the introducer needle. Specimens were repeatedly obtained until sufficient material had been collected for pathological examination or until the patient began to cough

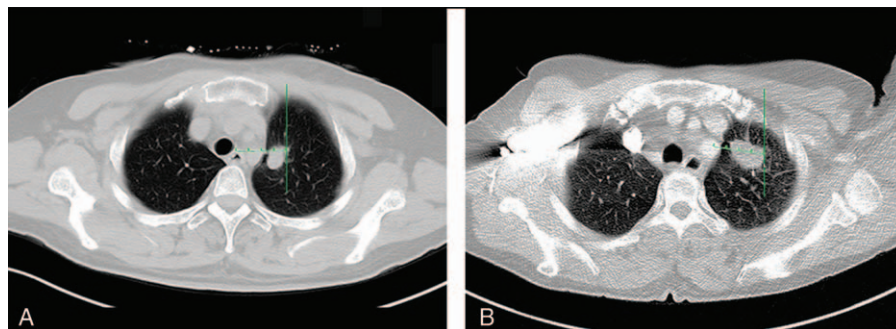


Figure 1. Definitions of paramediastinal lesion and nonparamediastinal lesion. A, CT image of a 49-year-old female showed a 16 mm nodule in left upper lobe. The distance from the exterior margin of the lesion to the nearest mediastinum was 18 mm (less than 3 cm). It was classified as a paramediastinal lesion. B, CT image of a 51-year-old female shows a 30 mm nodule in the left upper lobe. The distance from the exterior margin of the lesion to the nearest mediastinum is 35 mm (exceed 3 cm). This lesion was classified as a non-paramediastinal lesion. CT = computed tomography.

forcefully. After biopsy, CT images were taken to detect procedure-related complications.

2.3. Assessment of diagnostic accuracy

Specimens were successfully obtained from all patients. Final diagnoses were confirmed via one of the following methods: if a patient underwent surgical resection, then his or her final diagnosis was confirmed based on the pathology reports of the surgical specimens; if PTNB or other biopsy methods (including repeated PTNBs) revealed malignancies or specific benign abnormalities (e.g., mycosis or tuberculosis), then the diagnosis was confirmed based on a combination of pathology reports and clinical symptoms (e.g., metastatic symptoms, elevated carcinoembryonic antigen levels, mutated epidermal growth factor receptors); if nonspecific chronic inflammation was indicated in a pathology report, then a lesion was considered benign if it regressed with conservative medical treatment or remained stable for at least for 2 years (for biopsies performed before October 2013); and pathologic results were considered nondiagnostic if malignancies were suspected, but not confirmed.

2.4. Assessment of complications

Pneumothorax and hemothorax confirmed by CT were documented. Hemoptysis was recorded until the patient was discharged from the hospital. Self-limiting blood-stained sputum was considered to be hemoptysis in this study. Risk factors associated with hemoptysis such as lesion size, intrapulmonary needle path length, tissue sampling amount, lobe distribution, proximal to bronchus, proximal to pulmonary artery, and final diagnosis were analyzed.

2.5. Statistical analysis

Continuous data were presented as the mean \pm standard deviation if they showed a normal distribution or as the median and range if they showed a skewed distribution. Categorical data were presented as the frequency and percentage. Sensitivity, specificity, positive predictive value (PPV), negative predictive value (NPV), and diagnostic accuracy for malignancy were calculated. Differences between the 2 study groups were assessed using Student *t* test if the data showed a normal distribution, the Mann-Whitney *U* test if they showed a skewed distribution, or a chisquare test if they were categorical. Univariate and multivariate logistic regression analysis was used to determine independent risk factors for hemoptysis complication in the paramediastinal group. All analyses were performed using SPSS 18.0 (IBM, Chicago, IL) and had a significance threshold of $P < 0.05$.

3. Results

3.1. Diagnostic accuracy

Of the 1484 total pathology reports, 28 were judged to be nondiagnostic, and 821 were found to indicate malignancy. All indicated malignancies were true-positives. Of the 635 benign reports, 49 were false-negatives after a final diagnosis of malignancy was reached based on surgery ($n=4$) or other biopsy method ($n=45$). The remaining 586 benign reports were considered true-negatives after confirmation of the presence of tuberculosis ($n=86$), mycosis ($n=19$), or nonspecific inflammation ($n=481$). Nonspecific inflammation was established for one of the following reasons: the final diagnosis was confirmed by surgical

Table 1

Diagnostic yield of CT-guided percutaneous transthoracic needle biopsy.

Parameters	Paramediastinal (n = 195)	Nonparamediastinal (n = 1289)	Overall (N = 1484)
True-positive, n	109	712	821
True-negative, n	77	509	586
False-positive, n	0	0	0
False-negative, n	5	44	49
Nondiagnostic, n	4	24	28
Sensitivity, %	95.6	94.2	94.4
Specificity, %	100	100	100
PPV, %	100	100	100
NPV, %	94.0	92.0	92.3
Diagnostic accuracy, %	95.4	94.7	94.8

CT = computed tomography, NPV = negative predictive value, PPV = positive predictive value.

biopsy ($n=24$); pulmonary lesions were disappeared or significantly decreased after anti-infection treatment ($n=426$); the lesion was diagnosed as nonspecific inflammation by needle biopsy and remained stable in size, and the follow-up period was more than 2 years ($n=31$). Other 23 cases with stable lesions were excluded for the follow-up period was less than 2 years, although the biopsy results of them were nonspecific inflammations.

The overall sensitivity, specificity, PPV, and NPV for the diagnosis of malignancy were 94.4% (821 of 870), 100% (586 of 586), 100% (821 of 821), and 92.3% (586 of 635), respectively. The overall diagnostic accuracy was 94.8% (1407 of 1484).

The diagnostic yields for the paramediastinal and nonparamediastinal groups are shown in Table 1. Four pathology reports in the paramediastinal group were nondiagnostic. The diagnostic accuracy was 95.4% (186 of 195) for the paramediastinal group; a similar value was found for the nonparamediastinal group (94.7% [1221 of 1289]; $P=0.699$). In the paramediastinal group, the sensitivity was 95.6% (109 of 114), the specificity was 100% (77 of 77), the PPV was 100% (109 of 109), and the NPV was 94.0% (77 of 82). The corresponding diagnostic parameters in the nonparamediastinal group were 94.2% (712 of 756), 100% (509 of 509), 100% (712 of 712), and 92.0% (509 of 553).

3.2. Complications

The rate of pneumothorax was 8.63% (128 of 1,484), with 42 cases requiring air aspiration or closed thoracic drainage (Table 2). The pneumothorax rates were similar between the paramediastinal and nonparamediastinal groups (8.21% [16 of 195] vs 8.69% [112 of 1289]; $P=0.823$), as were the rates of air aspiration and closed thoracic drainage (2.56% [5 of 195] vs 2.87% [37 of 1289]; $P=0.81$).

The overall rate of hemoptysis was 20.6% (305 of 1484), with most cases having volumes ≤ 20 mL (19.1% [284 of 1484]) (Fig. 2). The hemoptysis rate in the paramediastinal group (28.2% [55 of 195]) was significantly higher than that in the nonparamediastinal group (19.4% [250 of 1289]; $P=0.005$). Two patients in the nonparamediastinal group suffered massive hemoptysis, which was resolved using tracheal intubation.

All of the enrolled patients were re-examined using CT after PTNB; during this process, hemothorax was identified in 24 patients (1.62%). These rates were similar between the paramediastinal group (2.56% [5 of 195]) and the nonparamediastinal group (1.47% [37 of 1289]; $P=0.261$).

Table 2**Complications of PTNB.**

Operation-related complications	Paramediastinal (n = 195)	Nonparamediastinal (n = 1289)	P
Pneumothorax	16 (8.21)	112 (8.69)	0.823
Requiring air aspiration	4 (2.1)	26 (2.0)	0.81
Requiring closed thoracic drainage	1 (0.5)	11 (0.9)	
Hemoptysis	55 (28.2)	250 (19.4)	0.005
≤20 mL	51 (26.2)	233 (18.1)	0.008
20–100 mL	4 (2.10)	9 (0.70)	0.42
>100 mL	0	8 (0.62)	
Hemothorax	5 (2.56)	19 (1.47)	0.261
Mild	4 (2.10)	17 (1.32)	
Moderate	1 (0.51)	2 (0.16)	

Note: all values are presented as no. (%).

PTNB = percutaneous transthoracic needle biopsy.

3.3. PTNB in subdivided paramediastinal regions

Table 3 summarizes more details associated with diagnostic performance and complication rates of PTNBs performed in each of the 6 defined paramediastinal regions. In region 4 (para-aortic arch region), PTNB achieved 100% diagnostic success in 38 patients, and in region 5 (right parahilar region), 1 pathologic report (25%) was nondiagnostic. The rates of diagnostic failure in the remaining regions (region 1, 2, 3, and 6) were all similar to the overall rate for the paramediastinal group (4.6%). The

complication rates varied among different regions. The “safest” region is the paraventricular region (region 6), where PTNB showed the lowest overall complication rate (13.6%). Pneumothorax occurred in only 2 patients, and hemoptysis was found in 1 patient. Among 4 patients who underwent PTNBs in the right parahilar region (region 5), 1 patient (25%) experienced mild hemoptysis. The complication rates in regions 1 to 4 were all greater than 30%, but in most circumstances, patients presented mild hemoptysis. Hemoptysis occurred most frequently in the apical region (31.3% [5 of 16]) and the posterior region (36.4% [24 of 66]), whereas pneumothorax occurred most frequently in the right anterior region (12.2% [6 of 49]). The overall complication rate of PTNBs was the highest (42.4% [28 of 66]) in the posterior region (region 2) (Figure 3).

3.4. Risk factors for hemoptysis

Univariate analysis identified smaller lesion size and longer lesion–pleura distance as risk factors for hemoptysis in the paramediastinal regions ($P=0.004$ and $P=0.006$, respectively; Table 4). Furthermore, the proximity of the needle path to the pulmonary artery was also identified as a risk factor for hemoptysis in the paramediastinal regions ($P<0.001$). In our study, fewer tissue samplings was shown as a risk factor ($P=0.008$). The results of multivariate analysis to identify independent risk factors for hemoptysis in the paramediastinal group are shown in Table 5. The significant independent risk factors were lesion size of 2 to 3 cm (OR 3.22, 95% CI 1.47–7.61, $P=0.003$), intrapulmonary length of needle path >2 cm (OR 8.85, 95% CI

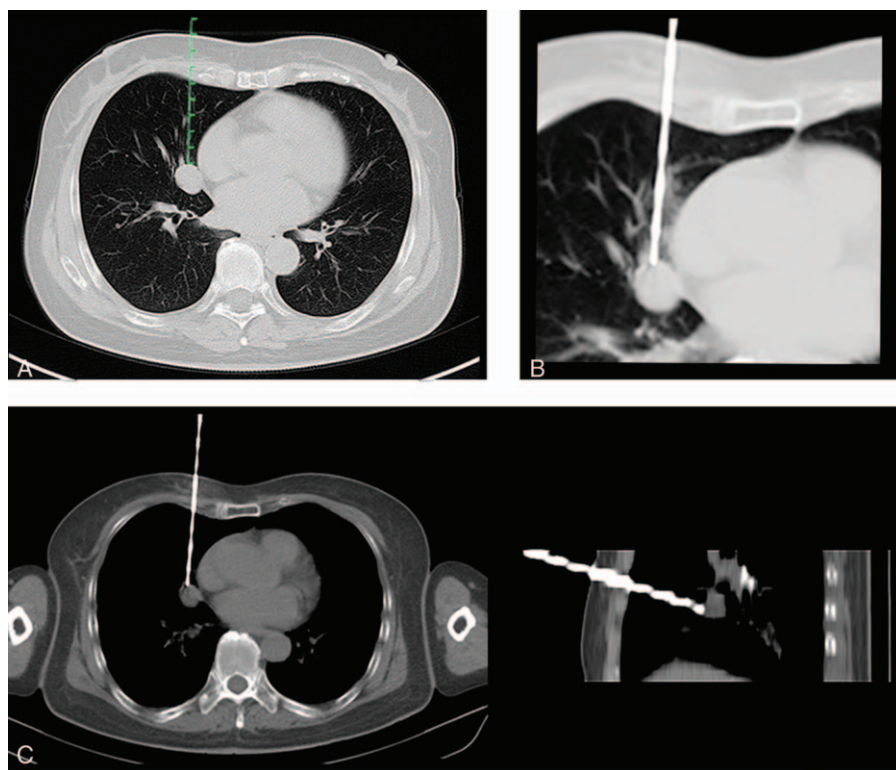


Figure 2. Hemorrhagic complication of CT-guided PTNB for a lesion in the right anterior region (region 3) in a 46-year-old female. A, CT image showed a 18 mm nodule attached to the right atrium in the right middle lobe. The needle path through the lung exceeded 5 cm and should have avoided injuring the pulmonary artery, vein, and bronchus of the middle lobe, which were identified clearly near the lesion. B, A 17-gauge introducer needle was inserted carefully, and biopsy was carried out with an 18-gauge semiautomatic cutting needle. C, CT showed intrapulmonary hemorrhage along the needle path. This patient presented mild hemoptysis after PTNB. CT = computed tomography, PTNB = percutaneous transthoracic needle biopsy.

Table 3**PTNB in each subdivided paramediastinal region.**

Locations	Paramediastinal regions (N=195)					
	1 (n=16)	2 (n=66)	3 (n=49)	4 (n=38)	5 (n=4)	6 (n=22)
Diagnostic failure*	Lung apices	Bilateral posterior	Right anterior	Near aortic arch	Near right hilus	Near ventricles
	1 (6.3)	3 (4.5)	3 (6.1)	0	1 (25)	1 (4.5)
Complications						
	6 (37.5)	28 (42.4)	19 (38.8)	13 (34.2)	1 (25)	3 (13.6)
Pneumothorax	1 (6.3)	4 (6.1)	6 (12.2)	3 (7.9)	0	2 (9.1)
Hemoptysis	5 (31.3)	24 (36.4)	13 (26.5)	11 (28.9)	1 (25)	1 (4.5)
Hemothorax	0	3 (4.5)	2 (4.1)	0	0	0

Note: all values are presented as no. (%).

PTNB=percutaneous transthoracic needle biopsy.

*Diagnostic failure consists of nondiagnostic, false-positive, and false-negative reports.

3.06–25.64, $P=0.002$), and proximal to pulmonary artery (OR 10.33, 95% CI 2.09–43.62, $P<0.001$).

4. Discussion

In the present study, we achieved an overall diagnostic accuracy of 94.8% (1407 of 1484), which was comparable with results reported by Hiraki et al^[1] (95.2% [952 of 1000]), Lee et al^[2] (97.0% [1056 of 1089]), and other previous studies.^[3–5] The sensitivity, specificity, PPV, and NPV were 94.4%, 100%, 100%,

and 92.3%, respectively, suggesting a very high diagnostic yield. In our study, the diagnostic accuracy for the paramediastinal region reached 95.4% (186 of 195), and the sensitivity, specificity, PPV, and NPV were all comparable with the values for the nonparamediastinal group.

The C-arm CT (CACT) system can offer real-time visualization of PTNB procedures and facilitate needle path planning with 3-dimensional images. It is more flexible in the orientation of the detector system compared with conventional CT systems. Therefore, it is more advantageous for the biopsy of small lung

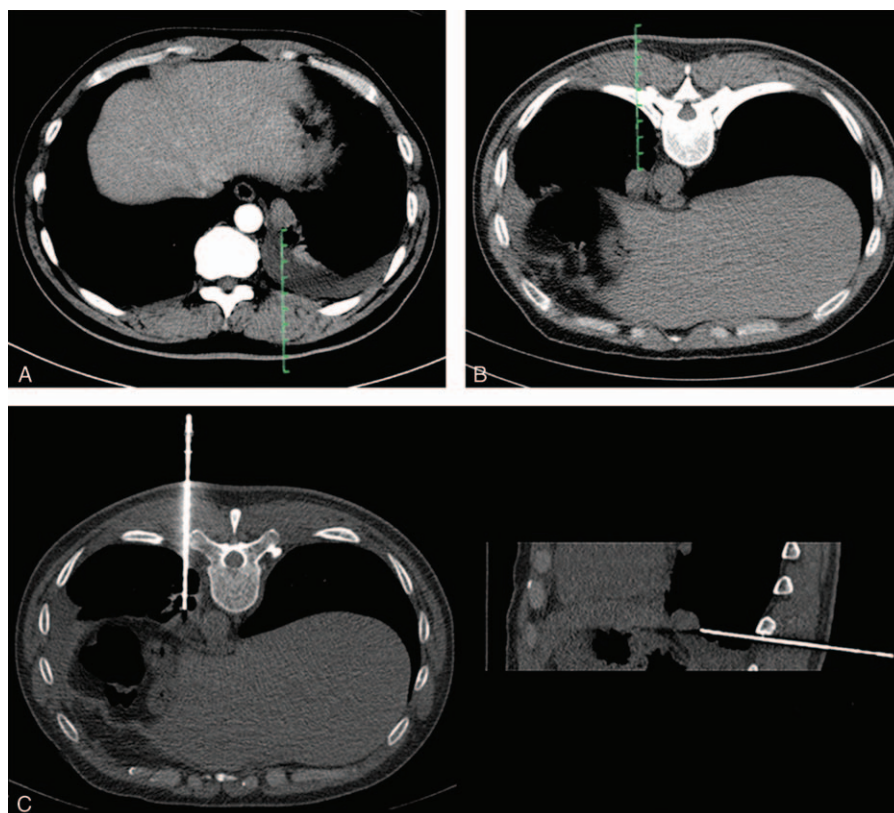


Figure 3. A CT-guided PTNB for a lesion in the posterior region (region 2) in a 48-year-old male. A, CT image showed an 18 mm nodule adjacent to the descending aorta in the left lower lobe, with some pleural effusion. B, When the patient was placed in the prone position, a CT image showed the lesion attached to the descending aorta more closely because of the fluidity of pleural effusion. C, A 17-gauge introducer needle was inserted stepwise into the lesion, and the acquisition of specimens was performed with a semiautomatic cutting needle to avoid liver or stomach injury. CT=computed tomography, PTNB=percutaneous transthoracic needle biopsy.

Table 4
Risk factors for hemoptysis in the paramediastinal group.

Characteristics	Hemoptysis		P
	Yes (n=58)	No (n=137)	
Age, y	54.9±14.8	56.4±13.7	0.494
Sex			0.996
Male	33	78	
Female	25	59	
Lesion size, cm			0.004
≤1	0	6	
1–2	9	28	
2–3	31	38	
>3	18	65	
Intrapulmonary length of needle path, cm			0.006
0	0	21	
0.1–2.0	6	45	
>2	52	71	
No. of tissue samplings			0.008
≤2	9	6	
≥3	49	131	
Lobe distribution			0.104
Upper and middle lobes	36	101	
Lower lobes	22	36	
Proximal to bronchus			0.958
Yes	18	42	
No	40	95	
Proximal to pulmonary artery			<0.001
Yes	18	7	
No	40	130	
Final diagnosis			0.487
Malignant	35	75	
Benign	22	59	

lesions.^[9,19] The diagnostic sensitivity, specificity, and accuracy of the CACT-guided technique for PTNB of lung lesions were 95.0% to 98.7%, 90.5% to 100%, and 91.5% to 97.0%, respectively.^[2,20–22] However, whether this technique will improve accuracy and safety for paramediastinal lesions is unknown.

Because of high diagnostic yield and low complication rate, bronchoscopy is performed before PTNB for diagnosis of central or paramediastinal lesions. However, the sensitivity decreases when the lesion can not be directly seen by bronchoscopy. Van't Westeinde et al^[23] evaluated the application of conventional bronchoscopy in the diagnosis of 308 patients with suspicious lung lesions. The sensitivity of conventional bronchoscopy was only 13.5%, and the NPV was 47.6%. Given that conventional bronchoscopy biopsy lacks a real-time visualization, making it difficult guiding to the target location, radial endobronchial ultrasound (EBUS) driven biopsy has been widely used to improve the diagnostic yield for lung lesions.^[24] Kurimoto et al^[25] described a study using radial EBUS to sample 150 pulmonary nodules, and the biopsies established a diagnosis in 77% of patients. Electromagnetic navigation bronchoscopy (ENB) procedures could allow thoracic surgeons to access lung lesions beyond the reach of conventional bronchoscopy. It was reported that ENB could acquire a diagnostic accuracy of 73.9% for lung nodules.^[26] A multicenter study which included 581 consecutive patients undergoing transbronchial biopsy found that the diagnostic yield was 63.7% with conventional bronchoscopy, 57.0% with radial EBUS alone, 38.5% with ENB alone, and 47.1% with ENB combined with radial EBUS.^[27]

Table 5
Results of multivariate analysis to identify independent risk factors for hemoptysis in the paramediastinal group.

Variables	Reference value	P	OR	95% CI
Lesion size, cm				
1–2	≤1	0.052	1.04	1.01–1.08
2–3	≤1	0.003	3.22	1.47–7.61
>3	≤1	0.217	3.53	0.52–35.78
Intrapulmonary length of needle path, cm				
0.1–2.0	0	0.262	2.31	0.66–9.81
>2	0	0.002	8.85	3.06–25.64
No. of tissue samplings				
≤2	≥3	0.259	1.37	0.76–2.44
Proximal to pulmonary artery				
Yes	No	<0.001	10.33	2.09–43.62

CI=confidence interval, OR=odds ratio.

Compared with EBUS or ENB, CT-guided PTNB seems to obtain higher diagnostic yield for lung lesions. However, so far, there is no study of direct comparison between needle biopsy and bronchoscopy for paramediastinal lung lesions.

Surgical excision biopsy by video-assisted thoracoscopic surgery (VATS) for indeterminate pulmonary nodules could acquire definitive diagnosis in 100% of cases. Another advantage of VATS is that it could remove the entire lesions when necessary. However, given its high cost and risk, it is only used for cases highly suspected as early-stage lung cancer, or nodules which cannot be diagnosed by bronchoscopy or PTNB.^[28–31]

The rate of pneumothorax in our study (8.6%) was substantially lower than those studies of CT-guided needle biopsy reported by Lee et al^[21] (17.0% [196 of 1153]); Geraghty et al^[4] (29.8% [252 of 846]), and Nour-Eldin et al^[5] (25.1% [163 of 650]). However, the rate of aspiration or closed thoracic drainage in our study (2.83% [42 of 1484]) was higher than that reported by Lee et al^[21] (1.1% [13 of 1153]).

The rates of pneumothorax, aspiration, and closed thoracic drainage were comparable between the paramediastinal and nonparamediastinal groups. These results suggest that paramediastinal PTNB might not increase pneumothorax risk, despite the fact that the introducer needle remains in the lung tissue longer than during nonparamediastinal puncture. We speculate that this result occurred because the procedure did not increase the risk of pleural injury. Alternatively, it may increase the risk of hemorrhage along the needle path, preventing air leakage; NaCl instillation reduces pneumothorax rates in a similar manner.^[32]

The overall rate of hemoptysis in our study was 20.6%, which is higher than the rates reported by Nour-Eldin et al^[33] (6.3% [20 of 318]), Wu et al^[34] (11% [11 of 100]), and Choi et al^[8] (14.5% [25 of 173]). A higher incidence of hemoptysis may be due to the definitions we used. Blood mixed in phlegm was determined to be mild hemoptysis in this study. In fact, most cases of hemoptysis were mild, as only 1.4% of cases (21 of 1484) involved volumes >20 mL. Hemoptysis occurred at a significantly higher rate in the paramediastinal group than in the nonparamediastinal group, likely due to higher risk of vessel injury near the mediastinum or hilum.

Lower incidences of pneumothorax and hemoptysis were found in radial EBUS and ENB compared with needle biopsy.^[35] A large series of radial EBUS in 467 patients with lung lesions yielded a pneumothorax rate of 2.8%.^[36] Another study which included 1033 ENB procedures reported a pneumothorax rate of 3.1%, whereas only 1.6% of these cases required chest tube drainage.^[26] A multicenter study analyzed the complication of

transbronchial biopsy, and found that bleeding occurred in only 1 of 581 patients (0.17%).^[27] A large review of 1033 ENB procedures reported bleeding occurred in 1% of cases.^[26] Before biopsy, the physician should make a detailed evaluation of each lesion and balance the diagnostic accuracy and complication rate in each patient when transbronchial biopsy and PTNB are all available.

In our study, the significant independent risk factors of hemoptysis were lesion size of 2 to 3 cm, intrapulmonary length of needle path >2 cm, and proximal to pulmonary artery, because the lesions were usually surrounded by abundance of vessels. The smaller the lesion size, the greater is the chance of vessel injury by cutting needles. Deeper needle insertions also enhanced the risk of vessel injury. Similarly, the presence of pulmonary arteries adjacent to the needle path increased the possibility of injury, resulting in a higher hemoptysis rate. Physicians should be more cautious when carrying out a needle biopsy for patients with such characteristics.

Whereas PTNB led to similar diagnostic accuracies and severe complication rates in the paramediastinal and nonparamediastinal groups, the operating procedures were quite different between the 2 groups. First, operators invested more time and energy into planning and performing paramediastinal procedures, and the insertion of introducer needles to reach paramediastinal lesions required more steps.^[37] Second, needle paths were precisely planned according to lesion location in each of the 6 defined paramediastinal regions. A standard path was designed for lesions in each region based on a combination of thoracic anatomy and clinical experiences. Third, a semiautomatic needle was used more frequently in patients with paramediastinal lesions, particularly when the lesions were attached to important mediastinal organs. The semiautomatic needle apparatus allowed the operator to feel tissue hardness and the pulsing of large vessels or the heart. This tactile feedback helped prevent organ injury caused by the cutting needle.

Whereas this study provides useful insights regarding the application of PTNB to identify paramediastinal lesions, the results should be interpreted with care because we did not use smaller introducer needles, fine needle aspiration, brushes, or other methods to obtain specimens. Our study design was retrospective, and a nonparametric grouping design was taken. Thus, there may have been an unknown bias. Furthermore, our study design did not include a comparison between the diagnostic accuracy of conventional CT and that of CACT-guided needle biopsy or bronchoscopic, surgical biopsy. Accordingly, we could not directly assess the advantages of the CT-guided needle biopsy over bronchoscopic or surgical biopsy.

In conclusion, CT-guided PTNB can diagnose paramediastinal lesions with high yield and acceptable complication rates, and it may be an appropriate alternative for transbronchial lung biopsy. Given higher rate of hemoptysis in PTNB for paramediastinal lesions, more attention should be paid in cases with high risks.

Acknowledgment

The authors are thankful to Professor Shihong Zhou who has provided the statistical consultation for this study.

References

- [1] Hiraki T, Mimura H, Gobara H, et al. CT fluoroscopy-guided biopsy of 1,000 pulmonary lesions performed with 20-gauge coaxial cutting needles: diagnostic yield and risk factors for diagnostic failure. *Chest* 2009;136:1612–7.
- [2] Lee SM, Park CM, Lee KH, et al. C-arm cone-beam CT-guided percutaneous transthoracic needle biopsy of lung nodules: clinical experience in 1108 patients. *Radiology* 2014;271:291–300.
- [3] Yeow KM, Tsay PK, Cheung YC, et al. Factors affecting diagnostic accuracy of CT-guided coaxial cutting needle lung biopsy: retrospective analysis of 631 procedures. *J Vasc Interv Radiol* 2003;14:581–8.
- [4] Geraghty PR, Kee ST, McFarlane G, et al. CT-guided transthoracic needle aspiration biopsy of pulmonary nodules: needle size and pneumothorax rate. *Radiology* 2003;229:475–81.
- [5] Nour-Eldin NE, Alsubhi M, Imam A, et al. Pneumothorax complicating coaxial and non-coaxial CT-guided lung biopsy: comparative analysis of determining risk factors and management of pneumothorax in a retrospective review of 650 patients. *Cardiovasc Intervent Radiol* 2016;39:261–70.
- [6] Yang W, Sun W, Li Q, et al. Diagnostic accuracy of CT-guided transthoracic needle biopsy for solitary pulmonary nodules. *PLoS One* 2015;10:e0131373.
- [7] Li Y, Du Y, Yang HF, et al. CT-guided percutaneous core needle biopsy for small (≤ 20 mm) pulmonary lesions. *Clin Radiol* 2013;68:e43–8.
- [8] Choi JW, Park CM, Goo JM, et al. C-arm cone-beam CT-guided percutaneous transthoracic needle biopsy of small (≤ 20 mm) lung nodules: diagnostic accuracy and complications in 161 patients. *AJR Am J Roentgenol* 2012;199:W322–30.
- [9] Choo JY, Park CM, Lee NK, et al. Percutaneous transthoracic needle biopsy of small (≤ 1 cm) lung nodules under C-arm cone-beam CT virtual navigation guidance. *Eur Radiol* 2013;23:712–9.
- [10] Hwang HS, Chung MJ, Lee JW, et al. C-arm cone-beam CT-guided percutaneous transthoracic lung biopsy: usefulness in evaluation of small pulmonary nodules. *AJR Am J Roentgenol* 2010;195:W400–7.
- [11] Montaudon M, Latrabe V, Pariente A, et al. Factors influencing accuracy of CT-guided percutaneous biopsies of pulmonary lesions. *Eur Radiol* 2004;14:1234–40.
- [12] Ohno Y, Hatabu H, Takenaka D, et al. CT-guided transthoracic needle aspiration biopsy of small (≤ 20 mm) solitary pulmonary nodules. *AJR Am J Roentgenol* 2003;180:1665–9.
- [13] Lucidarme O, Howarth N, Finet JF, et al. Intrapulmonary lesions: percutaneous automated biopsy with a detachable, 18-gauge, coaxial cutting needle. *Radiology* 1998;207:759–65.
- [14] Berquist TH, Bailey PB, Cortese DA, et al. Transthoracic needle biopsy: accuracy and complications in relation to location and type of lesion. *Mayo Clin Proc* 1980;55:475–81.
- [15] Jin KN, Park CM, Goo JM, et al. Initial experience of percutaneous transthoracic needle biopsy of lung nodules using C-arm cone-beam CT systems. *Eur Radiol* 2010;20:2108–15.
- [16] Yamagami T, Kato T, Iida S, et al. Percutaneous needle biopsy for small lung nodules beneath the rib under CT scan fluoroscopic guidance with gantry tilt. *Chest* 2004;126:744–7.
- [17] Layfield LJ, Coogan A, Johnston WW, et al. Transthoracic fine needle aspiration biopsy. Sensitivity in relation to guidance technique and lesion size and location. *Acta Cytol* 1996;40:687–90.
- [18] Poe RH, Kallay MC, Wicks CM, et al. Predicting risk of pneumothorax in needle biopsy of the lung. *Chest* 1984;85:232–5.
- [19] Jiao D, Yuan H, Zhang Q, et al. Flat detector C-arm CT-guided transthoracic needle biopsy of small (≤ 2.0 cm) pulmonary nodules: diagnostic accuracy and complication in 100 patients. *Radiol Med* 2016;121:268–78.
- [20] Rotolo N, Floridi C, Imperatori A, et al. Comparison of cone-beam CT-guided and CT fluoroscopy-guided transthoracic needle biopsy of lung nodules. *Eur Radiol* 2016;26:381–9.
- [21] Jiao DC, Li ZM, Yuan HF, et al. Flat detector C-arm CT-guidance system in performing percutaneous transthoracic needle biopsy of small (≤ 3 cm) pulmonary lesions. *Acta Radiol* 2015;57:677–83.
- [22] Jiao de C, Li TF, Han XW, et al. Clinical applications of the C-arm cone-beam CT-based 3D needle guidance system in performing percutaneous transthoracic needle biopsy of pulmonary lesions. *Diagn Interv Radiol* 2014;20:470–4.
- [23] van't Westeinde SC, Horeweg N, Vernhout RM, et al. The role of conventional bronchoscopy in the workup of suspicious CT scan screen-detected pulmonary nodules. *Chest* 2012;142:377–84.
- [24] Paone G, Nicastrì E, Lucantoni G, et al. Endobronchial ultrasound-driven biopsy in the diagnosis of peripheral lung lesions. *Chest* 2005;128:3551–7.
- [25] Kurimoto N, Miyazawa T, Okimasa S, et al. Endobronchial ultrasonography using a guide sheath increases the ability to diagnose peripheral pulmonary lesions endoscopically. *Chest* 2004;126:959–65.

- [26] Gex G, Pralong JA, Combescure C, et al. Diagnostic yield and safety of electromagnetic navigation bronchoscopy for lung nodules: a systematic review and meta-analysis. *Respiration* 2014;87:165–76.
- [27] Ost DE, Ernst A, Lei X, et al. Diagnostic yield and complications of bronchoscopy for peripheral lung lesions. Results of the AQUIRE Registry. *Am J Respir Crit Care Med* 2016;193:68–77.
- [28] Cardillo G, Regal M, Sera F, et al. Video thoracoscopic management of the solitary pulmonary nodule: a single-institution study on 429 cases. *Ann Thorac Surg* 2003;75:1607–11.
- [29] Murasugi M, Onuki T, Ikeda T, et al. The role of video-assisted thoracoscopic surgery in the diagnosis of the small peripheral pulmonary nodule. *Surg Endosc* 2001;15:734–6.
- [30] Jimenez MF. Spanish Video-Assisted Thoracic Surgery Study Group-Prospective study on video-assisted thoracoscopic surgery in the resection of pulmonary nodules: 209 cases from the Spanish Video-Assisted Thoracic Surgery Study Group. *Eur J Cardiothorac Surg* 2001;19:562–5.
- [31] Varoli F, Vergani C, Caminiti R, et al. Management of solitary pulmonary nodule. *Eur J Cardiothorac Surg* 2008;33:461–5.
- [32] Billich C, Muche R, Brenner G, et al. CT-guided lung biopsy: incidence of pneumothorax after instillation of NaCl into the biopsy track. *Eur Radiol* 2008;18:1146–52.
- [33] Nour-Eldin NE, Alsubhi M, Naguib NN, et al. Risk factor analysis of pulmonary hemorrhage complicating CT-guided lung biopsy in coaxial and non-coaxial core biopsy techniques in 650 patients. *Eur J Radiol* 2014;83:1945–52.
- [34] Wu RH, Tzeng WS, Lee WJ, et al. CT-guided transthoracic cutting needle biopsy of intrathoracic lesions: comparison between coaxial and single needle technique. *Eur J Radiol* 2012;81:e712–6.
- [35] Shepherd RW. Bronchoscopic pursuit of the peripheral pulmonary lesion: navigational bronchoscopy, radial endobronchial ultrasound, and ultrathin bronchoscopy. *Curr Opin Pulm Med* 2016;22:257–64.
- [36] Chen A, Chenna P, Loiselle A, et al. Radial probe endobronchial ultrasound for peripheral pulmonary lesions: a 5-year institutional experience. *Ann Am Thorac Soc* 2014;11:578–82.
- [37] Walsh CJ, Sapkota BH, Kalra MK, et al. Smaller and deeper lesions increase the number of acquired scan series in computed tomography-guided lung biopsy. *J Thorac Imaging* 2011;26:196–203.