

Original Article

Single stage transforaminal retrojugular tumor resection: The spinal keyhole for dumbbell tumors in the cervical spine

Lukas Bobinski, Yves Henchoz, Kishore Sandu¹, John Michael DuffNeurosurgical Service, Department of Clinical Neurosciences, University of Lausanne Hospital, ¹Department of Ear, Nose, and Throat, University of Lausanne Hospital, CHUV, Lausanne, SwitzerlandE-mail: Lukas Bobinski - lukasbobinski@yahoo.com; Yves Henchoz - yves.henchoz@chuv.ch; Kishore Sandu - kishore.sandu@chuv.ch;*John Michael Duff - johnmichael.duff@gmail.com

*Corresponding author

Received: 30 September 14 Accepted: 06 January 15 Published: 01 April 15

This article may be cited as:Bobinski L, Henchoz Y, Sandu K, Duff JM. Single stage transforaminal retrojugular tumor resection: The spinal keyhole for dumbbell tumors in the cervical spine. *Surg Neurol Int* 2015;6:53.Available FREE in open access from: <http://www.surgicalneurologyint.com/text.asp?2015/6/1/53/154453>

Copyright: © 2015 Bobinski L. This is an open-access article distributed under the terms of the Creative Commons Attribution License, which permits unrestricted use, distribution, and reproduction in any medium, provided the original author and source are credited.

Abstract

Background: Dumbbell tumors are defined as having an intradural and extradural component with an intermediate component within an expanded neural foramen. Complete resection of these lesions in the subaxial cervical spine is a challenge, and it has been achieved through a combined posterior/anterior or anterolateral approach. This study describes a single stage transforaminal retrojugular (TFR) approach for dumbbell tumors resection in the cervical spine.

Methods: This is a retrospective review of a series of 17 patients treated for cervical benign tumors, 4 of which were “true” cervical dumbbell tumors operated by a simplified retrojugular approach. The TFR approach allows a single stage gross total resection of both the extraspinal and intraspinal/intradural components of the tumor, taking advantage of the expanded neural foramen. All patients were followed clinically and radiologically with magnetic resonance imaging (MRI).

Results: Gross total resection was confirmed in all four patients by postoperative MRI. Minimal to no bone resection was performed. No fusion procedure was performed and no delayed instability was seen. At follow up, one patient had a persistent mild hand weakness and Horner's syndrome following resection of a hemangioblastoma of the C8 nerve root. The other three patients were neurologically normal.

Conclusions: The TFR approach appears to be a feasible surgical option for single stage resection in selective cases of dumbbell tumors of the cervical spine.

Key Words: Cervical spine, dumbbell tumors, transforaminal retrojugular approach

Access this article online**Website:**www.surgicalneurologyint.com**DOI:**

10.4103/2152-7806.154453

Quick Response Code:

INTRODUCTION

Historically, the term “dumbbell” tumor was used to describe an intraextraspinal tumor of neural origin growing across a constricting anatomical space confined by the boundaries of the bony neural foramen and investing dural nerve root sleeve.^[6,11] The most common forms are benign nerve sheath tumors (schwannomas and

neurofibromas), although malignant transformation can rarely occur.^[23] However, the descriptive term “dumbbell” has been widened to include heterogeneous tumors of vascular, dural, bone as well as neural origin such as hemangioblastomas, meningiomas, neuroblastomas, giant cell tumors, and gangliogliomas.^[1,3,8,10,12,13,16,18,19,21,22] The common feature of “true dumbbell” tumors is an intradural component and an extradural/paraspinal

component connected across an expanded neural foramen. The majority of dumbbell tumors occur in the cervical spine.^[14,16,18,22] The usual clinical presentation is neck pain, radicular symptoms, and/or symptoms of spinal cord compression.^[13-16,18]

Nerve sheath tumors with at C1 and C2 root levels do not have a bony foramen, so the entire tumor is accessible through a standard posterior approach. Such tumors pose a different surgical challenge and are not considered here.

For the purpose of this study, we report single stage surgical resection of both intradural and extradural components of dumbbell tumors of the subaxial cervical spine in four patients through a transforaminal approach. As examples, the magnetic resonance imaging (MRI) findings of a patient with a predominantly intradural component and of another patient with predominantly extradural component are shown in [Figures 1 and 2], respectively.

MATERIALS AND METHODS

Following hospital ethics committee approval, a retrospective chart review was carried out. Between 2007 and 2013, 17 patients underwent retrojugular resection of laterally placed cervical spinal tumors. Among these were four “true” dumbbell tumors resected using a transforaminal retrojugular (TFR) approach. The lead surgeon was the same in all cases (JMD). Clinical and radiological presentation is outlined in Table 1. In all but one case [Figure 1], the extraspinal component was larger than the intraspinal component. The index neural foramen was expanded in all four patients [Table 1]. All patients were followed up clinically and radiologically [Table 2].

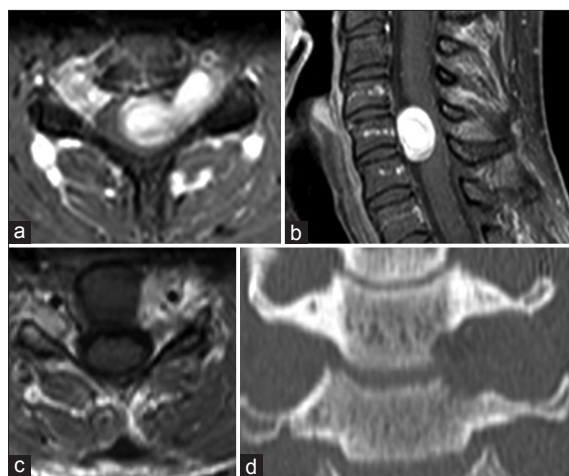

Figure 1 : Preoperative axial (a) and sagittal (b) MRI with contrast showing a predominantly intradural tumor component; postoperative MRI (c) (T1 with Gadolinium) showing a gross total resection through the expanded C5 foramen; coronal CT (d) showing the expanded C5 foramen (patient 1)

Surgical technique

A skin incision is taken along the anterior border of the sternocleidomastoid (SCM) muscle. A subplatysmal flap is raised anteriorly until the midline and posteriorly up to the trapezius. The SCM is mobilized to expose the carotid sheath, and superiorly, the spinal accessory nerve. The inferior belly of omohyoid is incised as posteriorly as possible and mobilized antero-superiorly up to its insertion on the hyoid bone, for later use as a vascularized muscle flap for dural closure. The internal jugular vein (IJV) is skeletonized and mobilized along with the vagus nerve. The transverse cervical artery, scalene muscles, phrenic nerve, and trunks of the brachial plexus are identified. The VI segment of vertebral artery (VA) is identified, and controlled with vessel loops, but is not mobilized or transposed.

For the tumor resection, standard microsurgical technique is used to internally debulk the extraspinal tumor component and amputate it at the neural foramen. The distal parent nerve root is divided. The tumor mass is followed through the expanded neural foramen and intradural portion is resected with division of the proximal parent root/fascicle. The foramen can be surgically enlarged (patient 4). The overlying VA is protected with a small spatula during bone drilling. Final transforaminal tumor resection inevitably results in a gush of cerebrospinal fluid (CSF). Dural closure is performed with local vascularized omohyoid or SCM flaps sutured onto the dural sleeve of the neural foramen, and reinforced with a synthetic dural sealant (Duraseal®).

No fusion was performed in any patient.

RESULTS

Average clinical follow was 30 months (range 6–78 months) [Table 2]. Duration of surgery ranged from 185 to 416 min (average 306 min). The perioperative bleeding ranged from 100 to 400 ml (average 250 ml). Patients were discharged home on day 5 (3 patients) and day 12 (patient 2) of their hospitalization. Gross total resection (GTR) was confirmed by in all four patients by postoperative MRI.

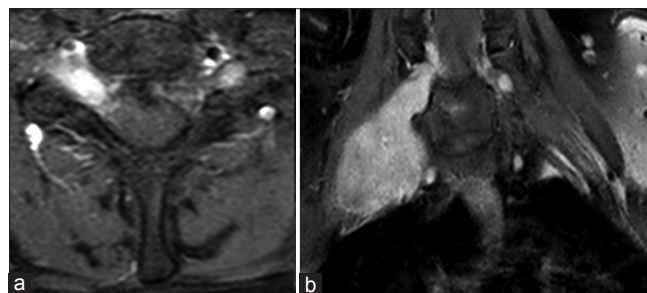


Figure 2 : Preoperative axial (a) and coronal (b) MRI with contrast showing a predominantly extradural tumor component (patient 3)

Table 1: Preoperative clinical and radiological data of patients undergoing dumbbell tumor resection using a TFR approach

Patient	Clinical and radiological data						Operative Data				
	Age (years)	Sex (M/F)	Preoperative symptoms	Pathology	MRI intradural max. tumor diam. (mm)	MRI paraspinal max. tumor diam. (mm)	MRI foramen diam. (mm)	Blood loss (ml)	Bone resection	Vascul. muscle patch	Resection
1	33	F	Cervical myelopathy; left arm weakness	Neurofibroma C5	19	8	12	400	No	Omo-hyoid	GTR
2	42	M	Cervical myelopathy; left arm weakness	MPNST C6	15	35	9	300	No	Omo-hyoid	GTR
3	39	F	Neck pain	Schwannoma C7	11	40	10	100	No	Omo-hyoid	GTR
4	31	M	C8 radiculo-pathy	Hemangioblastoma C8 R	8	23	11	200	Yes	SCM	GTR

TFR: Transforaminal retrojugular, MPNST: Malignant peripheral nerve sheath tumor, SCM: Sternocleidomastoid, GTR: Gross total resection

Table 2: Clinical and radiological follow-up data

Patient	Clinical data		Radiological data	
	Follow-up (months)	Follow-up symptoms	Follow-up (months)	Follow-up MRI finding
1	78	None	78	No recurrence
2	6	Palliative care for widespread CSF dissemination of the tumor, including Hydrocephalus, despite radiation and chemotherapy. Expired 9 months after surgery	4	Local recurrence and dissemination
3	24	None	24	No recurrence
4	13	Neuropathic pain; Rx with Lyrica; mild intrinsic hand weakness; persistent Horner's syndrome	13	No recurrence

CSF: Cerebrospinal fluid

Patient 1 had a delayed pseudomeningocele in the neck several weeks after surgery. In this case, the muscle flap had not been sutured in place, and was found to have displaced with a resultant CSF leak. The dural closure was successfully revised. Patient 2 succumbed to disseminated meningeal metastatic disease from a malignant peripheral nerve sheath tumor (MPNST) with hydrocephalus and multiple radiculopathies 9 months after surgery, despite radiotherapy and chemotherapy. Patient 4 had a persistent Horner's syndrome likely due to dissection and manipulation of the stellate ganglion, lying beneath the C8 tumor. He also had mild hand weakness and transient neuropathic pain treated with pregabalin. None of the three patients with benign tumors showed evidence of recurrence at last follow up [Table 2].

DISCUSSION

Spinal intradural tumors are rare with an incidence of 0.3–10/100,000.^[7,17,20] However, true dumbbell tumors with intradural–extradural/extraspinal growth pattern are rarer and occur in 15% of all cases.^[13,16,18,22] Tumor recurrence rate for these lesions has been reported to be 19.1% at 5 years and 43.4% after 10 years.^[16] The multi-compartment location of such tumors requires careful surgical planning to achieve GTR, watertight dural reconstruction, and avoidance of destabilizing bone

resection. All of these can be achieved by a single TFR approach.

Cervical dumbbell tumors are most commonly treated using a posterior laminectomy approach to access posterior or posterolaterally placed intradural tumors.^[13,16] For tumors extending through and beyond the intervertebral foramen, partial or complete facet resection is needed for complete resection leading to segmental instability.^[1,2,13-15,19] Proximal or distal control of the VA and its feeding branches is not possible, and may lead to extensive perioperative blood loss and VA sacrifice.^[13]

The anterolateral retrojugular approach described by George and co-workers allows single stage tumor resection without fusion.^[3-5,10,12,18,21] Mobilization and medial transposition of the sympathetic chain and the VA are necessary.^[5] Other anterolateral approaches require partial vertebral body resection for tumor exposure, with reconstruction and stabilization.^[13,15,19] Combined anterior/posterior approaches have also been described to achieve complete tumor excision.^[1,9]

The TFR approach is a simplification of the anterolateral retrojugular approach. Neither the sympathetic chain nor the VA is transposed. There is minimal to no bone resection. No fusion is required. Dural reconstruction is achieved using a novel local vascularized muscle flap.

The TFR approach exploits a surgical pathway created by the tumor. Early identification and control of the proximal VA in TFR is possible. It may decrease complications due to facetectomy and fusion.^[1,13,15,19] It may also decrease complications to postoperative CSF leak by the novel use of local vascularized muscle flaps.

CONCLUSIONS

The TFR approach is a feasible surgical option for resection of true dumbbell tumors of the cervical spine. The results in this small series are encouraging and comparable with those previously reported in the literature.^[1,13,16,18,23] The advantages are (i) Ready access to extradural and intradural tumor components by a single approach, (ii) direct access for proximal control of VA, (iii) no transposition of the VA or the sympathetic chain, (iv) minimal or no bone resection, (v) no additional stabilization procedure necessary, and (vi) easy access to local vascularized muscle flaps for dural closure.

We believe that the TFR approach can be a useful option for surgical treatment of cervical dumbbell tumors.

REFERENCES

- Asazuma T, Toyama Y, Maruiwa H, Fujimura Y, Hirabayashi K. Surgical strategy for cervical dumbbell tumors based on a three-dimensional classification. *Spine (Phila Pa 1976)* 2004;29:E10-4.
- Banczerowski P, Veres R, Vajda J. Modified surgical approach to cervical neurinomas with intraforaminal components: Minimal invasive facet joint sparing "open-tunnel" technique. *J Neurol Surg A Cent Eur Neurosurg* 2014;75:16-9.
- Barrey C, Kalamarides M, Polivka M, George B. Cervical dumbbell intra-extradural hemangioblastoma: Total removal through the lateral approach: Technical case report. *Neurosurgery* 2005;56:E625.
- Bruneau M, Cornelius JF, George B. Anterolateral approach to the V1 segment of the vertebral artery. *Neurosurgery* 2006;58 (4 Suppl 2):ONS-215-9.
- Bruneau M, Cornelius JF, George B. Anterolateral approach to the V2 segment of the vertebral artery. *Neurosurgery* 2005;57 (4 Suppl):S262-7.
- Eden K. The dumb-bell tumors of the spine. *Br J Surg* 1941;28:549-70.
- Fogelholm R, Uutela T, Murros K. Epidemiology of central nervous system neoplasms. A regional survey in Central Finland. *Acta Neurol Scand* 1984;69:129-36.
- Glasker S, Berlis A, Pagenstecher A, Vougioukas VI, Van Velthoven V. Characterization of hemangioblastomas of spinal nerves. *Neurosurgery* 2005;56:503-9.
- Habal MB, McComb JG, Shillito J Jr, Eisenberg HM, Murray JE. Combined posteroanterior approach to a tumor of the cervical spinal foramen. Technical note. *J Neurosurg* 1972;37:113-6.
- Hakuba A, Komiyama M, Tsujimoto T, Ahn MS, Nishimura S, Ohta T, et al. Transuncodiscal approach to dumbbell tumors of the cervical spinal canal. *J Neurosurg* 1984;61:1100-6.
- Heuer G. So-called hour-glass tumors of the spine. *Arch Surg* 1929;18:935-61.
- Iwasaki Y, Hida K, Koyanagi I, Yoshimoto T, Abe H. Anterior approach for dumbbell type cervical neurinoma. *Neurol Med Chir (Tokyo)* 1999;39:835-9.
- Jiang L, Lv Y, Liu XG, Ma QJ, Wei F, Dang GT, et al. Results of surgical treatment of cervical dumbbell tumors: Surgical approach and development of an anatomic classification system. *Spine (Phila Pa 1976)* 2009;34:1307-14.
- Jinnai T, Koyama T. Clinical characteristics of spinal nerve sheath tumors: Analysis of 149 cases. *Neurosurgery* 2005;56:510-5.
- Kim JH, Han S, Kwon TH, Chung HS, Park YK. Surgical consideration of the intraspinal component in extradural dumbbell tumors. *Surg Neurol* 2008;70:98-103.
- Klekamp J, Samii M. Surgery of spinal nerve sheath tumors with special reference to neurofibromatosis. *Neurosurgery* 1998;42:279-89.
- Kurland LT. The frequency of intracranial and intraspinal neoplasms in the resident population of Rochester, Minnesota. *J Neurosurg* 1958;15:627-41.
- Lot G, George B. Cervical neuromas with extradural components: Surgical management in a series of 57 patients. *Neurosurgery* 1997;41:813-20.
- McCormick PC. Surgical management of dumbbell tumors of the cervical spine. *Neurosurgery* 1996;38:294-300.
- Newton HB, Newton CL, Gatens C, Hebert R, Pack R. Spinal cord tumors: Review of etiology, diagnosis, and multidisciplinary approach to treatment. *Cancer Pract* 1995;3:207-18.
- O'Toole JE, McCormick PC. Midline ventral intradural schwannoma of the cervical spinal cord resected via anterior corpectomy with reconstruction: Technical case report and review of the literature. *Neurosurgery* 2003;52:1482-5.
- Ozawa H, Kokubun S, Aizawa T, Hoshikawa T, Kawahara C. Spinal dumbbell tumors: An analysis of a series of 118 cases. *J Neurosurg Spine* 2007;7:587-93.
- Seppala MT, Haltia MJ. Spinal malignant nerve-sheath tumor or cellular schwannoma? A striking difference in prognosis. *J Neurosurg* 1993;79: N528-32.