



Original article

Intra-articular lidocaine versus intravenous sedative and analgesic for reduction of anterior shoulder dislocation



Parvin Kashani ^a, Fatemeh Asayesh Zarchi ^{a, *}, Hamid Reza Hatamabadi ^b, Abbas Afshar ^c, Marzieh Amiri ^d

^a Department of Emergency Medicine, Lohmane Hakim Hospital, Shahid Beheshti University of Medical Sciences, Tehran, Iran

^b Safety Promotion & Injury Prevention Research Center, Shahid Beheshti University of Medical Sciences, Tehran, Iran

^c Department of Management, Mofateh Hospital, Shahid Beheshti University of Medical Sciences, Tehran, Iran

^d Department of Emergency Medicine, Shahid Beheshti Hospital, Guilan University of Medical Sciences, Anzali, Iran

ARTICLE INFO

Article history:

Received 10 November 2015

Received in revised form

3 February 2016

Accepted 10 April 2016

Available online 9 May 2016

Keywords:

Shoulder dislocation

Lidocaine

Intra-articular

Pain management

Emergency department

ABSTRACT

Objective: This prospective clinical trial was performed to compare the safety and efficiency of intra-articular lidocaine (IAL) versus intravenous sedative and analgesic (IVSA) in reduction of anterior shoulder dislocation.

Materials and methods: Patients with anterior shoulder dislocation were randomly divided into 2 groups to receive IAL and IVSA. One group patients received an intravenous dose of 0.05 mg/kg midazolam and 1 µg/kg fentanyl, while the other group received 20 mL intra-articular lidocaine (1%). Patient satisfaction (via a standard 5-choice questionnaire), pain score (based on visual analog scale ranging from 0 to 10 points), comfort reduction, recovery time, and side effects were recorded and compared between the two groups before, during and after the reduction procedure.

Results: Totally 104 patients with acute anterior shoulder dislocation and the mean age of 28.75 ± 7.24 years were included (86.5% male). There was no statistically significant difference between IAL and IVSA groups regarding age ($p = 0.45$) and gender ($p = 0.25$). A total of forty-seven (45.2%) patients, distributed in both groups, had a history of anterior shoulder dislocation. A significant difference was seen with regard to diminished pain intensity during reduction in IAL group ($p < 0.001$); Complications including nausea, apnea, hypoxia and headache were only observed in IVSA group, and there was no adverse effect in IAL group; increased patient satisfaction in IVSA group ($p = 0.007$); similar success rate at first attempt of reduction in both groups, and a shorter time to discharge in IAL group ($p < 0.001$).

Conclusion: It seems that the use of intra-articular lidocaine for reduction of anterior shoulder dislocation is effective, safe, and time saving in the emergency department and has few complications. It can be considered as the first line analgesia in managing anterior shoulder dislocation.

Copyright © 2016 The Emergency Medicine Association of Turkey. Production and hosting by Elsevier B.V. on behalf of the Owner. This is an open access article under the CC BY-NC-ND license (<http://creativecommons.org/licenses/by-nc-nd/4.0/>).

1. Introduction

Shoulder dislocation is the most common large joint dislocation which is classified to anterior, posterior, and inferior types.¹ Anterior shoulder dislocation accounts for approximately 95% of

all shoulder dislocations, that are commonly presented to emergency department (ED).^{2–4} According to the epidemiological data reported from different countries, the incidence of shoulder dislocation is 1–1.7 per 1,00,000 population a year.⁴ Male sex, white race, and an age less than thirty years have been introduced as significant demographic risk factors for shoulder injury.⁵ Selection of ideal and relatively pain-free reduction method could play a key role in management of shoulder dislocations. Intravenous sedation-analgesia (IVSA) is commonly applied for reduction in EDs and provide a trouble-free condition.^{1,4,6–11} Studies showed that IVSA can trigger some side effects such as central nervous system and cardio-respiratory depression, which requires close

* Corresponding author. Department of Emergency Medicine, Lohmane Hakim Hospital, Shahid Beheshti University of Medical Sciences, Tehran, Iran. Tel.: +98 9133567318.

E-mail address: dr_asayesh_f@yahoo.com (F. Asayesh Zarchi).

Peer review under responsibility of The Emergency Medicine Association of Turkey

patient monitoring and medical management.^{4,6} Moreover, other side effects including nausea, vomiting, and post reduction lethargy may also occur.^{4,6} The use of pain relief method for appropriate management of shoulder dislocation was first described by Lippitt et al who used intra-articular lidocaine (IAL) to ease shoulder reduction and compared it to intravenous narcotic sedation.¹² Meanwhile, IAL is recommended to be used as a probable alternative to IVSA and not the first choice, especially for patients with contraindication to IVSA that is proposed previously.^{2,4,6,13} On the other hand, prior reviews had controversies about significant differences between IAL and IVSA in this regard.¹³ Despite opposing results in this context, favorable impacts of lidocaine should not be ignored, which include adequate muscle relaxation, less pain and cost, prompt patient discharge, adequacy for patients in whom intravenous access is not easily obtainable, and not needing oxygen saturation monitoring and electrocardiography during or after reduction.^{1,4,10,14} Few prospective controlled trials have compared IAL and IVSA from the standpoint of effectiveness, safety, time taken, ED overcrowding, and especially pain intensity in acute anterior shoulder dislocation patients in Iran.¹⁵ Therefore, this prospective clinical trial was performed to compare the safety and efficiency of intra-articular lidocaine (IAL) versus intravenous sedative and analgesic (IVSA) in reduction of anterior shoulder dislocation.

2. Methods

2.1. Study design

This clinical trial was performed at the emergency department of Haft-e-Tir and Imam Hossein Hospitals (Tehran, Iran) between autumn 2012 and winter 2013. All patients with 18–40 years old who had acute anterior shoulder dislocation were considered eligible. Exclusion criteria were as follow: American society of anesthesia (ASA) physical status of ≥ 3 , anesthetics allergy, pregnancy, bone fractures on x-ray, signs of increased intracranial pressure, having cognitive disorders, using analgesics including sedatives, and consumption of narcotics, alcohol, psychotropic drugs or active psychotic drugs in the previous two weeks.¹⁶

2.2. Ethical issues

This study was permitted by the ethics committee of the Shahid Beheshti University of Medical Sciences. Eligible patients were enrolled after signing the informed consent. The Declaration of Helsinki ethical principles were followed and respected throughout the study.

2.3. Population and setting

Patients were randomized into two groups of IVSA and IAL, using an online random number generator according to a statistical consultant for the project. Before sedation, all patients underwent hemodynamic monitoring and continuous pulse oximetry using 3 L of nasal oxygen. IVSA group received an intravenous dose of 0.05 mg/kg midazolam and 1 μ g/kg fentanyl and after achievement of proper sedation, underwent reduction. The second group were injected with 20 mL of 1% lidocaine, during 30 s, using an 18–20 gage 0.7 \times 40-mm needle, into the shoulder joint about 2 cm below the lateral border of the acromion, towards the glenoid cavity under sterile conditions according to Gleeson and Tamaoki studies.^{1,7} In IAL group, reduction was performed 15 min after intra-articular injection. Leidelmeier method¹⁷ (advocated gentle, smooth traction to the arm while externally rotating it) was employed for reduction in both groups. The whole

procedure and maneuvers were performed by an emergency medicine specialist. Neurovascular examination was done before and after reduction. Patient satisfaction (using a 5-choice questionnaire), pain measurement (using a visual analog scale ranging from 0 to 10 points), recovery time, and side effects during and after reduction were assessed and compared between the two groups. After reduction in IVSA group, patients were evaluated for level of consciousness and hemodynamic state. A structured assessment known as the Aldrete Score^{18,19} was used to assess patient recovery and safety for discharge. Return to a pre-procedure baseline score or a score of at least 18 indicates that the patient is safe for discharge. In both group, patients were asked about the intensity of pain they felt during and after reduction. Duration of admission to discharge was also assessed in each group. If 2 attempts at reduction by emergency medicine specialists failed, reduction was considered unsuccessful leading to admission for reduction under general anesthesia. All patients in both groups underwent control x-ray to verify complete reduction. If the patients had no problem, they were discharged from the ED. All patients were followed 2 weeks after reduction and their outcome, shoulder range of motions, and complications such as axillary nerve injury and rupture of rotator cuff were evaluated and recorded.

2.4. Statistical analysis

All analyzes were performed using SPSS 20 statistical software (SPSS Inc, Chicago, IL, USA). Quantitative variables are shown as mean, median, frequency and standard deviation and qualitative variables as percentage. To compare the results between the two groups, T-test, Mann–Whitney, Pearson's chi-square and Fisher's exact tests were used. Finally, to eliminate the possible confounding effects, regression methods such as analysis of covariance and logistic regression were performed. P-value < 0.05 was considered significant.

3. Results

Totally 104 patients with acute anterior shoulder dislocation and the mean age of 28.75 ± 7.24 years were included (86.5% male). Twenty six (25%) patients had acute anterior shoulder dislocation caused by multiple traumas. The most common reason for anterior shoulder dislocation in IAL and IVSA groups were spontaneous (50%) and falling (42.3%), respectively. Forty seven (45.2%) patients had a history of anterior shoulder dislocation. The demographic features of patients are shown in Table 1.

No significant difference was seen in average pain intensity before ($p = 0.093$) and after ($p = 0.235$) the reduction in the 2 groups. However, mean pain intensity during reduction in IVSA group was significantly higher than IAL group ($p < 0.001$). Table 2 and Fig. 1 compare pain intensity before, during and after reduction in the 2 groups.

Patient satisfaction in IVSA group was significantly higher than IAL group (p -value = 0.007). Adverse drug reactions were not observed in either group. Other complications including nausea, apnea, hypoxia and headache were only observed in IVSA group, the difference was statistically significant with regard to apnea and hypoxia appearance (both $p = 0.013$). Success rate at first attempt of reduction (73.1% of patients) was similar distribution in both groups ($p = 0.038$). However, success rate at second attempt was higher (25%) in IAL group compared to IVSA (15.4%). Duration time from admission until discharge was significantly longer in IVSA group ($p < 0.001$). Outcome measures are included in Table 3.

Unsuccessful reduction led to admission of 7 (6.7%) cases in orthopedic ward for reduction under general anesthesia. On follow

Table 1
Demographic data of patients and comparison of intra-articular lidocaine (IAL) with intravenous analgesia sedation (IVSA).

Patients and variables	IAL	IVSA	Total	P-value
Number of cases (%)	52	52	104	
Mean age (range) in years ± SD	28.18 ± 7.85	29.9 ± 6.64	28.75 ± 7.24	0.446
Gender (%)				
Male	47 (90.4)	43 (82.7)	90 (86.5)	0.250
Female	5 (9.6)	9 (17.3)	14 (13.5)	
Traumatic causes (%)				
Spontaneous	26 (50)	20 (38.5)	46 (44.2)	0.508
Falling	15 (28.8)	22 (42.3)	37 (35.6)	
Motor vehicle collision	3 (5.8)	2 (3.8)	5 (4.8)	
Pedestrian car accident	5 (9.6)	3 (5.8)	8 (7.7)	
Car accident	3 (5.8)	5 (9.6)	8 (7.7)	
Multiple trauma				
Present	14 (26.9)	12 (23.1)	26 (25)	0.651
Absent	38 (73.1)	40 (76.9)	78 (75)	
History of acute anterior shoulder dislocation				
Present	20 (38.5%)	27 (51.9%)	47 (45.2)	0.168
Absent	32 (61.5%)	25 (48.1%)	57 (54.8)	
Injury in other sites of the body				
Chest	11 (21.2)	10 (19.2)	21 (20.2)	0.807
Head	12 (23.1)	8 (15.4)	20 (19.2)	0.320
Abdomen	2 (3.8)	4 (7.7)	6 (5.8)	0.339
History of drug sensitivity				
Present	3 (5.8)	1 (1.9)	4 (3.8)	0.309
Absent	49 (94.2)	51 (98.1)	100 (96.2)	

Table 2
Comparison of pain intensity according to VAS scales before, during and after the reduction.

Pain intensity	IAL	IVSA	P-value	Total
Before reduction	8.38 (1.46)	7.80 (1.62)	0.093	8.096 (1.56)
During reduction	0.29 (0.67)	2.92 (1.82)	<0.001	1.61 (1.55)
After reduction	1.05 (1.24)	1.0 (1.86)	0.235	1.03 (1.55)

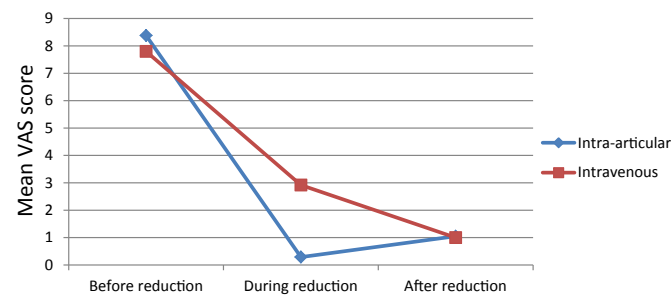


Fig. 1. Comparison of pain intensity according to VAS scales before, during and after reduction.

up 2 weeks after reduction, none of the patients experienced recurrent shoulder dislocation or drop arm. Complication was reported only in one case of IVSA group regarding range of motion restriction (poor abduction) which was not significant and resolved spontaneously later. No major complication was observed in IAL group ($p = 0.5$).

4. Discussion

Findings of this study showed significant difference in diminished pain intensity during reduction in IAL group; increased patient satisfaction in IVSA group; similar success rate at first attempt of reduction in both groups, and a shorter time to discharge in IAL group. Previously published studies have introduced several methods for reduction of shoulder dislocation paying more

Table 3
Outcome measures in intra-articular lidocaine (IAL) and intravenous analgesia sedation (IVSA) groups.

Outcome measures	IAL	IVSA	P-value	Total
Number of cases (%)				
Mean pain intensity ± SD				
Before reduction	8.38 ± 1.46	7.80 ± 1.62	0.093	8.096 ± 1.56
During reduction	0.29 ± 0.67	2.92 ± 1.82	<0.001	1.61 ± 1.9
After reduction	1.05 ± 1.24	1.0 ± 1.86	0.235	1.03 ± 1.55
Patient satisfaction				
Complete dissatisfaction	9 (17.3)	0 (0)	0.007	9 (8.7)
Partial dissatisfaction	4 (7.7)	1 (1.9)		5 (4.8)
Admissible	5 (9.6)	3 (5.8)		8 (7.7)
Partly satisfied	14 (26.9)	16 (30.8)		30 (28.8)
Quite satisfied	20 (38.5)	32 (61.5)		52 (50)
Complication				
Nausea	0 (0)	2 (3.8)	0.248	2 (1.9)
Apnea	0 (0)	6 (11.5)	0.013	6 (5.8)
Hypoxia	0 (0)	5 (9.6)	0.028	5 (4.8)
Headache	0 (0)	2 (3.8)	0.248	2 (1.9)
Success rate of reduction				
First time	38 (73.1)	38 (73.1)	0.038	76 (73.1)
Second time	13 (25)	8 (15.4)		21 (20.2)
Unsuccessful reduction	1 (1.9)	6 (11.5)		7 (6.7)
Time to discharge (minutes)				
Early (Before 30 min)	31 (59.6)	10 (19.2)	<0.001	41 (39.4)
Late (After 30 min)	21 (40.4)	42 (80.8)		63 (60.6)

Data in bold are significant.

attention to anterior form due to its higher incidence. Some of them have compared IAL and IVSA, sedative effect of inhalational and intra-venous methods and also assessed different maneuvers for reduction of acute anterior shoulder dislocation.^{2,4,6,14,20–23} Among them, more attention was paid to IAL use compared to IVSA. Results of a prospective randomized study comparing IAL with IVSA by Kosnik et al showed no statistically significant difference between the 2 groups for reduction of acute anterior shoulder dislocation regarding mean pain and ease of reduction scores, or success rates.²⁴ In our study, mean pain intensity during reduction in IAL group was significantly lower than IVSA, indicating that IAL could be preferable to IVSA for reduction of acute anterior shoulder dislocation. It should be mentioned that when

patient satisfaction about the whole process was assessed, it seems that the patients prefer to be unconscious during this procedure, so they were more satisfied with IVSA. But when pain measurement was assessed and patients were asked directly only about their pain score, it was revealed less pain intensity during procedure in IAL group. Our results differ from those reported by Kosnik et al; however, other studies have also indicated the superiority of IAL to IVSA with regard to successful reduction rate. In study comparing IAL with IVSA performed by Lippitt et al, IAL group had a 100% success rate compared to 75% in IVSA.¹² In contrast to Suder et al study that reported high success reduction rate using IAL and patient satisfaction using both IAL and IVSA, in the present study, patient satisfaction rate was higher in IVSA group.²⁵ In another study performed by Matthews et al good reduction rates for both methods, and higher ease of reduction rate in IAL method were reported, which is consistent with our study.²⁶ In a systematic review performed by Fitch et al, use of IAL was recommended as the first line of acute anterior shoulder dislocation therapy due to safety, effectiveness, and being time saving.² The results of their study are similar to our study, which found that IAL is a time saving method for reduction of acute anterior shoulder dislocation. In this study, we found the same results regarding the significantly lower complication rate and length of stay in IAL group compared to IVSA. On the other hand, we did not assess costs between the 2 groups, which needs to be evaluated in future studies. Data published by Hames et al regarding more successful closed reduction in IAL group compared to IVSA was in contrast to our study.²⁰ However, we obtained similar results in terms of no report of complications in either group during reduction and within 2 weeks. In recently published studies in 2014, one showed that IAL is safer compared to IVSA but both have a similar efficacy for manual closed reduction of acute anterior shoulder dislocation and the other showed effective pain reduction and ease of reduction in IAL injection.^{27,28} Taken together, most studies have suggested that IAL is a good alternative to IVSA for safe, effective, and relatively painless reduction and quick discharge of patients.

5. Conclusion

It is likely that use of IAL for reduction of anterior shoulder dislocation is effective, safe and time saving in the emergency department and has few complications. We can also conclude that it could be used for patients in whom IVSA is not desired, such as pregnant women and patients with multiple traumas, and also it is practical where there is no access to monitoring facilities.

6. Limitations

There were some limitations in our study. Compared to other studies, our follow up time was short and only limited to 2 weeks. Although uncommon, infection, chondrolysis and impingement syndrome are possible complication of such injections. Therefore, it is suggested to design studies in which all patients could be followed for a longer time and adverse effects. Furthermore, IAL therapy was carried out by emergency department physicians who were expert in this field, and we could not compare the reduction results between them and general physicians. There are too many patients with recurrent shoulder dislocation which means reduction would be easier. If this study will be perform on patients with first time dislocation may achieve different results.

Financial disclosure

All authors declare that there is no conflict of interest in this study.

Funding/support

This study was performed with a grant of Loghmane Hakim Research and Development Center.

Role of the sponsor

All authors declare that this study was conducted without any sponsors.

Author's contribution

All the authors have contributed to drafting/revising the manuscript, study concept, or design, as well as data interpretation.

Acknowledgment

We would like to express our special thanks to Dr. Alireza Baratloo, faculty member of Emergency Department in Shahid Beheshti University of Medical Sciences, who kindly help us preparing this manuscript. This article is part of Dr. Fatemeh Asayesh Zarchi thesis as an emergency medicine resident at Shahid Beheshti University of Medical Sciences.

References

1. Tamaoki MJ, Faloppa F, Wajnsztejn A, Archetti Netto N, Matsumoto MH, Belloti JC. Effectiveness of intra-articular lidocaine injection for reduction of anterior shoulder dislocation: randomized clinical trial. *Sao Paulo Med J*. 2012;130:367–372. PubMed PMID: 23338733. Epub 2013/01/23. eng.
2. Fitch RW, Kuhn JE. Intraarticular lidocaine versus intravenous procedural sedation with narcotics and benzodiazepines for reduction of the dislocated shoulder: a systematic review. *Acad Emerg Med*. 2008 Aug;15:703–708. PubMed PMID: 18783486. Epub 2008/09/12. eng.
3. Sahin N, Ozturk A, Ozkan Y, Atici T, Ozkaya G. A comparison of the scapular manipulation and Kocher's technique for acute anterior dislocation of the shoulder. *Eklemler Hast Cerrahisi*. 2011;22:28–32. PubMed PMID: 21417983. Epub 2011/03/23. eng.
4. Wakai A, O'Sullivan R, McCabe A. Intra-articular lignocaine versus intravenous analgesia with or without sedation for manual reduction of acute anterior shoulder dislocation in adults. *Cochrane Database Syst Rev*. 2011;CD004919. PubMed PMID: 21491392. Epub 2011/04/15. eng.
5. Owens BD, Dawson L, Burks R, Cameron KL. Incidence of shoulder dislocation in the United States military: demographic considerations from a high-risk population. *J Bone Jt Surg Am*. 2009 Apr;91:791–796. PubMed PMID: 19339562. Epub 2009/04/03. eng.
6. Ng VK, Hames H, Millard WM. Use of intra-articular lidocaine as analgesia in anterior shoulder dislocation: a review and meta-analysis of the literature. *Fall Can J Rural Med*. 2009;14:145–149. PubMed PMID: 19835705. Epub 2009/10/20. eng.
7. Gleeson AP, Graham CA, Meyer AD. Intra-articular lignocaine versus Entonox for reduction of acute anterior shoulder dislocation. *Injury*. 1999 Aug;30:403–405. PubMed PMID: 10645353. Epub 2000/01/25. eng.
8. Kariman H, Majidi AR, Amini A, et al. Nitrous oxide/oxygen compared with fentanyl in reducing pain among adults with isolated extremity trauma: a randomized trial. *Emerg Med Australasia*. 2011;6:761–768.
9. Alimohammadi H, Azizi MR, Safari S, Amini A, Kariman H, Hatamabadi HR. Axillary nerve block in comparison with intravenous midazolam/fentanyl for painless reduction of upper extremity fractures. *Acta Medica Iran*. 2014;2:122–124.
10. Alimohammadi H, Baratloo A, Abdalvand A, Rouhipour A, Safari S. Effects of pain relief on arterial blood O2 saturation. *Trauma Mon*. 2014;19.
11. Agran PF, Winn DG, Anderson CL, Del Valle C. Family, social, and cultural factors in pedestrian injuries among Hispanic children. *Inj Prev*. 1998;4:188–193.
12. Lippitt SB, Kennedy JP, Thompson TR. Intraarticular lidocaine versus intravenous analgesia in the reduction of dislocated shoulders. *Orthop Trans*. 1991;15:804.
13. Ceccarelli E, Bondi R, Campi S. Evidence in orthopaedics: comparison of intra-articular lidocaine vs. intravenous analgesia and sedation for reduction of acute shoulder dislocation. *J Orthop Traumatology*. 2004;5:194–196.
14. Miller SL, Cleeman E, Auerbach J, Flatow EL. Comparison of intra-articular lidocaine and intravenous sedation for reduction of shoulder dislocations: a randomized, prospective study. *J Bone Jt Surg Am*. 2002 Dec;84-A:2135–2139. PubMed PMID: 12473699. Epub 2002/12/11. eng.
15. Moharari RS, Khademhosseini P, Espandar R, et al. Intra-articular lidocaine versus intravenous meperidine/diazepam in anterior shoulder dislocation: a randomised clinical trial. *Emerg Med J*. 2008;25:262–264.

16. Miller SL, Cleeman E, Auerbach J, Flatow EL. Comparison of intra-articular lidocaine and intravenous sedation for reduction of shoulder dislocations. *J Bone & Jt Surg.* 2002;84:2135–2139.
17. Leidelmeier R. External rotation method of shoulder dislocation reduction. *Ann Emerg Med.* 1981;10:228.
18. Phillips NM, Haesler E, Street M, Kent B. Post-anaesthetic discharge scoring criteria: a systematic review. *JBI Database Syst Rev Implement Rep.* 2011;9: 1680–1713.
19. Aldrete JA, Kroulik D. A postanesthetic recovery score. *Anesth Analgesia.* 1970;49:924–934.
20. Hames H, McLeod S, Millard W. Intra-articular lidocaine versus intravenous sedation for the reduction of anterior shoulder dislocations in the emergency department. *CJEM.* 2011 Nov;13:378–383. PubMed PMID: 22436475. Epub 2012/03/23. eng.
21. Moharari RS, Khademhosseini P, Espandar R, et al. Intra-articular lidocaine versus intravenous meperidine/diazepam in anterior shoulder dislocation: a randomised clinical trial. *Emerg Med J.* 2008 May;25:262–264. PubMed PMID: 18434457. Epub 2008/04/25. eng.
22. Mahshidfar B, Asgari-Darian A, Ghafouri HB, Ersoy G, Yasinzadeh MR. Reduction of anterior shoulder dislocation in emergency department; is entonox((R)) effective? *Bioimpacts.* 2011;1:237–240. PubMed PMID: 23678434. PubMed Central PMCID: 3648972. Epub 2011/01/01. eng.
23. Pishbin E, Bolvardi E, Ahmadi K. Scapular manipulation for reduction of anterior shoulder dislocation without analgesia: results of a prospective study. *Emerg Med Australas.* 2011 Feb;23:54–58. PubMed PMID: 21284814. Epub 2011/02/03. eng.
24. Kosnik J, Shamsa F, Raphael E, Huang R, Malachias Z, Georgiadis GM. Anesthetic methods for reduction of acute shoulder dislocations: a prospective randomized study comparing intraarticular lidocaine with intravenous analgesia and sedation. *Am J Emerg Med.* 1999 Oct;17:566–570. PubMed PMID: 10530535. Epub 1999/10/26. eng.
25. Suder PA, Mikkelsen JB, Hougaard K, Jensen PE. [Reduction of traumatic primary anterior shoulder dislocation under local analgesia] [Reponering af traumatisk primær anterior skulderluxation i lokal analgesi. dan]. *Ugeskr Laeger.* 1995 Jun 19;157:3625–3629. PubMed PMID: 7652983. Epub 1995/06/19.
26. Matthews DE, Roberts T. Intraarticular lidocaine versus intravenous analgesic for reduction of acute anterior shoulder dislocations. A prospective randomized study. *Am J Sports Med.* 1995 Jan-Feb;23:54–58. PubMed PMID: 7726351. Epub 1995/01/01. eng.
27. Jiang N, Hu YJ, Zhang KR, Zhang S, Bin Y. Intra-articular lidocaine versus intravenous analgesia and sedation for manual closed reduction of acute anterior shoulder dislocation: an updated meta-analysis. *J Clin Anesth.* 2014 Aug;26:350–359. PubMed PMID: 25066879. Epub 2014/07/30. eng.
28. Aronson PL, Mistry RD. Intra-articular lidocaine for reduction of shoulder dislocation. *Pediatr Emerg Care.* 2014 May;30:358–362. quiz 63-5. PubMed PMID: 24786994. Epub 2014/05/03. eng.