

Submitted: 18/06/2016

Accepted: 18/11/2016

Published: 19/11/2016

Congenital deformity of the distal extremities in three dogs

F. Di Dona^{1,*}, G. Della Valle¹, L. Meomartino², F. Lamagna¹ and G. Fatone¹

¹Department of Veterinary Medicine and Animal Productions, University of Napoli "Federico II", Italy

²Interdepartmental Center of Veterinary Radiology, University of Napoli "Federico II", Italy

Abstract

Congenital limb deformities are very rare conditions and the knowledge about etiology, pathogenesis, clinical presentation and treatment is still poor. Moreover, many defects are still not reported in veterinary literature. This report documents clinical and radiographic findings in three dogs with congenital deformity involving the distal extremities. Case 1 was affected with bilateral aphyalangia of the pedes, case 2 presented a combination of brachydactyly and syndactyly, whereas in case 3 a unilateral ectrodactyly was observed. To the authors' knowledge, brachydactyly, as well as aphyalangia, are very uncommon anomalies and have been rarely documented. Moreover, association between syndactyly and brachydactyly has still not been reported.

Keywords: Aphyalangia, Brachydactyly, Congenital deformity, Dog, Syndactyly.

Introduction

Congenital skeletal deformities, also referred as dysostoses, are defects arising from errors during development and characterized by abnormal growth of individual bones or part of bones (Noden and de Lahunta, 1985). Causes can be hereditary, or intrinsic (abnormal developmental process), and environmental, or extrinsic (interference with a normal developmental process), and result in failure of a mesenchymal bone model to form, failure of anlagen to properly transform into cartilage, or failure to convert cartilage into bone (Towle and Breur, 2004).

In dogs, limb formation is a complex process that occurs between the 3rd and 5th week of gestation and that includes limb bud formation, limb elongation, digit formation, and bone and joint formation (Evans, 1993). The morphologic developmental aberrations and genes responsible for these aberrations have still not been identified in canine and feline dysostoses. Differently, several environmental factors have also been implicated in development of dysostoses and may include: drugs, maternal diseases, faulty maternal diet, modified-live vaccines, radiations, and trauma to the mother, embryo, or placenta (Towle and Breur, 2004). Although a wide number of dysostoses have been previously reported in domestic animals (Towle *et al.*, 2007; Barrand and Cornillie, 2008; Lockwood *et al.*, 2009; Pisoni *et al.*, 2012; Macrì *et al.*, 2014; Di Dona *et al.*, 2016), comparing to human literature, in veterinary medicine, a complete description of congenital skeletal malformations is still lacking (Temtamy and Aglan, 2008). Moreover, a clear classification of the possible anomalies detectable does not exist.

Congenital anomalies of the distal extremities include: aphyalangia (A = without; Phalanx = phalanx), absence of a digit or of one or more phalanges (Macrì *et al.*, 2012); polydactyly (Polys = many; Dactylos = digit), increase number of digits (Jezyk, 1985); oligodactyly (Oligos = few), decreased number of digits (Clark *et al.*, 2001); adactyly, absence of one or more digits (Barrand and Cornillie, 2008); brachydactyly (Brachus = short), reduced size of digits (Hoskins, 1995); syndactyly (Syn = together), adjacent digits are fused and can be classified as simple or complex, incomplete or complete, and uncomplicated or complicated (Towle and Breur, 2004); ectrodactyly (Ektroma = abortion), is congenital digital cleft formation extending between the metacarpal bones (Towle and Breur, 2004).

The current knowledge about congenital limb deformity in dogs and cats is very poor, and many congenital defects are still not described. In order to improve the knowledge about congenital limb anomalies in dogs, the aim of this report is to describe the clinical and radiographic findings in three dogs affected by dysostoses of the distal extremities.

Case details

Case 1

A 2-year-old, male miniature poodle was referred for left hind limb lameness. The dog had a story of a previous lameness occurred when he was 4-month-old due to an abnormal digits development that determined a severe skin lesion; the owner referred that the dog's activity was restricted previously, but no improvement on the gait was noticed. Successively the dog was submitted to amputation of the most distal portions of the III and IV digits. The owner was not able to provide any radiographic images prior the surgery.

*Corresponding Author: Francesco Di Dona. Department of Veterinary Medicine and Animal Productions, University of Napoli "Federico II". Via Federico Delpino, 1 – 80138 Napoli, Italy. Email: francesco.didona@unina.it

Inspection of the feet revealed a malformation of both pedes characterized by the absence of all digits and the underdevelopment of the metatarsal pad. Palpation of the distal end of the left foot showed discomfort and eliciting pain, while on the right side the dog was unresponsive. The physical examination was within normal limits and did not reveal any additional abnormality. On radiographic examination, all of the digits had missing of some phalangeal bones: in the right foot, there was the absence of one row of phalangeal bones (II or III row) and the distal row was characterized by "V" shaped phalangeal bones; in the left foot, II and V digits presented a single "V" shaped phalangeal bone, whereas the III and IV digits presented just portion of the base, probably as consequence of the amputation (Fig. 1).

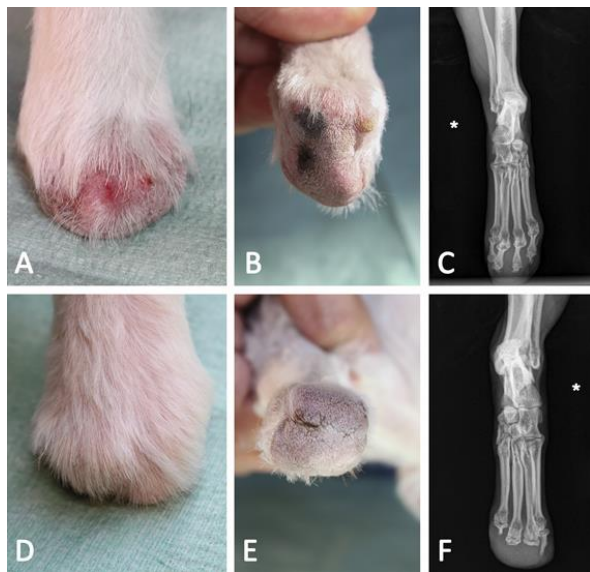


Fig. 1. Case 1: 2-year-old male miniature poodle. (A,B): Dorsal and plantar view of the right pes showing the absence of all the digits and all digital pads. (C): Dorso-plantar radiographic projection of the right pes [* = lateral side] showing the absence of all second phalangeal bones (brachymesophalangy). (D,E): Dorsal and plantar view of the left pes showing the absence of all the digits and all digital pads. (F): Dorso-plantar radiographic projection of the left pes showing the absence of the first and second phalangeal bones of the II and V digits, whereas the two intermediate digits present just a sketch.

Clinical and radiographic findings showed bilateral partial aphyalangia. The dog was managed by using orthopedic braces for protecting the pads.

The dog adapted to the use of protections and no evidence of skin lesion or lameness were detected after 2 months.

Case 2

A 3-month-old female English setter was referred with lameness and paw malformation to the left front limb. On clinical examination, the IV and V digits of the left

paw were shorter than normal. Moreover, the left shoulder joint showed local soft tissue swelling and flexion-extension maneuvers elicited pain. The physical examination was within normal limits and did not reveal any additional abnormality. On radiographic examination, the IV and V digits of the left paw had short metacarpi (i.e. only the bases were visible), both hypoplastic first phalanx and second phalanx of the V digit fused with the first phalangeal bone of the IV digit. The V digit was the most affected and just the III phalangeal bone was clearly identifiable, whereas the I phalangeal bone appeared as an isolated sketch, shorter and thinner than normal (Fig. 2).

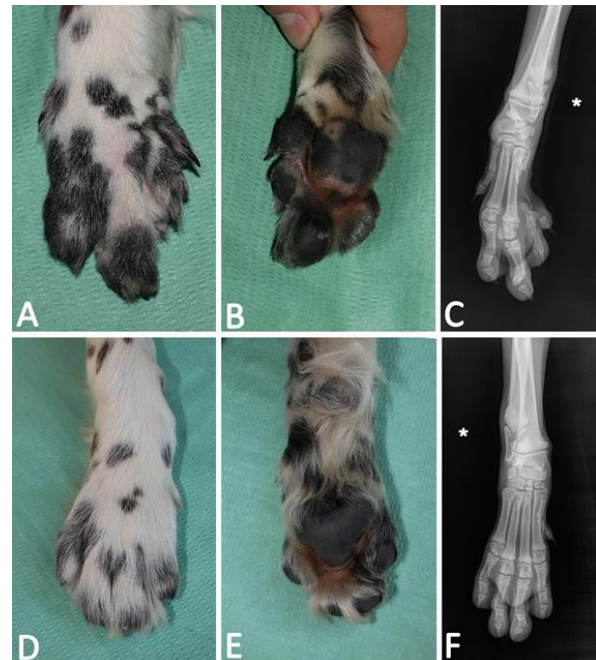


Fig. 2. Case 2: 3-month-old female English setter. (A,B): Dorsal and plantar view of the left manus showing an abnormal development and the evident shortening of the most lateral digits, however all the pads are present. (C): Dorso-plantar radiographic projection of the left manus [* = lateral side] showing short (or partially developed) IV and V metacarpal bones, hypoplastic phalanges of the V digit (just the III phalangeal bone was clearly identifiable, whereas the I phalangeal bone appeared as an isolated sketch, shorter and thinner than normal), synostosis between the I phalangeal bone of the IV digit and the II phalangeal bone of the V digit. (D,E,F): Dorsal and plantar view and dorso-plantar radiographic projection of the right manus showing a normal development.

Radiographic examination of the left shoulder joint revealed a severe deformity of the proximal humeral epiphysis characterized by an irregularly flattening and hypoplasia of the head; the shaft of the humerus showed a more pronounced sigmoid-shape and shortness compared to the contralateral. Moreover, the infraglenoid tubercle and the caudal end of the glenoid

cavity of the scapula were hypoplastic and sclerotic (Fig. 3).

Clinical and radiographic findings showed a partial brachydactyly and syndactyly, in association to avascular necrosis of the humeral head. No treatment was considered at time for managing the congenital deformity. Unfortunately, after the first evaluation, the follow up was lost.

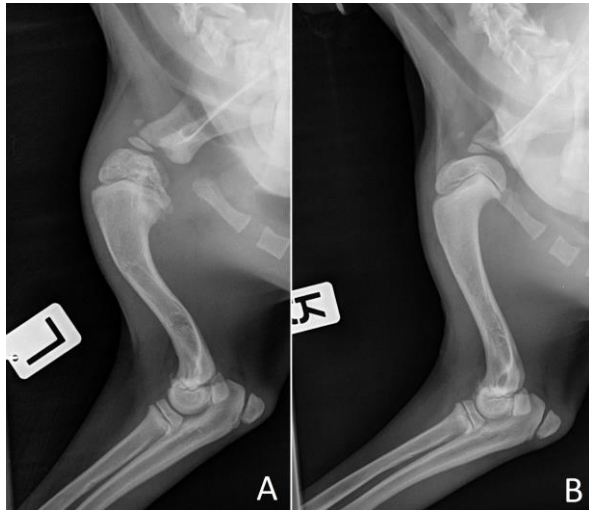


Fig. 3. Case 2: 3-month-old female English setter. (A): Lateral radiographic projection of the left shoulder joint. There is a severe deformity characterized by collapse and flattening of the proximal humeral epiphysis, as well as a more pronounced sigmoid-shape and shortness of the shaft of the humerus. Moreover, the infraglenoid tubercle and the caudal end of the glenoid cavity of the scapula were hypoplastic and sclerotic. (B): Lateral radiographic projection of the right shoulder joint. The anatomy is preserved and no abnormalities are detectable.

Case 3

A 3-years-old, male border collie was referred for the presence of an abnormal right front paw not associated to any lameness. Physical examination of the involved limb revealed a deformity of the paw characterized by the absence of the IV digit and the fusion of the II and the III digits which determined a “cleft hand aspect” (Fig. 4).

The physical examination was otherwise within normal limits and did not reveal any additional congenital anomaly. Dorso-palmar radiographic view of both manus were taken. On the right side, there was the absence of the IV digit distal to the base of the metacarpal bone, that, however, was thinner than normal, and the V digit showed a varus deviation. On the left side, the clinical unaffected paw, the radiographic examination revealed, as an incidental finding, a varus deviation of the last two phalangeal bones of the V digit (Fig. 5).

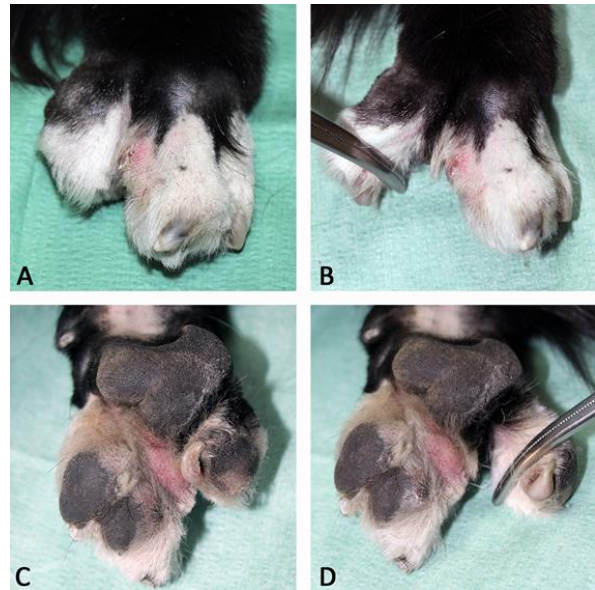


Fig. 4. Case 3: 3-year-old male Border collie. Dorsal (A,B) and palmar (C,D) macroscopic view of the right manus. Note the complete absence of the IV digit, visible in all the pictures, and the cutaneous syndactyly between the II and III digits, visible in pictures C and D.

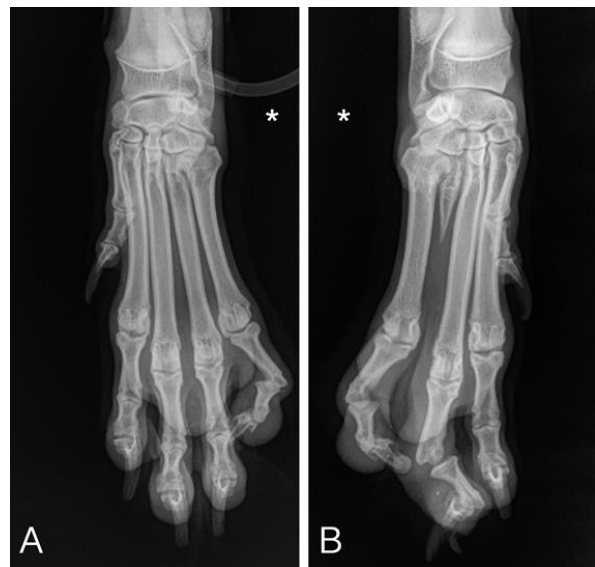

Fig. 5. Case 3: 3-year-old male Border collie. (A): Dorso-palmar radiographic projection of the left manus [* = lateral side] showing a normal development of all the digits and a varus deviation of the last two phalangeal bones of the V digit. (B): Dorso-palmar radiographic projection of the right manus showing the absence of the IV digits with a residual sketch of the relative metacarpal on the right side, as well as varus deviation of the last two phalangeal bones of the III and V digits.

Clinical and radiographic findings showed unilateral ectrodactyly. No treatment was instituted at time because the dog had no evidence of discomfort.

Discussion

The definition of limb malformations is quite complex since the lack of a uniform and consistent nomenclature. *Nomina Embryologica Veterinaria* (2006) represents the gold standard about the identification and classification of congenital anomalies in animals, but as previously indicated by Cornillie *et al.* (2004), it needs to be expanded and ambiguous definition should be agreed upon. Many terms used in human literature for the identification of specific dysostoses are still not mentioned in the official list. Moreover many affections can be distinctly identified and named, whereas many others cannot be easily classified and in such cases more than one term can be used for describing the same anomaly (Ogino, 2007).

Case 1 was clinically characterized by the involvement of both hind paws with the absence/shortening of all the digits, the global hypoplasia of the extremity and the cutaneous fusion; whereas, on radiographic examination, the lesions characterized by the absence of many phalanges bilaterally. In our opinion, the clinical presentation can be identified by using the term adactyly; however the radiographic findings led us to identify the affection with the term of partial aphyalangy. Case 2 was, clinically and radiographically, characterized by the involvement of the left front paw with the abnormal shortening of the IV and V digits. According to the definitions previously introduced, this congenital anomaly can be classified as brachydactyly on the basis of the clinical presentation, whereas, on radiographic examination, a combination of more anomalies including brachydactyly and syndactyly can be appreciated. The concurrent shoulder affection on the same side of the congenital defect could support a common origin of both lesions; however, a different and independent origin cannot be excluded.

Case 3 was clinically characterized by a V-shaped cleft situated in the centre of the right paw, the absence of the IV digit and cutaneous fusion of the II and III digits. Radiographically, the defects were less severe because clearly involved exclusively the IV digit that showed just a sketch of its proximal metacarpal. According to the definitions previously introduced, this affection can be classified as ectrodactyly based on the clinical presentation, but can be identified as oligodactyly, partial adactyly or aphyalangy based on radiographic aspect.

The use of some terms is still controversial and probably this can influence the modality of description and classification of many congenital anomalies. For example, the term brachydactyly has not been used frequently in animals and currently, in literature, there are few reports dealing with this anomaly. Towle and Breur (2004) in a review about dysostoses of the canine and feline appendicular skeleton provided a concise

guide to the clinical signs, diagnosis, treatment, prognosis, and heritability for each reported appendicular dysostosis; however, they did not report any mention to brachydactyly. On the other hand, in two guides on canine and feline congenital defects, where a schematic list of abnormalities is provided, the term brachydactyly is reported and defined as “reduced size and function of outer toes”, but the authors did not provide any reference about this congenital anomaly (Hoskins and Taboada, 1992; Hoskins, 1995). To our knowledge, in literature, this lesion has been documented in the dog exclusively by Hudson and Money (1995), reporting a case affected by abnormal shortening of the II and V digits bilaterally, identifying the affection as abnormal development of the metacarpal bones. Although the authors named the affection as brachymetacarpalia (Hudson and Money, 1995). In our opinion, and according to the human literature, it can be considered a particular form of brachydactyly (Schwabe and Mundlos, 2004).

Descriptions of adactyly and aphyalangy have been recently reported in both dogs and cats (Macrì *et al.*, 2011, 2012). These papers added contribution to the literature but different widely from the cases described here. Adactyly is defined partial when there is the absence of one to four digits and their metacarpals or metatarsals; whereas partial aphyalangy refers to the absence of one or more phalanges from one to four digits (Macrì *et al.*, 2012). According to this classification, case 1 was clearly affected by a bilateral partial aphyalangy of both pedes. Whereas case 3 could be classified as aphyalangy and not as adactyly because the metacarpal bone was present, even though only in part.

Ectrodactyly has been frequently reported and probably it is the most common malformation involving the manus in dogs (Pratschke, 1996; Barrand, 2004; Carvallo *et al.*, 2011). However, there are various types of ectrodactyly and some defects can differ much from others (Ogino, 2007). Some reports defined ectrodactyly as congenital digital cleft formation extending between the metacarpal bones, associated with hypoplasia or absence of one or more bones in the adjacent area of the distal portion of the limb, and characterized by severely hypoplastic or missing carpal bones (Carrig *et al.*, 1981; Towle and Breur, 2004).

The affection of the dog in case 3, showing clinically the typical “cleft-hand aspect” and the absence of one central digit, was classified as ectrodactyly, even though the carpus did not show any morphological alteration.

The knowledge about etiology, pathogenesis, presentation, and treatment of congenital skeletal defects in the dog is still weak. In the Online Mendelian Inheritance in Animals database (OMIA; <http://omia.org.au>), which offers the most recent

references about inheritable disorders in several animal species, has listed only the terms brachydactyly and ectrodactyly of all the aforementioned terms; but no specific reference about the genetic influence is reported in dogs. However, some authors investigated the inheritance of brachydactyly and allied abnormalities in rabbits, defining the types of deformities, the inheritance, and the embryological changes, concluding that this disorder is "a recessive mutant which reduces the size and function of the outside toes on the front and sometimes the hind feet" (Greene and Saxton, 1939; Green, 1957).

There is no general or specific treatment to manage a dog with a congenital limb deformity. The treatment must be planned based on the type and severity of the malformation, as well as if the lesion is separated or more structures are involved. Surgical management of ectrodactyly has been described in dogs; the main goal of the surgery is to provide metacarpal synostosis and recover the function of the manus (Innes *et al.*, 2001; Harasen, 2010; Pisoni *et al.*, 2014).

Differently, there is no mention in literature to the management of the other digital anomalies in dogs. In human medicine, the main goal of surgery is to improve child's ability to grasp and pinch. Surgery may also have an esthetic role making the child's hand look more typical. Possible options include skin separation in case of a combination with syndactyly, phalangeal transfer and bone lengthening. Prognosis for the brachydactylies, and terminal transverse defects in general, is strongly dependent on the nature of the lesion, and may vary from excellent to severely influencing hand function. If the limb defect is part of a syndrome, prognosis often depends on the nature of the associated anomalies (Temtamy and Aglan, 2008). In dogs, the surgical management of terminal transverse defects of the distal extremities is not considered in most of the cases, because the affection can be compatible with a normal life, as experienced in the cases presented here. Conservative management with the use of protective braces can avoid the secondary lesions that can be associated to the underdevelopment of the toes and the digital pads in particular.

This report enriches the available literature about congenital limb deformities, describing the features of rarely reported lesions and discussing about how difficult it is to know the correct identification and classification. We would like to underline the need for a standard resource of unequivocal and well-defined nomenclature. In our opinion many dysostoses are either not diagnosed or not reported and large-scale studies are necessary to understand the real prevalence of these affections in companion animals.

Conflict of interest

The authors declare that there is no conflict of interest.

References

- Barrand, K.R. 2004. Ectrodactyly in a West Highland white terrier. *J. Small Anim. Pract.* 45, 315-318.
- Barrand, K.R. and Cornillie, P. 2008. Bilateral hindlimb adactyly in an adult cat. *J. Small Anim. Pract.* 49, 252-253.
- Carrig, C.B., Wortman, J.A., Morris, E.L., Blevins, W.E., Root, C.R., Hanlon, G.F. and Suter, P.F. 1981. Ectrodactyly (split-hand deformity) in the dog. *Vet. Radiol. Ultrasound* 22, 123-144.
- Carvalho, F.R., Domínguez, A.S. and Morales, P.C. 2011. Bilateral ectrodactyly and spinal deformation in a mixed-breed dog. *Can. Vet. J.* 52, 47-49.
- Clark, R.M., Marker, P.C., Roessler, E., Dutra, A., Schimenti, J.C., Muenke, M. and Kingsley, D.M. 2001. Reciprocal mouse and human limb phenotypes caused by gain- and loss-of-function mutations affecting *Lmbr1*. *Genetics* 159, 715-726.
- Cornillie, P., Van Lancker, S. and Simoens, P. 2004. Two cases of Brachymelia in cats. *Anat. Histol. Embryo.* 33, 115-118.
- Di Dona, F., Murino, C., Della Valle, G. and Fatone G. 2016. Bilateral tibial agenesis and syndactyly in a cat. *Vet. Comp. Orthop. Traumatol.* 29, 277-282.
- Evans, H.E. 1993. Prenatal development. In Miller's anatomy of the dog, Ed., Miller, M.E.: W.B. Saunders, Philadelphia, pp: 32-97.
- Green, E.L. 1957. Mutant stocks of cats and dogs offered for research. *J. Hered.* 48, 56-58.
- Greene, H.S.N. and Saxton, J.A. 1939. Hereditary brachydactylia and allied abnormalities in the rabbit. *J. Exp. Med.* 69, 301-314.
- Harasen, G. 2010. Surgical management of ectrodactyly in a Siberian husky. *Can. Vet. J.* 51, 421-424.
- Hoskins, J.D. and Taboada, J. 1992. Congenital defects of the dog. *Compend. Contin. Educ. Vet.* 14, 873-897.
- Hoskins, J.D. 1995. Congenital defects of cats. *Compend. Contin. Educ. Vet.* 17, 385-405.
- Hudson, L.C. and Money, D.W. 1995. Symmetric Bilateral Brachymetacarpalia of a Dog. *Vet. Pathol.* 32, 187-189.
- Jezyk, P.F. 1985. Constitutional disorders of the skeleton in dogs and cats. In *Textbook of Small Animal Orthopaedics*, Eds., Newton C.D. and Nunamaker D.M.: International Veterinary Information Service, Ithaca, NY, USA, chapter 57.
- Innes, J.F., McKee, W.M., Mitchell, R.A.S., Lascelles, B.D.X. and Johnson, K.A. 2001. Surgical reconstruction of ectrodactyly deformity in four dogs. *Vet. Comp. Orthop. Traumatol.* 14, 201-209.
- Lockwood, A., Montgomery, R. and McEwen, V. 2009. Bilateral radial hemimelia, polydactyly and cardiomegaly in two cats. *Vet. Comp. Orthop. Traumatol.* 22, 511-513.

- Macrì, F., Ciotola, F., Rapisarda, G., Lanteri, G., Albarella, S., Aiudi, G., Liotta, L. and Marino, F. 2014. A rare case of simple syndactyly in a puppy. *J. Small Anim. Pract.* 55, 170-173.
- Macrì, F., Lanteri, G., Rapisarda, G. and Marini, F. 2012. Unilateral forelimb partial aphyalangia in a kitten. *J. Feline Med. Surg.* 14, 272-275.
- Macrì, F., Marino, F., Rapisarda, G., Lanteri, G. and Mazzullo, G. 2011. A case of unilateral pelvic limb adactyly in a puppy dog. *Anat. Histol. Embryol.* 40, 104-106.
- Noden, D.M. and de Lahunta, A. 1985. The embryology of domestic animals. *Developmental Mechanisms and Malformations*. Williams and Wilkins, Baltimore, MD, USA, pp: 196-210.
- Nomina Embryologica Veterinaria. 2006. (Second Edition). World Association of Veterinary Anatomists. Available at: (http://www.wavamav.org/Downloads/nev_2006.pdf).
- Ogino, T. 2007. Clinical features and teratogenic mechanisms of congenital absence of digits. *Dev. Growth Differ.* 49, 523-531.
- Pisoni, L., Cinti, F., Del Magno, S. and Joechler, M. 2012. Bilateral radial hemimelia and multiple malformations in a kitten. *J. Feline Med. Surg.* 14, 598-602.
- Pisoni, L., Del Magno, S., Cinti, F., Dalpozzo, B., Bellei, E., Cloriti, E. and Joechler, M. 2014. Surgical induction of metacarpal synostosis for treatment of ectrodactyly in a dog. *Vet. Comp. Orthop. Traumatol.* 27, 166-171.
- Pratschke, K. 1996. A case of ectrodactyly in a dog. *Irish Vet. J.* 49, 412-413.
- Schwabe, G.C. and Mundlos, S. 2004. Genetics of congenital hand anomalies. *Handchir. Mikrochir. Plast. Chir.* 36, 85-97.
- Temtam, S.A. and Aglan, M.S. 2008. Brachydactyly. *Orphanet J. Rare Dis.* 3, 15.
- Towle, H.A. and Breur, G.J. 2004. Dysostoses of the canine and feline appendicular skeleton. *J. Am. Vet. Med. Assoc.* 225, 1685-1692.
- Towle, H., Friedlander, K., Ko, R., Aper, R. and Breur, G. 2007. Surgical treatment of simple syndactylism with secondary deep digital flexor tendon contracture in a Basset Hound. *Vet. Comp. Orthop. Traumatol.* 20, 219-223.