

IMPG2-associated unilateral adult onset vitelliform macular dystrophy

Michalis Georgiou^{a,b,c}, Muhammad Z. Chauhan^a, Michel Michaelides^{b,c}, Sami H. Uwaydat^{a,*}

^a Jones Eye Institute, University of Arkansas for Medical Sciences, Little Rock, AR, USA

^b Moorfields Eye Hospital NHS Foundation Trust, City Road, London, EC1V 2PD, UK

^c UCL Institute of Ophthalmology, University College London, 11-43 Bath Street, London, EC1V 9EL, UK

ARTICLE INFO

Keywords:

Unilateral AVMD

IMPG2

Best disease

Unilateral vitelliform

Adult-onset vitelliform macular dystrophy

ABSTRACT

Purpose: To present a case of unilateral *IMPG2*-associated adult onset vitelliform macular dystrophy (AVMD).

Observations: A 68 year-old female presented with best corrected visual acuity (BCVA) of 20/20 and 20/40 for the right and left eye respectively. The patient had a left subfoveal yellow lesion on dilated fundus examination. Optical coherence tomography showed hyper-reflective material accumulation below the fovea in the left eye only. The patient was followed for 10 years with stable BCVA, and evolution of the subretinal vitelliform lesion to a “vitelliruptive” stage. The right eye did not develop vitelliform lesion. Genetic testing identified a heterozygous likely disease-causing variant in *IMPG2*; c.3423–7_3423–4del.

Conclusions and importance: This is the first report of unilateral AVMD associated with *IMPG2*, expanding the phenotypic spectrum of *IMPG2* retinopathy. We provide further evidence that *IMPG2* variants can cause both autosomal recessive rod-cone dystrophy and autosomal dominant AVMD, with implications for patient counselling.

1. Introduction

Adult vitelliform macular dystrophy (AVMD) is an adult onset, slowly progressive macular dystrophy, presenting with symmetric, yellowish, sub-retinal foveal deposits. *BEST1*, *PRPH2*, *IMPG1* and *IMPG2* variants can cause AVMD.¹ However, in most cases no responsible genetic cause is identified.² An appearance in keeping with AVMD can also be caused by non-inherited pathologies including age-related macular degeneration, acute exudative polymorphous vitelliform maculopathy (AEPVM), paraneoplastic cloudy vitelliform maculopathy, acute idiopathic maculopathy (AIM), resolved subretinal haemorrhage, and vitreomacular traction (VMT). Optical coherence tomography (OCT) best identifies the subretinal vitelliform lesion, which is associated with a high signal on FAF imaging.³ In rare instances unilateral cases of AVMD have been described, either associated with *BEST1* variants,^{4,5} or with negative genetic testing for *PRPH2* and *BEST1*.⁶ No case of unilateral disease has been described in association with *PRPH2*, *IMPG1* or *IMPG2* variants.

The Interphotoreceptor Matrix Proteoglycan 2 (*IMPG2*) gene encodes for a component of the extracellular matrix and facilitates retinal adhesion.⁷ *IMPG2* variants have been associated with autosomal recessive rod-cone dystrophy (AR RCD), autosomal dominant (AD) AVMD,

and recently reported in “Stargardt-like juvenile macular dystrophy” in a north Indian family.⁸ Macular focal retinal pigment epithelium thickening on OCT has been described in parents of affected children with AR RCD,⁹ as well as part of *IMPG1*- and *IMPG2*-associated AVMD.¹⁰ However, it remains unclear whether the same variants can cause AR RCD and AVMD.

Herein we report the first case of unilateral AVMD due to a heterozygous disease-causing *IMPG2* variant, with long term follow-up.

2. Case report

A 68 year-old white female found to have decreased best corrected visual acuity (BCVA) in the left eye on annual review by a local optometrist, was referred to a tertiary eye centre (Jones Eye Hospital, University of Arkansas Medical Science, Little Rock, AR) for further evaluation. The patient had an otherwise unremarkable medical history, no previous ocular history, and denied any family history of eye diseases.

BCVA was 20/20 and 20/30 for the right and left eye respectively, not improving with pinhole or refraction. Intraocular pressure was 15/16 mmHg. Confrontational visual fields and ocular mobility were normal. Examination of the anterior segment was remarkable only for

* Corresponding author. Harvey and Bernice Jones Eye Institute, University of Arkansas for Medical Sciences, 4105 Outpatient Circle, Little Rock, AR, 72205, USA.
E-mail address: shuwaydat@uams.edu (S.H. Uwaydat).

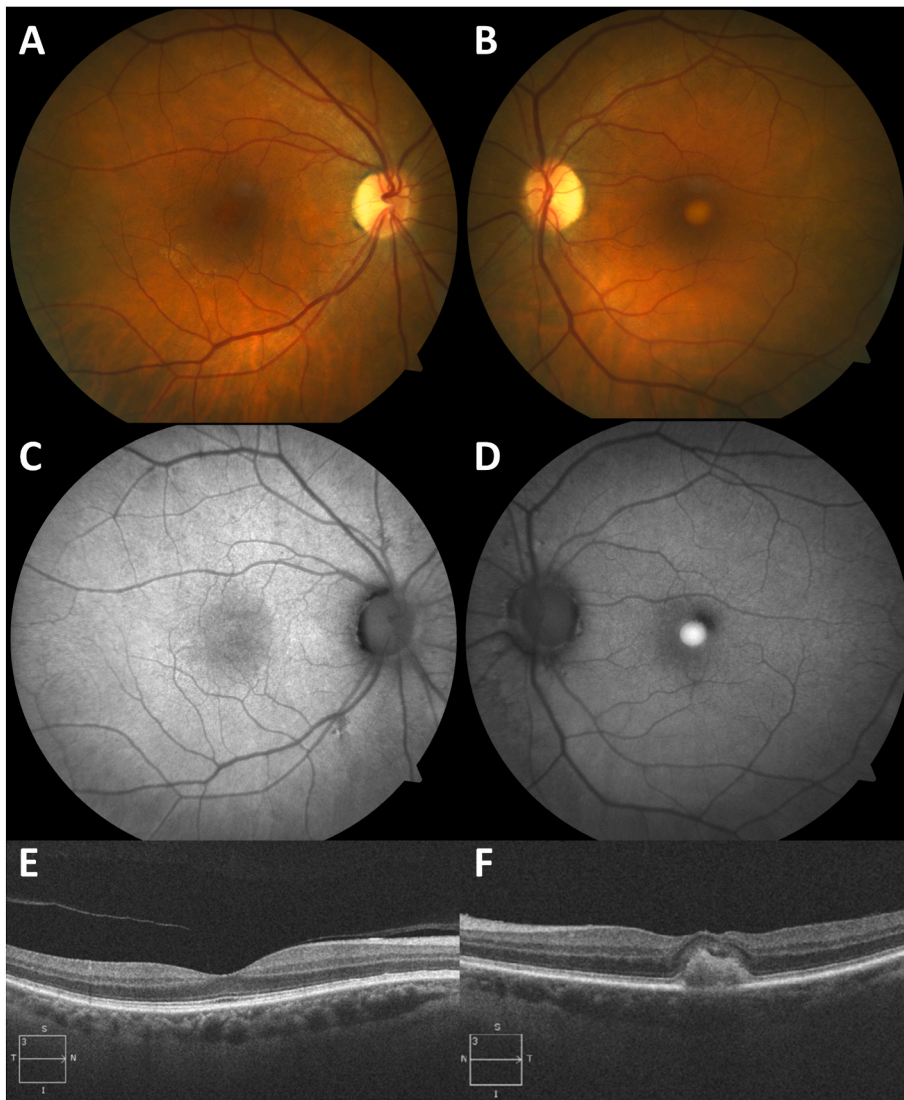


Fig. 1. Multimodal Imaging at Baseline Exam (68 years of age)

Color fundus photographs of the right (A) and left (B) eye. (A) Blunted reflex, and infero-temporal drusenoid changes. (B) Yellow vitelliform lesion. Fundus autofluorescence of the right (C) and left (D) eye. The right eye had normal foveal autofluorescence with a few subtle hyper-reflective changes along the inferior arcade, and in the left eye the macular lesion was hyper-autofluorescent. Optical Coherence Tomography with increased reflectivity of the interdigitation-retinal pigment epithelium complex for the right eye (E), and hyper-reflective material accumulation below the fovea in the left eye (F). (For interpretation of the references to colour in this figure legend, the reader is referred to the Web version of this article.)

moderate nuclear sclerosis in both eyes. Dilated funduscopy revealed a right blunted foveal reflex, and infero-temporal drusenoid changes (Fig. 1A), and a yellow lesion under the fovea in the left eye (Fig. 1B). Optic discs were healthy, and the retinal periphery was unremarkable in both eyes. Fundus autofluorescence imaging was normal in the right eye (Fig. 1C), with the left foveal lesion associated with increased autofluorescence (Fig. 1D). OCT showed subtle increased reflectivity of the interdigitation zone and retinal pigment epithelium complex in the right eye (Fig. 1E), and sub-foveal hyper-reflective material accumulation in the left eye (Fig. 1F). Full-field electroretinography was normal. The patient was followed longitudinally for 10 years with stable BCVA. The right eye did not develop vitelliform lesion (Fig. 2A, C and 2E). However progressive drusenoid changes nasal to the disc were noted (Fig. 2C). The vitelliform lesion in the left eye progressed to a “vitelliruptive” stage (Fig. 2B).

The patient underwent genetic panel testing, which included sequence analysis and deletion/duplication testing of 248 genes (Invitae Diagnostic Testing, San Francisco, CA, USA), and was found to harbor a heterozygous intronic *IMPG2* variant; c.3423-7_3423-4del. Genomic DNA obtained from the submitted sample is enriched for targeted regions using a hybridization-based protocol, and sequenced using Illumina technology. Reads are aligned to a reference sequence (GRCh37) and sequence changes are identified and interpreted in the context of a single, clinically relevant transcript. Analysis focuses on the coding

sequence of the indicated transcripts and 10bp of flanking intronic sequence. This sequence change falls in intron 16 of the *IMPG2* gene and is very rare in population databases (rs534452999, ExAC 0.009%). The variant has been previously reported in individuals with AR RCD and has also been observed to segregate with disease in related individuals.^{11,12} Experimental studies have shown that this variant disrupts mRNA splicing.¹¹ For these reasons, this variant has been classified as pathogenic.

3. Discussion

Unilateral AVMD has been previously reported in patients harbouring *BEST1* variants, and in patients negative for *BEST1* and *PRPH2* variants.⁶ The previously reported patients overall had good prognosis, and our reported patient retained good BCVA over 10 years, with the right eye remaining unaffected. Unilateral AVMD is a rare presentation, and, to our knowledge, this is the first case associated with an *IMPG2* variant. The reported patient does not have the typical characteristics associated with age-related maculopathy, any other inherited macular disorders, trauma, or toxicity. *BEST1*- and *PRPH2*- associated retinopathy has variable penetrance and expressivity and can cause AD or AR disease.^{1,13} Similar to *BEST1* and *PRPH2* genes, there is growing evidence supporting an equally diverse disease spectrum for the rarer causes of AVMD, namely *IMPG1* and *IMPG2*.¹⁴ The presented patient

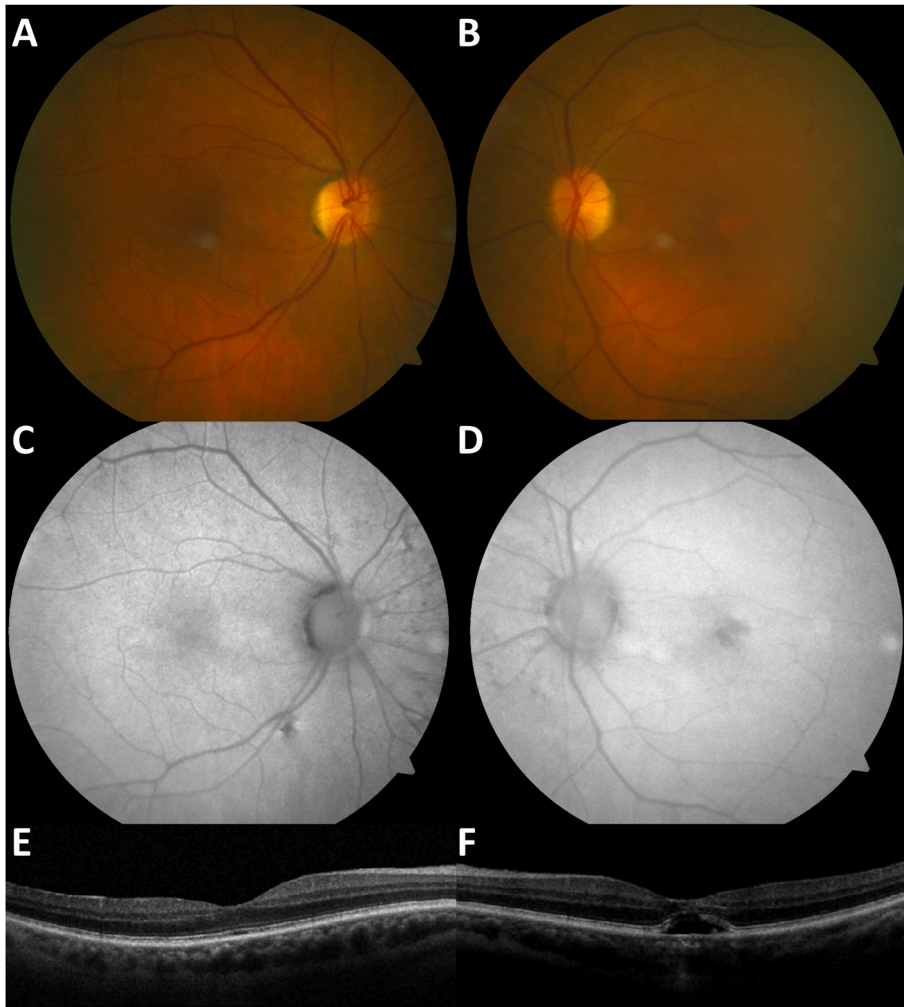


Fig. 2. Multimodal Imaging at Last Follow-up (78 years of age)

Multimodal imaging after 10 years of follow-up, demonstrating progression of the vitelliform lesion to a “vitelliruptive” stage. Color fundus photographs of the right (A) and left (B) eye. (A) Blunted reflex, inferior arcade drusenoid changes. (B) The vitelliform lesion, progressed to a “vitelliruptive” stage. Fundus autofluorescence of the right (C) and left (D) eye. The right eye demonstrates areas of decreased signal nasal to the disc and along the inferior arcade, and the left eye demonstrates an irregular hypo-autofluorescent macular lesion. Optical Coherence Tomography of the right eye (E) and left eye (F). (E) Increased reflectivity of the interdigitation - retinal pigment epithelium complex unchanged to baseline. (F) Ellipsoid zone disruption, transmission defects and hypo-reflective band at the fovea. (For interpretation of the references to colour in this figure legend, the reader is referred to the Web version of this article.)

had a benign course with stable BCVA over a long term follow-up.

In the largest cohort investigating the retinal phenotype in *IMPG2* carriers, relatives of affected individuals with recessive disease were found to have macular focal retinal pigment epithelium thickening on OCT, with one case of segmental hyperpigmentation.⁹ Of note all reported carriers are younger than our patient. The surveillance of these patients for development of further retinal changes over time will be of interest. The focal RPE changes previously identified appear similar to the changes in the right eye along the inferior arcade and nasally to the optic nerve of the patient reported herein. The asymmetric involvement between right and left eyes, can be attributed to the mild phenotype and possible variable level of expression of the normal protein. Asymmetry in inherited retinal diseases is more often present in milder phenotypes, albeit rare.

From our unpublished data of an on-going international natural history study for AR RCD associated with *IMPG2*, we have identified the reported variant herein, in 6 out of 60 patients. We have also identified the *IMPG2* variant p.Lys1158Ter (c.3472A > T) in our cohort. The aforementioned variant was recently reported in a case of bilateral AVMD.¹⁵ The above provides support to our hypothesis that specific *IMPG2* variants can cause AVMD in the heterozygous state and RCD in the homozygous or compound heterozygous state. We speculate that those variants cause both recessive and dominant disease, resulting in different phenotypes, likely secondary to different levels of expression of the normal protein.

One of the limitations of our study is a lack of detailed functional testing, including electro-oculogram and visual fields. Genetic testing

and examination of family members would have strengthened the current report. Unfortunately, they did not agree to assessment.

4. Conclusions

IMPG2 variants can cause both autosomal recessive rod-cone dystrophy and autosomal dominant AVMD, with implications for patient counselling. This is the first report of unilateral AVMD associated with *IMPG2*, expanding the phenotypic spectrum of *IMPG2* retinopathy and the genetic basis of unilateral AVMD. Genetic screening of *IMPG1* and *IMPG2* should be considered in case of unilateral AVMD.

Funding

None.

Authorship

All authors attest that they meet the current ICMJE criteria for Authorship.

Patient consent

Written consent to publish this case has not been obtained. This report does not contain any personal identifying information.

Declaration of competing interest

None.

Acknowledgements

None.

References

- Rahman N, Georgiou M, Khan KN, Michaelides M. Macular dystrophies: clinical and imaging features, molecular genetics and therapeutic options. *Br J Ophthalmol*. 2020; 104:451–460.
- Tosano L, Grunin M, Hagbi-Levi S, Banin E, Averbukh E, Chowers I. Characterising the phenotype and progression of sporadic adult-onset foveomacular vitelliform dystrophy. *Br J Ophthalmol*. 2016;100:1476–1481.
- Georgiou M, Fujinami K, Michaelides M. Retinal imaging in inherited retinal diseases. *Ann Eye Sci*. 2020;5:25.
- Arora R, Khan K, Kasilian ML, et al. Unilateral BEST1-associated retinopathy. *Am J Ophthalmol*. 2016;169:24–32.
- Kaden TR, Tan AC, Feiner L, Freund KB. Unilateral best disease: a case report. *Retin Cases Brief Rep*. 2017;11(Suppl 1):S191–s196.
- Subash M, Rotsos T, Wright GA, et al. Unilateral vitelliform maculopathy: a comprehensive phenotype study with molecular screening of BEST1 and PRPH2. *Br J Ophthalmol*. 2012;96:719–722.
- Salido EM, Ramamurthy V. Proteoglycan IMPG2 shapes the interphotoreceptor matrix and modulates vision. *J Neurosci*. 2020;40:4059–4072.
- Chatterjee S, Gupta S, Chaudhry VN, Chaudhry P, Mukherjee A, Mutsuddi M. Whole exome sequencing identifies a novel splice-site mutation in IMPG2 gene causing Stargardt-like juvenile macular dystrophy in a north Indian family. *Gene*. 2022;816, 146158.
- Khan AO, Al Teneiji AM. Homozygous and heterozygous retinal phenotypes in families harbouring IMPG2 mutations. *Ophthalmic Genet*. 2019;40:247–251.
- Meunier I, Manes G, Bocquet B, et al. Frequency and clinical pattern of vitelliform macular dystrophy caused by mutations of interphotoreceptor matrix IMPG1 and IMPG2 genes. *Ophthalmology*. 2014;121:2406–2414.
- van Huet RA, Collin RW, Stemiakowska AM, et al. IMPG2-associated retinitis pigmentosa displays relatively early macular involvement. *Invest Ophthalmol Vis Sci*. 2014;55:3939–3953.
- Neveling K, Collin RW, Gilissen C, et al. Next-generation genetic testing for retinitis pigmentosa. *Hum Mutat*. 2012;33:963–972.
- Casalino G, Khan KN, Armengol M, et al. Autosomal recessive bestrophinopathy: clinical features, natural history and genetic findings in preparation for clinical trials. *Ophthalmology*. 2020.
- Olivier G, Corton M, Intartaglia D, et al. Pathogenic variants in IMPG1 cause autosomal dominant and autosomal recessive retinitis pigmentosa. *J Med Genet*. 2021;58:570–578.
- Shah SM, Schimmenti LA, Marmorstein AD, Bakri SJ. Adult-onset vitelliform macular dystrophy secondary to A novel Impg2 gene variant. *Retin Cases Brief Rep*. 2018.