

REFERENCES

1. Calkins H, Hindricks G, Cappato R, et al. 2017 HRS/EHRA/ECAS/APHRS/SOLAECE expert consensus statement on catheter and surgical ablation of atrial fibrillation. *Heart Rhythm* 2017;14:e275-444.
2. Piccini JP, Sinner MF, Greiner MA, et al. Outcomes of Medicare beneficiaries undergoing catheter ablation for atrial fibrillation. *Circulation* 2012;126:2200-7.

⁶⁸Ga-DOTATATE PET Identifies Residual Myocardial Inflammation and Bone Marrow Activation After Myocardial Infarction



Myocardial infarction (MI) healing occurs in 2 phases: first an inflammatory phase, where clearance of necrotic debris occurs, followed by a reparative phase characterized by angiogenesis, granulation tissue formation, and attempts to repair the extracellular matrix. While efficient healing relies on coordinated mobilization of monocytes to the damaged myocardium, with resolution of the acute inflammatory response by ~10 to 14 days, excessive inflammation impairs myocardial salvage and promotes adverse cardiac remodeling.

In ischemic heart failure, pro-inflammatory macrophages persist long after the formation of healed scar in remote and border zones of the infarcted, remodeled heart because of maladaptive changes in the mononuclear phagocytic network and spleen (1). An accurate means of diagnosing harmful inflammation after an MI is urgently needed.

We previously demonstrated that ⁶⁸Ga-DOTATATE, a somatostatin receptor subtype-2 positron emission tomography (PET) ligand, could identify pro-inflammatory macrophages within atherosclerotic plaques (2). Here, in this substudy of our original prospective observational study, we examined whether ⁶⁸Ga-DOTATATE could reveal *residual* post-infarction myocardial inflammation.

Patients with an MI within 3 months treated by percutaneous coronary intervention (“recent MI,” n = 6), and patients with a past history of MI and echocardiography data available from after their event (“old MI,” n = 6), were included. Patients with equivocal culprit arteries, and those managed medically or with coronary artery bypass grafting surgery, were excluded.

ECG-gated PET imaging was performed as previously described (2). Maximum standardized uptake

values (SUV_{max}) and tissue-to-blood ratios (TBR_{max}), normalized for blood pool activity in the superior vena cava, were derived blinded to clinical details in each of the 16 myocardial segments.

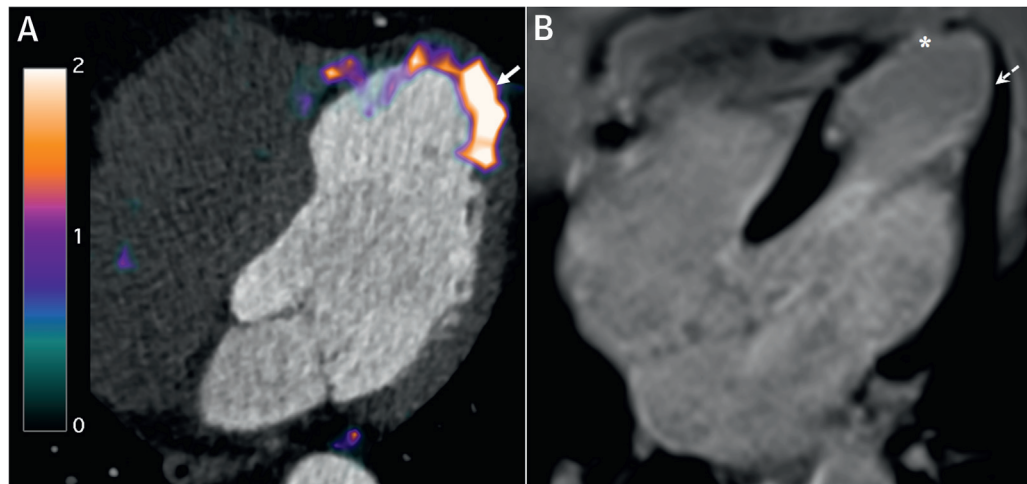
Myocardial ⁶⁸Ga-DOTATATE and ¹⁸F-FDG PET signals were compared: 1) within infarcted and non-infarcted segments; 2) to each other; and 3) to tracer activity in the thoracic vertebral bone marrow as an experimental marker of systemic inflammation, using standard nonparametric statistical tests (all data median [interquartile range (IQR)] unless stated). Recently infarcted myocardial segments were defined by clinically adjudicated (treated) culprit artery territories, with individual anatomical variation verified by angiography. In patients with old MI, infarcted myocardium was determined by echocardiographic wall motion abnormalities (hypokinesia/akinesia), assessed independently of the study and prior to enrollment.

Demographics were similar for recent MI (age 74 years [IQR: 64 to 78 years], 83% male) and old MI (age 59 years [IQR: 56 to 72 years], all male) patients. There were 3 ST-segment elevation MIs, which were all old MIs. PET imaging occurred 35 days (range 21 to 80 days) after recent MIs, and 7 years (range 1.8 to 22 years) after old MIs, with 2 days (range 1 to 21 days) in between ⁶⁸Ga-DOTATATE and ¹⁸F-FDG scans.

⁶⁸Ga-DOTATATE signals were higher in infarcted compared with noninfarcted myocardium in patients with both recent MI (SUV_{max} 1.60 [IQR: 1.45 to 2.11] vs. 1.33 [IQR: 1.25 to 1.52]; p = 0.03; TBR_{max} 2.33 [IQR: 1.55 to 2.71] vs. 1.80 [IQR: 1.32 to 2.22]; p = 0.03) and old MI (SUV_{max} 2.22 [IQR: 2.03 to 2.50] vs. 1.78 [IQR: 1.63 to 2.13]; p < 0.0001; TBR_{max} 2.79 [IQR: 2.47 to 3.23] vs. 1.89 [IQR: 1.52 to 2.36]; p < 0.0001).

Unlike ⁶⁸Ga-DOTATATE, which exhibited very low background myocardial binding in all patients, avid myocardial ¹⁸F-FDG uptake (basal inferoseptum SUV_{max} >5) rendered 5 (42%) scans uninterpretable despite 6-h pre-scan fasting. In the readable scans, the 2 tracers showed reasonable agreement in the myocardium (r = 0.38, 95% confidence interval [CI]: 0.20 to 0.53; p < 0.0001). Despite high liver and spleen ⁶⁸Ga-DOTATATE activity, focal myocardial signals were clearly distinguishable in all 5 patients with inferior infarcts.

Bone marrow ⁶⁸Ga-DOTATATE signals were highly correlated with both infarct-related myocardial inflammation detected by ⁶⁸Ga-DOTATATE (r = 0.83 [95% CI: 0.48 to 0.95]; p = 0.001), and metabolic bone marrow activity measured by ¹⁸F-FDG (r = 0.64 [95% CI: 0.08 to 0.89]; p = 0.03).

FIGURE 1 Post-Infarction Myocardial Inflammation Identified by ^{68}Ga -DOTATATE PET

(A) ^{68}Ga -DOTATATE positron emission tomography (PET)-computed tomography image (scale bar: standardized uptake values) demonstrating residual inflammation (arrow) in (B) partially viable myocardium with subendocardial infarct (dashed arrow), bordering full-thickness scarring (asterisk) confirmed by late gadolinium enhancement magnetic resonance imaging, 4 years after a left anterior descending artery myocardial infarction. ^{18}F -FDG positron emission tomography imaging reproduced a near-identical pattern of abnormal myocardial tracer uptake. Stress magnetic resonance imaging was negative for ischemia.

We found that ^{68}Ga -DOTATATE identified active inflammation in recently infarcted myocardium, as well as old ischemic injury. Our observations agree with existing clinical data (3), but contradict findings in mice (4). ^{68}Ga -DOTATATE binding in chronically damaged myocardium, particularly at the infarct border (Figure 1), likely reflects residual macrophage-driven inflammation; however, histological validation is needed. While tracer binding to myocytes and/or fibroblasts are possible alternative explanations, transcriptomic data from infarcted mouse hearts (5) indicates that *SSTR2* is not expressed in these cell types.

Residual myocardial inflammation detected by ^{68}Ga -DOTATATE could represent an important prognostic biomarker to study disease mechanisms and test novel therapies for the inflamed, failing heart.

Jason M. Tarkin, PhD, MBBS
 Claudia Calcagno, MD, PhD
 Marc R. Dweck, MD, PhD
 Nicholas R. Evans, PhD, MB BChir
 Mohammed M. Chowdhury, MB ChB
 Deepa Gopalan, MD
 David E. Newby, PhD, FMedSci
 Zahi A. Fayad, PhD
 Martin R. Bennett, PhD, FMedSci
 *James H.F. Rudd, MD, PhD

*Division of Cardiovascular Medicine
 University of Cambridge
 Level 6, Box 110
 ACCI, Addenbrooke's Hospital, Hills Road
 Cambridge CB2 0QQ
 United Kingdom
 E-mail: jhfr2@cam.ac.uk
 Twitter: @jhfrudd

<https://doi.org/10.1016/j.jacc.2019.02.052>

© 2019 The Authors. Published by Elsevier on behalf of the American College of Cardiology Foundation. This is an open access article under the CC BY license (<http://creativecommons.org/licenses/by/4.0/>).

Please note: Dr. Tarkin has been supported by the Wellcome Trust (104492/Z/14/Z, 211100/Z/18/Z) and the National Institute for Health Research. Dr. Calcagno has been supported by the National Institutes of Health (NIH) (P01 HL131478, R01 HL071021, R01HL135878) and the American Heart Association (16SDG27250090). Dr. Evans has been supported by the National Institute for Health Research and Dunhill Trust (RTF44/0114). Dr. Chowdhury has been supported by the British Heart Foundation (FS/16/29/31957). Dr. Fayad has been supported by the NIH (P01 HL131478, R01 HL071021, R01 HL128056, R01HL135878, NBIB R01 EB009638) and the American Heart Association (14SFRN20780005). Dr. Rudd has been supported by the Higher Education Funding Council for England, the National Institute for Health Research Cambridge Biomedical Research Centre, the Wellcome Trust, the British Heart Foundation, and the Cambridge Center for Mathematics in Healthcare. This research was conducted in accordance with the study protocol approved by the local research ethics committee (14/EE/0019), Good Clinical Practice, and the Declaration of Helsinki. (Vascular Inflammation Imaging Using Somatostatin Receptor Positron Emission Tomography [VISION]; NCT02021188). Damini Dey, PhD, served as Guest Associate Editor for this letter.

REFERENCES

1. Ismahil MA, Hamid T, Bansal SS, et al. Remodeling of the mononuclear phagocyte network underlies chronic inflammation and disease progression in

heart failure: critical importance of the cardioplenic axis. *Circ Res* 2014;114:266-82.

2. Tarkin JM, Joshi FR, Evans NR, et al. Detection of atherosclerotic inflammation by (68)Ga-DOTATATE PET compared to [(18)F]FDG PET imaging. *J Am Coll Cardiol* 2017;69:1774-91.

3. Lapa C, Reiter T, Li X, et al. Imaging of myocardial inflammation with somatostatin receptor based PET/CT—a comparison to cardiac MRI. *Int J Cardiol* 2015;194:44-9.

4. Thackeray JT, Bankstahl JP, Wang Y, et al. Targeting post-infarct inflammation by PET imaging: comparison of 68Ga-citrate and 68Ga-DOTATATE with 18F-FDG in a mouse model. *Eur J Nucl Med Mol Imaging* 2014;42:317-27.

5. Quaife-Ryan GA, Sim CB, Ziemann M, et al. Multicellular transcriptional analysis of mammalian heart regeneration. *Circulation* 2017;136:1123-39.

Mini-Sternotomy Versus Conventional Sternotomy for Aortic Valve Replacement



Outcomes following aortic valve replacement (AVR) surgery are generally excellent, with in-hospital observed mortality in the United Kingdom of 1.5% for first-time elective procedures (1). These results are not observed in all populations; in high-risk groups, conventional surgery risks perioperative organ injury and prolonged recovery, with death occurring in up to 31% of patients within 1 year of surgery (2). Minimally invasive surgery combines the durability of surgical repair with reductions in surgical trauma, which together should reduce perioperative morbidity. However, reductions in morbidity and resource use (3) may be confounded by multiple sources of bias and are at odds with the limited evidence from trials that have not shown improved outcomes (4). There is variability in the uptake of minimally invasive surgery internationally, and conventional AVR remains the mainstay for the majority of patients. Minimally invasive surgery requires robust evaluation to better understand its utility.

MAVRIC (Manubrium-limited ministernotomy versus conventional sternotomy for aortic valve replacement) was a single-center, single-blind, randomized superiority trial comparing AVR via manubrium-limited mini-sternotomy using a 5- to 7-cm midline incision (intervention) and conventional median sternotomy using a midline incision from the sternal notch to the xiphisternum (usual care) assessing post-operative red cell transfusion.

The trial was prospectively registered (ISRCTN29567910) and published (5). Patients were stratified by baseline logistic EuroSCORE and hemoglobin and were followed for 12 weeks. The primary outcome was the

proportion of patients receiving red cell transfusion within 7 days of surgery.

Using the Fisher exact test with 90% power, 5% alpha, we estimated that 260 patients would be required to detect a 17% reduction in the proportion of patients requiring a red cell transfusion (13% compared with 30%), using a 2-sided test. Allowing for loss to follow-up, the sample size was increased to 270.

A total of 271 patients were randomized using a computer system with concealed allocation; 270 received surgery and contributed to the intention-to-treat analysis. Patients were blinded to the type of sternotomy they received until after they completed their day 2 quality-of-life and pain assessments.

Baseline characteristics were similar between the groups. Mean age 69.3 ± 9.3 years (mini-sternotomy group) and 68.7 ± 8.4 years (conventional group); range 39 to 88 years. Most were male: 57.8% (mini-sternotomy group) versus 64.4% (conventional group). Mean logistic EuroSCORE was 5.2 ± 3.5 (mini-sternotomy group) compared with 5.1 ± 3.5 (conventional group), and mean hemoglobin at randomization was 137.9 ± 14.3 g/dl (mini-sternotomy group) and 137.1 ± 16.1 g/dl (conventional group).

No difference between the mini-sternotomy and conventional groups in red cell transfusion within 7 days was found; 23 of 135 patients in each group received a transfusion, odds ratio: 1.0 (95% confidence interval: 0.5 to 2.0), risk difference 0.0 (95% confidence interval: -0.1 to 0.1) (Table 1). Mini-sternotomy reduced chest drain losses, mean 181.6 ± 138.7 ml versus conventional sternotomy, mean 306.9 ± 348.6 ml; this did not reduce red cell transfusions. Mean valve size and post-operative valve function were comparable between mini-sternotomy and conventional groups: 23 mm versus 24 mm, and 6 of 134 moderate or severe aortic regurgitation versus 3 of 130, respectively. Mini-sternotomy resulted in longer bypass time of 82.7 ± 23.5 min versus 59.6 ± 15.1 min and cross-clamp time (64.1 ± 17.1 min vs. 46.3 ± 10.7 min). Three experienced consultant cardiac surgeons (E.A., W.A.O., and A.G.), experts at performing both techniques, performed all operations as part of the trial: surgeon A, 58 of each operation; surgeon B, 43 mini-sternotomy and 35 conventional; surgeon C, 34 mini-sternotomy and 42 conventional. A total of 16 patients required conversion from mini to conventional sternotomy; these occurred due to: difficult vascular access (n = 9), anesthetic emergency (n = 2), and intraoperative complications (n = 5). Conventional sternotomy was more cost-effective, with a 5.8% probability of mini-sternotomy being cost-effective at a willingness to pay of £20,000/quality-adjusted life year.