

Dual anti-neutrophil cytoplasmic antibody and anti-glomerular basement membrane antibody-positive crescent glomerulonephritis in a patient with monoclonal gammopathy of undetermined significance

A case report

Xiaoli Li, MS^a, Yunfei Hao, MS^b, Rong Xue, MS^a, Xueting Qi, MS^a, Zhigang Ma, MD^{a,*}

Abstract

Rationale: Anti-neutrophil cytoplasmic antibody (ANCA)-associated vasculitis (AAV) and anti-glomerular basement membrane (GBM) antibody disease are both rare autoimmune diseases. Monoclonal gammopathy of undetermined significance (MGUS) is one of the most common causes of plasma cell dyscrasias (PCD). The three entities can cause renal lesions via different mechanisms and, however, they have not been reported in a single patient with renal lesion.

Patient concerns: Here, we describe a patient with half-year fatigue and 40-day nausea and vomiting. Laboratory workup displayed increased serum creatinine, proteinuria, and mild microscopic hematuria. Serological tests were positive for anti-nuclear antibody (titer 1:100), anti-GBM antibodies (not quantified), and myeloperoxidase (MPO)-ANCA (228 RU/ml). Serum immunofixation electrophoresis found monoclonal immunoglobulin (MIg) G κ -light chain in the serum. Renal biopsy displayed crescentic formation in glomerule by microscopy and staining for liner IgG (+), sparse C3 (+/-) and light chain (κ and λ) (+/-) by immunofluorescence. The bone marrow examination indicated basically normal myelogram and sporadic plasma cells positive for CD38, CD138 staining, and κ light-chain restriction.

Diagnosis: Crescentic glomerulonephritis and MGUS.

Interventions: The patient was treated with plasmapheresis, pulse methylprednisolone therapy in combination with cyclophosphamide.

Outcomes: The patient still became hemodialysis-dependent.

Lessons: The present study discusses, to the best of our knowledge, first case of crescentic glomerulonephritis seropositive for ANCA anti-GBM antibody in MGUS. The rare concurrence highlights it as a clinical concern.

Abbreviations: AASV = anti-neutrophil cytoplasmic antibody-associated vasculitis, ANCA = anti-neutrophil cytoplasmic antibody, C = complement, GBM = anti-glomerular basement membrane, Ig = immunoglobulin, MG = monoclonal gammopathy, MGRS = monoclonal gammopathy of renal significance, MGUS = monoclonal gammopathy of undetermined significance, MIg = monoclonal immunoglobulin, P-ANCA = perinuclear anti-neutrophil cytoplasmic antibody, PCD = plasma cell dyscrasias.

Keywords: anti-glomerular basement membrane antibodies, anti-neutrophil cytoplasmic antibody, crescent glomerulonephritis, monoclonal gammopathy of renal significance, monoclonal gammopathy of undetermined significance

Editor: N/A.

XL and YH have equally contributed to this study.

Written informed consent was obtained from the patient for publication of this case report and any accompanying images. A copy of the written consent is available for review by the Editor-in-chief of this journal.

Details of the patient are available in the hospital notes for the Editor-in-chief of this journal for review.

The authors declare that they have no competing interests.

^a Department of Nephrology, ^b Cerebrovascular Disease Center, Gansu Provincial Hospital, Lanzhou, Gansu Province, China.

* Correspondence: Zhigang Ma, Department of Nephrology, Gansu Provincial Hospital, No. 204, Donggang West Road, Lanzhou 730000, Gansu Province, China (e-mail: 337381887@qq.com).

Copyright © 2019 the Author(s). Published by Wolters Kluwer Health, Inc.

This is an open access article distributed under the terms of the Creative Commons Attribution-Non Commercial License 4.0 (CCBY-NC), where it is permissible to download, share, remix, transform, and build upon the work provided it is properly cited. The work cannot be used commercially without permission from the journal.

Medicine (2019) 98:7(e14557)

Received: 17 October 2018 / Received in final form: 15 January 2019 / Accepted: 23 January 2019

<http://dx.doi.org/10.1097/MD.00000000000014557>

1. Introduction

Anti-neutrophil cytoplasmic antibody (ANCA)-associated vasculitis (AAV) and anti-glomerular basement membrane (GBM) antibody disease are both rare autoimmune diseases that typically present as pulmonary hemorrhage and rapidly progressive glomerulonephritis, with the estimated incidences in Europe of 1.6 and 20 per million population per year, respectively.^[1,2] The patients with both ANCA and anti-GBM antibodies, so-called double positive, present different clinical manifestations and outcome compared to patients with ANCA or anti-GBM alone and cause 1-year survival of 35% and renal survival of 0%.^[3]

Plasma cell dyscrasias (PCD) is defined as excessive amounts of monoclonal immunoglobulin (MIg) in the blood, usually due to proliferation of components of Ig-producing B lymphocytes or plasma cells, such as multiple myeloma, lymphoplasmacytic lymphoma (including Waldenström macroglobulinemia), or a B-cell lymphoproliferative neoplasm, or a nonmalignant clonal proliferation of plasma cells or B lymphocytes, known as monoclonal gammopathy (MG) of undetermined significance (MGUS).^[4]

AAV, anti-GBM disease, and PCD can cause a wide spectrum of renal lesions via different physiopathological mechanisms, and, however, the three entities have not been reported to concur in a single case with renal lesions. Herein, we reported the first patient with AAV and anti-GBM disease coexisting with PCD, which presented as MIg G kappa (κ)-light chain in the serum.

2. Case presentation

A 46-year-old male was presented to our hospital with half-year fatigue and 40-day nausea and vomiting. Eight days previously, the patient was admitted to a local hospital and the laboratory examinations displayed a hemoglobin level of 94 g/l, serum creatinine level of 502.3 $\mu\text{mol/l}$, a serum albumin level of 38 g/l, and a 24-h urinary protein excretion level of 2.85 g. Chest computed tomography displayed multiple stripped or patchy high-density shadow and bilaterally pleural thickening. Fever, hemoptysis, diarrhea, oliguria, and edema were not seen during the course. He denied any past diseases or family history of genetic disorders.

On admission to our hospital, the creatinine level rose to 1333 $\mu\text{mol/l}$ and the 24-h urinary protein excretion level dropped to 0.234 g. Physical examination found pulse 73 beats/minute, blood pressure 128/73 mm Hg, and pale skin. Lungs were clear to auscultation and the remainder was unremarkable. There was no ocular inflammation, joint tenderness or effusion, and rash.

Other laboratory data included the following values: blood urea nitrogen of 38.2 mmol/l, albumin of 39 g/l, and hemoglobin of 97 g/l. Urinalysis showed proteinuria 3+ and mild microscopic hematuria. Plasma complement (C) 3 was slightly decreased at 0.69 g/l (normal range 0.79–1.52 g/l), whereas C4 was normal at 0.35 g/l (0.16–0.35 g/l). IgG was at the upper limit of normal range: 14.30 g/l (7.51–15.6 g/l), whereas IgA and IgM were respectively 1.09 g/l (0.82–4.53 g/l) and 0.66 g/l (0.46–3.04 g/l). Erythrocyte sedimentation rate was 67 mm/h (0–15 mm/h). C-reactive protein was 11.5 mg/l (0–5 mg/l). Serological tests were positive for antinuclear antibody (titer 1:100) and anti-GBM antibodies (not quantified). Perinuclear-ANCA (P-ANCA) were detected in the serum, with specificity for myeloperoxidase (228 RU/ml). Serum immunofixation electrophoresis found MIg G κ . Serology was negative for rheumatoid factor and viral hepatitis. Chest radiograph showed mild exudation in the middle fields of both lungs. Renal ultrasound revealed normal sized kidneys (left

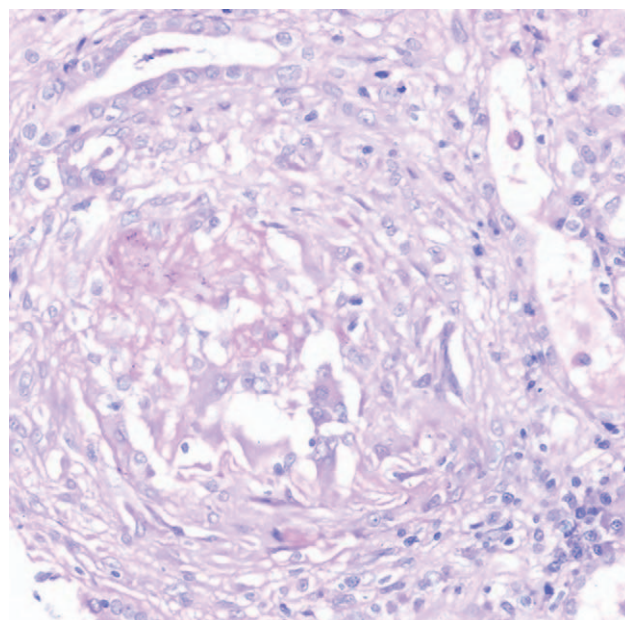


Figure 1. Hematoxylin and eosin staining, showing cellular crescents in glomeruli.

kidney 105×54 mm and right kidney 112×52 mm), cortical hyperechogenicity, and obscure corticomedullary differentiation. A bone scan showed no abnormal concentration.

Renal biopsy was performed. A total of 3 glomeruli were obtained, 2 having cellular crescents (Fig. 1) and 1 having fibrocellular crescent (Fig. 2). The tubules were focally atrophic and contain a large amount of protein casts. Inflammatory cells were observed in some interstitial region. Arterioles showed thickening wall thickening and narrowing vessel lumen. Immunofluorescence showed liner staining for IgG (+) (Fig. 3), with sparse staining for C3 (+-), light chain (κ and (λ))

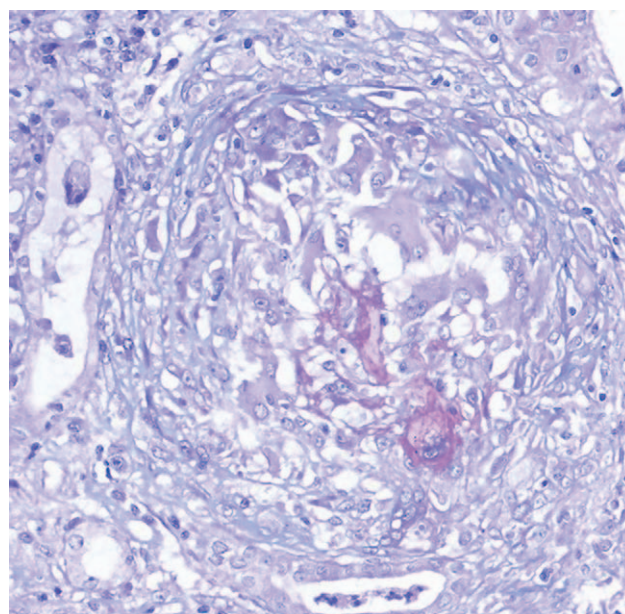


Figure 2. Masson staining, showing fibrocellular crescent are observed in glomeruli.

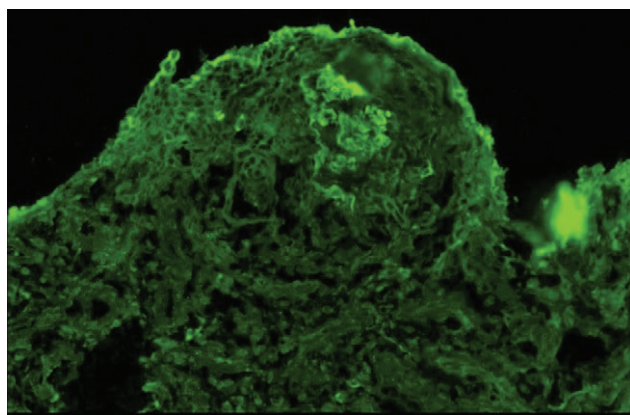


Figure 3. Immunofluorescence microscopy, showing linear staining for IgG (+) along glomerular basement membrane.

(+/-) and not detectable for IgM, IgA, C1q. Congo staining was negative. Electron microscopy showed proliferation of parietal epithelial cells and no electron-dense deposits.

A bone marrow aspiration indicated secondary anemia and the normal portion of plasma cell. A bone marrow biopsy showed basically normal myelogram, except sporadic plasma cells, which was then confirmed as the aberrant cells with positive CD38 and CD138 staining by flow cytometry. Further immunostaining suggested κ light-chain restriction.

Crescentic glomerulonephritis and MGUS were made. The patient was given plasmapheresis, pulse methylprednisolone therapy (500 mg/day IV for 3 days followed by 50 mg/d, orally), and cyclophosphamide (400 mg per two weeks, IV). He progressed rapidly to end-stage kidney disease. The patient was followed up for 6 months. He did not recover and became hemodialysis-dependent, with the serum creatinine level of around 650 $\mu\text{mol/L}$.

3. Discussion

To the best of our knowledge, the present study reports the first case of AAV and anti-GBM disease coexisting with PCD and presenting as a M Ig G κ -light chain in the serum, which was classified into MGUS. The AAV and anti-GBM disease diagnosis was based on the presence of serum ANCA and anti-GBM antibodies and renal biopsy that revealed crescent formation and liner staining for IgG along the GBM, whereas MGUS was confirmed via serum immunofixation electrophoresis results combined with bone marrow aspiration, biopsy, and plasma cells immunostained positive for CD38, CD138, and κ .

MGUS is the most common type of PCD, defined by 3 criteria: <3 g/dL of M Ig , <10% of plasma cells in the bone marrow, and no evidence of end organ damage.^[5] It is usually known to be a precursor of malignant hematological disorders, such as multiple myeloma, amyloidosis, and Waldenström's macroglobulinemia, with a risk rate of 1% per year, and requires only clinical and biological surveillance without chemotherapy.^[6] However, MGUS patients sometimes manifest renal lesions in the absence of hematologic malignancy, thereby confusing treatment protocols. The International Kidney and Monoclonal Gammopathy Research Group introduced the term monoclonal gammopathy of renal significance (MGRS) in order to separate these entities from both benign and malignant hematologic conditions and

facilitate the adoption of therapies directed toward clonal proliferation.^[7] MGRS consists of a wide spectrum of renal lesions that are typically classified into two categories: the larger subset consisting of direct renal deposition of tM Ig and/or components with immunofluorescence positive for M Ig such as amyloidosis, M Ig deposition disease, proliferative glomerulonephritis with M Ig deposits, immunotactoid glomerulopathy, fibrillary glomerulonephritis, cast nephropathy, and light-chain proximal tubulopathy; and the smaller subset consisting of indirect mechanisms without tissue deposition of M Ig , including complement activation (C3 glomerulopathy characterized by bright staining for C3 with minimal or no staining for Ig) and endothelial injury (thrombotic microangiopathy via thrombi in glomerular capillaries, mesangiolytic, and double contours of the GBMs).^[8] The present patient only showed liner staining for IgG (+) along the GBM, trace results (+/-) for C3, κ , and λ ; and negative results for Congo red staining and others. No immune complex was found via electron microscopy. Notably, renal lesions in the present patient were not caused via the aforementioned mechanisms.

ANCA and anti-GBM antibodies are respectively special for AAV and anti-GBM diseases, both of which are pathologically characterized by the crescent formation of glomeruli. These patients demonstrate clinical features of both AAV (older age distribution and longer prodrome of systemic symptoms) and anti-GBM disease (severe renal disease, high frequency of lung hemorrhage at presentation, and synchronous crescent formation in the glomeruli).^[9] However, the double-positive patients did not present more severe outcome when compared to the single-positive patient. Instead, they showed good response to treatment and a greater tendency to recover from dialysis dependency after treatment, especially patients with higher ANCA and lower anti-GBM titers, even although they had more evidence of chronic injury upon renal biopsy.^[10] Unfortunately, the mechanism of association is not yet fully understood. Notably, the two entities were antigenically distinct, and no cross-reactivity was found at the B-cell level due to the absence of structural similarity. Some studies presumed that ANCA-mediated glomerular inflammation may precede and damage the GBM, and thereby uncover the "hidden antigens" ($\alpha 3$ (IV)NC1 or other components) in the GBM, resulting in the formation of anti-GBM antibodies and a fulminant anti-GBM response.^[11] However, the hypothesis fails to explain why anti-GBM antibodies are detected before ANCA development. A recent study suggested that anti-GBM disease might be triggered by molecular mimicry.^[12] Furthermore, the coexistence of the anti-GBM antibody and ANCA could be explained by minimal primary sequence homology, which possibly initiates cross-reactive T cell responses.^[11] In the present patient, serological antibody examinations were not initially performed and sampled glomeruli were few; therefore, it was difficult to confirm the presence of the anti-GBM antibody. However, the patient reported a history of half-year fatigue, indicating AAV as the possible precursor.

It is more complicated when the ANCA and anti-GBM antibodies coexist with M Ig in the serum. The mechanism is unclear, and cannot be explained without detailed evidence. Numerous clinical studies have highlighted a strong association between PCD and autoimmune diseases.^[13] Osserman and Takatsuki were the first to hypothesize that chronic antigen stimulation probably triggered the development of PCD,^[14] possibly due to the introduction of pro-oncogenic mutations in rapidly dividing cells (including plasma cells), immune dysregulation, and/or sustained immune stimulation.^[15] Autoimmune

diseases that occur frequently include Sjögren's syndrome, polymyositis, vitiligo, Kikuchi disease, neuromyelitis optica, and ankylosing spondylitis. Although rare, there are also separate cases that report ANCA or anti-GBM antibodies in hematological neoplasm. In a 1990 study, the authors evaluated 150 serum samples from 125 MG patients and found that 17 were positive for ANCA.^[16] Moreover, Liu H et al reported a case of AAV coexisting with MM.^[17] Others argue that MIg might be responsible for the presence of antibodies. Isolated cases have shown hematologic neoplasms with B lymphocytes or plasma cells secretly directing MIg toward self-antigens. Bellotti et al reported 3 MG patients with lupus-like anticoagulants whose coagulative studies showed that paraproteins were responsible for anticoagulant activity by interacting with the thromboplastin phospholipids.^[18] Another case involving Sweet's syndrome associated with MIg G- λ type and P-ANCA positivity showed that the MIg possibly acted as an antibody that was directed toward neutrophils, thereby leading to their fragmentation and release of antigens responsible for the appearance of p-ANCA.^[19] Castleman's tumors also secreted autoantibodies that reacted against epidermal proteins, which is an essential factor in the pathogenesis of paraneoplastic pemphigus.^[20] Recently, a study suggested a causal relationship between anti-GBM disease and homologous malignancy. The author biopsied lymph nodes from a patient with Castleman's disease and found that sporadic plasma cells produced $\alpha 3$ (IV)NC1-IgG25.^[21] Notable, our study hypothesizes PCD tumor cells to be the source of autoantibodies such as ANCA and/or anti-GBM antibodies.

Unfortunately, we did not study the functional behavior of the MIg proteins in our patient toward neutrophil cytoplasmic antibodies and GBM. Despite this limitation, our study adds to the limited available information regarding the association between PCD and autoantibodies (ANCA and anti-GBM antibodies).

In conclusion, the present study is the first case of AAV and anti-GBM disease coexisting PCD. It suggests a causal relationship among the three entities, which are worthy of clinical attention and further study. This finding may shed new light on the pathogenesis and treatment of this rare occurrence.

Author contributions

Data curation: Zhigang Ma.

Investigation: Xueting Qi.

Methodology: Rong Xue.

Writing – original draft: Xiaoli Li, Yunfei Hao.

Xiaoli Li orcid: 0000-0002-9821-5434.

References

- [1] Watts RA, Mahr A, Mohammad AJ, et al. Classification, epidemiology and clinical subgrouping of antineutrophil cytoplasmic antibody (ANCA)-associated vasculitis. *Nephrol Dial Transplant* 2015;30(Suppl 1):i14–22.
- [2] Thibaud V, Rioux-Leclercq N, Vigneau C, et al. Recurrence of Goodpasture syndrome without circulating anti-glomerular basement membrane antibodies after kidney transplant, a case report. *BMC Nephrol* 2019;20:6.
- [3] Levy JB, Hammad T, Coulthart A, et al. Clinical features and outcome of patients with both ANCA and anti-GBM antibodies. *Kidney Int* 2004;66:1535–40.
- [4] Khouri J, Samaras C, Valent J, et al. Monoclonal gammopathy of undetermined significance: a primary care guide. *Cleve Clin J Med* 2019;86:39–46.
- [5] Glavey SV, Leung N. Monoclonal gammopathy: the good, the bad and the ugly. *Blood Rev* 2016;30:223–31.
- [6] Kyle RA, Larson DR, Therneau TM, et al. Long-term follow-up of monoclonal gammopathy of undetermined significance. *N Engl J Med* 2018;378:241–9.
- [7] Leung N, Bridoux F, Hutchison CA, et al. Monoclonal gammopathy of renal significance: when MGUS is no longer undetermined or insignificant. *Blood* 2012;120:4292–5.
- [8] Sethi S, Rajkumar SV, D'Agati VD. The complexity and heterogeneity of monoclonal immunoglobulin-associated renal diseases. *J Am Soc Nephrol* 2018;29:1810–23.
- [9] Balderia P, Andeen N, Jefferson JA. Characteristics and outcomes of patients with anti-glomerular basement membrane antibody disease and anti-neutrophil cytoplasmic antibodies. *Curr Rheumatol Rev* 2018;14:1–10.
- [10] McAdoo SP, Tanna A, Hruskova Z, et al. Patients double-seropositive for ANCA and anti-GBM antibodies have varied renal survival, frequency of relapse, and outcomes compared to single-seropositive patients. *Kidney Int* 2017;92:693–702.
- [11] Yang R, Hellmark T, Zhao J, et al. Antigen and epitope specificity of anti-glomerular basement membrane antibodies in patients with Goodpasture disease with or without anti-neutrophil cytoplasmic antibodies. *J Am Soc Nephrol* 2007;18:1338–43.
- [12] Arends J, Wu J, Borillo J, et al. T cell epitope mimicry in anti-glomerular basement membrane disease. *J Immunol* 2006;176:1252–8.
- [13] McShane CM, Murray LJ, Landgren O, et al. Prior autoimmune disease and risk of monoclonal gammopathy of undetermined significance and multiple myeloma: a systematic review. *Cancer Epidemiol Biomarkers Prev* 2014;23:332–42.
- [14] Söderberg KC, Jonsson F, Winqvist O, et al. Autoimmune diseases, asthma and risk of haematological malignancies: a nationwide case-control study in Sweden. *Eur J Cancer* 2006;42:3028–33.
- [15] Cho SY, Yang HS, Jeon YL, et al. A case series of autoimmune diseases accompanied by incidentally diagnosed monoclonal gammopathy: is there a link between the two diseases? *Int J Rheum Dis* 2015;17:635–9.
- [16] Esnault VL, Jayne DR, Keogan MT, et al. Anti-neutrophil cytoplasmic antibodies in patients with monoclonal gammopathies. *J Clin Lab Immunol* 1990;32:153.
- [17] Liu H, Xiong J, Zhang J, et al. Possible intrinsic association of anti-neutrophil cytoplasmic antibody-associated vasculitis coexisting with multiple myeloma. *Oncol Lett* 2016;12:2084–6.
- [18] Bellotti V, Gamba G, Merlini G, et al. Study of three patients with monoclonal gammopathies and 'lupus-like' anticoagulants. *Br J Haematol* 2010;73:221–7.
- [19] Nocente R, Cammarota G, Gentiloni SN, et al. A case of Sweet's syndrome associated with monoclonal immunoglobulin of IgG-lambda type and p-ANCA positivity. *Panminerva Med* 2002;44:149.
- [20] Wang L, Bu D, Yang Y, et al. Castleman's tumours and production of autoantibody in paraneoplastic pemphigus. *Lancet* 2004;363:525–31.
- [21] Gu QH, Jia XY, Hu SY, et al. The clinical and immunologic features of patients with combined anti-GBM disease and Castleman disease. *Am J Kidney Dis* 2018;71:904–8.