

# Cutaneous Invasive Fungal Infections with *Saksenaea* Species in Immunocompetent Patients in Europe: A Systematic Review and Case Report

Andrea Planegger, MD\*  
 Semra Uyulmaz, MD\*  
 Audrius Poskevicius, MD†  
 Andrea Zbinden, MD‡  
 Nicolas J. Müller, MD§  
 Maurizio Calcagni, MD\*

**Background:** Invasive fungal infections from *Saksenaea*, a fungus belonging to the *Mucorales*, have been rarely reported in central European climate zones. This study aims to raise awareness of invasive cutaneous infections with *Saksenaea* species. The first case of a cutaneous infection was diagnosed in Switzerland in an immunocompetent 79-year-old patient. A minor skin trauma of her left lower leg led to a fulminant infection causing necrosis and extensive loss of tissue. The combination of surgical debridement and administration of antifungal agents averted a prolonged course with a possible worse outcome. A pedicled hemisoleus muscle flap was used to reconstruct the defect and treatment was continued for 63 days.

**Methods:** A systematic review in accordance with the Preferred Reporting Items for Systematic review and Meta-Analysis guidelines was conducted to identify all European cases of infection with *Saksenaea* species in immunocompetent hosts. The epidemiology, clinical presentation, microbiological diagnosis, and management of cases reported in Europe were summarized and analyzed.

**Conclusions:** The prognosis of soft tissue infections with *Saksenaea* species depends on early diagnosis and appropriate antifungal and surgical treatment. Reconstruction can be successful under ongoing antifungal treatment. (*Plast Reconstr Surg Glob Open* 2022;10:e4230; doi: 10.1097/GOX.0000000000004230; Published online 8 April 2022.)

## INTRODUCTION

Necrotizing soft tissue infections involve skin, fascia, and/or muscle and are rapidly progressing infections predominantly caused by polymicrobial infections in 70%–80% and monomicrobial infections in 20%–30% of cases.<sup>1</sup>

Fungal necrotizing soft tissue infections are of low prevalence and most commonly belong to the order *Mucorales*, causing invasive fungal infection referred to as mucormycosis.<sup>2</sup>

Mucormycosis is an angioinvasive fungal soft tissue infection resulting in high morbidity and mortality.

From the \*Department of Plastic Surgery and Hand Surgery, University Hospital Zurich, Zurich, Switzerland; †Department of General, Emergency and Visceral Surgery, Cantonal Hospital Obwalden, Sarnen, Switzerland; ‡Institute of Medical Microbiology, University of Zurich, Zurich, Switzerland; and §Department of Infectious Diseases and Hospital Epidemiology, University of Zurich, Zurich, Switzerland.

Received for publication December 2, 2021; accepted February 9, 2022.

Copyright © 2022 The Authors. Published by Wolters Kluwer Health, Inc. on behalf of The American Society of Plastic Surgeons. This is an open-access article distributed under the terms of the Creative Commons Attribution-Non Commercial-No Derivatives License 4.0 (CCBY-NC-ND), where it is permissible to download and share the work provided it is properly cited. The work cannot be changed in any way or used commercially without permission from the journal.

DOI: 10.1097/GOX.0000000000004230

A global rise in prevalence of mucormycosis has been observed within the recent years due to new subtypes of *Saksenaea* species (spp.) and susceptible population.<sup>3</sup>

Infections caused by *Saksenaea* spp. commonly occur in immunocompromised patients (hematologic malignancy, neutropenia, high-dose corticosteroids, diabetes mellitus, organ transplantation, malnutrition, and burns).<sup>4</sup>

Mucormycosis can, however, affect immunocompetent patients without any known underlying illness. The reported prevalence of mucormycosis in immunocompetent hosts is approximately 19%.<sup>3</sup> Mucormycosis from *Saksenaea* spp. accounts for approximately 3% of infections from all the *Mucorales*.<sup>5</sup> Infections with *Saksenaea* spp. occur in immunocompetent individuals most commonly after trauma, ranging from insect bites to surgical site infections to polytrauma.<sup>6,7</sup>

These fungal organisms are ubiquitous; they are part of normal soil flora or have been associated with decaying vegetation.<sup>8</sup> Skin defects exposed to soil or dirt potentially result in the acquiring of an infection with *Saksenaea* spp.<sup>6,9,10</sup> Microbiologist S.B. Saksenaea had extracted the fungus from Indian soil in 1953 and distinguished the invasive fungus by its particularly flask-shaped sporangia, from other *Saksenaea* spp. and referred to it as *Saksenaea vasiformis*.<sup>11,12</sup>

**Disclosure:** The authors have no financial interest to declare in relation to the content of this article.

The clinical presentation of infections with *Saksenaea* spp. varies between localized or systemic disease.

The cutaneous manifestation is the most common one and can rapidly progress.<sup>6</sup> Localized cutaneous or subcutaneous invasion initiates with spores of the fungus entering the body via defected skin barriers.<sup>6,13</sup> Clinically, these patients present with necrotic or ulcerative skin and soft tissue lesions or necrotizing fasciitis.<sup>4,7,9,14</sup> According to a review, 46%–67% of cutaneous mucormycosis was reported in immunocompetent patients.<sup>3</sup> Patients' prognosis depends on early diagnosis and immediate treatment. In cutaneous cases, surgical debridement and systemic administration of antifungal medication are the recommended first line treatments. Contrary to the more common mucormycosis infections, no specific guidelines are available for the management of cutaneous infections with *Saksenaea* spp.,<sup>9</sup> which have been reported worldwide. Most cases have been related to warmer (tropical/subtropical) climate zones. Cases in central European climate conditions are rare.<sup>6,15</sup> We report a case of cutaneous *Saksenaea vasiformis* infection in an immunocompetent patient in Switzerland following minor skin trauma from a stone wall in southern Italy.

In an attempt to identify cases of *Saksenaea* spp. infections in immunocompetent patients reported in Europe and their management strategies, a systematic review of the literature was conducted. The purpose of this work was to raise awareness for this uncommon pathology in Europe and provide evidence for the management of soft tissue infections with *Saksenaea* spp.

### Case Report

A 79-year-old immunocompetent woman was admitted to a regional hospital in Switzerland with 23 cm x 20 cm dermal abrasion on her left lower leg (medial third/anterior-medial). During a recent vacation in Sardinia, the patient had grazed her left lower leg at a stone wall 6 days before the initial admission.

On admission at the regional hospital, the periphery of the abrasion appeared necrotic with clinical signs of lymphangitis extending to the dorsum of the foot. An empiric antibiotic treatment (amoxicillin-clavulanate intravenously) was initiated upon initial admission in the regional hospital. The wound was surgically debrided on day 8, and tissue samples were sent for microbiological and histopathological examination. The tissue intraoperatively mimicked a necrotizing panniculitis (Figs. 1, 2). A vacuum-assisted closure system was used for wound cover.

The patient's clinical condition worsened with fever and pain. Infection markers increased rapidly, reaching 280 mg per l (C-reactive protein) and 10.2 G per l (white blood cell count) on day 9. The antibiotic regimen was changed to clindamycin (orally) combined with cefepime intravenously. Results from microbiological samples taken on day 8 showed growth with gram-positive cocci and *Pseudomonas aeruginosa*, which was susceptible to clindamycin. Debridement was repeated on day 10.

On day 12, the patient was transferred to the University Hospital of Zurich due to uncontrollable tissue necrosis

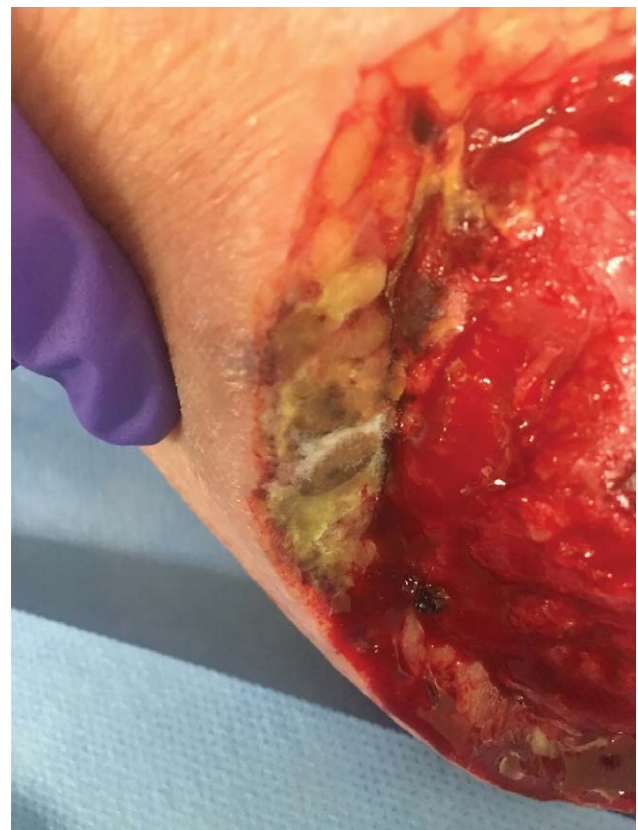### Takeaways

**Question:** What are the characteristics of reported patient cases of fungal infections with *Saksenaea* species in Europe?

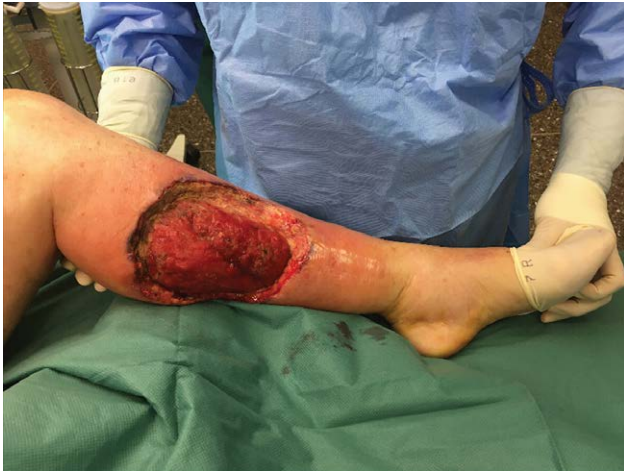**Findings:** Nine cases of immunocompetent infections by *Saksenaea* were reported in Europe. All cases resulted from skin trauma and the average discovery time was 21 days. All patients received a minimum of 1 surgical debridement and the average treatment time with antifungal agents was 73 days.

**Meaning:** *Saksenaea* invasive fungal infections should be considered in immunocompetent patients, following skin trauma with rapid progression and without improvement on adequate antibiotic treatment. Surgical debridement together with antifungal agents is the treatment of choice.

in the wound bed despite escalated antibiotic treatment. The patient presented with a defect of 400 cm<sup>2</sup> on her left lower leg (Fig. 3). The defect extended from the anterior aspect of the tibial bone medially toward the popliteal fossa proximally, exposing the soleus muscle and the medial head of the gastrocnemius muscle, 12 cm above the medial malleolus. Due to ongoing necrosis and an ambiguous diagnosis, another surgical debridement was performed (Fig. 4). Samples were sent for microbiological investigations; the wound was covered with a vacuum-assisted closure system.

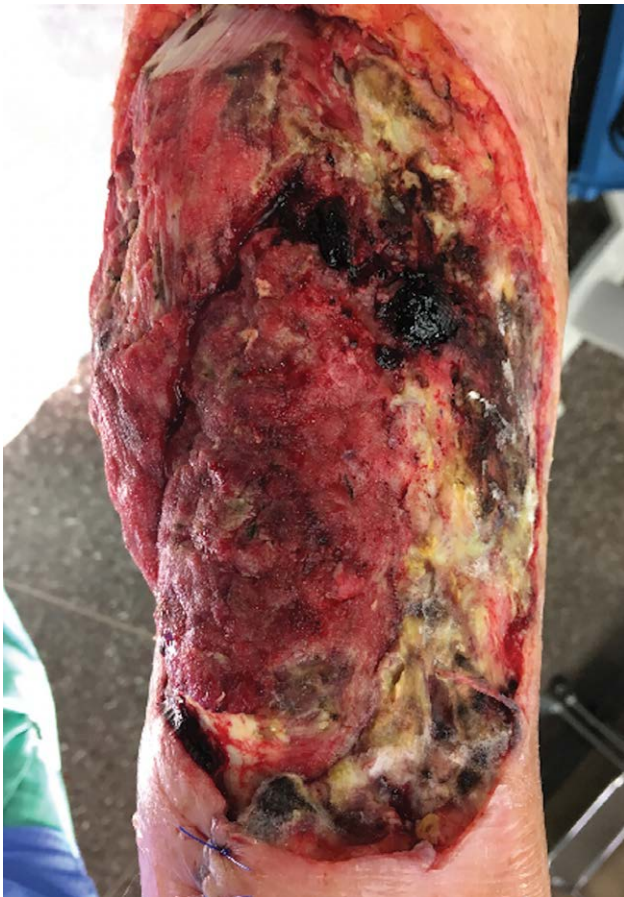

**Fig. 1.** Preoperative (magnified) view of the wound showing necrotizing panniculitis on the left lower leg (taken on day 8).



**Fig. 2.** Photograph showing the extent of the wound of the left lower leg defect (taken on day 8).

Fungal microscopy with periodic acid Schiff staining of the tissue samples showed aseptate fungal hyphae consistent with zygomycete infection. On day 14, fungal growth with filamentous fungi in the tissue samples confirmed an invasive mucormycosis and treatment with posaconazole 300 mg per 12 hours was started immediately. Due to the



**Fig. 3.** Defect on left lower leg demonstrating necrosis (photographs taken on day 12, before debridement).

lack of sporulation at the fungal cultures, identification of the filamentous fungus was obtained by molecular analyses of the internal transcribed spacer (ITS) region of the rRNA operon.<sup>16</sup> An identification of genus level *Saksenaea* spp. was achieved, with best matching sequence similarity to *S. vasiformis* and *S. erythospora*. Additionally, *Bacillus* spp. and *Staphylococcus epidermidis* were isolated in multiple samples. The antibiotic regimen was changed to daptomycin and piperacillin-tazobactam intravenously. After five further debridements, tissue samples on day 20 did not show evidence of ongoing infection with *Saksenaea* spp.

After eight surgical debridements and under antifungal treatment, clinical improvement was observed. Six weeks after initial presentation (at the regional hospital), the wound showed rosy granulation tissue and vital skin margins. At this stage, the defect anteriorly exposed the tibia and posteriorly the musculotendinous junction of the gastrocnemius muscle (Fig. 5). As healing by secondary intention was likely to fail and the periosteum of the tibia was still there, the defects were grafted with a dermal regeneration template followed by split-thickness skin and covered with a vacuum-assisted closure system.

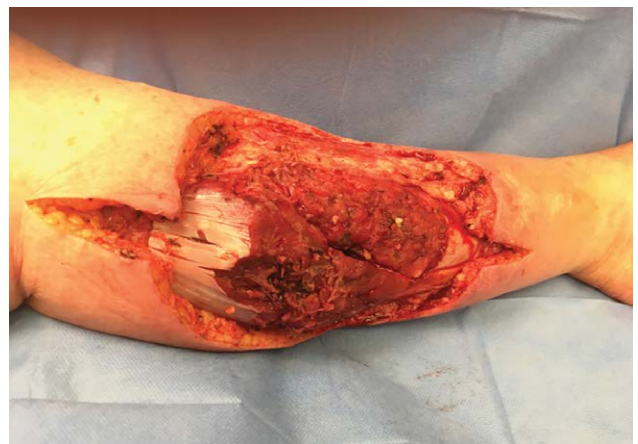Twelve weeks after initial presentation, incomplete wound healing at the tibia site anteriorly was noted, and a revision and reconstruction with a pedicled hemi soleus muscle flap (medial part) and split-skin graft performed, which covered the wound sufficiently allowing for return to daily activities (Figs. 6, 7). Treatment with posaconazole was maintained for a total of 63 days.

This case demonstrates the importance of an early and accurate diagnosis of *Saksenaea* spp. in a poorly recovering soft tissue infection, highlighting the importance of interdisciplinary management.

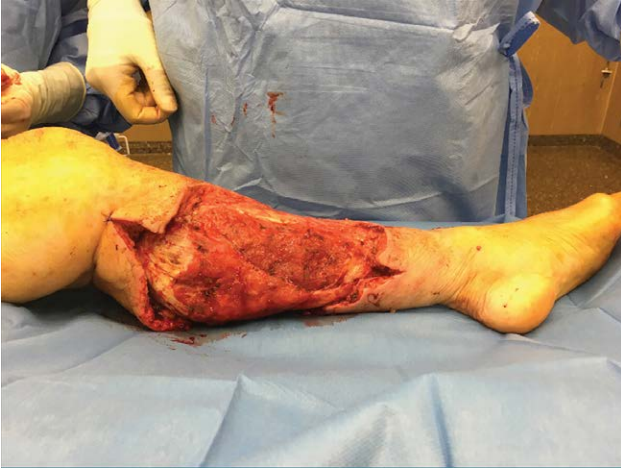## METHODS

### Literature Review

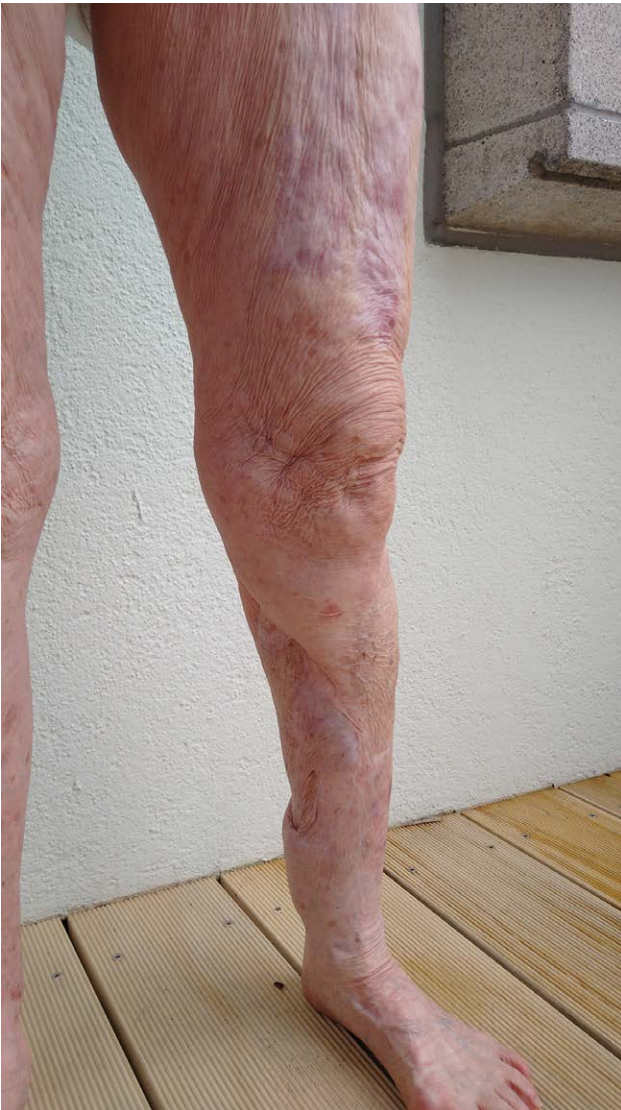A registration of the protocol on the PROSPERO International Prospective Register of Systematic Reviews (CRD42021256711) was performed according to the guidelines described in the Preferred Reporting Items for



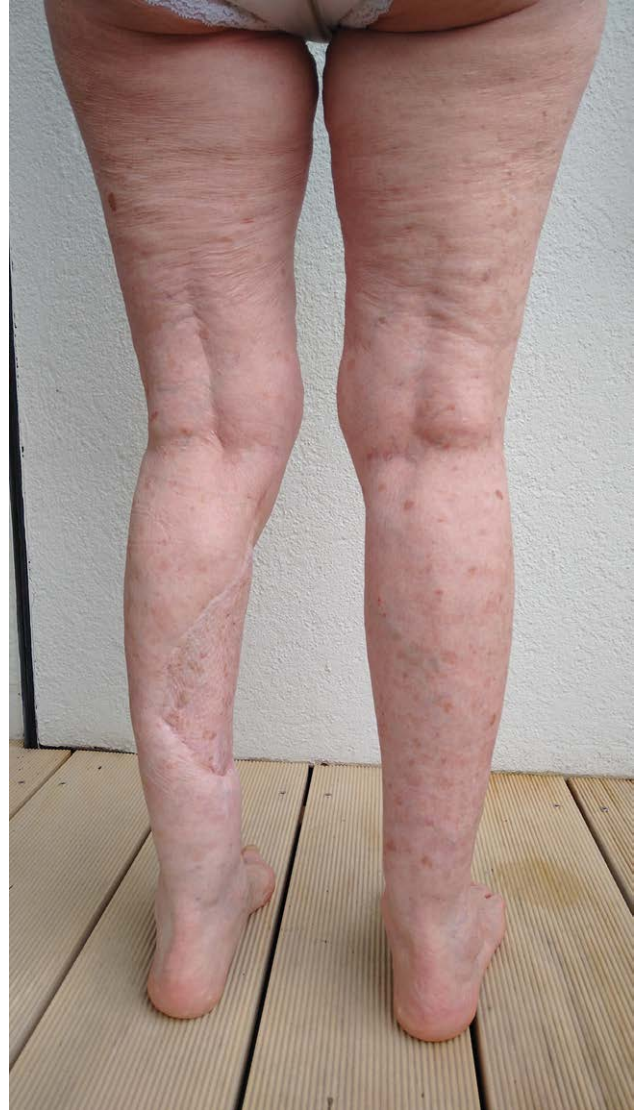**Fig. 4.** Defect on left lower leg demonstrating necrosis (photographs taken on day 12, after debridement).



**Fig. 5.** Photograph of left lower leg defect after eight debridements, 6 weeks after initial presentation at regional hospital.



**Fig. 6.** Photograph taken 12 months postoperative of left lower leg, following a medial hemi soleus flap coverage (anterior view/left leg).



**Fig. 7.** Photograph taken 12 months postoperative of lower legs bilaterally, following a medial hemi soleus flap coverage (posterior view).

Systematic review and Meta-Analysis Protocols flow chart (Fig. 8).

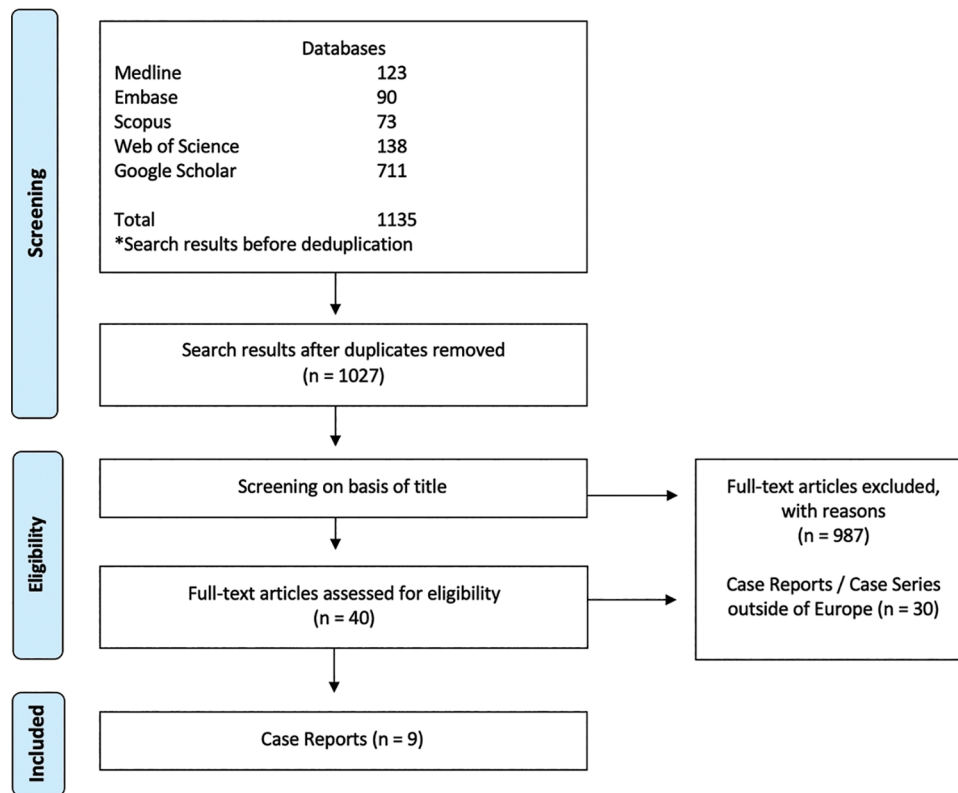
#### Search Strategy

Electronic data bases (Embase, Google Scholar, Medline, Scopus and Web of Science) were screened to identify all case reports containing the keyword “Saksen\*” on 10th May 2021.

#### Data Extraction

Firstly, duplicates were removed by the first author. Two authors performed a review of publications. Articles were selected based on inclusion and exclusion criteria. Disagreement between the two reviewers concerning the inclusion of particular studies was resolved in consensus with the senior reviewer.

The final bibliography of the included studies was screened to check for additional case reports missed by the search strategy. The list of screened and included studies was organized in a structured Excel sheet.



**Fig. 8.** Preferred Reporting Items for Systematic review and Meta-Analysis Protocols flow chart.

### Study Selection

We included all published studies on immunocompetent patients with soft tissue infection with any species of *Saksenaea* in Europe.

Cases of solitary disseminated infections and rhino-orbital and pulmonary infections were excluded. Case reports of primarily local cutaneous infections eventually resulting in a disseminated infection were included,<sup>17</sup> while cases of primarily disseminated,<sup>18–20</sup> nosocomial,<sup>21</sup> cranial,<sup>22</sup> rhino-(oto)-cerebral infections,<sup>23–26</sup> with skin manifestations that presented secondarily<sup>27</sup> were excluded.

All pediatric cases (<18 years), cases in immunocompromised patients and burns were excluded. We did not consider diabetes as an exclusion criterion.

All published case reports of immunocompetent patients with infection from any *Saksenaea* species, that were treated with surgical debridement and/or systemic administration of antifungals were included. For each reported case of *Saksenaea* infection, clinical manifestations, sites of infection, discovery times, co-infections, and treatment-times with both antibiotics and antifungals were analyzed (Table 1). Furthermore, the types of surgical treatment the patients received were compared, including respective results.

## RESULTS

### Epidemiology

Nine cases were reported in Europe. All reported infections were caused by *S. vasiformis*. The average age

of reported cases in Europe was 56 years with an almost equal gender distribution (four female/four male cases).

All reported cases in Europe resulted from skin trauma. Five reported infections were posttraumatic following motor vehicle accidents.<sup>7,17,29–31</sup> As a result of progression of cutaneous lesion, four reported cases had a fatal outcome,<sup>17,29–31</sup> and all of them were initially caused by motor vehicle accidents.

### Clinical Presentation

Cutaneous presentation included local skin necrosis and necrotizing cellulitis with edema and erythema in all cases. The infection was localized at an extremity site in seven patients. In four patients, it affected a lower extremity site, and in four patients, an upper extremity site was involved. The cranial area (traumatic head injury)<sup>29</sup> and the lumbar region<sup>31</sup> were the other sites of infection.

### Microbiological Diagnostics

Three patients had confirmed bacterial coinfections.<sup>17,30,31</sup> One report lacked information about bacterial coinfections and respective treatment.<sup>29</sup> The average discovery time of the invasive fungal infection after primary incidence causing the infection was 21 days. One article did not report the time to diagnosis.<sup>10</sup>

### Management

Four confirmed cases of bacterial coinfections received antibiotics,<sup>17,30,31</sup> while four patients were started on empiric antibiotics.<sup>7,10,11,28</sup>

**Table 1. Characteristics of Immunocompetent Patients with Soft Tissue Infection by Any Species of *Saksenaea* in Europe**

Patient No.	Reference	Country	S/A	Etiology	CM	Site	DT	Co-infection	CAT	AmB/PCZ			AB	Surgery	Outcome/ Survival	Amputation (of Affected Limb)	Reconstructive Procedures Performed (If Applicable)
										MT	CT	AMTT					
1	7	UK	F/55	Fall from high altitude (4th floor)	Necrotizing cellulitis	Left knee (supracondylar fracture)	14	None	x	35	High-dose, broad-spectrum antibiotics	Two debridements with removal of necrotic skin, subcutaneous tissue, and muscle to the level of the bone	Yes	Yes, below knee leg amputation			
2	10	Spain	M/66	Brain injury after MVA	Cellulitis, necrotizing plaque	Right cranial area	20	None	x	/	None	Extensive debridement (single intervention)	No				
3	11	Spain	F/46	MVA	Necrotizing fasciitis, edema	Right arm, progression to scapulo-humeral, axillo-pectoral, mammary, and thoracic, including abdominal wall	12	<i>Pseudomonas aeruginosa</i> , <i>Enterobacteriaceae</i> and <i>Serratia fonticola</i>	x	4	Pipercycline tazobactam	Debridement, amputation of the affected limb, mastectomy, removal of pectoral muscles, scapula, and part of the clavicle*	No	Yes			
4	17	Spain	M/58	MVA with a tractor, poly-trauma	Necrotic eschar, edema, dissemination	Left forearm (open fracture of radius and ulna bone), forehead (facial abrasions)	15	<i>Staphylococcus epidermidis</i> , <i>Prevotella buccae</i>	x	135	Vancomycin cefazidime cefazolin, gentamicin, ciprofloxacin, imipenem, and daptomycin Doxycycline amoxicillin-clavulanic acid, imipenem	Multiple and radical face and forearm debridements*	No		Skin graft		
5	28	Spain	M/76	Bite of unknown origin	Necrotizing cellulitis	Left forearm	—	None	x	90	Doxycycline amoxicillin-clavulanic acid, imipenem	Multiple debridements*	Yes				
6	29	Greece	M/39	Mild injury while cleaning a water drainage system	Initially topical inflammation, later involving muscle with pus secretion	Right leg	63	None	Amb, PCZ	90	Amoxicillin-clavulanic acid, clindamycin	Repeated surgical debridements*	Yes		Transposition flap and skin grafting		

(Continued)

Table 1. (Continued)

Patient No.	Reference	Country	S/A	Etiology	CM	Site	DT	Co-infection	AmB/PCZ			Surgery Debridement	Outcome/ Survival	Amputation (of Affected Limb)	Reconstructive Procedures Performed (If Applicable)
									CAT	MT	CT AMTT				
7	<sup>30</sup>	France	F/49	High velocity MVA	Erythematous lesions and ulcers, septic shock	Right forearm	14	—	AmB, PCZ Aspofungin, Fungizone	180	Meropenem amikacin, vancomycin	Extensive debridements every 2 d, including a right mastectomy*	Yes	Amputation of the right upper limb with inter-scapular-thoracic disarticulation,	Reconstruction with a DIEP flap
8	<sup>31</sup>	Greece	M/30	MVA	Erythema, swelling and necrotic lesions	Head injury (subarachnoid and subdural hemorrhage), superficial injuries lumbar (left side), rapid progression of infection to posterior truncal area, multi-organ failure	20	<i>Klebsiella pneumoniae</i> , <i>Pseudomonas aeruginosa</i> , <i>Acinetobacter baumannii</i> , <i>Bacillus cereus</i> and <i>Bacillus licheniformis</i>	AmB, PCZ	10	Yes but not specified	Daily debridements (involving the muscle) and revealing the underlying left kidney*	No		
9	<sup>32</sup>	Greece	F/62	Working at building reconstruction site after a flood	Initially violaceous discoloration, progressive erythema, and tenderness of the lesion	Right thigh	12		AmB, PCZ	42	Ceftazidime, ciprofloxacin, meropenem tigecycline	Surgical debridement every other day	Yes	Yes, disarticulation of the right leg	Musculotaneous flap from the gluteus maximus muscle

\*Exact number not declared.

AB, Antifungal; AmB MT, Amphotericin Monotherapy; AMTT, Antimycotic treatment time (in days); CAT, Combination Antimycotic Therapy; CM, Clinical Manifestation; DT, Discovery time (in days); MVA, Motor vehicle accident; PCZ CT, Posaconazol Monotherapy; Spp., Species; SV, *Saksenaea vasiformis*.

Nine patients received amphotericin B for antifungal treatment. Posaconazole was added to amphotericin B in four patients.<sup>7,11,31,32</sup> Posaconazole was used as the sole agent in none of the reported cases.

All patients received a minimum of one surgical debridement, and the average treatment time with any antifungal agents (monotherapy / combined therapy) was 72 days.

#### Outcome: Survival/Recovery

The survival rate of reported cases in Europe (including the present case) was 55% (five of nine patients). Despite surgical debridement and antifungal treatment with amphotericin B and/or posaconazole, cases of limb amputation have been described to prevent the infection from progressing.<sup>7,28,32</sup> The amputation rate in patients with affected extremity sites was 50%.

#### Surgical Reconstruction

All nine case reports have been surgically debrided; four cases were managed by surgical reconstructive procedures.<sup>7,11,17,32</sup> Detailed information on reconstructive procedures is listed in [Table 1](#).

## DISCUSSION

#### Epidemiology

While subtypes such as *S. dorisiae*<sup>33</sup> were only found in nonclinical extractions, only *S. erythrospora*<sup>34–36</sup> and most frequently *S. vasiformis* have been reported to cause human invasive infections. Although the subtype *S. erythrospora* caused mycormycosis in immunocompetent adults globally,<sup>37–39</sup> it was not reported to cause any infection in Europe.

Previous European reports have been related to Mediterranean climatic conditions. In the present case, the injury and consequently the infection with *S. vasiformis* originated in Sardinia, where the climate is much warmer compared with that in Switzerland.

There is a relation between prevalence of fungal infections with *Saksenaee* spp. and wounds exposed to agricultural contamination.<sup>8</sup> Given the mechanism of injury in the presented case in particular with an injury from climbing a stone wall, the wound was very likely exposed to dirt or soil from mosses or various flora and fauna growing on the wall (fungi).

#### Clinical Presentation

The majority of *S. vasiformis* infection cases affect mainly healthy or nonimmunocompromised individuals.<sup>6</sup> The patient from the present case was negative for any acquired or inherited immunodeficiency that could have promoted a fungal infection.

Onset with early cutaneous skin necrosis is considered the most common characteristic of soft tissue *S. vasiformis* infection. Characterized histopathologically by angioinvasion and tissue necrosis,<sup>6</sup> the clinical presentation of the present case is comparable to the majority of primary cutaneous cases previously reported in the literature.

#### Microbiological Diagnosis

Prompt diagnosis to initiate treatment as early as possible is fundamental<sup>7</sup> as delay in diagnosis negatively affects a patient's prognosis and increases mortality. Infections by emerging fungi are rare, difficult to diagnose, and therefore may be underreported.<sup>9,10</sup> *Saksenaee* spp. only rarely sporulate on routine mycological media.<sup>6</sup>

Direct examination of fungal elements in tissue samples by microscopy provides orientation on whether a fungal infection is suspected.<sup>9</sup> Microscopic evaluation of the characteristic morphologies of fungal hyphae is indicative for zygomycete but allows for testing of only a small amount of tissue.

Fungal cultures allow for fungal identification and antifungal drug susceptibility testing; however, compared with microscopic evaluation, they are more time-consuming. *Saksenaee* spp. can be grown on any fungal media; however, the use of a nutritionally deficient medium or Czapek-Dox agar has shown the best sporulation, allowing identification by conventional phenotypic methods.<sup>6,40</sup>

#### Management

There is no data from clinical trials to specifically guide antifungal therapies in treating necrotizing soft tissue infections.<sup>2</sup> Trauma-related mucormycosis in immunocompetent patients is uncommon; consequently, there are no controlled studies to guide management.<sup>41</sup> Management of mycormycosis with *Saksenaee* spp. requires a highly specialized and an interdisciplinary approach. Infections with *S. vasiformis* are commonly marked by its rapid progression into adjacent tissues necessitating aggressive and repeated debridement in combination with antifungal therapy. Abscess formation and fat necrosis have also been reported as cutaneous presentation of *S. vasiformis* infections.<sup>6</sup> Treatment classically consists of aggressive debridement and antifungal therapy. Antifungal treatment alone is not sufficient, and neither is radical surgery.<sup>33</sup>

As stated by the Royal Center of Defence (Switzerland),<sup>41</sup> infections in combat military victims tend to be trapped in deeper tissue layers, necessitating extensive and multiple debridements until there are no more clinical signs of infection. The protocol for repetition of debridement declares 48–72 hours between the operations and includes the irrigation of wounds with hydrogen peroxide followed by generous amounts of warmed saline. Documentation of each stage of the wound is done photographically.<sup>8</sup> For the surgical debridement, it is necessary to identify a clear margin of viable to necrotic tissue. While margins appear clinically intact, often ongoing growth of fungus can be detected microbiologically.<sup>41</sup>

Amputation<sup>6,28,42,43</sup> and fatal progression despite treatment have been described in the literature and were associated with motor vehicle accidents. All of the fatal outcomes appear to be in the patients with polymicrobial coinfections (4/9 cases). While the data suggest a high mortality in the series of patients with *Saksenaee* spp., it appears to be difficult to distinguish the confounder of coinfection.

All European cases were treated with liposomal amphotericin B, which is considered a first-line treatment



together with surgical debridement according to ESCMID (European Society of Clinical Microbiology and Infectious Diseases) and ECMM (European Confederation of Medical Mycology) guidelines for the management of mucormycosis.<sup>44</sup> Posaconazole is recommended as a salvage treatment and has the highest cure rates when combined with surgery as part of the treatment strategy.<sup>44,45</sup>

As such, posaconazole alone might be adequate if the patient is managed with aggressive surgical debridement. It might reduce the nephrotoxicity associated with amphotericin B in patients with *Saksenaea*.<sup>46</sup> Our decision concerning which antifungal regimen to choose and how to administer it, was guided by data demonstrating posaconazole's efficiency in treatment of *S. vasiformis* fungal infections<sup>46</sup> and by the clinical status of the patient. The patient was clinically stable, which is why we chose to administer posaconazole orally.

The duration with antifungal treatment should be at least two weeks after resolution of any evidence of infection symptoms; however, it needs to be tailored individually to each patient.<sup>2</sup>

Following studies examining the in vitro activity of *S. vasiformis*, it was proven that the minimum inhibitory concentration (MIC measured in mg/ml) after 24 and 48 hours of posaconazole is lower than those of amphotericin B.<sup>47</sup> Amphotericin B is limited in its application due to nephrotoxicity; it must be closely monitored and is bound to restrictions for dosage and duration of treatment.<sup>6</sup>

### Surgical Reconstruction

The reconstruction of defects following fungal infections has to be tailored to each individual patient.<sup>41</sup> Aggressive debridement led to extensive defects in most reported cases. Comparison of timing and approaches was complicated by scarceness of details and further information within individual case reports.

For the timing of the reconstruction, a clean (not-contaminated) wound with removal of all dead tissue is considered priority.<sup>8</sup>

Reconstruction was considered after 4 weeks following the initiation of therapy with posaconazole and as soon as all samples remained negative for fungal growth. We have given posaconazole for 6 weeks and reconstructed thereafter. For this time frame, there are currently no guidelines. We made a decision based on the clinical course and the tissue samples, which were all negative after 4 weeks of posaconazole.

For a successful free flap reconstruction, a well-controlled and adjusted antifungal-treatment period is suggested, as mucormycosis is known to clot vessels by thrombus or even cause dissections, which would threaten the success of the flap.<sup>7</sup> We have therefore chosen a pedicled muscle flap, which provided excellent functional and aesthetic outcomes.

In summary, this article is important, as it provides an overview of this rare condition. It aims to raise awareness for invasive fungal infections in patients with even minor wounds that occurred outdoors if they travelled to the Mediterranean. *Saksenaea* spp. as causative fungus might be underreported because of challenges caused

by phenotypic identification methods. Thus, fungal cultures on nutritionally deficient media for conventional phenotypic methods or investigations by molecular techniques are highly recommended for ready identification of *Saksenaea* spp. in clinical samples. In the present case, coverage by split skin-graft on a dermal regeneration template resulted in incomplete wound healing at the tibia site of the defect. The second attempt performed after completion of antifungal treatment with a pedicled hemi-soleus flap resulted in complete closure of the defect.

## CONCLUSIONS

Erythematous, nonpurulent skin or soft-tissue necrosis with rapid progression and no history of immunodeficiency should raise the suspicion for mucormycosis. Early diagnosis is essential to stop the progress of the rapidly spreading cutaneous *S. vasiformis* infections and prevent amputation of limbs, dissemination, or fatal consequences.

Repeated and extensive surgical debridement of the necrotic tissue together with antifungal agents are crucial for successful treatment. Posaconazole is less nephrotoxic and was successfully used to treat the *Saksenaea* soft tissue infection as a single agent. Defect coverage by local muscle flaps for extremity reconstructions should be considered in select cases.

Andrea Planegger, MD

Dept of Plastic Surgery and Hand Surgery  
University Hospital Zurich  
Raemistrasse 100  
8091 Zurich  
Switzerland  
E-mail: andrea.planegger@icloud.com

## REFERENCES

1. Bonne SL, Kadri SS. Evaluation and management of necrotizing soft tissue infections. *Infect Dis Clin North Am.* 2017;31:497–511.
2. Bartram L, Aaron JG. Fungal necrotizing skin and soft tissue infections. *Curr Fungal Infect Rep.* 2019;13:146–156.
3. Prakash H, Chakrabarti A. Global epidemiology of mucormycosis. *J Fungi (Basel).* 2019;5:E26.
4. Prabhu RM, Patel R. Mucormycosis and entomophthoromycosis: a review of the clinical manifestations, diagnosis and treatment. *Clin Microbiol Infect.* 2004;10 suppl 1:31–47.
5. Jeong W, Keighley C, Wolfe R, et al. The epidemiology and clinical manifestations of mucormycosis: a systematic review and meta-analysis of case reports. *Clin Microbiol Infect.* 2019;25:26–34.
6. Gomes MZ, Lewis RE, Kontoyiannis DP. Mucormycosis caused by unusual mucormycetes, non-Rhizopus, -Mucor, and -Lichtheimia species. *Clin Microbiol Rev.* 2011;24:411–445.
7. Reinbold C, Derder M, Hivelin M, et al. *Using Free Flaps for Reconstruction During Infections by Mucormycosis: A Case Report and a Structured Review of the Literature.* Philadelphia: Elsevier; 2016.
8. Evriviades D, Jeffery S, Cubison T, et al. Shaping the military wound: issues surrounding the reconstruction of injured servicemen at the Royal Centre for Defence Medicine. *Philos Trans R Soc Lond B Biol Sci.* 2011;366:219–230.
9. Delliere S, Rivero-Menendez O, Gautier C, et al. Emerging mould infections: get prepared to meet unexpected fungi in your patient. *Med Mycol.* 2019;21:21.
10. Coronel-Perez IM, Rodriguez-Rey EM, Castilla-Guerra L, et al. Primary cutaneous mucormycosis due to *Saksenaea*

- vasiformis* in an immunocompetent patient. *Actas Dermosifiliogr.* 2015;106:516–518.
11. Samaras K, Markantonatou AM, Karapiperis D, et al. *Saksenaea vasiformis* infections: a case of an immunocompetent adult after mild injury and a literature review. *J Mycol Med.* 2019;29:260–264.
  12. Saksena SB. A new genus of the mucorales. *Mycologia.* 1953;45:426–436.
  13. Chakrabarti A, Kumar P, Padhye AA, et al. Primary cutaneous zygomycosis due to *Saksenaea vasiformis* and *Apophysomyces elegans*. *Clin Infect Dis.* 1997;24:580–583.
  14. Lelievre L, Garcia-Hermoso D, Abdoul H, et al; and the French Mycosis Study Group. Posttraumatic mucormycosis: a nationwide study in France and review of the literature. *Medicine (Baltimore).* 2014;93:395–404.
  15. Lechevalier P, Hermoso DG, Carol A, et al. Molecular diagnosis of *Saksenaea vasiformis* cutaneous infection after scorpion sting in an immunocompetent adolescent. *J Clin Microbiol.* 2008;46.
  16. Ciardo DE, Schär G, Altwegg M, et al. Identification of moulds in the diagnostic laboratory—an algorithm implementing molecular and phenotypic methods. *Diagn Microbiol Infect Dis.* 2007;59:49–60.
  17. Gómez-Camarasa C, Rojo-Martín MD, Miranda-Casas C, et al. Disseminated infection due to *Saksenaea vasiformis* secondary to cutaneous mucormycosis. *Mycopathologia.* 2014;177:97–101.
  18. Torell J, Cooper BH, Helgeson NG. Disseminated *Saksenaea vasiformis* infection. *Am J Clin Pathol.* 1981;76:116–121.
  19. Hay RJ, Campbell CK, Marshall WM, et al. Disseminated zygomycosis (mucormycosis) caused by *Saksenaea vasiformis*. *J Infect.* 1983;7:162–165.
  20. Solano T, Atkins B, Tambosis E, et al. Disseminated mucormycosis due to *Saksenaea vasiformis* in an immunocompetent adult. *Clin Infect Dis.* 2000;30:942–943.
  21. Oberle AD, Penn RL. Nosocomial invasive *Saksenaea vasiformis* infection. *Am J Clin Pathol.* 1983;80:885–888.
  22. Dean DF, Ajello L, Irwin RS, et al. Cranial zygomycosis caused by *Saksenaea vasiformis*. Case report. *J Neurosurg.* 1977;46:97–103.
  23. García-Martínez J, López-Medrano F, Alhambra A, et al. Rhinocerebral zygomycosis caused by *Saksenaea vasiformis* in a diabetic patient. *Mycoses.* 2008;51:549–553.
  24. Shatriah I, Mohd-Amin N, Tuan-Jaafar TN, et al. Rhino-orbitocerebral mucormycosis in an immunocompetent patient: case report and review of literature. *Middle East Afr J Ophthalmol.* 2012;19:258–261.
  25. Al-Otaibi F, Albloushi M, Alhindi H, et al. Carotid artery occlusion by rhinoorbitocerebral mucormycosis. *Case Rep Surg.* 2012;2012:812420.
  26. Marechal E, Barry F, Dalle F, et al. Fatal invasive otitis with skull base osteomyelitis caused by *Saksenaea vasiformis*. *QJM.* 2018;111:499–500.
  27. Dominguez MD, Sanchez J, Carmona E, et al. Elderly patient with rapidly progressive skin lesions. *Enferm Infecc Microbiol Clin.* 2012;30:43–45.
  28. Cefai C, Elliott TS, Nutton RW, et al. Zygomycotic gangrenous cellulitis. *Lancet.* 1987;2:1337–1338.
  29. Gómez Merino E, Blanch Sancho JJ, Iñiguez de Onzoño L, et al. Necrotic lesion in scalp after injury. *Rev Clin Esp.* 2003;203:451–452.
  30. Mayayo E, Stchigel AM, Cano JF, et al. Necrotising fasciitis caused by *Saksenaea vasiformis* in an immunocompetent patient after a car accident. *Rev Iberoam Micol.* 2013;30:57–60.
  31. Kompoti M, Michalia M, Kallitsi G, et al. Fatal cutaneous *Saksenaea vasiformis* infection in a critically ill trauma patient. *Mycoses.* 2011;54:e599–e601.
  32. Gkegkes ID, Kotrogiannis I, Konstantara F, et al. Cutaneous mucormycosis by *Saksenaea vasiformis*: an unusual case report and review of literature. *Mycopathologia.* 2019;184:159–167.
  33. Labuda R, Bernreiter A, Hochenauer D, et al. *Saksenaea dorisiae* sp. nov., a new opportunistic pathogenic fungus from Europe. *Int J Microbiol.* 2019;2019:6253829.
  34. Hospenthal DR, Chung KK, Loret K, et al. *Saksenaea erythrospora* infection following combat trauma. *J Clin Microbiol.* 2011;49:3707–3709.
  35. Relloso S, Romano V, Landaburu MF, et al. *Saksenaea erythrospora* infection following a serious sailing accident. *J Med Microbiol.* 2014;63(pt 2):317–321.
  36. Tendolkar U, Baradkar V, Baveja S, et al. Cutaneous Zygomycosis due to *Saksenaea vasiformis* in a patient with paraparesis, burns and pressure ulcer. *Int J Inf Dis.* 2011;10:6.
  37. Tendolkar U, van Diepeningen A, Joshi A, et al. Rhinosinusitis caused by *Saksenaea erythrospora* in an immunocompetent patient in India: a first report. *JMM Case Rep.* 2015;2:3.
  38. Rodríguez JY, Rodríguez GJ, Morales-López SE, et al. *Saksenaea erythrospora* infection after medical tourism for esthetic breast augmentation surgery. *Int J Infect Dis.* 2016;49:107–110.
  39. Chander J, Singla N, Kaur M, et al. *Saksenaea erythrospora*, an emerging mucoralean fungus causing severe necrotizing skin and soft tissue infections – a study from a tertiary care hospital in north India. *Infect Dis (Lond).* 2017;49:170–177.
  40. Alvarez E, Garcia-Hermoso D, Sutton D, et al. Molecular phylogeny of the emerging pathogenic fungus *Saksenaea*: proposal of two new species. *Am Soc Microbiol.* 2010;48:4410–4416.
  41. Walsh TJ, Hospenthal DR, Petraitis V, et al. Necrotizing mucormycosis of wounds following combat injuries, natural disasters, burns, and other trauma. *J Fungi (Basel).* 2019;5:E57.
  42. Wilson PA. Zygomycosis due to *Saksenaea vasiformis* caused by a magpie peck. *Med J Aust.* 2008;189:521–522.
  43. Padhye AA, Koshi G, Anandi V, et al. First case of subcutaneous zygomycosis caused by *Saksenaea vasiformis* in India. *Diagn Microbiol Infect Dis.* 1988;9:69–77.
  44. Cornely O, Arikan-Akdagli S, Dannaoui E, et al. ESCMID and ECMM joint clinical guidelines for the diagnosis and management of mucormycosis 2013. *Clin Microbiol Infect.* 2014;20 suppl 3:5–26.
  45. Samaras K, Markantonatou A, Karapiperis D, et al. *Saksenaea vasiformis* infections: a case of an immunocompetent adult after mild injury and a literature review. *J de Mycologie.* 2019;26:260-264.
  46. Salas V, Pastor FJ, Calvo E, et al. Experimental murine model of disseminated infection by *Saksenaea vasiformis*: successful treatment with posaconazole. *Med Mycol.* 2012;50:710–715.
  47. Sun QN, Fothergill AW, McCarthy DI, et al. *In vitro* activities of posaconazole, itraconazole, voriconazole, amphotericin B, and fluconazole against 37 clinical isolates of zygomycetes. *Antimicrob Agents Chemother.* 2002;46:1581–1582.