

## A Rare Case of Concurrent Herpes Simplex Encephalitis and Glioblastoma Multiforme

### Abstract

Herpes encephalitis superimposed on an intracranial malignancy has previously been described mainly in the context of malignancy imitating infection or in the postoperative setting after neurosurgical intervention. We report a rare case of *de novo* presentation of concurrent herpes encephalitis and glioblastoma. A 63-year-old man presented with status epilepticus and subsequent magnetic resonance imaging (MRI) brain showed a right temporal enhancing lesion with mass effect. He underwent a craniotomy and debulking of this lesion, which on subsequent histology was positive for herpes simplex virus (HSV) antigens and HSV DNA was confirmed by polymerase chain reaction analysis. The sample however also had some hypercellular areas with atypical astrocytes. Our patient recovered well from surgery and was eventually commenced on acyclovir albeit with a delay of 3 weeks due to the initial diagnostic dilemma. However, he re-presented with lethargy and confusion a further 3 weeks later and an MRI scan showed recurrence of the temporal lesion with MR spectroscopy more suggestive of high-grade glioma. He, therefore, underwent a further debulking surgery and the histology revealed a WHO Grade 4 glioblastoma with some residual areas of inflammation. A diagnosis of 2 co-existing pathologies namely HSV encephalitis and glioblastoma was thus reached. Unfortunately, due to poor performance status, he could not undergo chemo-radiotherapy and died 8 months after presentation. Immuno-modulators, expressed locally and globally in glioma patients, are likely to render them susceptible to infections. There are an increasing number of reports of HSV encephalitis in the glioma setting postoperatively. However, we report a *de novo* presentation which has only been recognized once before in the 1970s. Recognition of HSV encephalitis in glioma patients in the *de novo* and also the postoperative context is important for commencing early treatment and preventing poor outcomes.

**Keywords:** Concurrent, encephalitis, glioblastoma, herpes simplex

### Introduction

HSV encephalitis in the context of high grade gliomas/ intracranial malignancy has been previously described in the post-operative phase or after chemo-radiotherapy. Even in this scenario, it is probably under-diagnosed and hence under-reported. We report a rare *de novo* presentation of concurrent HSV encephalitis and glioblastoma, an entity which has only been reported once, in the 1970s.

### Case Report

A 63-year-old man was initially admitted with status epilepticus and was commenced on phenytoin.

Magnetic resonance imaging (MRI) brain [Figure 1] revealed a right temporal lobe enhancing lesion extending into the frontal lobe with extensive surrounding edema

causing significant mass effect with a likely radiological diagnosis of glioblastoma. After discussion at the multi-disciplinary meeting, he underwent craniotomy and right temporal lobectomy for debulking of the lesion with a satisfactory 48-h postoperative MRI [Figure 2] and an uneventful postoperative recovery.

Histology [Figure 3] revealed widespread infarction, with some sparing of cortical layer I. There was an abundance of foamy macrophages and neovascularization. In addition, there was a marked inflammatory infiltrate with lymphocytes (largely CD3-positive T-lymphocytes) distributed throughout the brain parenchyma, with some additional perivascular cuffs. In addition, but less extensively, there were regions that were more hypercellular with atypical astrocytes (some of which were gemistocytic) together with mitotic figures, vascular proliferation and an elevated

**Parag Sayal,  
Arif Zafar<sup>1</sup>,  
Robin Highley<sup>2</sup>**

*Department of Neurosurgery,  
The National Hospital for  
Neurology and Neurosurgery,  
London, Departments  
of <sup>1</sup>Neurosurgery and  
<sup>2</sup>Neuropathology, Hull Royal  
Infirmary, Hull, United Kingdom*

**Address for correspondence:**  
Mr. Parag Sayal,  
Department of Neurosurgery,  
The National Hospital  
for Neurology and  
Neurosurgery, London, WC1N  
3BG, United Kingdom.  
E-mail: [paragsayal@gmail.com](mailto:paragsayal@gmail.com)

Access this article online

Website: [www.asianjns.org](http://www.asianjns.org)

DOI: 10.4103/1793-5482.181141

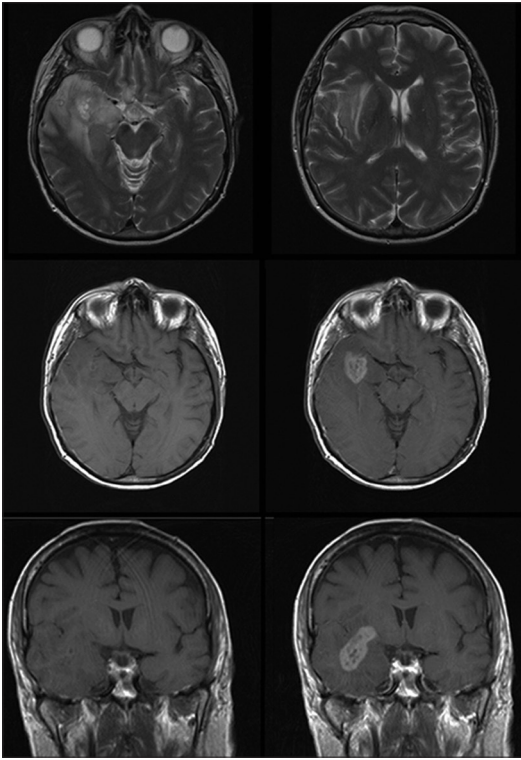
Quick Response Code:



**How to cite this article:** Sayal P, Zafar A, Highley R. A rare case of concurrent herpes simplex encephalitis and glioblastoma multiforme. *Asian J Neurosurg* 2018;13:78-82.

This is an open access article distributed under the terms of the Creative Commons Attribution-NonCommercial-ShareAlike 3.0 License, which allows others to remix, tweak, and build upon the work non-commercially, as long as the author is credited and the new creations are licensed under the identical terms.

For reprints contact: [reprints@medknow.com](mailto:reprints@medknow.com)



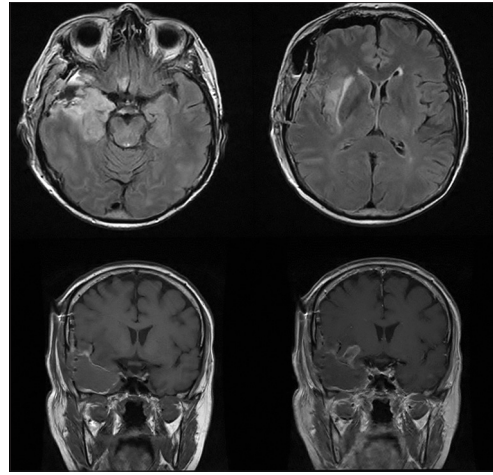
**Figure 1: Preoperative scan prior to first surgery. Axial T2: Increased T2 signal involving grey and white matter in right temporal lobe anteriorly, extending into the right ganglionic region infralaterally within which a reasonably well defined “mass” containing several small “encystic” foci infralaterally is apparent. (Top Row). Axial and coronal T1 ( $\pm$ gadolinium): Enhancement of the central component in the temporal lobe extending into the ganglionic region infralaterally; apart from the foci of cystic change (middle and bottom row)**

Ki67 (Mib1) proliferation index. Immunohistochemistry showed expression of herpes simplex virus (HSV) antigens. Following this, HSV1 DNA was detected by polymerase chain reaction (PCR).

As the inflammatory features were florid and predominant, and in light of the HSV immunohistochemistry and PCR, a diagnosis of HSV encephalitis was made, albeit with the proviso that there may be a neoplastic component on the basis of the astrocyte atypia and evidence of elevated cell turnover. Treatment with acyclovir was eventually started 3 weeks after surgery due to the delay in confirmation of diagnosis.

2 months following his initial surgery, the patient became increasingly lethargic and confused. A repeat MRI [Figure 4] revealed recurrence of his temporal lesion and in view of his equivocal diagnosis, diffusion and perfusion-weighted MRI and MR spectroscopy was performed which revealed features suggesting a highly aggressive tumor. Hence, he underwent re-do craniotomy and debulking of the lesion.

Histology [Figure 5] from the second operation differed from the first specimen by having much more extensive regions of glial hypercellularity with nuclear atypia, an



**Figure 2: Postoperative scan within 48 h of surgery. Axial FLAIR (fluid attenuated inversion recovery): Postoperative cavity from right temporal lobectomy. Residual deep tumor extending into ganglionic region**

elevated Ki67 proliferation index, mitotic figures and dense glial fibrillary acidic protein immunoreactivity. There did remain some residual regions with inflammatory features.

In the light of the clinical and radiological features, an overall diagnosis was made of two pathological processes, namely glioblastoma with superimposed herpes simplex encephalitis. It is likely that the region of higher cell turnover, glial atypia and cellularity in the specimen from the first surgery represented glioblastoma.

Treatment with acyclovir was continued for a further three weeks intravenously. After completion of acyclovir course, the patient underwent a repeat MRI which revealed the progression of the temporal mass. However, it was difficult to comment on whether this was an actual progression of tumor or pseudo-progression secondary to inflammation.

The patient was too unwell for radiotherapy at the time. His condition gradually deteriorated and the patient died 8 months after initial presentation.

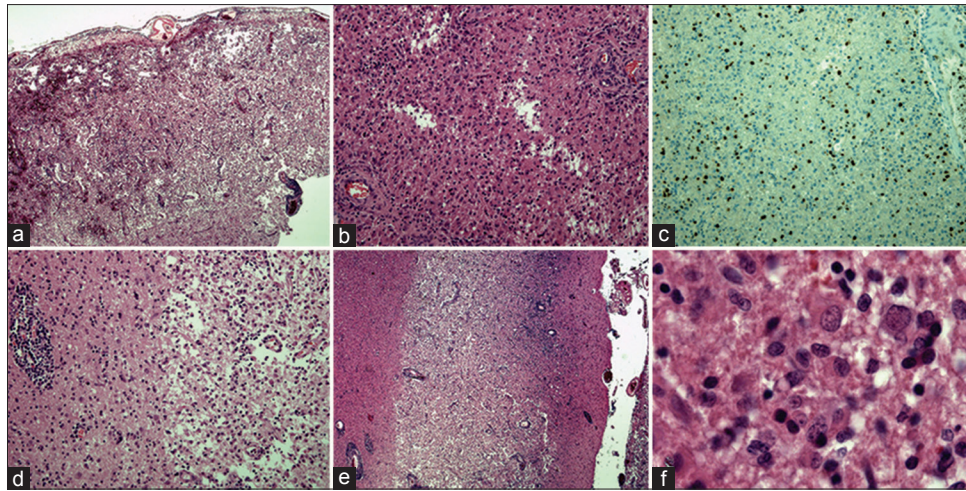
## Discussion

Glioblastoma is renowned for its varied radiological and pathological appearances.<sup>[1,2]</sup> Our patient presented with a lesion in the fronto-temporal lobe which anatomically could be associated with both pathologies however the radiological features appeared to coincide more with glioblastoma. Investigations, however, confirmed this patient to have both pathologies; an exceptionally rare occurrence with only one similar report published in the 1970s.

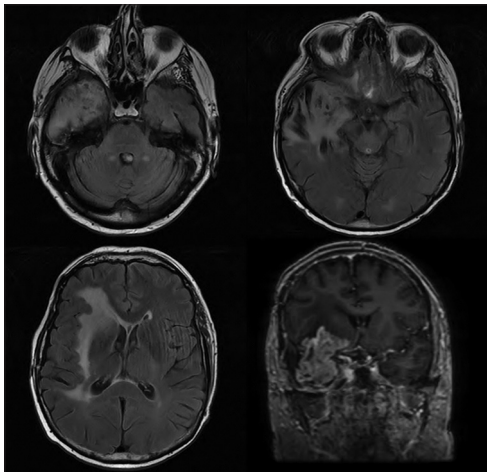
The incidence of encephalitis has been reported to be between 3.5 and 7.4 per 100,000,<sup>[3]</sup> with infection being the main etiological factor. However, autoimmune<sup>[4]</sup> and rarely malignant<sup>[5]</sup> causes have been identified. 60–85%<sup>[6,7]</sup> of patients can have unknown causes.

Herpes encephalitis superimposed on an existing malignancy has been previously described but remains





**Figure 3:** Histology of tissue from the first operation revealed widespread necrosis (a, low power) with hypercellularity (b) on high power. The Ki67 proliferation index was brisk (c). The necrosis showed a laminar pattern with perivascular lymphocytic cuffs (d, high power and e, low power). In a few small foci, astrocytes showed quite marked nuclear atypia (d and f)



**Figure 4:** Preoperative scan prior to second surgery. Axial FLAIR (fluid-attenuated inversion recovery)- post operative cavity effaced by enlargement of the mass. More extensive increased T2 signal anterosuperiorly (Top row). Coronal T1 with gadolinium - enhancing mass now fills the previous postoperative cavity and is more extensive in the right ganglionic region (bottom row)

an exceptionally rare occurrence with little understood regarding pathophysiology. Many papers describe the imitation of malignancies with infection. Granerod *et al.*<sup>[7]</sup> found that four patients initially suspected to have encephalitis were actually found to have primary brain tumors. Other papers have also described similar findings including Whitley *et al.* who found that 3 out of 95 patients who were initially thought to have herpes encephalitis, in fact, were primary brain malignancies.<sup>[8,9]</sup>

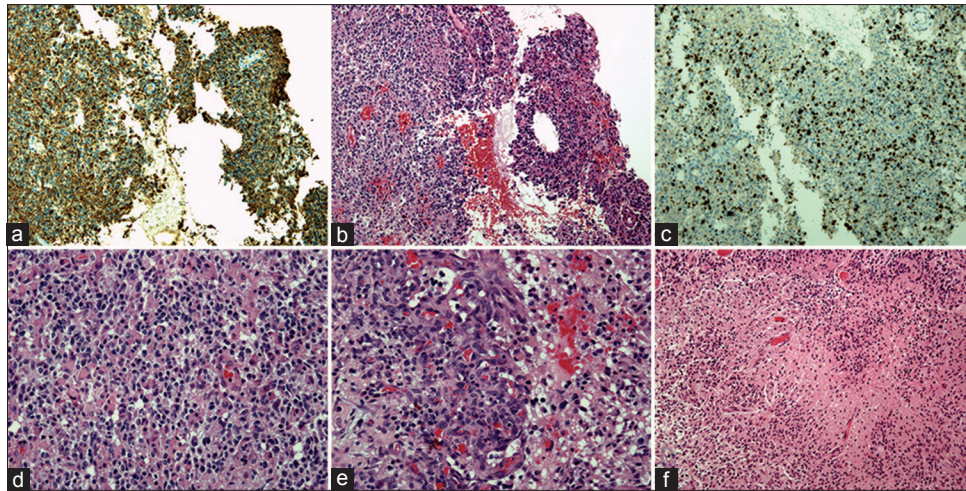
While mimicry has been described, there have also been reported cases of concurrent malignancy and herpes encephalitis. Virtually all these cases describe encephalitis postoperatively after neurosurgical intervention. Whether this is secondary to a reactivation of latent infection, respiratory seeding or even possibly primary infection has

been an issue of much debate and questions have been raised regarding the impact of operative stress and steroid use.<sup>[10]</sup>

The presentation has been described after various surgical approaches with an average time of onset being 6 days post-surgery.<sup>[11]</sup> Clinical symptoms are those of any encephalitis but early diagnosis and commencement of prompt treatment appear to be paramount in such cases.<sup>[12,13]</sup> Three different reported cases, whereby no treatment was commenced, all resulted in mortality.<sup>[14-16]</sup> Many papers report significant morbidity and prognosis is deemed generally poor in most cases.<sup>[17-19]</sup>

A literature search has revealed only one other publication that describes the concurrent presentation of herpes encephalitis and high-grade glioma.<sup>[20]</sup> In this case series which was in the pre-CT scan and PCR analysis era all three patients were confirmed histologically to have concurrent malignant astrocytoma and inclusion body encephalitis but only two of the three cases were confirmed to have herpes virus via direct tissue culture. In another paper, herpes simplex encephalitis PCR was found to be positive in cerebrospinal fluid leading to suspicion of HSV encephalitis. However, specimens from surgery were shown to be histologically glioblastoma with no HSV DNA in the samples.<sup>[21]</sup> This differs to our case where both the PCR and HSV DNA were positive in the resected specimen itself.

Berzero *et al.* recently reported 5 cases of HSV encephalitis in 1750 high-grade glioma patients treated over 5 years.<sup>[22]</sup> These were all in the postoperative chemotherapy phase, known to induce immunosuppression. Glioma cancer stem cells exert immunosuppression of the innate immune system, in addition to inhibition of the adaptive immune response.<sup>[23]</sup> Gliomas possess strong local and global immunosuppressive capabilities though downregulation of



**Figure 5:** Histology of tissue from the second operation showed much more marked hypercellularity with glial fibrillary acidic protein expression in immunohistochemistry (a and b). The Ki67 proliferation index was much higher (c). The cell density and atypia was more marked than in the first specimen (d) and there was vascular proliferation (e) and necrosis (f)

interleukin-2 (IL-2) production, induction of CD-4 T-cell lymphopenia and production of IL-10 and transforming growth factor- $\beta$ .<sup>[24]</sup> We believe that this immunosuppressive milieu played a role in the development of HSV encephalitis in our patient.

Although there is very little evidence of a direct relationship between herpes simplex type I and cancer, the association of certain viruses with malignancy has been long documented with growing interest in vaccination and reducing infection risk as a means of decreasing cancer incidence.<sup>[25,26]</sup> Conversely, it is easy to understand how an area of abnormal cancer cells with altered cellular function could be predisposed to re-activation of a latent infection or susceptible to seeding from systemic pathogens.

As seen in our case, diagnosis remains difficult not just with the concurrent presentation but also in postoperative cases. If a diagnosis of herpes encephalitis is suspected, early commencement of treatment is essential and may contribute to a favorable outcome.<sup>[27]</sup>

An interesting point of discussion is the reported finding of an improved prognosis in some cases of intra-cranial malignancy following an infection. Several published reports have detailed tumor regression or even remission following an infection, in some cases of postoperative onset and others secondary to active treatment using bacterial toxins. A case series documenting postoperative bacterial infections in primary brain tumors documented a significantly prolonged survival in such patients.<sup>[28]</sup> This phenomenon remains rare with limited published data and mostly pertaining to bacterial infections. Other than one case report,<sup>[29]</sup> no such evidence was found regarding viral infections and primary brain tumors.

On the contrary, HSV infection has generally been associated with a poor outcome as also has been shown in our case. Outcome following herpes encephalitis or

glioblastoma multiforme (GBM) individually has generally been reported to be poor with high morbidity and mortality. In a large 12-year retrospective study, the 1-year mortality with HSV encephalitis was 14% and epilepsy was the most common post-infection morbidity.<sup>[30]</sup> Prognosis with GBM has been generally improving in the last decade and yet patients under the age of 70 have an average survival of 13 months.<sup>[31]</sup> Several case reports document herpes encephalitis following neurosurgery with early mortality being the common outcome.<sup>[13]</sup>

Another likely factor contributing to poor outcome is the effect of encephalitis to lead to poor performance status. Encephalitis often leads to significant morbidity and can significantly influence a patient's performance grading. Even if the patient recovers from the episode of encephalitis, it leads to a delay in post-operative chemo or radiotherapy and could effect a patient's general status to such a degree whereby they are unable to tolerate further aggressive therapy.

As discussed, early treatment appears to be the most important factor in these cases and, therefore, we would advocate early use of antivirals in cases where herpes encephalitis is suspected. Surgical intervention remains limited to selected cases.

## Conclusion

While our case is a rare concomitant occurrence of HSV encephalitis and glioblastoma before any treatment, but it probably represents a spectrum of similar cases that occur in the postoperative or radio/chemotherapy phase. We would like to bring to the attention of neuro-oncologists this probably under-reported, uncommon but non-negligible and yet difficult to diagnose entity which leads to significant morbidity/mortality due to delayed diagnosis. We highlight the need for early recognition and treatment of this entity



in the *de novo* and in the post-operative setting in glioma patients as it has significant prognostic implications.

### Financial support and sponsorship

Nil.

### Conflicts of interest

There are no conflicts of interest.

### References

1. Rees JH, Smirniotopoulos JG, Jones RV, Wong K. Glioblastoma multiforme: Radiologic-pathologic correlation. *Radiographics* 1996;16:1413-38.
2. Altman DA, Atkinson DS Jr., Brat DJ. Best cases from the AFIP: Glioblastoma multiforme. *Radiographics* 2007;27:883-8.
3. Granerod J, Crowcroft NS. The epidemiology of acute encephalitis. *Neuropsychol Rehabil* 2007;17:406-28.
4. Irani SR, Vincent A. Autoimmune encephalitis – New awareness, challenging questions. *Discov Med* 2011;11:449-58.
5. Bakheit AM, Kennedy PG, Behan PO. Paraneoplastic limbic encephalitis: Clinico-pathological correlations. *J Neurol Neurosurg Psychiatry* 1990;53:1084-8.
6. Davison KL, Crowcroft NS, Ramsay ME, Brown DW, Andrews NJ. Viral encephalitis in England, 1989-1998: What did we miss? *Emerg Infect Dis* 2003;9:234-40.
7. Granerod J, Ambrose HE, Davies NW, Clewley JP, Walsh AL, Morgan D, *et al.* Causes of encephalitis and differences in their clinical presentations in England: A multicentre, population-based prospective study. *Lancet Infect Dis* 2010;10:835-44.
8. Whitley RJ, Cobbs CG, Alford CA Jr., Soong SJ, Hirsch MS, Connor JD, *et al.* Diseases that mimic herpes simplex encephalitis. Diagnosis, presentation, and outcome. NIAD Collaborative Antiviral Study Group. *JAMA* 1989;262:234-9.
9. Rees JH, Howard RS. High-grade glioma mimicking acute viral encephalitis – Three case reports. *Postgrad Med J* 1999;75:727-30.
10. Graber JJ, Rosenblum MK, DeAngelis LM. Herpes simplex encephalitis in patients with cancer. *J Neurooncol* 2011;105:415-21.
11. Aldea S, Joly LM, Roujeau T, Oswald AM, Devaux B. Postoperative herpes simplex virus encephalitis after neurosurgery: Case report and review of the literature. *Clin Infect Dis* 2003;36:e96-9.
12. Kwon JW, Cho BK, Kim EC, Wang KC, Kim SK. Herpes simplex encephalitis after craniopharyngioma surgery. *J Neurosurg Pediatr* 2008;2:355-8.
13. Kuhnt D, Coras R, Eyupoglu IY, Struffert T, Schellinger PD, Buchfelder M, *et al.* Herpes simplex encephalitis after neurosurgical operations: Report of 2 cases and review of the literature. *J Neurol Surg A Cent Eur Neurosurg* 2012;73:116-22.
14. Spuler A, Blaszyk H, Parisi JE, Davis DH. Herpes simplex encephalitis after brain surgery: Case report and review of the literature. *J Neurol Neurosurg Psychiatry* 1999;67:239-42.
15. Fearnside MR, Grant JM. Acute necrotizing encephalitis complicating bifrontal craniotomy and pituitary curettage. Report of two cases. *J Neurosurg* 1972;36:499-502.
16. Sheleg SV, Nedzved MK, Nedzved AM, Kulichkovskaya IV. Contamination of glioblastoma multiforme with type 1 herpes simplex virus. Case illustration. *J Neurosurg* 2001;95:721.
17. Ochsner F. Contamination of a glioma by the herpes virus. *Schweiz Arch Neurol Neurochir Psychiatr* 1981;129:19-30.
18. Perry JD, Girkin CA, Miller NR, Kerr DA. Herpes simplex encephalitis and bilateral acute retinal necrosis syndrome after craniotomy. *Am J Ophthalmol* 1998;126:456-60.
19. Bourgeois M, Vinikoff L, Lellouch-Tubiana A, Sainte-Rose C. Reactivation of herpes virus after surgery for epilepsy in a pediatric patient with mesial temporal sclerosis: Case report. *Neurosurgery* 1999;44:633-5.
20. Benjamin SP, McCormack LJ, Chatty ME, Dohn DF. Coexistent herpes simplex encephalitis and malignant astrocytoma. A clinicopathologic study of three cases. *Cleve Clin Q* 1972;39:135-43.
21. McDermott SS, McDermott PF, Skare J, Glantz M, Smith TW, Litofsky NS, *et al.* Positive CSF HSV PCR in patients with GBM: A note of caution. *Neurology* 2000;54:746-9.
22. Berzero G, Di Stefano AL, Dehais C, Sanson M, Gaviani P, Silvani A, *et al.* Herpes simplex encephalitis in glioma patients: A challenging diagnosis. *J Neurol Neurosurg Psychiatry* 2015;86:374-7.
23. Wu A, Wei J, Kong LY, Wang Y, Priebe W, Qiao W, *et al.* Glioma cancer stem cells induce immunosuppressive macrophages/microglia. *Neuro Oncol* 2010;12:1113-25.
24. Vega EA, Graner MW, Sampson JH. Combating immunosuppression in glioma. *Future Oncol* 2008;4:433-42.
25. Kuper H, Adami HO, Trichopoulos D. Infections as a major preventable cause of human cancer. *J Intern Med* 2000;248:171-83.
26. Franco EL, Harper DM. Vaccination against human papillomavirus infection: A new paradigm in cervical cancer control. *Vaccine* 2005;23:2388-94.
27. Filipo R, Attanasio G, De Seta E, Viccaro M. Post-operative Herpes simplex virus encephalitis after surgical resection of acoustic neuroma: A case report. *J Laryngol Otol* 2005;119:558-60.
28. Bowles AP Jr., Perkins E. Long-term remission of malignant brain tumors after intracranial infection: A report of four cases. *Neurosurgery* 1999;44:636-42.
29. Kapp JP. Microorganisms as antineoplastic agents in CNS tumors. *Arch Neurol* 1983;40:637-42.
30. Hjalmarsson A, Blomqvist P, Sköldenberg B. Herpes simplex encephalitis in Sweden, 1990-2001: Incidence, morbidity, and mortality. *Clin Infect Dis* 2007;45:875-80.
31. Lawrence YR, Mishra MV, Werner-Wasik M, Andrews DW, Showalter TN, Glass J, *et al.* Improving prognosis of glioblastoma in the 21<sup>st</sup> century: Who has benefited most? *Cancer* 2012;118:4228-34.