

Research Article



Proximity of maxillary molar apexes to the cortical bone surface and the maxillary sinus

Han Shin Lee , Dokyung Kim , Sung Kyo Kim *

Department of Conservative Dentistry, School of Dentistry, Kyungpook National University, Daegu, Korea



Received: Feb 14, 2022

Revised: Jul 6, 2022

Accepted: Jul 6, 2022

Published online: Aug 8, 2022

Lee HS, Kim D, Kim SK

*Correspondence to

Sung Kyo Kim, DDS, MSD, PhD

Professor, Department of Conservative Dentistry, Kyungpook National University School of Dentistry, 2175 Dalgubeol-daero, Jung-gu, Daegu 41940, Korea.
Email: skykim@knu.ac.kr

Copyright © 2022. The Korean Academy of Conservative Dentistry

This is an Open Access article distributed under the terms of the Creative Commons Attribution Non-Commercial License (<https://creativecommons.org/licenses/by-nc/4.0/>) which permits unrestricted non-commercial use, distribution, and reproduction in any medium, provided the original work is properly cited.

Conflict of Interest

No potential conflict of interest relevant to this article was reported.

Author Contributions

Conceptualization: Kim SK, Kim DK, Lee HS.
Data curation: Lee HS. Formal analysis: Lee HS, Kim SK. Investigation: Lee HS, Methodology: Lee HS, Kim SK. Project administration: Kim SK. Resources: Kim DK, Kim SK. Software: Lee HS. Supervision: Kim SK. Validation: Lee HS, Kim DK, Kim SK. Visualization: Lee HS. Writing - original draft: Lee HS. Writing - review & editing: Kim SK.

ABSTRACT

Objectives: This study aimed to analyze the proximity of maxillary molar roots to their overlying cortical bone surfaces and the maxillary sinus.

Materials and Methods: Cone-beam computed tomographic images of 151 patients with completely erupted upper molars that had 3 separate roots were studied. The following distances were measured: from the root apex to the cortical plate and maxillary sinus floor, and from the apical 3-mm level of the root to the cortical plate. Differences between groups were analyzed with 1-way analysis of variance and the Scheffé *post hoc* test, the significance of differences between cone-beam computed tomography views with the paired *t*-test, and the significance of differences among age groups with linear regression analysis. The significance level was set at $p < 0.05$.


Results: The mesiobuccal and distobuccal root apices of maxillary second molars were more distant from the buccal cortical plate than the maxillary first molars ($p < 0.05$). The apical 3-mm level of the mesiobuccal root of the first molar was closer to the buccal cortical bone than the second molar ($p < 0.05$). In the maxillary first molars, the thickness of the buccal cortical bone decreased in all roots with age ($p < 0.05$). In all root apices of both molars, the difference in the vertical level between the maxillary sinus floor and the root apex increased with age ($p < 0.05$).

Conclusions: Awareness of the anatomical profile of maxillary molar apices in relation to the cortical bones and maxillary sinus will be beneficial for apical surgery.

Keywords: Maxillary molar; Proximity; Cortical plate; Maxillary sinus; Endodontic surgery

INTRODUCTION

In planning apical surgery for molar teeth, the surgeon must be sure of the exact apex location and must determine the proximity of the neighboring anatomic structures, including the cortical bone and maxillary sinus [1-3]. From a surgical standpoint, it is most challenging to precisely ascertain where the apex is located in the molar region. To expose the root apices accurately, osteotomy (*i.e.*, removal of the cortical plate) must be performed carefully after locating the apex on radiographs [1].

ORCID iDsHan Shin Lee <https://orcid.org/0000-0003-1242-5447>Dokyung Kim <https://orcid.org/0000-0002-9419-5624>Sung Kyo Kim <https://orcid.org/0000-0002-9160-7187>

Unlike the mandibular molar roots, the maxillary molar roots are located near the maxillary sinus [4]. Due to their close location, periapical lesions originating from the maxillary molars can influence the maxillary sinus, and apical surgery on the maxillary molars may harm the sinus. Several studies have reported maxillary sinus infections transmitted from the maxillary molars [5-9]. Watzek *et al.* [10] showed that 28% of endodontic surgical cases resulted in maxillary sinus perforations. These reports indicate the importance of understanding the anatomical relationship between the molar roots and their adjacent structures for maxillary molar surgery.

Computed tomographic (CT) scans have made it possible to evaluate bony lesions and their relationship to adjacent anatomical structures [11]. Furthermore, CT scans may provide information regarding the lesion and the healing pattern of bone after endodontic treatment [12,13].

The recently developed modality of cone-beam computed tomography (CBCT) has significant advantages over traditional periapical or panoramic radiographs, especially for the localization and evaluation of periapical or periodontal lesions. A systematic review found that CBCT was more effective than conventional radiography for visualizing the location of impacted teeth [14]. Another study compared conventional radiographs and CBCT for periapical and maxillary sinus evaluations and reported that CBCT was significantly more accurate than conventional imaging for identifying lesions and their proximity to the maxillary sinus [15].

Because CBCT scans provide 3-dimensional information on anatomic structures and allow the recognition of the spatial relationship of roots with adjacent structures, the cortical bone thickness over the molar roots and their proximity to the maxillary sinus can be ascertained with CBCT when planning an endodontic surgical procedure for the upper molars.

Therefore, this study aimed to analyze the proximity of the maxillary molar roots to their overlying cortical bones and the relationship between the maxillary molar root and the maxillary sinus by using CBCT images.

MATERIALS AND METHODS

This study received approval from the Institutional Review Board (KNUDH-2020-04-04-01). The PRIRATE 2020 flowchart for the research is shown in **Figure 1**. Imaging records were retrieved from the archives of the Kyungpook National University Dental Hospital in 2019 and 2020. The scanned data were from the Korean population. CBCT scans were obtained using a Pax-Flex 3D imaging system (Vatech, Seoul, Korea) operating at 5 mA and 89 kV, with a 24-second scanning time. Data containing small-volume CBCT scans were evaluated. The CT images were taken with 0.2-mm-thick cross-sectional slices in a 12 × 12 × 8.5 cm field of view using a high-resolution bone algorithm. The reconstruction matrix was 416 × 416 pixels. The images were reconstructed and saved using Ez3Dplus software (Vatech America Inc., Fort Lee, NJ, USA) and a picture archiving and communication system (PACS). The inclusion criteria were as follows: patients at least 17 years of age who had maxillary molars with 3 separate roots. The exclusion criteria were cases missing at least 1 of the 4 maxillary molars, with an apical lesion close to the cortical bone or maxillary sinus, and with teeth that had only 1 or 2 roots. In total, 151 cases (91 men and 60 women) were selected for this study. This study included 298 maxillary first molars and 269 maxillary second molars from patients with a mean age of 33 years (ranging, 17–81 years) (**Table 1**).

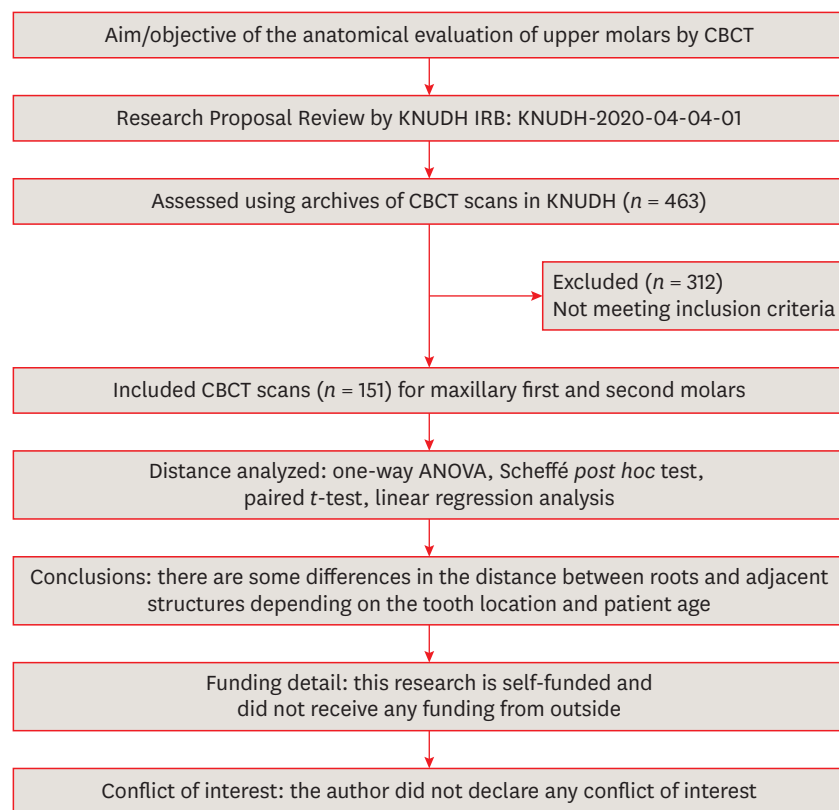


Figure 1. PRIRATE 2020 flowchart for the experimental design.

CBCT, cone-beam computed tomography; KNUDH, Kyungpook National University Dental Hospital; IRB, Institutional Review Board; ANOVA, analysis of variance.

Table 1. Data on the cases included in this study

Age	No.	Male	Female	Number of 3-rooted teeth		
				First molar	Second molar	Total
10–19	14	7	7	28	23	51
20–29	67	45	22	132	129	261
30–39	25	16	9	50	43	93
40–49	22	11	11	42	39	81
50–59	18	9	9	36	27	63
60–69	4	3	1	8	6	14
70–79	0	0	0	0	0	0
80–89	1	0	1	2	2	4
Total	151	91	60	298	269	567

Data acquisition

All teeth were analyzed by measuring the distance from the adjacent buccal or palatal cortical plate to the root apex and to the center of root at 3.0 mm from the apex (**Figure 2**), and the difference in the vertical level from the sinus floor to the root apex. The vertical relationship between the maxillary molar apex and maxillary sinus was categorized as follows (**Figure 3**): type I, protrusion of the root apex into the sinus; type II, the root apex at the same vertical level as the sinus floor; and type III, location of the root apex below the sinus floor.

On the axial and coronal views of the CBCT scans, the distance was measured (Infinitt PACS, Infinitt, Seoul, Korea) in millimeters. The measured values were grouped according to the tooth location and the age of the patient.

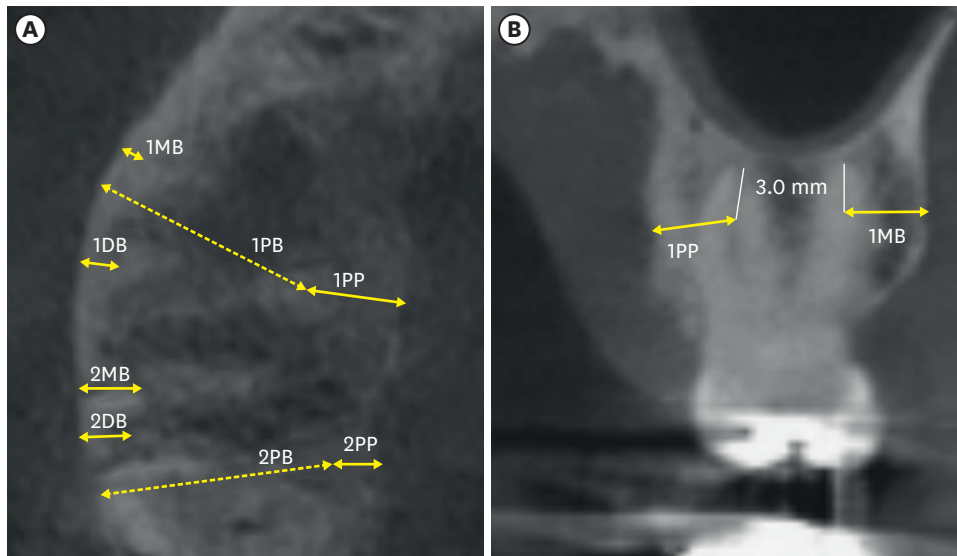


Figure 2. Measurements of root distance from the cortical bone. A. Measurements of the maxillary molar root apex from the axial view of cone-beam computed tomography (CBCT). B. Measurements at the apical 3-mm level of the root from the coronal view of CBCT.

1MB, distance between the first molar mesiobuccal root and the buccal cortical plate; 1DB, distance between the first molar distobuccal root and the buccal cortical plate; 1PB, distance between the first molar palatal root and the buccal cortical plate; 1PP, distance between the first molar palatal root and the palatal cortical plate; 2MB, distance between the second molar mesiobuccal root and the buccal cortical plate; 2DB, distance between the second molar distobuccal root and the buccal cortical plate; 2PB, distance between the second molar palatal root and the buccal cortical plate; 2PP, distance between the second molar palatal root and the palatal cortical plate.

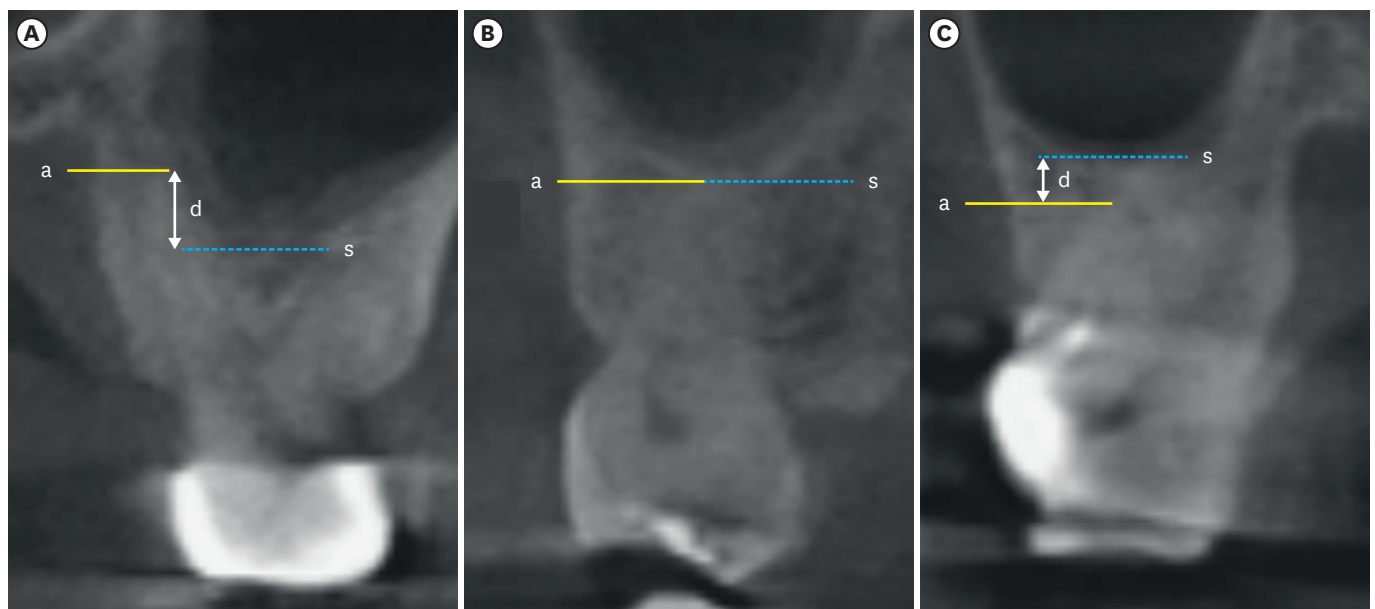


Figure 3. The vertical relationship between the maxillary molar apex and the maxillary sinus floor. (A) Type I, the root apex protruded into the sinus; (B) type II, the root apex was 0 mm from the sinus floor or was at the same vertical level as the sinus floor; and (C) type III, the root apex was below the sinus floor. a, level of root apex; s, level of maxillary sinus floor; d, level distance between root apex and sinus floor.

Statistical analysis

Means \pm standard deviations (SD) were calculated. To evaluate the differences between groups, 1-way analysis of variance and the Scheffé *post hoc* test were used. The paired *t*-test was used to test the significance of differences between CBCT views. Linear regression analysis was used to test the significance of differences among age groups. A *p* value < 0.05 was

considered significant. All statistical analyses were performed with SPSS version 21.0 (IBM Corp., Armonk, NY, USA).

RESULTS

The distance between the root apex and the cortical bone

In both axial and coronal views, the mesiobuccal and distobuccal root apexes of maxillary second molars showed greater distances from buccal cortical bone than the maxillary first molars ($p < 0.05$).

Among the buccal root apexes of the maxillary molars, the closest root to the buccal cortical bone plate was the first molar's mesiobuccal root apex (average value: 3.34 mm) as measured in the axial view (**Table 2**). The mesiobuccal root of the second molar showed the thickest buccal cortical bone among the buccal roots (average value: 5.56 mm). The average distance between the palatal root apex and the palatal cortical bone was 3.52 mm and 3.24 mm in the first and second molars, respectively.

The distance between the 3-mm level from the root apex and the cortical plate

The mesiobuccal root of the first molar was closer to the buccal cortical bone than the same root of the second molar ($p < 0.05$).

In the coronal plane, the closest point to the cortical bone was between the palatal root of the first molar and the palatal cortical plate (average: 3.73 mm) (**Table 3**). The mesiobuccal root of the second molar showed the thickest buccal bone among the buccal roots (6.01 mm).

The proximity of the root apex to the overlying cortical bone in relation to age

A comparison across different age groups is shown in **Table 4**. In the maxillary first molar, the buccal bone thickness tended to decrease in all roots with age ($p < 0.05$), and in the second molar had thinner buccal cortical bone with age (linear regression analysis, $p < 0.05$).

Table 2. The distance from 3-rooted maxillary molar root apices to the adjacent cortical bone in the axial view (mm)

Tooth	No.	Mean \pm SD	Max-Min	
First molar	MB	298	3.34 \pm 1.52	8.48-0.00
	DB	298	3.63 \pm 1.34	7.57-0.87
	P	298	3.52 \pm 1.03	7.67-1.27
Second molar	MB	269	5.56 \pm 1.39	10.98-2.37
	DB	269	4.27 \pm 1.50	8.84-1.68
	P	269	3.24 \pm 1.18	7.29-1.11

SD, standard deviation; MB, mesiobuccal; DB, distobuccal; P, palatal.

Table 3. The distance from the 3-mm level from the root apex to the adjacent cortical bone in the coronal view (mm)

Tooth	No.	Mean \pm SD	Max-Min	
First molar	MB	298	4.59* \pm 1.27	6.67-2.45
	DB	298	4.57 \pm 1.24	5.86-2.17
	P	298	3.73 \pm 0.94	5.13-2.61
Second molar	MB	269	6.01* \pm 1.10	9.51-4.69
	DB	269	4.75 \pm 1.35	8.81-3.43
	P	269	3.81 \pm 1.29	7.11-2.67

SD, standard deviation; MB, mesiobuccal; DB, distobuccal; P, palatal.

* $p < 0.05$ between the first and the second molars.

Table 4. The distance from the root apex to the buccal cortical bone in relation to age in the axial view (mm)

Age	No.	Maxillary first molar			Maxillary second molar		
		MB	DB	P	MB	DB	P
10–19	14	3.81 ± 1.55	4.42 ± 1.50	14.32 ± 1.88	6.37 ± 1.59	4.83 ± 1.19	13.05 ± 1.77
20–29	67	3.58 ± 1.73	3.74 ± 1.39	13.54 ± 2.04	5.74 ± 1.51	4.44 ± 1.56	12.71 ± 1.55
30–39	25	3.47 ± 1.26	3.56 ± 1.17	13.52 ± 1.46	5.49 ± 1.13	3.79 ± 1.11	12.15 ± 1.31
40–49	22	3.03 ± 1.15	3.59 ± 1.13	12.82 ± 1.46	5.72 ± 1.27	4.38 ± 1.58	12.04 ± 1.74
50–59	18	2.61 ± 0.94	3.03 ± 0.88	12.74 ± 1.76	5.11 ± 1.28	3.70 ± 1.41	11.91 ± 1.87
60–69	4	2.26 ± 0.90	2.83 ± 1.74	11.61 ± 0.89	5.59 ± 1.96	4.41 ± 2.14	10.43 ± 2.61
70–79	0						
80–89	1	2.18	1.69	10.41	3.48	1.93	10.45
<i>p</i> value		0.00*	0.02*	0.00*	0.35	0.26	0.00*

Values are presented as mean ± standard deviation.

MB, mesiobuccal; DB, distobuccal; P, palatal.

**p* < 0.05 (linear regression analysis, showing a decrease with age).

The vertical relationship and distance from the root apex to the maxillary sinus floor

Cases where the root apex protruded into the maxillary sinus were marked as negative values (Tables 5 and 6). The mesiobuccal root apex of the second molars showed more frequent type I and less frequent type III configurations than those of the first molars. The mesiobuccal root apex of the second molars was closer to the maxillary sinus floor than that of the first molars, albeit without statistical significance. Only the mesiobuccal root apex of the maxillary second molar slightly protruded into the maxillary sinus (average: 0.1 mm). The palatal root apex of the second molars was located further from the maxillary sinus floor than that of the first molars (*p* < 0.05).

Table 5. The vertical relationship between maxillary molar apices and the maxillary sinus (coronal view)

Tooth	No.	Type I	Type II	Type III	Mean ± SD	
First molar	MB	298	28.86%	24.16%	46.98%	0.67 ± 2.71
	DB	298	26.17%	30.54%	43.29%	0.59 ± 2.39
	P	298	30.11%	25.50%	43.62%	0.62* ± 2.83
Second molar	MB	269	41.26%	28.25%	30.48%	-0.05 ± 2.19
	DB	269	30.87%	28.25%	41.64%	0.56 ± 2.44
	P	269	14.50%	29.00%	56.51%	1.49* ± 2.63

Mean ± SD values represent the distance from the root apex to the maxillary sinus floor in millimeters. A negative value means type I.

Type I, protrusion of the root apex into the sinus; type II, the root apex at the same vertical level as the sinus floor; type III, location of the root apex below the sinus floor; SD, standard deviation; MB, mesiobuccal; DB, distobuccal; P, palatal.

**p* < 0.05 between the first and the second molars for the vertical distance from the root apices to the maxillary sinus.

Table 6. The distance from the root apex to the maxillary sinus floor according to age (mm)

Age	No.	Maxillary first molar			Maxillary second molar		
		MB	DB	P	MB	DB	P
10–19	14	-0.69 ± 2.55	-0.87 ± 2.38	-0.42 ± 1.94	-1.51 ± 2.04	-0.86 ± 1.11	-0.31 ± 1.77
20–29	67	0.23 ± 2.64	0.06 ± 1.97	-0.29 ± 2.58	-0.47 ± 1.58	-0.20 ± 1.78	0.59 ± 2.12
30–39	25	0.34 ± 1.58	0.11 ± 1.51	0.87 ± 2.40	0.05 ± 1.87	1.15 ± 1.80	2.07 ± 2.73
40–49	22	1.16 ± 1.69	0.82 ± 1.91	1.49 ± 2.25	0.60 ± 1.86	1.31 ± 2.45	2.36 ± 2.65
50–59	18	2.35 ± 2.69	2.33 ± 2.52	3.18 ± 3.09	1.81 ± 2.29	2.48 ± 2.98	2.92 ± 2.58
60–69	4	2.55 ± 2.52	2.86 ± 2.57	3.72 ± 3.70	1.76 ± 4.10	3.33 ± 4.82	4.42 ± 4.86
70–79	0						
80–89	1	3.68	4.52	4.08	5.14	8.41	8.62
<i>p</i> value		0.00*	0.00*	0.01*	0.00*	0.00*	0.02*

Values are presented as mean ± standard deviation.

MB, mesiobuccal; DB, distobuccal; P, palatal.

**p* < 0.05 (linear regression analysis, showing that the distance from root apex to maxillary sinus floor increased with age).

In all root apexes of both molars, the vertical distance between the maxillary sinus and the root apex increased with age (linear regression analysis, $p < 0.05$) (Table 6).

DISCUSSION

The present study used CBCT scans to analyze the proximity of the root apex of maxillary molar teeth to cortical bone and the maxillary sinus. Through endodontic microsurgery, the cause of failure of previous non-surgical root canal therapy can be effectively removed, including remaining pathogens in the apical area [16,17]. When planning apical surgery, it is necessary to accurately evaluate the surrounding structures because the surgical procedure includes osteotomy and root resection. Therefore, the spatial relationship between the root apex, overlying cortical bone, and the maxillary sinus is a very important factor [18].

In the present study, root apexes were used as anatomical landmarks, the proximity of which to the cortical plate and maxillary sinus was analyzed. Even though a single mesiobuccal root may contain 1, 2, or 3 canals and an isthmus in between, 1 prominent root apex of the mesiobuccal root was used as an anatomical landmark [19].

In this study, the mesiobuccal and distobuccal root apexes of maxillary second molars were more distant from the buccal cortical bone than those of maxillary first molars. This finding for the maxillary molars is in accordance with the previous finding for the mandibular molars, in that the buccal cortical bone is thicker in the second molar than in the first molar [20]. In previous studies, the mesiobuccal root of the upper second molar was located farthest from the buccal cortical plate. However, this root was the closest to the maxillary sinus floor [21-23].

In the present study, there was a tendency for buccal cortical bone thickness to decrease with age, especially over the maxillary first molar roots. This finding may be related to factors such as vitamin D deficiency, decreased osteoblast function, decreased growth hormone, and decreased maximum bone mass [24,25]. Furthermore, these results also align with a study reporting that skeletal aging starts after an individual reaches peak bone mass, followed by progressive bone loss [26]. That study also showed that changes in bone quality and quantity take place during growth and subsequent aging [26]. A National Institutes of Health report showed that up to 90% of peak bone mass is acquired by age 18 in girls and by age 20 in boys [27].

Some studies have also been conducted on differences in the thickness of buccal cortical bone [17,26,28]. Most of these studies investigated the proximity of the root apex to the cortical plate, but in endodontic microsurgery, the operation is actually performed at the apical 3-mm level. Therefore, in this study, the distance from the apical 3 mm of the root to the cortical bone was also measured. Most irregularities in the root system are located within 3 mm of the apex, and most problems can be eliminated through 3-mm root resection and 3-mm retrograde filling [17,18,29-32]. In the present study, the thickness of overlying cortical bone over the maxillary second molars was significantly greater than that over the first molars, especially on the mesiobuccal root. Therefore, more cortical bone needs to be removed to reach the root of the maxillary second molar than to reach the root of the first molar during surgery.

The maxillary sinus gradually changes in size with age [33]. At the age of 12, it is located at the level of the nasal floor, and at the age of about 20, it reaches its largest size and descends to the lowest point [34,35]. Although the relationship between the root of the maxillary molars is affected by changes in the position of the maxilla, little information in the literature exists on whether the position of the teeth in the maxillary molars changes. According to previous studies in Brazil and Turkey, 10% to 14.3% of molar apexes protruded into the maxillary sinus and more than 20% were in contact [36,37]. However, a higher percentage of cases showed protrusion into the maxillary sinus in the present study in the Korean population.

In all root apices of both molars, the vertical distance between the maxillary sinus and the root apex increased with age. This finding may be related to a previous study showing that older patients had smaller maxillary sinuses in terms of volume, regardless of sex and edentulism status [26]. This finding may also be related to another study that found that maxillary sinuses tended to grow smaller with older age [28].

CBCT has recently been used in endodontics increasingly often [38]. CBCT scans provide clinically necessary information that cannot be seen on periapical radiographs [39-41]. If the CBCT is performed according to appropriate indications, CBCT may increase accuracy in both non-surgical and surgical endodontics without violating the radiation safety guidelines [42].

CONCLUSIONS

Within the limits of this study, these findings regarding the distance from the maxillary molar root apex to the cortical bone and the vertical relationship of the root apex to the maxillary sinus may provide essential information for clinical endodontic surgery. Understanding the anatomical profile of the maxillary molars in relation to the surrounding cortical bone and maxillary sinus will be beneficial for apical surgery.

REFERENCES

1. Maggiore F, Kim S. Chapter 7. Osteotomy. In: Kim S, Kratchman S, editors. *Microsurgery in endodontics*. Hoboken, NJ: Wiley Blackwell; 2018. p57-65.
2. Punwutikorn J, Waikakul A, Pairuchvej V. Clinically significant oroantral communications--a study of incidence and site. *Int J Oral Maxillofac Surg* 1994;23:19-21.
[PUBMED](#) | [CROSSREF](#)
3. Oberli K, Bornstein MM, von Arx T. Periapical surgery and the maxillary sinus: radiographic parameters for clinical outcome. *Oral Surg Oral Med Oral Pathol Oral Radiol Endod* 2007;103:848-853.
[PUBMED](#) | [CROSSREF](#)
4. Hauman CH, Chandler NP, Tong DC. Endodontic implications of the maxillary sinus: a review. *Int Endod J* 2002;35:127-141.
[PUBMED](#) | [CROSSREF](#)
5. Arijji Y, Obayashi N, Goto M, Izumi M, Naitoh M, Kurita K, Shimozato K, Arijji E. Roots of the maxillary first and second molars in horizontal relation to alveolar cortical plates and maxillary sinus: computed tomography assessment for infection spread. *Clin Oral Investig* 2006;10:35-41.
[PUBMED](#) | [CROSSREF](#)
6. Bornstein MM, Wasmer J, Sendi P, Janner SF, Buser D, von Arx T. Characteristics and dimensions of the Schneiderian membrane and apical bone in maxillary molars referred for apical surgery: a comparative radiographic analysis using limited cone beam computed tomography. *J Endod* 2012;38:51-57.
[PUBMED](#) | [CROSSREF](#)

7. Lu Y, Liu Z, Zhang L, Zhou X, Zheng Q, Duan X, Zheng G, Wang H, Huang D. Associations between maxillary sinus mucosal thickening and apical periodontitis using cone-beam computed tomography scanning: a retrospective study. *J Endod* 2012;38:1069-1074.
[PUBMED](#) | [CROSSREF](#)
8. Phothikhun S, Suphanantachat S, Chuenchompoonut V, Nisapakultorn K. Cone-beam computed tomographic evidence of the association between periodontal bone loss and mucosal thickening of the maxillary sinus. *J Periodontol* 2012;83:557-564.
[PUBMED](#) | [CROSSREF](#)
9. Shanbhag S, Karnik P, Shirke P, Shanbhag V. Association between periapical lesions and maxillary sinus mucosal thickening: a retrospective cone-beam computed tomographic study. *J Endod* 2013;39:853-857.
[PUBMED](#) | [CROSSREF](#)
10. Watzek G, Bernhart T, Ulm C. Complications of sinus perforations and their management in endodontics. *Dent Clin North Am* 1997;41:563-583.
[PUBMED](#) | [CROSSREF](#)
11. Cotti E, Vargiu P, Dettori C, Mallarini G. Computerized tomography in the management and follow-up of extensive periapical lesion. *Endod Dent Traumatol* 1999;15:186-189.
[PUBMED](#) | [CROSSREF](#)
12. Aggarwal V, Singla M. Use of computed tomography scans and ultrasound in differential diagnosis and evaluation of nonsurgical management of periapical lesions. *Oral Surg Oral Med Oral Pathol Oral Radiol Endod* 2010;109:917-923.
[PUBMED](#) | [CROSSREF](#)
13. Dhamija R, Tewari S, Sangwan P, Duhan J, Mittal S. Impact of platelet-rich plasma in the healing of through-and-through periapical lesions using 2-dimensional and 3-dimensional evaluation: a randomized controlled trial. *J Endod* 2020;46:1167-1184.
[PUBMED](#) | [CROSSREF](#)
14. Eslami E, Barkhordar H, Abramovitch K, Kim J, Masoud MI. Cone-beam computed tomography vs conventional radiography in visualization of maxillary impacted-canine localization: a systematic review of comparative studies. *Am J Orthod Dentofacial Orthop* 2017;151:248-258.
[PUBMED](#) | [CROSSREF](#)
15. Low KM, Dula K, Bürgin W, von Arx T. Comparison of periapical radiography and limited cone-beam tomography in posterior maxillary teeth referred for apical surgery. *J Endod* 2008;34:557-562.
[PUBMED](#) | [CROSSREF](#)
16. Siqueira JF Jr. Aetiology of root canal treatment failure: why well-treated teeth can fail. *Int Endod J* 2001;34:1-10.
[PUBMED](#) | [CROSSREF](#)
17. Johnson BR, Fayad MI. Periradicular surgery. In: Hargreaves KM, Berman LH, editors. *Cohen's pathways of the pulp*. 11th ed. Philadelphia, PA: Elsevier Inc.; 2016. P387-446.
18. Kim S. Chapter 9. Osteotomy and apical root resection. In: *Color atlas of microsurgery in endodontics*. Philadelphia, PA: Saunders; 2000.
19. Vertucci FJ. Root canal anatomy of the human permanent teeth. *Oral Surg Oral Med Oral Pathol* 1984;58:589-599.
[PUBMED](#) | [CROSSREF](#)
20. Kim D, Ha JH, Jin MU, Kim YK, Kim SK. Proximity of the mandibular molar root apex from the buccal bone surface: a cone-beam computed tomographic study. *Restor Dent Endod* 2016;41:182-188.
[PUBMED](#) | [CROSSREF](#)
21. Degerness RA, Bowles WR. Dimension, anatomy and morphology of the mesiobuccal root canal system in maxillary molars. *J Endod* 2010;36:985-989.
[PUBMED](#) | [CROSSREF](#)
22. Eberhardt JA, Torabinejad M, Christiansen EL. A computed tomographic study of the distances between the maxillary sinus floor and the apices of the maxillary posterior teeth. *Oral Surg Oral Med Oral Pathol* 1992;73:345-346.
[PUBMED](#) | [CROSSREF](#)
23. Jin GC, Kim KD, Roh BD, Lee CY, Lee SJ. Buccal bone plate thickness of the Asian people. *J Endod* 2005;31:430-434.
[PUBMED](#) | [CROSSREF](#)
24. Goltzman D. The aging skeleton. *Adv Exp Med Biol* 2019;1164:153-160.
[PUBMED](#) | [CROSSREF](#)
25. Velasco-Torres M, Padial-Molina M, Avila-Ortiz G, García-Delgado R, O'Valle F, Catena A, Galindo-Moreno P. Maxillary sinus dimensions decrease as age and tooth loss increase. *Implant Dent* 2017;26:288-295.
[PUBMED](#) | [CROSSREF](#)

26. Kang SH, Kim BS, Kim Y. Proximity of posterior teeth to the maxillary sinus and buccal bone thickness: a biometric assessment using cone-beam computed tomography. *J Endod* 2015;41:1839-1846.
[PUBMED](#) | [CROSSREF](#)
27. NIH Osteonecrosis and Related Bone Diseases National Resource Center. NIH Pub. No. 18-7891. Osteoporosis: peak bone mass in women. Bethesda, MD: National Institutes of Health; 2018.
28. Timock AM, Cook V, McDonald T, Leo MC, Crowe J, Benninger BL, Covell DA Jr. Accuracy and reliability of buccal bone height and thickness measurements from cone-beam computed tomography imaging. *Am J Orthod Dentofacial Orthop* 2011;140:734-744.
[PUBMED](#) | [CROSSREF](#)
29. De Deus QD, Horizonte B. Frequency, location, and direction of the lateral, secondary, and accessory canals. *J Endod* 1975;1:361-366.
[PUBMED](#) | [CROSSREF](#)
30. Seltzer S, Soltanoff W, Bender IB, Ziontz M. Biologic aspects of endodontics, I. Histologic observations of the anatomy and morphology of root apices and surrounding structures. *Oral Surg Oral Med Oral Pathol* 1966;22:375-385.
[CROSSREF](#)
31. Wada M, Takase T, Nakanuma K, Arisue K, Nagahama F, Yamazaki M. Clinical study of refractory apical periodontitis treated by apicectomy. Part 1. Root canal morphology of resected apex. *Int Endod J* 1998;31:53-56.
[PUBMED](#) | [CROSSREF](#)
32. Kim S. Principles of endodontic microsurgery. *Dent Clin North Am* 1997;41:481-497.
[PUBMED](#) | [CROSSREF](#)
33. Jun BC, Song SW, Park CS, Lee DH, Cho KJ, Cho JH. The analysis of maxillary sinus aeration according to aging process; volume assessment by 3-dimensional reconstruction by high-resolucional CT scanning. *Otolaryngol Head Neck Surg* 2005;132:429-434.
[PUBMED](#) | [CROSSREF](#)
34. Sharan A, Madjar D. Maxillary sinus pneumatization following extractions: a radiographic study. *Int J Oral Maxillofac Implants* 2008;23:48-56.
[PUBMED](#)
35. Louie AF. Surgical and radiologic anatomy for oral implantology. 1st ed. Hanover: Quintessence Publishing; 2013
36. Pagin O, Centurion BS, Rubira-Bullen IR, Alvares Capelozza AL. Maxillary sinus and posterior teeth: accessing close relationship by cone-beam computed tomographic scanning in a Brazilian population. *J Endod* 2013;39:748-751.
[PUBMED](#) | [CROSSREF](#)
37. Kilic C, Kamburoglu K, Yuksel SP, Ozen T. An assessment of the relationship between the maxillary sinus floor and the maxillary posterior teeth root tips using dental cone-beam computerized tomography. *Eur J Dent* 2010;4:462-467.
[PUBMED](#) | [CROSSREF](#)
38. Rigolone M, Pasqualini D, Bianchi L, Berutti E, Bianchi SD. Vestibular surgical access to the palatine root of the superior first molar: "low-dose cone-beam" CT analysis of the pathway and its anatomic variations. *J Endod* 2003;29:773-775.
[PUBMED](#) | [CROSSREF](#)
39. Rabiee H, McDonald NJ, Jacobs R, Aminlari A, Inglehart MR. Endodontics program directors', residents', and endodontists' considerations about CBCT-related graduate education. *J Dent Educ* 2018;82:989-999.
[PUBMED](#) | [CROSSREF](#)
40. Kalender A, Aksoy U, Basmaci F, Orhan K, Orhan AI. Cone-beam computed tomography analysis of the vestibular surgical pathway to the palatine root of the maxillary first molar. *Eur J Dent* 2013;7:35-40.
[PUBMED](#) | [CROSSREF](#)
41. Kim SY, Kim BS, Woo J, Kim Y. Morphology of mandibular first molars analyzed by cone-beam computed tomography in a Korean population: variations in the number of roots and canals. *J Endod* 2013;39:1516-1521.
[PUBMED](#) | [CROSSREF](#)
42. American Association of Endodontists/American Academy of Oral and Maxillofacial Radiography. AAE and AAOMR joint position statement. Use of cone-beam-computed tomography in endodontics. *Pa Dent J (Harrisb)* 2011;78:37-39.
[PUBMED](#)