

**Received:** 2011.12.01  
**Accepted:** 2012.01.20  
**Published:** 2012.08.16

## Maxillary and orbital brown tumor of primary hyperparathyroidism

Eshagh Bahrami<sup>1</sup>, Tabibkhoodie Alireza<sup>1</sup>, Hejazian Ebrahim<sup>2</sup>,  
 Saatian Mohammadreza<sup>1</sup>

<sup>1</sup> Department of Neurosurgery, Rasool Hospital, Tehran, Iran

<sup>2</sup> Babol University of Medicine, Babol, Mazandaran, Iran

### Summary

**Background:**

Brown tumors have rarely been described as involving the orbital bones. In this article we present the radiological and clinical properties, diagnosis and treatment of an orbital brown tumor case with primary HPT caused by parathyroid adenoma.

**Case Report:**

A 38-year-old woman presented with left-sided facial pain and history of leg pain from 1.5 years before that time, with walking difficulties. In imaging, left maxillary erosion was found. She underwent an excisional biopsy and the mass was diagnosed histologically as eosinophilic granuloma. A few months later the patient had right-sided facial pain again and progressive visual loss. In images, fluid-fluid level was noted in the cystic component of the mass. Right side exophthalmus and downward deviation of the globe was seen. Magnetic resonance imaging showed a well-defined extra-conal complex mass, with hypointense on T-1 and hyperintense on T-2 weighted images with fluid-fluid levels. Postoperatively the patients vision improved dramatically. Excision of the parathyroid adenoma normalized her metabolic status.

**Conclusions:**

Brown tumor is an extremely rare manifestation of primary HPT. Delay in diagnosis can result in unnecessary complications. The management is multi-disciplinary, and therapeutic options should target the underlying cause.

**key words:**

**brown tumor • orbit • primary hyperparathyroidism**

**Full-text PDF:**

<http://www.amjcaserep.com/fulltxt.php?ICID=883325>

**Word count:**

1357

**Tables:**

1

**Figures:**

2

**References:**

27

**Author's address:**

Tabibkhoodie Alireza, No 1, Golha Avenue, 38<sup>th</sup> West Avenue, South Allame Tabatabaei Avenue, Saadat abad, Tehran, Iran

## BACKGROUND

Brown tumors represent localized bony accumulations of fibrous tissue and giant cells that can occur in patients with primary, secondary and tertiary hyperparathyroidism (HPT). They appear as well-defined lesions of the skeleton, most commonly in the ribs, clavicle, pelvic girdle and mandible. Only 16 cases have been reported in the orbit and except for 2 cases, all presented as single lesions [1–14].

In 1891 Von Reckling Housen recognized the clinical impact of hyperparathyroidism (HPT) and described osteitis fibrosa cystica as the pathognomonic bone lesion of this entity. In 1962 Mandle operated on a parathyroid tumor in a patient with hypercalcemia and radiological changes of osteitis fibrosa cystica, and demonstrated post-operative regression of the bone disease and biochemical abnormalities. Incidence of primary HPT has been reported as approximately 5 per 10,000 population per year. Among patients over 60 years of age the frequency is even higher, approaching nearly 1 per 1000 in men and twice that in women [6,15–19].

The term "brown tumor" is derived from the characteristic appearance of brownish material within the cystic lesion. This appearance is due to blood pigments that are both free and within Hemosiderin-Laden macrophages [9,10,13,14]. While renal calculi has been reported in 10–25% of primary HPT, frequency of bone disease has been reported as 10–20% [20].

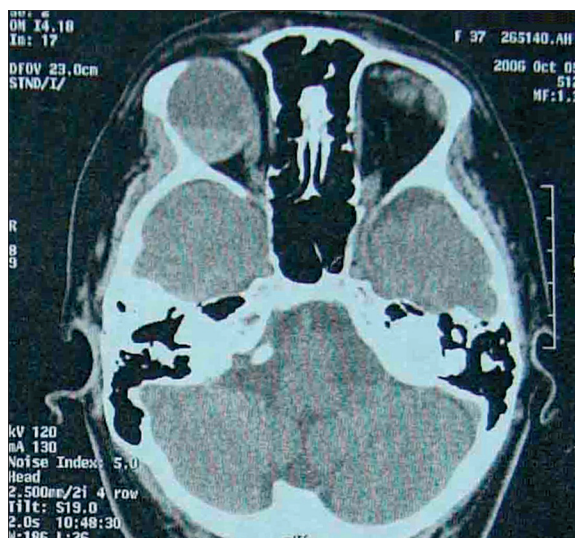
Brown tumors have rarely been described as involving the orbital bones [15]. In this article we present the radiological and clinical properties, diagnosis and treatment of an orbital brown tumor case with primary HPT caused by parathyroid adenoma.

## CASE REPORT

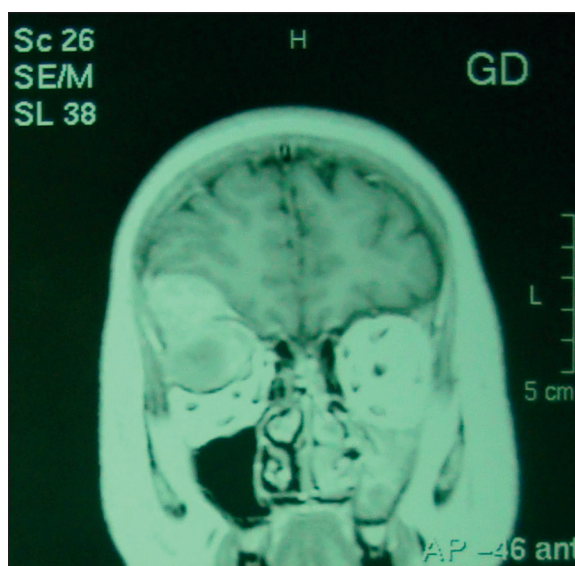A 38-year-old woman had left sided facial pain in 2006. The first diagnosis was sinusitis. She had a history of sever leg pain from 1.5 years ago, with walking difficulties. In imaging, left maxillary erosion was found. At that time, she underwent an excisional biopsy and the mass was diagnosed histologically as eosinophilic granuloma. A few months later the patient had right-sided facial pain again and consequently progressive visual loss, proptosis, deformity and peri-orbital edema of the right eye, which gradually aggravated. In 2007, urge incontinency, sever leg pain and movement restriction appeared.

Neurological examination revealed moderate-to-severe-paraparesis, 2/5–3/5 muscle forces, detected. On ophthalmologic examination, right visual acuity was 6/10 without correction and 10/10 with correction. Visual acuity of the left eye was 10/10. Marcus Gunn pupil was not found. Obvious right-sided proptosis and inferior displacement of the globe were seen. Funduscopic examination revealed no optic neuropathy. Due to mass compression, there was macular folding. Computed tomography demonstrated a well-defined extra-conal solid cystic mass in the superior-lateral part of the right orbit, extending to the anterior cranial fossa. Extra-cranial component was noted (Figure 1).

In contrast images, fluid-fluid level was noted in the cystic component of the mass. There were exophthalmus of right



**Figure 1.** Axial CT-Scan without contrast, intra-orbital mass with fluid-fluid level.



**Figure 2.** Coronal T1-weighted MRI with contrast, orbital roof destruction by the enhancing mass.

eye and downward deviation of the globe. Magnetic resonance imaging showed a well-defined extra-conal complex mass with hypo-intense on T-1 and hyper-intense on T-2 weighted images, with fluid-fluid levels (Figure 2).

Following resection of the mass with trans-cranial surgery, the patient's proptosis disappeared.

The histological studies revealed bone tissue involved by a benign lesion composed of large spaces filled with blood interspaced by fibrous septations containing mononuclear cells with round-to-spindle vesicular nuclei, multinucleated osteoclasts like giant cells and an area of osteoid formation. Fragments of bony trabecular were also seen.

About 1 month after trans-cranial resection of the orbital mass, she developed proptosis in her right eye and mild

**Table 1.** Table shows the summary of brown tumor cases in facial bones which has been reported up to 2010.

Age/sex	Country	Site of brown tumor	Cause of brown tumor	Year of study [references]
24/M		Floor, Medial & Lat wall of orbit	Secondary HPT	2010 [9]
21/F		Lateral wall of orbit	Secondary HPT	2010 [9]
42/F	Greek	Maxillary sinus	Primary HPT	2009 [12]
58/F	Brazil	Maxilla & Mandible	Tertiary HPT	2009 [3]
40/F		Multiple brown tumor of orbit (temporal & frontal orbital margin)	Secondary HPT (CRF)	2008 [1]
29/M	Sanfransisco	Superior orbit & frontal calvarium	Secondary HPT (CRF)	2006 [4]
71/F		Right nasal fossa (epistaxis)	Primary HPT	2005 [6]
62/F	Turkey	Mandible	Primary HPT	2004 [14]
59/F	Turkey	Sellar para-sellar site	Primary HPT	2004 [21]
47/F	Japan (Ishihara Hospital)	Sphenoid sinus	Secondary HPT (ESRD)	2004 [8]
16/F	Spain	Anterior part of mandible	Primary HPT	2004 [11]
7/F		Ethmoid & posterior orbit (lethargy and eye rubbing)	Secondary HPT (CRF)	1986 [15]
44/F		Maxillary sinus (retro-orbital)	Secondary HPT	1983 [5]
70/F		Orbital ridge	Primary HPT	1980 [7]
24/F		Retro-orbital	Secondary HPT (CRF)	1977 [23]

supraduction restriction. Visual acuity and intra-ocular pressure of both eyes were normal. Concurrent laboratory studies showed the elevation of parathyroid hormone (PTH) to 750 (NL: 10-65) and elevation of alkaline phosphatase to 1250 (NL: 64-306). Serum calcium and phosphate were 12.5 and 1 mg/dl, respectively. Serum mg, sodium, potassium, and liver enzyme levels were in normal range. Urinary tract sonography was normal, but thyroid and parathyroid evaluation showed a well-defined 11.7 mm diameter hypochoic mass within the posterior part of the right thyroid lobe and the medial to the right common carotid artery.

According to the parathyroid sonography, the suspicious right superior parathyroid adenoma was resected.

Histopathological studies revealed benign parathyroid proliferation, suggesting an adenoma. The diagnosis of brown tumor was confirmed by clinical, laboratory and histopathological findings.

Postoperatively the patients vision improved dramatically. Excision of the parathyroid adenoma normalized her metabolic status. At her follow-up examination, her disease was under control and she was independent in her daily activities but still had walking difficulties, urge incontinency.

## DISCUSSION

Although there have been previous reports of brown tumor of HPT affecting the orbit and skull, the present case raises

important issues regarding the management of brown tumors in patients with primary HPT.

## Review of literature

Osteitis fibrosa cystica is a focal osteoclastic defect of bone, resulting from primary, secondary or tertiary HPT, which leads to formation of cysts, usually affecting the pelvis, ribs, clavicles and extremities. These cysts may become filled with fibrous tissue. If the highly vascularized fibrous tissue contains spots of hemorrhage, blood pigment (hemosiderin) will accumulate, which imparts a reddish-brown hue and gives the lesion its name of "brown tumor", a reparative cellular process and not a true neoplasm. The association between osteitis fibrosa cystica and parathyroid adenoma was first recorded in 1904 by Askanazy, whereas the link between PTH and calcium metabolism was not described until 1915. The incidence of brown tumor is 3% in primary HPT and it is caused by adenoma or hyperplasia of the parathyroid gland. In secondary HPT, the incidence of brown tumor is 1.5% to 1.7%, and it is caused by chronic renal failure [12,21,22].

There is a paucity of reports describing the atypical location of Brown tumor involving the orbit, the maxillofacial bones, the clavicles and the cervical spine. Patients with Brown tumors in the orbit may have a mass, proptosis, pain, diplopia, decreased extra ocular motility or decreased visual acuity. Brown tumors arise more frequently in the mandible than in maxilla [6] (Table 1).

## Diagnosis

The diagnosis of HPT is made by PTH assay. The intact PTH assay has become the most widely used, and is readily available. Complemented by the elevation of alkaline phosphatase, high ionic calcium and low phosphate [22,24]. A definite diagnosis is only possible on completion of the clinical, radiological, and biochemical analysis. Brown tumors exhibit no pathognomonic histologic changes and differentiating between a brown tumor and other giant cell tumors may be very difficult, even with histology. Fibrous dysplasia affects the bones of the face, and it is most common among young women [4,12]. The differential diagnosis (DDX) considered in the present case, based on clinical and radiologic findings, included osteosarcoma, metastatic lesions, aneurysmal bone cyst, eosinophilic granuloma, cholesteatoma, and adenoid cystic carcinoma of the lacrimal gland. The histopathologic DDX included giant cell tumor of bone, aneurysmal bone cyst, osteosarcoma and brown tumor of HPT.

## Treatment

Parathyroidectomy is the treatment of choice for primary HPT. However, opinions are divided as to the treatment of bone lesions. Authors such as Scott et al. [25] believe that bone lesions reappear spontaneously following removal of the diseased parathyroid gland. Others, such as Martínez-Gavidia et al. [26], recommended initial treatment with systemic corticosteroids in order to reduce the tumor size, followed by surgical removal of the residual lesions. In the case of large destructive cysts, the amount of tissue damaged may be so great that there are few possibilities of remodeling once normocalcemia has been achieved. Yamazaki et al. [27] recommended curettage and enucleation in these situations or in cases where the lesions continue for more than 6 months, there is disruption of the function of the affected organ, or growth despite adequate metabolic control. Curative surgical ablation for parathyroid adenoma/hyperplasia includes resection of the adenoma and subtotal and total parathyroidectomy, coupled with subcutaneous auto-transplantation [16,18,19,22].

## CONCLUSIONS

Nowadays brown tumor is an extremely rare manifestation of primary HPT. A delay in diagnosis and in curative parathyroidectomy can result in unnecessary complications such as progressive blindness [13]. Once hyperparathyroidism is controlled, the tumor tends to regress, although in some cases such as ours surgical removal is necessary, especially for patients who have large symptomatic tumors. Our patient required surgical removal. Brown tumor can recur if hyperparathyroidism persists or recurs [6,11].

## REFERENCES:

1. Monteiro ML: Multiple brown tumors of the orbital walls: case report. *Arq Bras Oftalmol*, 2009; 72(1): 116–18
2. Fernández-Sanromán J, Antón-Badiola IM, Costas-López A: Brown tumor of the mandible as first manifestation of primary hyperparathyroidism: diagnosis and treatment. *Med Oral Patol Oral Cir Bucal*, 2005; 10(2): 169–72

3. Magalhães DP, Osterne RL, Alves AP et al: Multiple brown tumours of tertiary hyperparathyroidism in a renal transplant recipient: a case report. *Med Oral Patol Oral Cir Bucal*, 2009; 15(1): e10–13
4. Zwick OM, Vagefi MR, Cockerham KP, McDermott MW: Brown tumor of secondary hyperparathyroidism involving the superior orbit and frontal calvarium. *Ophthalm Plast Reconstr Surg*, 2006; 22(4): 304–6
5. Slem C, Varinli S, Köker F: Brown tumor of the orbit. *Ann Ophthalmol*, 1983; 15(9): 811–12
6. Lessa MM, Sakae FA, Tsuji RK et al: Brown tumor of the facial bones: case report and literature review. *Ear Nose Throat J*, 2005; 84(7): 432–34
7. Naiman J, Green WR, d'Heurle D et al: Brown tumor of the orbit associated with primary hyperparathyroidism. *Am J Ophthalmol*, 1980; 90(4): 565–71
8. Takeshita T, Tanaka H, Harasawa A et al: Brown Tumor of the Sphenoid Sinus in a Patient with Secondary Hyperparathyroidism: CT and MR Imaging Findings. *Radiation Medicine*, 2004; 22(4): 265–68
9. Cecchetti DFA, Paula SA, Cruz AAV et al: Orbital Involvement in Craniofacial Brown Tumors. *Ophthalm Plast Reconstr Surg*, 2010; 26: 106–11
10. Chew FS, Huang-Hellinger F: Brown Tumor. *Radiologic-Pathologic Conferences of the Massachusetts General Hospital. AJR*, 1993; 160: 752
11. Fernández Sanromán J, Antón Badiola IM, Costas López A: Brown tumor of the mandible as first manifestation of primary hyperparathyroidism: diagnosis and treatment. *Med Oral Patol Oral Cir Bucal*, 2005; 10: 169–72
12. Proimos E, Chimona TS, Tamiolakis D et al: Brown tumor of the maxillary sinus in a patient with primary hyperparathyroidism: a case report. *Journal of Medical Case Reports*, 2009; 3: 74–95
13. Schweitzer VG, Thompson NW, McClatchey KD: Sphenoid sinus brown tumor, hypercalcemia, and blindness: An unusual presentation of primary hyperparathyroidism. *Head & Neck Surgery*, 2006; 8(5): 379–86
14. Haluk Emin A, Süolu Y, Demir D, Can Karatay M: Normocalcemic hyperparathyroidism presented with mandibular brown tumor: report of a case. *Auris Nasus Larynx*, 2004; 31(3): 299–304
15. Parrish CM, O'Day DM: Brown tumor of the orbit. Case report and review of the literature. *Arch Ophthalmol*, 1986; 104(8): 1199–202
16. De Pablos PL, Ramos I, De La Galle H: Brown tumor of the plate associated with primary HPT. *J Oral Maxillofacial Surg*, 1987; 45: 719–20
17. Levine MR, Chu A, Abdul-Karim FW: Brown tumor and secondary Hyperparathyroidism. *Arch Ophthalmol*, 1991; 109: 847–49
18. Mcwhorter AG, Layton S: Giant cell lesion associated with secondary hyperparathyroidism: case report. *Pediatr Dent*, 1989; 11: 55–58
19. Weiss RR, Schoeneman MJ, Primack W et al: Maxillary brown tumor of secondary hyperparathyroidism in a hemodialysis patient. *JAMA*, 1980; 243: 1929–30
20. Hamdi Sahan M, Guner S, Ilkay Guner S: Radiological findings in the primary hyperparathyroid case with multiple brown tumors: a case report. *Eastern Journal of Medicine*, 2008; 13: 30–34
21. Yilmazlar S, Arslan E, Aksoy K, Tolunay S: Sellar-Parasellar Brown Tumor: Case Report and Review of Literature. *Skull Base*, 2004; 14(3): 163–68
22. Imad K, Mohamed A, Ayman R, Jihad A: Sphenid sinus Brown Tumor of Secondary Hyperparathyroidism: case report. *Neurosurgery*. 1998; 42(6): 1374–77
23. Hozler NJ et al: Brown tumor of the orbit. *JAMA*, 1977; 238: 1758–59
24. Spasovski G, Masin-Spasovska J, Gjurchinov D: Successful treatment of severe secondary hyperparathyroidism (Brown tumor) by kidney transplantation and pulses of oral calcitriol. *Clin Transplant*, 2009; 23: 426–30
25. Scott SN, Graham SM, Sato Y, Robinson RA: Brown tumor of the palate in a patient with primary hyperparathyroidism. *Ann Otol Rhinol Laryngol*, 1999; 108: 91–94
26. Martínez-Gavidia EM, Bagan JV, Millan-Masaret MA et al: Highly aggressive brown tumor of maxilla as first manifestation of primary hyperparathyroidism. *Int J Oral Maxillofacial Surg*, 1996; 45: 465–70
27. Yamazaki H, Ota Y, Aoki T, Karakida K: Brown tumor of the maxilla and mandible: Progressive mandibular brown tumor after removal of parathyroid adenoma. *J Oral Maxillofacial Surg*, 2003; 6: 719–22