



Case series

Oral rehabilitation of maxillofacial trauma using fixed corticobasal implant-supported prostheses: A case series

Fadia Awadalkreem^{a,*}, Nadia Khalifa^b, Abdelnasser G. Ahmad^c, Ahmed Mohamed Suliman^d, Motaz Osman^e

^a RAK College of Dental Sciences, RAK Medical and Health Sciences University, Ras Al Khaimah, United Arab Emirates

^b Department of Preventive and Restorative Dentistry, University of Sharjah/Faculty of Dental Medicine, Sharjah, United Arab Emirates

^c International University of Africa, Oral and Maxillofacial Surgery Department, Khartoum, Sudan

^d Department of Oral and Maxillofacial Surgery, Faculty of Dentistry, University of Khartoum, Khartoum, Sudan

^e Implant Department, Khartoum Teaching Dental Hospital, Federal Ministry of Health, Khartoum, Sudan

ARTICLE INFO

Keywords:

Maxillofacial trauma
Dental implants
Corticobasal implants
Road traffic accidents

ABSTRACT

Introduction: Maxillofacial trauma is associated with severe loss of soft and hard tissues that lead to aesthetic and functional disfigurements, adverse psychological impacts on the patient's general and oral health, and decreased quality of life. Therefore, treatment of maxillofacial trauma is challenging.

Presentation of case: We present three patients with maxillofacial trauma owing to road traffic accidents that were rehabilitated by immediate use of loaded fixed corticobasal implant-supported prostheses with follow-up periods of 6, 5, and 7 years. All treated patients had a 100 % implant survival rate, healthy peri-implant tissues, stable prosthesis with significant improvement in mastication and phonation, and high patient satisfaction.

Discussion: Rehabilitation of patients with intensive maxillofacial trauma requires a multidisciplinary approach to ensure the standard of care during treatment. The described treatment eliminates the need for bone grafting, reduces susceptibility to grafting complications, shortens treatment time, and provides the patient with a fixed prosthesis with predictable success, excellent implant survival, healthy peri-implant tissue, improved prosthetic stability, and high satisfaction rates.

Conclusion: Corticobasal implant-supported prostheses are a feasible treatment modality to rehabilitate patients with maxillofacial trauma with high success and survival rates and patient satisfaction.

1. Introduction¹

Maxillofacial trauma may result in severe loss of soft and hard tissues leading to aesthetic and functional disturbance, adverse psychological effects, and reduced quality of life [1]. Maxillofacial trauma treatment necessitates an interdisciplinary approach [2].

Extensive tissue loss complicates case management and compromises the retention, support, and stability of prospective prostheses [3].

Treatment selection depends on patient age, sex, trauma site and etiology, synchronized tissue loss, and associated bone fractures [2,4,5]. Dental implant use improves patient outcomes [1–5].

However, the loss or fracture of the supported alveolar bone may preclude conventional implant use without bone grafting [3,4,6]. The patient age and medical condition, and care-provider's inexperience may

intensify procedure complexity [6–9].

Corticobasal implant use is associated with high success rates without requiring bone grafts [8–12]. Implants are anchored to the basal bone and connected through a metal framework [8–12]. Although corticobasal implants can be used successfully in cases of compromised bone support, the associated long-term outcomes in maxillofacial trauma remain unclear.

To our knowledge, this is the first case series to describe successful rehabilitation of three patients using corticobasal implant-supported fixed prostheses with follow-up of 6, 5, and 7 years.

This prospective study was conducted according to the Preferred Reporting of Case Series in Surgery 2020 criteria [13]. Ethical approval for the study and informed consents were obtained for treatment and publication.

* Corresponding author.

E-mail address: fadia.alfateh@rakmhsu.ac.ae (F. Awadalkreem).

¹ RTA, road traffic accidents.

2. Presentation of cases

Three men (21–31 years old) were referred to the last author's prosthodontic department, following dentoalveolar trauma from a road traffic accident (RTA) (2014–2021), without any relevant medical or family history.

A team of maxillofacial surgeon and prosthodontists was formed, and all prosthetic options were discussed with the patients. The approved treatment plan involved corticobasal implant insertion (BCS®, Dr. Ihde Dental AG, Switzerland) to support an immediately loaded fixed implant-supported reconstructive prosthesis. An expert maxillofacial

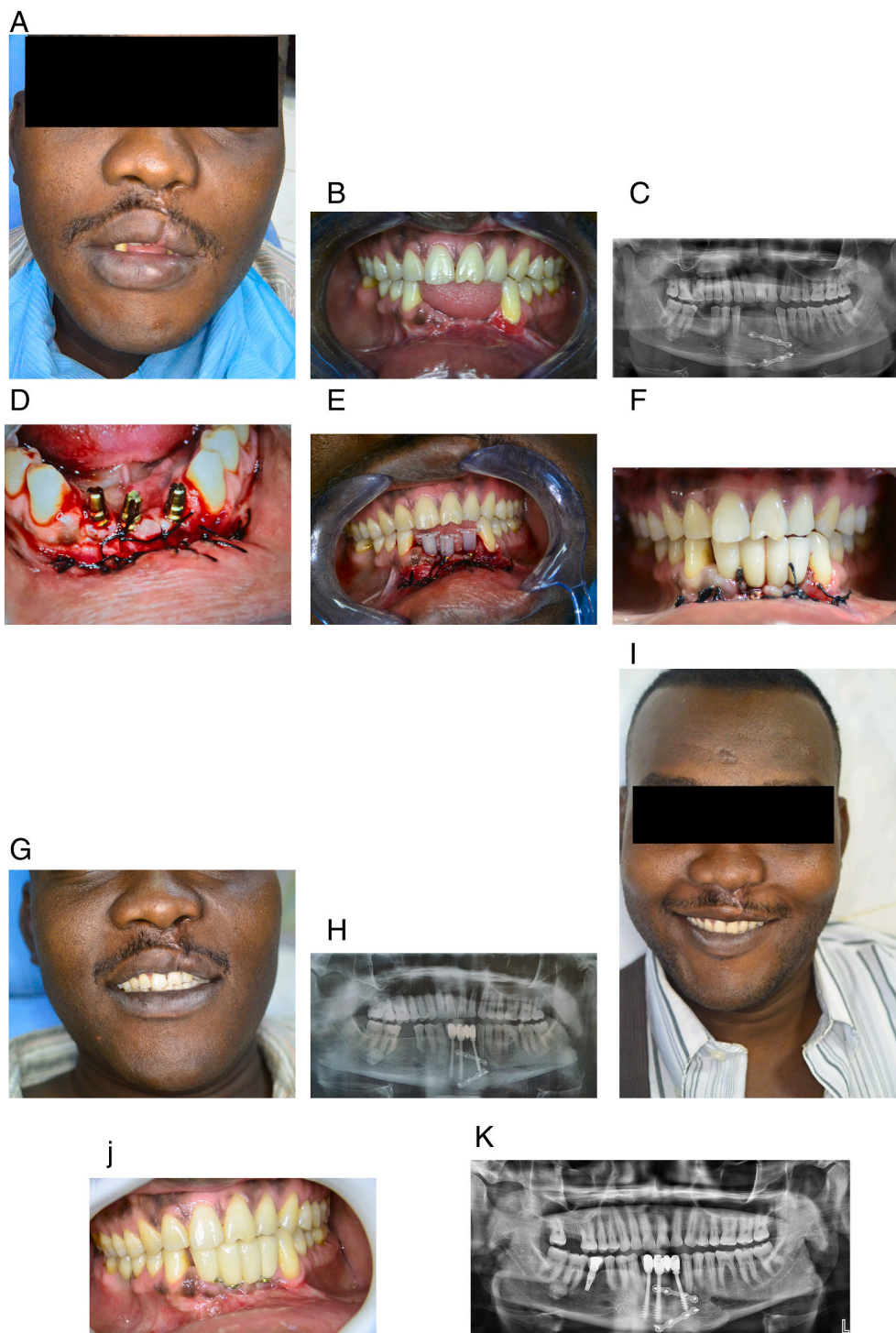
surgeon with vast experience in corticobasal implants performed all implant insertions; the prostheses were placed using a standard technique by the same prosthodontists.

2.1. Case 1

A 31-year-old man presented with a symmetrical face, right upper lip swelling, and a fibrotic scar splitting the lip and left nasolabial area (Fig. 1A). Intraoral clinical examination revealed missing teeth (42, 41, 31, and 32), while tooth number 33 showed localized periodontal inflammation associated with gingival recession and grade II mobility.

Fig. 1. The patient's code 01 presentation.

A. Patient's photograph presents his frontal view at the time of presentation, showing an asymmetrical face, swollen right upper lip, and a fibrotic scar splitting the lip and left nasolabial area. B. Intraoral view showing a comprehensive horizontal and vertical bone loss, missing teeth numbers 42, 41, 31, and 32; note the localized periodontal inflammation associated with gingival recession at tooth 33 and an obliterated labial sulcus. C. Panoramic radiograph shows the presence of two reconstructive plates at the midline, fixating a symphysis fracture. D. Intraoral view presenting implant distribution and vestibuloplasty. E. Panoramic view showing implant distribution. F. Intraoral view showing impression copings. G. Final fixed, immediately loaded, corticobasal implant-supported prosthesis. H. Patient's frontal view after prosthesis insertion. I. Patient's frontal view after 6 years. J. Intraoral view of the patient showing the prosthesis after 6 years of function. K. Panoramic radiograph at 6 years showing an acceptable peri-implant bone contact around the corticobasal implants; note the two-stage implant replacing 46.



The edentulous space showed comprehensive bone loss with an obliterated vestibule (Fig. 1B). A radiographic evaluation using the digital panoramic view (ProMax, Planmeca, Finland) showed the presence of two reconstructive plates at the midline, fixating a symphysis fracture (Fig. 1C). A treatment plan involving a corticobasal implant-supported reconstructive prosthesis and follow-up program was formulated.

Implant surgery was performed under aseptic conditions. Local anesthesia was induced (2 % lidocaine with epinephrine 1:100000). Implant osteotomy was performed, and three BCS® implants of appropriate lengths and diameters were inserted. Vestibuloplasty was performed (Fig. 1D, E), and antibiotics and analgesics were prescribed, including amoxicillin (1 g), metronidazole (500 mg), and diclofenac potassium (50 mg, Rapidus). The impression copings were attached over the abutment, and the final impression was obtained using a monophasic VPS (Ivoclar Vivadent AG, Schaan, Liechtenstein) (Fig. 1F).

The next day, the metal framework was evaluated, and passive fitness was ensured. After 24 h, a fixed prosthesis was delivered, and the aesthetic and functional parameters were satisfactory (Fig. 1G-I).

The patient was provided oral hygiene instructions and scheduled for

follow-up at 1, 3, 6, and 12 weeks, and every 6 months thereafter (Fig. 1I-K). Six months later, tooth number 46 was replaced using delayed loading, two-stage, fixed implant-supported prosthesis following the standard technique (Fig. 1L).

During follow-up, the patient presented with healthy peri-implant soft tissue without evidence of complications. After 6 years, the patient showed improved aesthetics, masticatory function, and quality of life, and was satisfied with the outcome.

2.2. Case 2

A 28-year-old man was referred for prosthetic rehabilitation following dental trauma. The patient had a history of RTA 7 months prior, resulting in mandibular fracture, surgery, and avulsed teeth numbers 11, 12, 13, 41, 42, and 43. The fracture was severely displaced, both vertically and horizontally. Despite fracture fixation using a reconstructive plate, post-operative occlusion was defective.

Extraoral examination revealed facial asymmetry associated with incompetent lips and a scar on the right upper lip (Fig. 2A). Intraoral

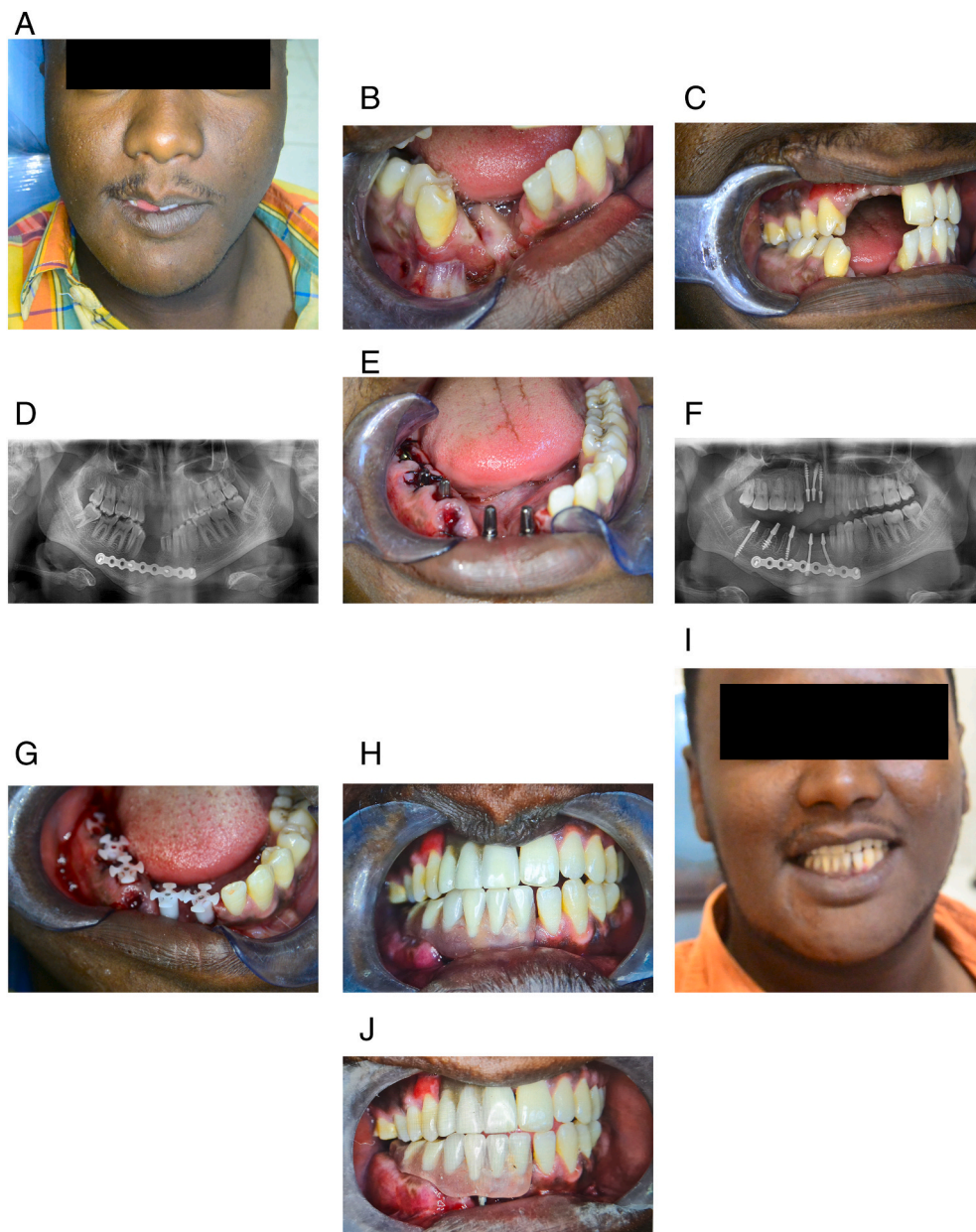


Fig. 2. The patient's code 02 presentation. A. Patient's photograph presents his frontal view at the time of presentation showing facial asymmetry associated with incompetent lips and scar on the right side of the upper lip. B. Intraoral view showing missing teeth numbers 11, 12, 13, 41, 42, and 43. C. Intraoral view showing localized redness of the mucosa at the region of 14, 13, 12, and 11, a scattered generalized brown hyperpigmentation, and posterior defective occlusion, and teeth numbers 45, 46, 47, and 48 that are severely lingually inclined. D. Panoramic radiograph revealing a symphysis fracture splinted by a reconstructive plate. E. Intraoral view presenting implant distribution and extracted sockets. F. Panoramic view showing implant distribution. G. Intraoral view showing impression copings. H. Final, fixed, immediately loaded corticobasal implant-supported prosthesis. I. Patient's frontal view after prosthesis insertion. J. Patient's intraoral view after 5 years.

examination showed missing teeth (11, 12, 13, 31, 41, 42, and 43). Teeth numbers 46 and 47 were carious (Fig. 2B). Localized redness of the mucosa at the region of teeth numbers 14, 13, 12, and 11 and scattered generalized brown hyperpigmentation were observed (Fig. 2C). Teeth numbers 31, 44, and 45 showed mobility grades III, III, and II, respectively. Occlusion of the patient was deflective and, the posterior teeth were severely lingually inclined (Fig. 2C). The mandibular edentulous spaces showed bone defects. Panoramic radiograph revealed a fixated symphysis fracture (Fig. 2D). The patient was severely depressed. All treatment options were extensively discussed with the patient using mounted study casts; the patient refused any comprehensive management to treat the carious teeth and establish the correct occlusion (i.e., root canal treatment, crowns, and teeth alignment). Thus, a treatment plan was formulated involving mobile and carious teeth extraction and the construction of a fixed corticobasal implant-supported prosthesis.

Following the administration of local anesthetic, teeth numbers 48, 47, 46, 45, 44, and 31 were extracted. Five BCS® implants were immediately placed. Sutures were placed to reduce the socket size and promote healing. Moreover, three implants were inserted at 11, 12, and 13 regions. A post-operative panoramic view was captured (Fig. 2E-F). Impression was obtained and antibiotic, analgesic, and mouthwash were prescribed.

One day later, the metal framework was tried. The final prosthesis was inserted on the third day (Fig. 2H-I). The patient was scheduled for follow-up after 2 weeks to examine complete soft tissue healing.

After two weeks, the soft tissue showed complete healing, and occlusal adjustment was performed. The patient was highly satisfied with the treatment results and scheduled for follow-up.

After 5 years of follow-up, the patient presented with a stable prosthesis and healthy peri-implant tissues, without any complaints, and was highly satisfied (Fig. 2J).

2.3. Case 3

A 22-year-old man presented with a history of an RTA resulting in maxillary and mandibular anterior teeth loss (Fig. 3A). The clinical and radiographical examinations revealed missing teeth with extensive vertical and horizontal bone losses. Scattered patches of brown hyperpigmentation were observed on the mucosa (Fig. 3B). Radiographic examination showed missing teeth numbers 11, 12, 13, 21, 22, 23, 41, 42 and 43 (Fig. 3C). The treatment plan involved a maxillary and mandibular corticobasal implant reconstructive prostheses.

Following the surgical protocol described in cases 1 and 2, implant osteotomy was accomplished with the insertion of 7 BSC® implants (Fig. 3D, E). Antibiotics and analgesics were prescribed.

Following the same prosthetic technique, a fixed prosthesis was inserted on the third day and occlusion was adjusted (Fig. 3F, G, H, I, J and K). The patient reported satisfaction with the treatment results and was scheduled for follow-up. After 7 years, the clinical and radiographic evaluation showed optimum implant health without prosthetic complaints; the patient was satisfied with the outcome (Fig. 3L).

3. Discussion

The rehabilitation of patients with maxillofacial trauma is challenging and necessitates collaboration among medical and dental specialists [2].

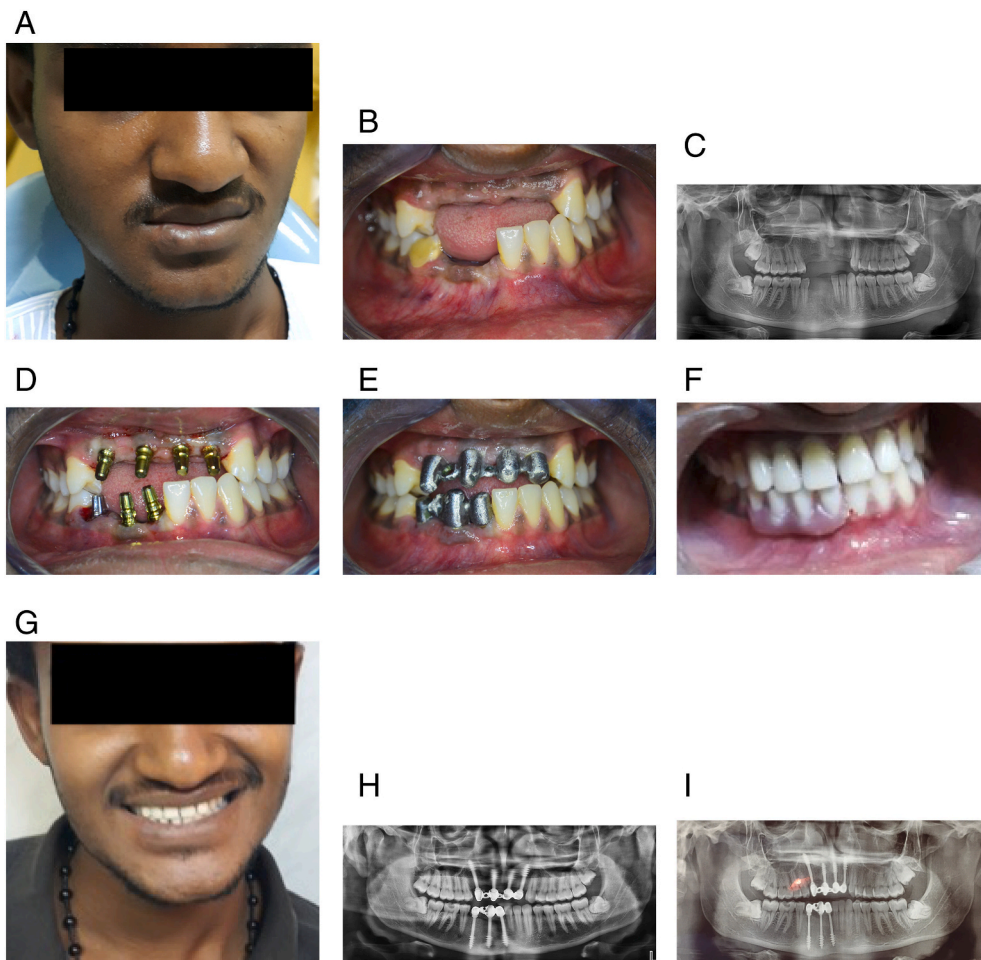


Fig. 3. The patient's code 03 presentation. A. Patient's photograph presents his frontal view at the time of presentation. B. Intraoral view showing missing teeth number 13, 12, 11, 21, 22, 41, 42, and 43, and compromised bone support. Tooth 43 presents with a fractured crown. C. Panoramic view showing missing teeth numbers 11, 12, 13, 21, 22, 23, 41, 42 43. D. Intraoral view showing implant distribution. E. Panoramic view showing implant distribution. F. Extraoral view showing the metal frameworks on the casts. G. Intraoral view showing the metal frameworks on the patient's mouth. H. Final, fixed, immediately loaded corticobasal implant-supported prosthesis on the casts. I. Final, fixed, immediately loaded corticobasal implant-supported prosthesis inserted inside the patient's mouth. J. Patient's frontal view after prosthesis insertion. K. The intraoral view of the patient depicting his clinical presentation exhibiting optimal peri-implant oral health. L. A panoramic radiograph showing the prostheses after 5 years of function.

In the reported cases, the selected treatment eliminated the need for bone grafting, and reduced procedure complexity, time required, and post-operative complications risk [8–11].

Moreover, it provided patients with immediate loading treatment to ensure fast prosthetic treatment. A review conducted by Esposito et al. [14] reported no differences in prosthesis and implant failure or bone loss rates among different loading protocols.

Our findings are consistent with those of cases studies involving severe tissue loss [8,10,11]. Moreover, Lukasz and Lazarov [10] reported a survival rate of 99 % in patients with and without periodontitis with bicortical smooth surface implants.

Furthermore, Awadalkreem et al. [15] described the successful prosthetic rehabilitation of a man using a mandibular reconstructive prosthesis after a gunshot injury. After 7 years, the patient presented with excellent peri-implant soft tissue health and reported improvement in aesthetics, function (mastication and speech), and quality of life.

The peri-implant health reported in these cases is attributed to the BCS® implant design, which is characterized by a smooth surface and matches the results of other investigators who considered that a rough implant surface may form a platform for microbial adhesion and accumulation [15–18]. This microbial biofilm may increase the risk of inflammation around the implant, resulting in peri-implant mucositis or peri-implantitis in some cases [15–18].

Patient age has a key role in prosthetic selection [2,3]; young patients request fixed treatment modalities. Hence, the selected treatment modality matched the patients' desires which greatly improved their self-esteem and explains the high level of satisfaction. This result is in line with that of Lazarov [19] and Awadalkreem et al. [20], who reported high patient satisfaction and significant improvement in patient comfort, masticatory function, phonetics, and aesthetics following corticobasal implant treatment.

The use of a metal framework and implant splinting greatly improved the biomechanical force distribution thereby increasing the implant success rate, consistent with findings of previous studies [8,9,21,22]. Meanwhile, hybrid prosthesis use has an aesthetic advantage as it compensates for the severe tissue loss associated with maxillofacial trauma and provides the support needed for the collapsed tissues and limited bone availability [8,9,21,22].

The strength of our case series is that we documented a prompt treatment modality with good outcomes and high patient satisfaction. Further studies with larger sample sizes are recommended.

4. Conclusion

Corticobasal implant-supported prostheses are a feasible treatment modality for the rehabilitation of patients with maxillofacial trauma, with a reportedly high success rate and satisfaction level.

Ethical approval

The research was registered at the research centre of the Khartoum Dental Teaching Hospital, Federal Ministry of Health, Khartoum, Sudan, after the approval of the research ethical committee of Khartoum Dental Teaching Hospital.

Sources of funding

This research did not receive any specific grant from funding agencies in the public, commercial, or not-for-profit sectors.

CRediT authorship contribution statement

Awadalkreem F contributed to the conceptualization, treating the patient, writing, editing, finalization and submission of the case.

Khalifa N contributed to the conceptualization, validation, and supervision of the case.

Ahmad A contributed to the conceptualization, validation, treating the patient, and supervision of the case.

Suliman AM was contributed to the conceptualization validation, and supervision of the case.

Osman M contributed to the conceptualization, treating the patient, editing, and finalization of the manuscript.

Registration of research studies

The research approved by the research ethical committee of Khartoum Dental Teaching Hospital, Federal Ministry of Health, Khartoum, Sudan.

The research was registered at the Research Registry with the unique identifying number: research registry 8286.

Provenance and peer review

Not commissioned, externally peer-reviewed.

Informed consent statement

The patients have provided written informed consent for publication of the case.

Declaration of competing interest

The authors declare no conflicts of interest in connection with this research and manuscript.

References

- [1] J. Chesterman, R. Chauhan, M. Patel, M.F. Chan, The management of traumatic tooth loss with dental implants: part 1, *Br. Dent. J.* 217 (11) (2014 Dec 5) 627–633, <https://doi.org/10.1038/sj.bdj.2014.1050>.
- [2] S. Yamano, M. Nissenbaum, T.B. Dodson, G.O. Gallucci, C. Sukotjo, Multidisciplinary treatment for a young patient with severe maxillofacial trauma from a snowmobile accident: a case report, *J. Oral. Implantol.* 36 (2) (2010) 141–144.
- [3] E. Brauner, G. Pompa, A. Quarato, S. Jamshir, F. De Angelis, S. Di Carlo, V. Valentini, Maxillofacial prosthesis in dentofacial traumas: a retrospective clinical study and introduction of new classification method, *Biomed. Res. Int.* 2017 (2017) 8136878, <https://doi.org/10.1155/2017/8136878>.
- [4] F.G. Robinson, L.L. Cunningham, Oral rehabilitation of severe dentoalveolar trauma: a clinical report, *J. Oral. Implantol.* 38 (6) (2012 Dec) 757–761, <https://doi.org/10.1563/AAID-JOI-D-10-00121>.
- [5] K. Subhashraj, N. Nandakumar, C. Ravindran, Review of maxillofacial injuries in Chennai, India: a study of 2748 cases, *Br. J. Oral Maxillofac. Surg.* 45 (8) (2007 Dec) 637–639, <https://doi.org/10.1016/j.bjoms.2007.03.012>.
- [6] A.M. Kökat, A.R. Erçöçen, B. Karayazgan-Saraçoğlu, Simultaneous implant placement in a mandibular defect reconstructed with a free fibula graft and fabrication of a fixed metal porcelain prosthesis, *J. Craniofac. Surg.* 29 (5) (2018 Jul) 1307–1311, <https://doi.org/10.1097/SCS.00000000000004526>.
- [7] R. Bocklage, Advanced alveolar crest atrophy: an alternative treatment technique for maxilla and mandible, *Implant. Dent.* 10 (2001) 30–35.
- [8] F. Awadalkreem, N. Khalifa, A. Satti, A.M. Suliman, Rehabilitation of marginal mandibulectomy patients using immediately loaded basal implant-supported prostheses, *J. Oral Maxillofac. Surg., Medicine, and Pathology* 34 (2022) 24–35.
- [9] S. Ihde, A. Ihde, Immediate Loading Guideline to Successful Implantology, 2nd ed., The International Implant Foundation Publishing, Munich, 2010.
- [10] R. Lukaz, L.R. Paika, A. Lazarov, Immediately loaded bicortical implants inserted in fresh extraction and healed sites in patients with and without a history of periodontal disease, *Ann Maxillofac Surg* 9 (2019) 371–378.
- [11] A. Lazarov, Immediate functional loading: results for the concept of the strategic implant®, *Ann Maxillofac Surg* 9 (2019) 78–88.
- [12] I. Antonina, A. Lazarov, V. Gaur, V. Lysenko, V. Konstantinovic, G. Grombkötö, et al., Consensus regarding 16 recognized and clinically proven methods and sub-methods for placing corticobasal® oral implants, *Ann Maxillofac Surg* 10 (2020) 457–462.
- [13] C.Sohrabi R.A. Agha G. Mathew, Guideline: updating consensus preferred reporting of CasE series in surgery (PROCESS) guidelines, *Int. J. Surg.* 84 (2020) 231–235.
- [14] M. Esposito, M.G. Grusovin, H. Maghahre, H.V. Worthington, Interventions for replacing missing teeth: different times for loading dental implants, *Cochrane Database Syst. Rev.* 28 (3) (2013), <https://doi.org/10.1002/14651858.CD003878>.
- [15] F. Awadalkreem, N. Khalifa, A.G. Ahmad, A.M. Suliman, M. Osman, Prosthetic rehabilitation of maxillary and mandibular gunshot defects with fixed basal

- implant-supported prostheses: a 5-year follow-up case report, *Int. J. Surg. Case Rep.* 68 (2020) 27–31, <https://doi.org/10.1016/j.ijscr.2020.02.025>.
- [16] V.A.R. Barão, R.C. Costa, J.A. Shibli, M. Bertolini, J.G.S. Souza, Emerging titanium surface modifications: the war against polymicrobial infections on dental implants, *Braz. Dent. J.* 33 (1) (2022) 1–12, <https://doi.org/10.1590/0103-6440202204860>.
- [17] A. Rehman, J. Hu, S.J. Ott, B. Grössner-Schreiber, Microbial community composition on modified dental implant surfaces: an in vivo study, *Int. J. Oral Maxillofac. Implants* 27 (4) (2012) 811–819. PMID: 22848882.
- [18] W. Teughels, N. Van Assche, I. Sliepen, M. Quirynen, Effect of material characteristics and/or surface topography on biofilm development, *Clin. Oral Implants Res.* 17 (Suppl. 2) (2006) 68–81, <https://doi.org/10.1111/j.1600-0501.2006.01353.x>.
- [19] A.B. Lazarov, The impact of diabetes, smoking, and periodontitis on patients' oral health related quality of life after treatment with corticobasal implants - an evaluative study, *Ann Maxillofac Surg* 11 (2021) 253–260.
- [20] F. Awadalkreem, N. Khalifa, A. Satti, A.M. Suleiman, The influence of immediately loaded basal implant treatment on patient satisfaction, *Int. J. Dent.* 14 (2020) (2020 Apr) 6590202.
- [21] D.L. Guichet, D. Yoshinobu, A.A. Caputo, Effect of splinting and interproximal contact tightness on load transfer by implant restorations, *J. Prosthet. Dent.* 87 (2002) 528–535.
- [22] C.E. Misch, H.L. Wang, C.M. Misch, M. Sharawy, J. Lemons, K.W. Judy, Rationale for the application of immediate load in implant dentistry: part II, *Implant. Dent.* 13 (2004) 310–321.