

Received: 2012.03.05
Accepted: 2012.05.10
Published: 2012.09.01

Atovaquone ameliorate gastrointestinal Toxoplasmosis complications in a pregnancy model

Authors' Contribution:

- A** Study Design
- B** Data Collection
- C** Statistical Analysis
- D** Data Interpretation
- E** Manuscript Preparation
- F** Literature Search
- G** Funds Collection

Helieh S. Oz^{1ABCDEF}, Thomas Tobin^{2G}

¹ Department of Physiology, College of Medicine, Department of Internal Medicine, University of Kentucky Medical Center, Lexington, KY, U.S.A.

² Department of Veterinary Science, The Maxwell H. Gluck Equine Research Center and The Graduate Center for Toxicology, University of Kentucky, Lexington, KY, U.S.A.

Source of support: The study was supported by the grants Kentucky Science and Technology (KSTC) and the National Institutes of Health DE019177

This Research was partially presented at the DDW 2011

Summary

Background:

Toxoplasma is an important source of foodborne hospitalization with no safe and effective therapy against chronic or congenital Toxoplasmosis. Atovaquone is a drug of choice but not approved for use in congenital Toxoplasmosis. We hypothesized atovaquone to be safe and effective against fetomaternal Toxoplasmosis.

Material/Methods:

Programmed pregnant mice were *i.p.* infected with 50–2400 Tachyzoites from Type II strain (clone PTG). Dams were treated daily with atovaquone or sham and monitored for pain, and complications.

Results:

Dams developed pain related abdominal hypersensitivity (allodynia) to mechanical stimuli in a Tachyzoites dose dependent manner. Infected dams were anemic and exhibited ascities and severe hepatitis (score 3.6 ± 0.01 on scale 0 – normal to 4 – severe) with influx of inflammatory and plasma cells, multinucleated dysplastic hepatocytes and necrosis. In addition, dams expressed mild to severe pancreatitis with mononuclear cell invasion, loss of islets and necrosis. This was consistent with splenomegaly (X3 Fold), and massive infiltration of epithelioid cells and loss of germinal structure. Colon became significantly shortened in length ($p < 0.01$) with semi-normal content. Pathological manifestation included, shortening of crypts with numerous microabscess formations, infiltration of lymphocytes, and macrophages. The severe clinical complications led to abortion (50%), early birth (25%) or still birth (25%) consistent with the high dose of Tachyzoites inoculation. Atovaquone treatment partially but significantly protected the dams from the severity of hepatitis, splenomegaly, colitis, myocarditis, and pain related responses as well as fetal demise.

Conclusions:

This is a valuable model for therapeutic evaluation of fetomaternal Toxoplasmosis and gastrointestinal complications. Atovaquone protects dams and their fetuses against some infectious/inflammatory aspects of the disease.

Key words:

feto-maternal Toxoplasmosis • gastrointestinal • pregnancy • hepatitis • atovaquone

Full-text PDF:

<http://www.medscimonit.com/fulltxt.php?ICID=883342>

Word count:

4045

Tables:

1

Figures:

7

References:

41

Author's address:

Helieh S. Oz, Department of Physiology, and Internal Medicine, MS635 University of Kentucky Medical Center, 800 Rose Street, Lexington, KY 40536, U.S.A., e-mail: hoz2@email.uky.edu

BACKGROUND

Toxoplasma gondii, an obligate intracellular protozoan, is an important source of foodborne hospitalization. *Toxoplasma* infects humans and animals, specifically in impoverished and disadvantage populations. Toxoplasmosis in immunocompetent individuals is usually asymptomatic or manifested as flu like syndrome, but outcomes can include severe impediment in immunocompromised hosts as well as fetuses leading to demise and death [1]. It is estimated that 1,500,000 cases of Toxoplasmosis occurs in the U.S.A each year, and about 15% of these cases show clinical symptoms [2]. Toxoplasmosis reactivation occurs primarily during pregnancy and in AIDS and in immunocompromised individuals when cysts rupture. Congenital Toxoplasmosis in humans as well as animals (*e.g.* sheep and goats) is initiated by the transplacental transmission of organisms during maternal infection [3]. The congenital transmission of Toxoplasmosis was first reported in a 3 day old infant from New York in 1939 [4], and the importance of maternal fetal transmission has long been recognized [5]. Congenital Toxoplasmosis leads to spontaneous abortion, intrauterine fetal death or severe congenital defects, such as encephalitis, hydrocephaly and chorioretinitis [6]. *Toxoplasma* invades the central nervous system (CNS) with adverse affect in brain neuro-structural development and pathological as well as psycho-behavioral alteration leading to mental retardation [7–9]. More recently, maternal exposure to *Toxoplasma* organisms has been linked to a potential increased risk for schizophrenic episodes and this hypothesis has received a significant media attention.

Current therapy against Toxoplasmosis includes atovaquone (hydroxy-1,4-naphthoquinone) which is an FDA approved treatment but not in use for congenital Toxoplasmosis [10]. Atovaquone has been proven to be effective against opportunistic diseases such as *Pneumocystis carinii* pneumonia [11], malarial infections [12], and *Babesia microti* causative of human babesiosis [13,14]. So far, there is no safe and effective therapy (FDA approved) against congenital Toxoplasmosis or any drug capable of eliminating the persistent, chronic *Toxoplasma* infection. Spiramycin alone or associated with pyrimethamine-sulfadoxine are used to prevent transfer of *Toxoplasma* from the actively infected mother to the fetus. However, this approach is not always effective and associated with unwanted side effects [15–18].

The congenital Toxoplasmosis models are induced by the oral inoculation of *Toxoplasma* cysts or Tachyzoites from infected animals [19] or intraperitoneal injection of cysts from ME49 strain [20]. Consequently, a simple and reliable model for Toxoplasmosis induced fetomaternal complications is highly desirable to study the progression of disease and to investigate the therapeutic modalities in the model.

The objectives of this study were to: a) to develop a fetal maternal model to present moderate to severe gastrointestinal Toxoplasmosis complications during the pregnancy for the use in drug evaluation and b) to study efficacy of atovaquone against *Toxoplasma* infection in the model.

Therefore, it was hypothesized that atovaquone to be safe and effective against fetomaternal complications as consequences of Toxoplasmosis in a murine pregnancy model.

MATERIAL AND METHODS

Toxoplasma gondii propagation

Type II isolates of *Toxoplasma* including ME-49 strain is predominantly discovered in human congenital Toxoplasmosis [21]. For this study, *Toxoplasma* Tachyzoites from PTG strain (ME-49, ATCC50841TM) were originally cloned and propagated [22] and kindly provided by Dr. Daniel Howe, PhD, Maxwell H Gluck Equine Research Center, College of Agriculture, University of Kentucky. Briefly, Tachyzoites were cultured by serial passage in bovine turbinate cells and maintained in minimum essential medium (MEM-RS, HyClone Labs, Inc.) supplemented with 4% fetal clone III (HyClone, Labs, Inc.), Penicillin/Streptomycin/Fungizone (BioWhittaker, Inc.), and non-essential amino acids solution (HyClone, Labs, Inc.). Upon disruption of the host cell monolayer, extracellular Tachyzoites were harvested and purified from host cell debris by filtration through 3.0 µm membranes. Tachyzoites were enumerated in a hemocytometer and suspended in phosphate buffer saline (PBS) to the appropriate concentrations for inoculation. To ensure Tachyzoites viability, inoculums were given intraperitoneally (*i.p.*) in 100 µl volume and within 1 h of harvest.

Murine model

This investigation was conducted according to the guidelines and approved by the Institutional Biosafety Committee (IBC) and Institutional Animal Care and use committee (IACUC) at University of Kentucky Medical Center which is certified by the American Association of Accreditation of Laboratory Animal Care (AAALAC).

On day 1 of programmed pregnancy, 9 weeks old CD1 mice were purchased from Charles River Lab Inc. (Wilmington, MA) and housed individually in micro-isolator cages in a pathogen free environment. The room was maintained at 22°C with a 12:12-hr light:dark cycle at the Maxwell H. Gluck Equine Research Center Laboratory Animal Facility at the University of Kentucky. Dams were fed irradiated rodent chow and sterilized drinking water *ad libitum*. After 5 days acclimation, dams were weighed and ear-punched for appropriate identification.

To establish the model, dams were assigned into 6 animals per each group, and injected with 100 µl of Tachyzoites from 0–50–100 and then 300–600–1200–2400 organisms (at proportion of about 2 fold increments) given *i.p.* using 0.5 ml insulin syringes. Control dams (group 7) received 100 µl sham vehicle injection with sterile PBS. Animals were monitored daily 3 times for physical appearance, distress, pain, and vaginal discharge to detect abortion, early delivery, or gastrointestinal complications [23]. The experiment was terminated on gestation day 16 before the possible early or premature birth to study the fetomaternal complications. For further drug evaluation we chose a cutoff dose of 600 Tachyzoites inoculations where animals developed a moderately severe fetomaternal Toxoplasmosis.

Atovaquone treatment

Atovaquone is currently used as a drug of choice against Toxoplasmosis but not tested in pregnancy. In order to study

efficacy of atovaquone against Toxoplasmosis in pregnancy, dams were divided into 2 groups. One group received atovaquone (hydroxy-1,4-naphthoquinone) incorporated into daily diet as indicated in our previous publications [13,14]. Control group received sham treatment (inert talcum powder). The treatment was initiated on Day 5 of pregnancy and continued until day 16 when dams were euthanized. On day 8 of pregnancy dams on treatment or sham control arms were further divided into 3 subgroups of 6–8 animals and were inoculated each with 0 (PBS), 300, or 600 Tachyzoites. Pregnant animals voluntarily consumed the diet with no major changes in their appearance, food consumption or weight/loss gain.

Sample collection

At the end of study dams were weight and euthanized using Co2 inhalation. Immediately, their chests were opened and blood from right ventricle collected into microtainer (BD Biosource, Rockville, MD). Sera were separated and stored frozen at -80°C . The splenic weight and length were recorded. Organs including liver, pancreas, spleen, heart and uterus were excised and weighed. Sections of these tissues were flash frozen in liquid nitrogen and stored at -80°C for future studies. Live fetuses were removed from uteri, counted, weighed and their length measured from crown to the base of the tail using a digital caliper.

Histopathological Examination

Colonic tissue and H&E staining

Colonic tissues were flushed with PBS (pH 7.2) and a portion from proximal and distal colonic tissue was fixed in 10% neutral formalin for histological examinations. The remainder was snap-frozen in liquid nitrogen and stored at -80°C . The formalin fixed sections were processed and stained with hematoxylin and eosin (H&E), and slides evaluated by Zeiss light microscopy. Severity of colitis was assessed with a histological semi-quantitative grading score and performed in a blinded fashion. The scores were based on histopathological features with a numeric value (0 – normal to 4 – severe) assigned according to the tissue involvement [24] that corresponded to either of the following criteria: Grade 0 – No detectable lesions, no inflammatory cells, normal mucosal appearance. Grade 1 – Focal inflammatory infiltrate in the mucosa. Grade 2 – Mild multi-focal inflammation with moderate expansion of the mucosa. Grade 3 – Moderate multi-focal inflammation with moderate expansion of the mucosa. Grade 4 – Severe diffuse inflammation with crypt epithelium disruption and ulceration.

Hepatic tissues

A small portion of the right lobe from hepatic tissues was placed in cassettes and fixed with 10% neutral buffered formalin. The specimens were dehydrated and embedded in paraffin, and tissue sections of $5\mu\text{m}$ were stained by Hematoxylin Eosin (H&E). Each slide was evaluated under light microscopy [25]. Hepatic lesions were graded on a scale of 0 to 4+, based on degeneration, inflammation, and necrosis as follows:

- Grade 0 – Represented no detectable lesions, no degeneration, infiltration of inflammatory cells, normal tissue appearance.
- Grade 1 – Focal infiltration of inflammatory cells in the tissue, and hepatocytes degeneration.
- Grade 2 – Mild multi-focal infiltration of inflammatory cells, and hepatocytes degeneration.
- Grade 3 – Moderate multi-focal infiltration of inflammatory cells, and hepatocytes degeneration.
- Grade 4 – Severe diffuse infiltration of inflammatory cells, and necrosis.

Giemsa staining

Giemsa is a delicate polychromatic stain that reveals a fine nuclear detail of *Toxoplasma* organisms. Giemsa stain contains Methylene Blue Azure Basic dyes combined with Eosin Acidic dyes. The deparaffinized slide sections were placed into the polychromatic Giemsa (40drops/50ml distilled water) to stain nuclei of the *Toxoplasma* organisms and to permit differentiation among the cells. Then, the slides were depreciated in 1% Glacial Acetic Acid, dehydrated in alcohol and xylene series and mounted in synthetic resin on the slides.

Immunohistochemical (IHC) staining

IHC was performed using Dabo EnVision+ System-HRP (DAB) kit. Anti-*Toxoplasma* antibody and IHC procedure were kindly provided by David S. Lindsay, PhD at University of West Virginia. Briefly, paraffin-embedded sections were cut, deparaffinized with xylene, rehydrated in alcohol baths, washed in PBS and 0.1% BSA, quenched endogenous peroxidase activity by incubating in 3% hydrogen peroxide in methanol for 30 min, then blocked with rabbit serum (Dako #N1699), for 30 min. The sections were incubated with polyclonal anti-*Toxoplasma* antibody, diluted 1:500 for 90 min and developed with DAB-Chromogen (Dako Carpenteria, CA) for about 5 min until signal developed. Slides were subsequently counterstained with hematoxylin then ammonia treated and dehydrated stepwise through alcohol, and cleared with xylene.

Behavioral test: assessment of pain related mechanical allodynia by testing abdominal withdrawal threshold

Abdominal withdrawal responses to mechanical stimuli were quantified with von Frey monofilaments (Semmes-Weinstein Anesthesiometer Kit, model #18011, Wood Dale, IL) according to our previous publication with some modification [26]. Briefly, mice were placed into plastic enclosures on the custom made screen meshed platform. The monofilament range used for this study included 5 different intensities corresponding to (hair diameter) gram force [(4.08) 1.0 g; (3.61) 0.4 g; (3.22) 0.166 g; (2.83) 0.07; (2.36) 0.02g forces]. Testing for mechanical stimulation was performed on the first and the last day of treatment. A single trial consisted of 5 applications of the each filament used once every 6 seconds to allow the dam to cease any response and return to an inactive position. Mean values of the percentage of responses of the abdominal withdrawal to each filament (mean withdrawal/5 \times 100) were used as % scores in this study. This behavioral test reflected basal level for reflex score and any possible sensory changes observed in the treated mice. Total 4 dams were tested per each group.

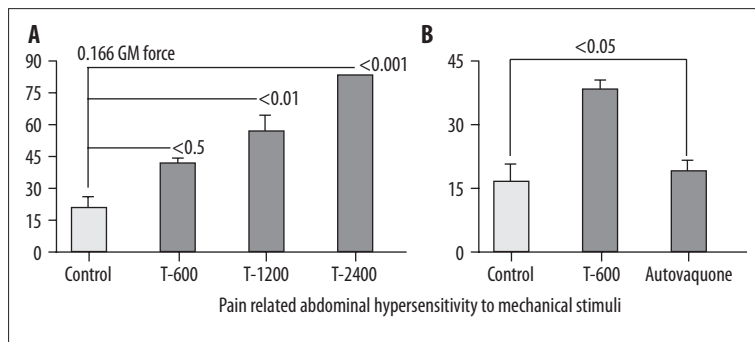


Figure 1. Percent pain related abdominal response to Von Frey mechanical stimuli to 0.166 GM force. **(A)** Dose dependent abdominal response from dams infected with Tachyzoites (T-600 to T-2400) compared to normal Controls demonstrating increased hypersensitivity to stimuli. **(B)** Atovaquone treatment ameliorated hypersensitivity to stimuli (allodynia) in infected dams (T-600).

Statistical analysis

Results are expressed as mean \pm SEM unless otherwise stated. Data was evaluated with ANOVA followed by appropriate *post hoc* test (Tukey compared all pairs) using GraphPad Instat version 3 for Windows (GraphPad Software, San Diego, CA). Statistical significance was set at $p < 0.05$.

RESULTS

Model for feto-maternal Toxoplasmosis

To establish the model, dams were infected with single inoculum of PTG strain Tachyzoites ranging from 100 to 2400 during the 2nd trimester of pregnancy. Dams infected with low dose (T-50) showed no significant clinical symptoms. While, those infected with higher number of Tachyzoites developed moderate to severe clinical complications in a dose dependent manner leading to abortion (4/8, 50%), early birth (1/4, 25%) or still birth (1/4, 25%).

Pain related abdominal response to stimuli

Infected dams showed significant increases in abdominal response to the mechanical stimuli (allodynia) with von Frey monofilaments. The elevated hypersensitivity showed a Tachyzoites dose dependent response with about 4 fold increments in dams receiving the highest dose (T-2400, $p < 0.001$) representing the most severe reaction to the stimuli (Figure 1A).

Excess body weight gain

Both uninfected normals as well as infected dams gained weight. However, dams infected with high doses of Tachyzoites (T-1200 to T-2400) showed a more severe edema, ascities, and hydrothorax with a significant excess body weight gain leading to fetal abortion or mummified embryos. Ascities consisted of a bright to bloody fluid and was mainly noted in the peritoneal and chest cavities (pneumothorax) and correlated with the higher doses of Tachyzoites.

Anemia

Infected dams became anemic with pale mucosa (hematocrit: $p < 0.01$ T-2400 Figure 2), in addition to hydrothorax and ascities. This was consistent with the splenomegaly with about X3 fold increases in splenic weight (Figure 3A) and length (Figure 3C) in the infected dams mainly due to the scavenging infected cells by the splenic tissues and the severe immune response to infection, demonstrating massive

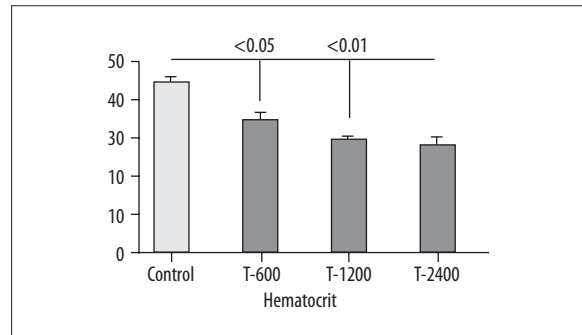


Figure 2. Infected dams had pale mucosa and became anemic as demonstrated by significant decreases in hematocrit values in a dose dependent manner (controls vs. T-600 $p < 0.05$, Controls vs. T-1200 and T-2400 $p < 0.01$).

infiltration of epithelioid cells, and engulfed infected macrophages in conjunction with loss of germinal structure in spleen in a dose dependent manner.

Hepatic and pancreatic pathology

Hepatic tissue became pale in color and weight increased due to inflammation. Infected dams developed hepatitis (scale 0 – normal to 4 – severe, T-1200 = 3.6 ± 0.1 $p < 0.001$) presenting portal lobular influx of inflammatory and plasma cells, multinucleated “dysplastic” hepatocytes and mild to severe hepatic necrosis. These lesions were in a dose dependent manner and correlated with the number of inoculated Tachyzoites (Figure 4A). In addition, dams showed mild to moderately severe pancreatitis with mononuclear cell invasion and loss of islets (not shown).

Cardiac pathology

Infected dams developed a mild to moderate myocardial necrosis, fibrin deposit, and infiltration of inflammatory cells (Figure 5). Small pseudocysts to elongated cysts were detected with a few to numerous bradyzoites embedded with aggregates of macrophages, plasma and monocytes infiltration. The cysts and occasional free organisms were detected in the heart, hepatic, and splenic tissues which were confirmed with Giemsa and immunohistochemical techniques (IHC).

Fetal weight and length

Dams infected with low doses of Tachyzoites (T-50 to T-300) did not show a significant differences between the

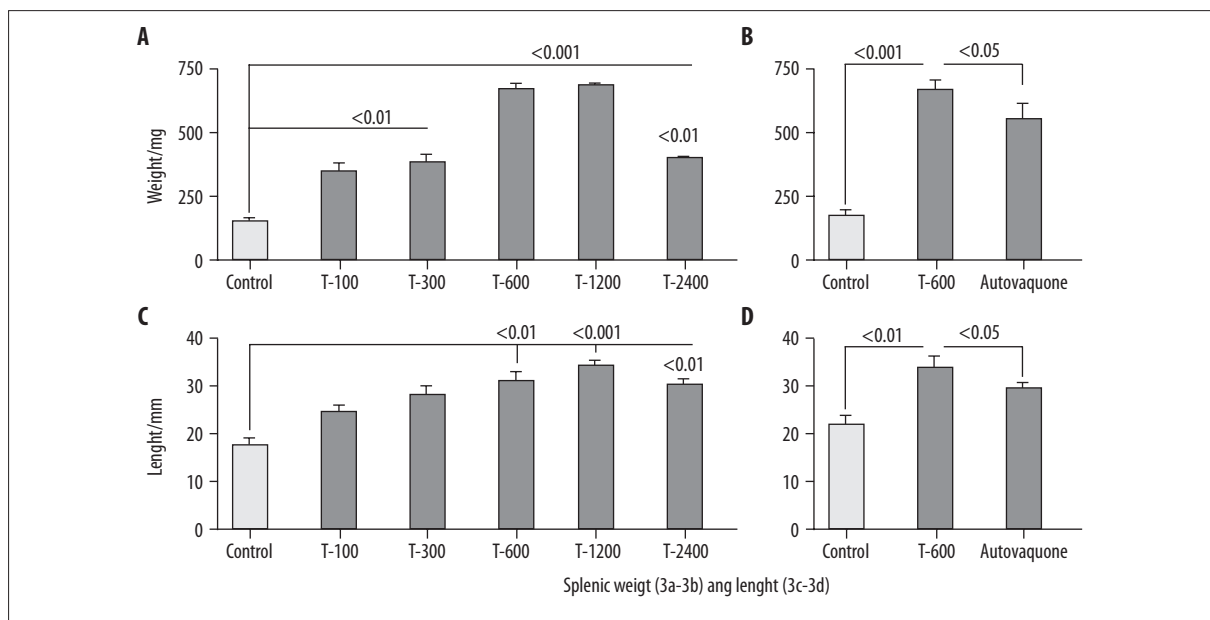


Figure 3. Splenic weight (A) and length (C) significantly increased in infected dams and partially but significantly improved in atovaquone treated animals (B, D, $p < 0.05$).

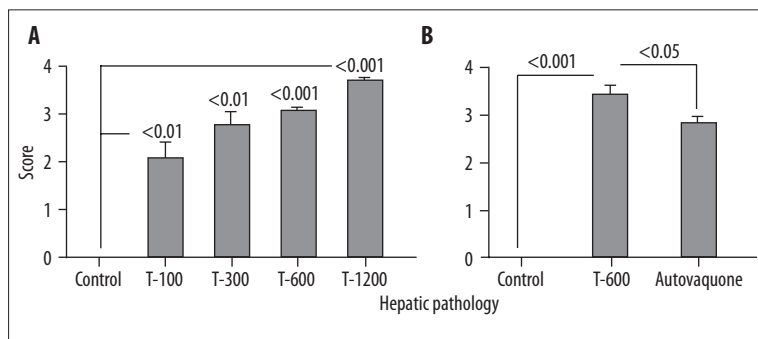


Figure 4. H&E stained sections from hepatic tissues were scored from normal (0) to severe (4) hepatitis (A). Atovaquone treatment significantly ameliorated the lesions in dams and protected against hepatitis as consequences of Toxoplasmosis (B).

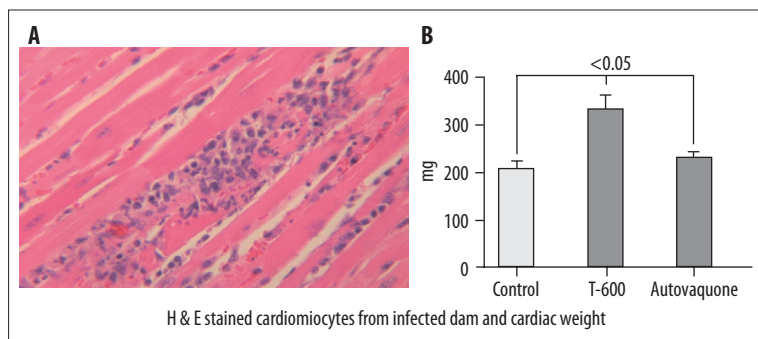


Figure 5. H&E stained cardiomyocytes from infected Dam and cardiac weight. Infected dams developed mild to moderate myocarditis (A) with infiltration of inflammatory cells (H&E staining). Cardiac weight increased in infected dams and atovaquone treatment attenuated pathological inflammatory response and excess weight (B).

appearance, fetal number, weight and length of the live fetuses ($p > 0.05$, NS). In contrast those dams inoculated with the high doses (T-1200 to T-2400) developed more progressive disease leading to abortion, or intrauterine fetal demise, and still birth (Figure 6A). Occasionally organisms were detected in the uterine tissue from infected dams with high dose of Tachyzoites by means of IHC (Figure 6B). Fetal weight (Figure 7A) was significantly affected in infected dams in a dose dependent manner leading to retarded and/or fetal loss.

Therefore, based on the above obtained data, a cutoff at 600 Tachyzoites (T-600) per inoculum was established to induce a moderately severe fetomaternal Toxoplasmosis in the model for further drug evaluation.

Atovaquone therapy in pregnancy model

Overall, atovaquone treated uninfected control dams showed no major differences compared to untreated normal controls (sham injected) for the parameters measured, and

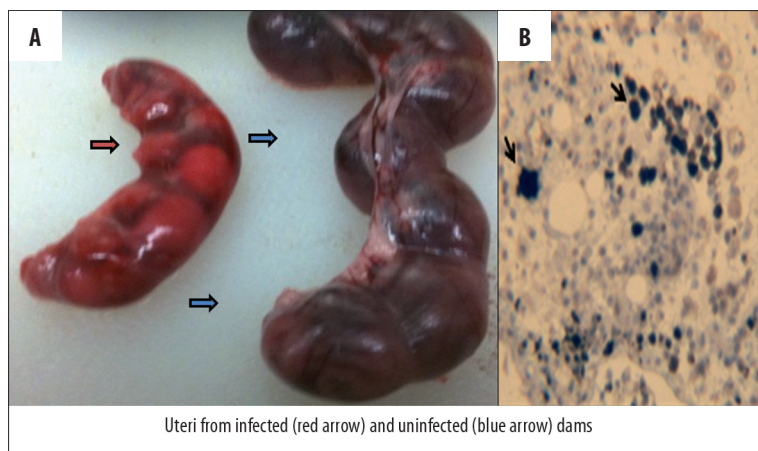


Figure 6. Uteri from infected (red arrow) and uninfected (blue arrow) dams (A) similar to atovaquone treated ones (not shown here). Immunohistochemical staining demonstrating infected uteri. Arrows point at the organisms (B).

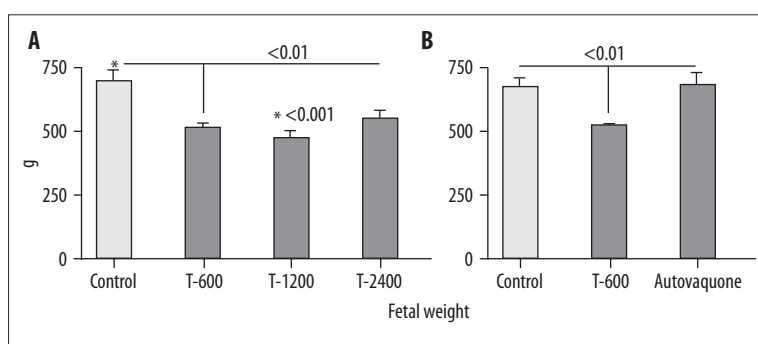


Figure 7. Fetal weight significantly decreased in a dose dependent response due to the infection (A). Atovaquone treatment returned the fetal weight to a normal value (B).

Table 1. Dams were infected with *Toxoplasma* Tachyzoites (T-600) on pregnancy and treated with atovaquone daily.

Tissues from Dams	Control	Infected	Infected + Treated	P < value
Body Weight gain (g)	14.2±0.6***	22.8±1	22.5±0.9	***<0.001
Colonic length (cm)	10.25±0.25**	8.6±0.27	8.6±0.5	**<0.01
Colonic weight/ atrophy (mg)	250±10**	200±10**,*	230±10*	**<0.01, *<0.05
Hematocrit (%)	44.5±1.2*	37±1.4	34.7±3.3	*<0.05
Uteri weight (g)	11.6±0.5*	13.9±0.7*	12.8±1	*<0.05
Hepatic weight (g)	1.78±0.24**,*	3.4±0.13**	3.1±0.34*	**<0.01, *<0.05

P value – * <0.05; ** <0.01; *** <0.001.

kept a normal status. Whereas, atovaquone treated and infected dams showed no significant improvement in their excess body weight gain compared to infected (untreated) animals (Table 1).

Pain related abdominal response to stimuli and atovaquone therapy

Infected dams (T-600) showed a significant pain related abdominal hypersensitivity ($p < 0.05$) to mechanical stimuli (Figure 1B). In contrast, atovaquone treatment attenuated this neuropathological reactions to a normal level ($p < 0.05$) indicating efficacy of atovaquone to ameliorate pain related clinical symptoms of infection/inflammatory induced hypersensitivity (Figure 1B).

Anemia, splenomegaly and atovaquone therapy

Atovaquone did not improve hematocrit or anemia in infected and treated dams (Table 1). Infected dams developed enlarged fragile splenic tissues. In contrast, atovaquone therapy partially but significantly attenuated splenomegaly and the pathological increases in the splenic weight and length in infected dams (Figure 3B, D).

Pathology and atovaquone therapy

Hepatitis

Infected dams (T-600) developed moderately severe hepatic lesions (score of 3.3 ± 0.01 , $P < 0.001$) presenting, scattered dysplastic hepatocytes and moderate to severe hepatic

necrosis and excess weight due to infiltration of inflammatory cells ($p < 0.01$) (Figure 4). Atovaquone partially but significantly attenuated these pathological manifestations and improved hepatic structural integrity (score 2.8 ± 0.1 , $p < 0.05$) (Figure 4B) as well as the excess hepatic weight ($p < 0.05$) (Table 1).

Colonic pathology

Colonic tissues from infected dams (T-600) were significantly shortened in length (10.4 ± 0.2 vs. infected 8.7 ± 0.6 cm, $p < 0.01$) and decreased in weight ($p < 0.01$) presumably through the mechanism of sloughing off of the brush boarder in infected dams (Table 1). Colonic pathology manifested with shortening of crypts with numerous microabscess formations, and infiltration of inflammatory cells, including lymphocytes, and macrophages with few scattered neutrophils detected in the mucosal area. Atovaquone extensively protected dams from colonic inflammatory and necrotic/atrophic responses to the infection ($p < 0.05$). In addition, a mild to severe pancreatitis was diagnosed in infected dams (T-600 vs. Normal, $p < 0.05$) with invasion of mononuclear cells and loss of islets (not shown). Similarly, atovaquone treatment partially but significantly protected the dams from these pathological and inflammatory aspects of the GI Toxoplasmosis.

Cardiac pathology

Infected dams developed a mild myocardial necrosis, fibrin deposit, and infiltration of inflammatory cells as shown in H&E staining (Figure 5). Small to elongated cysts were detected with a few to numerous bradyzoites embedded with aggregates of macrophages and plasma and monocytes infiltration. This was consistent with the detection of cysts and free organisms in the heart, hepatic as well as the splenic tissues which were confirmed with Giemsa and IHC techniques. Atovaquone significantly improved myocardial pathology and excess cardiac weight (Figure 5B).

Fetal weight

Infected dams (T-600) showed fetal retardation and sporadic cases of still birth. In contrast, atovaquone treatment protected nested fetuses in uterine from weight loss, retardation and demise (Figure 7B).

DISCUSSION

Two billion people worldwide are predicted to have Toxoplasmosis, frequently with unknown lifelong health consequences [28]. *Toxoplasma* is considered as the 3rd major cause of foodborne diseases' hospitalization and death in the U.S.A [27]. Toxoplasmosis can have mild effects on immunocompetent to very severe pathological damage in congenital transmission. Congenital Toxoplasmosis is caused by a reactivation, or as an acquired infection during pregnancy is known to be associated with an altered balance of immune response rather than direct noxious actions of the pathogen [3–5]. Feto-maternal Toxoplasmosis results in an extensive immune and inflammatory response to the organisms in the gastrointestinal tissues with a low number of pathogenic burdens as demonstrated in this pregnancy model. Indeed, managing the inflammation is vital in order to prevent damage to the host and the nested fetus

during the infection. While, uncontrolled inflammatory response in Toxoplasmosis can be fatal during the pathogenic clearance [29].

Our findings with this murine system support the model in which fetal health is compromised by the invasion of pathogens and encountered inflammatory responses from infected dam through the mechanism of transplacental transmission and in a dose dependent manner. A recent study indicates that a dose of 10,000 bradyzoites or 100 oocysts of the Prugniald strain (Type II) to cause 50% congenital infection of the rat litters. In contrast, lactation alone did not support transmission of infection from dams to the neonates [19].

Pregnant women become infected by ingestion of oocysts contaminated food, or consumption of cysts harboring bradyzoites-infected meat. Additionally, transplacental transmission is acquired by the reactivation of the chronic or latent infection due to the stressors including pregnancy and immunosuppressors. In any circumstances, whether oocysts, cysts, (or Tachyzoites) are the origin of the infection the organisms transform to Tachyzoites and replicate in the organs to cause the infection. Then the Tachyzoites are required to bypass the transplacental blood barrier to invade the fetus and to compromise the embryonic developmental process.

The current model bypasses the requirement for oral passage and a large number of organisms by using direct intraperitoneal inoculation to cause feto-maternal Toxoplasmosis.

This model imitates well the *Toxoplasma* reactivation or contaminated blood transfusion and organ transplantation, and uses a fewer organisms than those required for an oral infection. Additionally, this model eliminates the use of extra animals (mice or cats) to develop cysts or oocysts. Therefore, the present model mimics well the process of the intrauterine infection, and evades the oral inoculation and the need for a large numbers of the organisms.

The majority of *Toxoplasma* strains so far isolated from North America and Europe belong to three clonal lineages I–III, of which types I and II are associated with congenital Toxoplasmosis [30]. For this study, we used type II Tachyzoites from PTG strain (ME-49) originally cloned and propagated [22] to initiate the infection. ME-49 genotype II strain is most frequently associated with the human disease including congenital Toxoplasmosis [21,30–33] and used in this study to develop the feto-maternal model for the drug evaluation.

Thus far, there is no safe and effective or FDA approved therapy against congenital Toxoplasmosis or any drug capable of eliminating the persistent, chronic infection [10]. Atovaquone is a drug of choice against Toxoplasmosis but not yet approved for the use in pregnancy or small children. As shown in this study, atovaquone was effective against complications in the model and limited the inflammatory responses to Tachyzoites infection in organs such as cardiac, spleen, hepatic and colonic tissues and therefore protected the fetuses and the dams from the infection.

Atovaquone has been shown to be effective against Tachyzoites and cyst forms of *Toxoplasma* [12], *Pneumocystis*

carinii [11], *Plasmodium Falciparum* (12) and *B. microti* [13,14] organisms. Atovaquone is known to inhibit parasite and fungal respiration by binding to the ubiquinol oxidation site of cytochrome bc1 complex [34] by affecting the mitochondrial function and collapsing their membrane [35]. The radio-labelled tracing in man has proven that atovaquone mainly attaches to the plasma protein (99%) with a half life of 1.5 to 3 days with 2 peaks; the 1st peak appears at 1–8 h and 2nd in 1–4 days after a single oral dose in human volunteers. In addition, surgical biliary tube insulation in patients demonstrated that atovaquone is exclusively (94%) excluded from the body through the feces and it is not metabolized by humans [36]. Indeed, mice with a targeted gene mutation in the interferon regulatory factor 8 when latently infected with *Toxoplasma*, developed reactivated encephalitis, and those treated with atovaquone were protected against encephalitis and death [37]. Furthermore, atovaquone treatment was proven to be superior to the standard therapy with pyrimethamine plus sulfadiazine or combination of pyrimethamine plus clindamycin based on the inflammatory responses in the brain parenchyma, and the number of the organisms located in the brain in a mice [37]. In addition, atovaquone was detectable in sera, brains, livers, and lungs from infected mice using high pressure liquid chromatography (HPLC) and Mass Spectroscopy [37].

Generally, *Toxoplasma* disseminates from the gut throughout the body, and the organisms seek refuge in the muscular tissue and CNS in cysts forms during the dormant stage [38]. It is known that extracellular Tachyzoites readily infect the host leucocytes, monocytes and dendritic cells and exploiting the host cells as “Trojan Horse” a) to disseminate throughout the body and to cross the placenta [39] as well as the blood brain barrier and b) to provide protection against host immune defense [40].

In this investigation, the model well mimicked the disease in the human pregnancy and atovaquone had a limited but significant protective effect against gastrointestinal complications in these animals. Here, dams demonstrated significant excess weight gain ($p < 0.001$) due to the inflammatory response to the infection. This is in accord with a recent retrospective cohort study in 194 infected pregnant women who gained more weight when compared to 785 uninfected moms ($P < 0.001$) [41]. However, atovaquone had minor effect on the excess body weight gain in this model.

Thus, the fetomaternal and GI complications described here permitted us to evaluate the efficacy of atovaquone in this Toxoplasmosis pregnancy model. Atovaquone proved to be fairly safe and to protect against inflammatory aspects of the fetomaternal progression of Toxoplasmosis. These findings warrant further functional, biochemical and molecular mechanistic studies in the fetal development, and related syndrome and the use for development of new and effective therapies.

CONCLUSIONS

This model can be used for therapeutic evaluation in fetomaternal Toxoplasmosis and gastrointestinal complications. This study proves that atovaquone protects against some inflammatory aspects of gastrointestinal and fetomaternal Toxoplasmosis in this model.

Acknowledgement

Felicia Kost assisted with animal handling. Tachyzoites were provided by Dr Daniel Howe. Dr David S. Lindsay kindly provided anti-mouse *Toxoplasma* specific antibody for immunohistochemical staining. Dana Ross assisted with IHC staining. This research was supported partially by the grants from Kentucky Science and Technology KSTC 721-RFP-006 (Dr. Thomas Tobin) and National Institutes of Health NIH-DE019177 (H. Oz).

Abbreviations

BSA – Bovine serum albumin; **CDC** – Center for Disease Control; **CNS** – Central nervous system; **FDA** – Food and Drug Administration; **H&E** – Hematoxylin Eosin; **IACUC** – Institutional Animal Care Use Committee; **IBC** – Institutional Biosafety Committee; **IHC** – Immunohistochemical staining; **i.p.** – Intraperitoneally; **MEM** – Minimum essential medium; **PBS** – Phosphate buffer saline.

REFERENCES:

- Dubey JP, Jones JL: *Toxoplasma gondii* infection in humans and animals in the United States. *Int J Parasitol*, 2008; 38: 1257–78
- Jones JL, Kruszon-Moran D, Wilson M et al: *Toxoplasma gondii* infection in the United States: Seroprevalence and risk factors. *Amer J Epidemiol*, 2001; 154: 357–65
- Buxton D, Thomson K, Maley S et al: Vaccination of sheep with a live incomplete strain (S48) of *Toxoplasma gondii* and their immunity to challenge when pregnant. *Vet Rec*, 1991; 129: 89–93
- Wolf A, Cowen D, Paige B: Human Toxoplasmosis: occurrence in infants as an encephalomyelitis verified by transmission to animals. *Science*, 1939; 89: 226–27
- Jones JL, Lopez A, Wilson M et al: Congenital Toxoplasmosis: A review. *Obst Gynecol Surv* 2001;56: 296–305.
- Wong SY, Remington JS: Toxoplasmosis in pregnancy. *Clin Infect Dis*, 1994; 18: 853–61
- Brown AS, Schaefer CA, Quesenberry CP Jr et al: Maternal exposure to Toxoplasmosis and risk of schizophrenia in adult offspring. *Am J Psychiatry*, 2005; 162: 767–73
- Bachmann S, Schröder J, Bottmer C et al: Psychopathology in first-episode schizophrenia and antibodies to *Toxoplasma gondii*. *Psychopathology*, 2005; 38: 87–90
- Wang HL, Wang GH, Li QY et al: Prevalence of *Toxoplasma* infection in first-episode schizophrenia and comparison between *Toxoplasma*-seropositive and *Toxoplasma*-seronegative schizophrenia. *Acta Psychiatr Scand*, 2006; 114: 40–48
- Cortina-Borja M, Tan HK, Wallon M et al.; European Multicentre Study on Congenital Toxoplasmosis (EMSCOT): Prenatal treatment for serious neurological sequelae of congenital Toxoplasmosis: an observational prospective cohort study. *PLoS Med*, 2010; 12(7) pii: e1000351
- Oz HS, Hughes W, Reh J: A rat model for dual opportunistic pathogens: *Cryptosporidium parvum* and *Pneumocystis carinii*. *Lab Animal Sci*, 1999; 49: 331–34
- Hudson AT, Dickens M, Ginger CD et al: 566C80: a potent broad spectrum anti-infective agent with activity against malaria and opportunistic infections in AIDS patients. *Drugs Exp Clin Res*, 1991; 17: 427–35
- Hughes W, Oz HS: Successful prevention and treatment of babesiosis with atovaquone. *J Infect Dis*, 1995; 172: 1042–46
- Oz HS, Westlund KH: “Human Babesiosis” an emerging transfusion dilemma. *Int J Hepatol*, 2012; doi:10.1155/2012/431761
- Daffos F, Forestier F, Capella-Pavlovsky M et al: Prenatal management of 746 pregnancies at risk for congenital Toxoplasmosis. *N Engl J Med*, 1998; 318: 271–75
- Berrebi A, Assouline C, Bessieres MH et al: Long-term outcome of children with congenital Toxoplasmosis. *Am J Obstet Gynecol*, 2010; 203: 552.e1–6
- Habib FA: Post-treatment assessment of acute *Toxoplasma* infection during pregnancy. *J Obstet Gynaecol*, 2008; 28: 593–95

18. Julliac B, Theophile H, Begorre M, Richez B, Haramburu F: Side effects of spiramycin masquerading as local anesthetic toxicity during labor epidural analgesia. *Int J Obstet Anesth*, 2010; 19: 331–32
19. Dubey JP, Ferreira LR, Martins J, McLeod R: Oral oocyst-induced mouse model of Toxoplasmosis: effect of infection with *Toxoplasma gondii* strains of different genotypes, dose, and mouse strains (transgenic, out-bred, in-bred) on pathogenesis and mortality. *Parasitology*, 2011; 14: 1–13
20. Takahashi J, Fukuda T, Tanaka J et al: Bax-induced apoptosis not demonstrated in the congenital Toxoplasmosis in mice. *Brain Dev*, 2001; 23: 50–53
21. Howe DK, Honore S, Derouin F, Sibley LD: Determination of genotypes of *Toxoplasma gondii* strains isolated from patients with Toxoplasmosis. *J Clin Microbiol*, 1997; 35: 1411–14
22. Su C, Howe DK, Dubey JP et al: Identification of quantitative trait loci controlling acute virulence in *Toxoplasma gondii*. *PNAS*, 2002; 99: 10753–58
23. Oz HS, Ebersole J, de Villiers W: The Macrophage Pattern Recognition Scavenger Receptors SR-A and CD36 protect against microbial induced pregnancy loss. *Inflam Res*, 2011; 60: 93–97
24. Oz HS, Chen T, Nagasawa H: Comparative Efficacies of Two Cysteine Prodrugs and a Glutathione Delivery Agent in a Colitis Model. *Transl Res*, 2007; 150: 122–29
25. Oz HS, IM H, Chen T et al: Glutathione enhancing agents protect against Steatohepatitis in a model. *J Biochem Mol Toxicol*, 2006; 20: 39–47
26. Westlund KH, Zhang L, Ma F, Oz HS: Chronic inflammation and pain in a tumor necrosis factor receptor (TNFR) (p55/p75-/-) dual deficient murine model. *Transl Res*, 2012; 160(1): 84–94
27. Mead PS, Slutsker L, Dietz V et al: Food-related illness and death in the United States. *Emerg Infect Dis*, 1999; 5: 606–25
28. Prandota J: The importance of toxoplasma gondii infection in diseases presenting with headaches. Headaches and aseptic meningitis may be manifestations of the Jarisch-Herxheimer reaction. *Int J Neurosci*, 2009; 119: 2144–82
29. Machado FS, Johndrow JE, Esper L et al: Anti-inflammatory actions of lipoxin A4 and Aspirin-triggered lipoxin are SOCS-2 dependent. *Nat Med*, 2006; 12: 330–34
30. Ajzenberg D, Cogne N, Paris L et al: Genotype of 86 *Toxoplasma gondii* isolates associated with human congenital Toxoplasmosis, and correlation with clinical findings. *J Infect Dis*, 2002; 186: 684–89
31. Howe DK, Sibley LD: *Toxoplasma gondii* comprises three clonal lineages: correlation of parasite genotype with human disease. *J Infect Dis*, 1995; 172: 1561–66
32. Sibley LD, Howe DK: Genetic basis of pathogenicity in Toxoplasmosis. *Curr Top Microbiol Immunol*, 1996; 219: 3–16
33. Araujo FG, Slifer T: Different Strains of *Toxoplasma gondii* Induce Different Cytokine Responses in CBA/Ca Mice. *Infect Immun*, 2003; 71: 4171–414
34. Freyre A, Falcon J, Mendez J, Gonzalez M: *Toxoplasma gondii*: an improved rat model of congenital infection. *Exp Parasitol*, 2008; 120: 142–46
35. Srivastava IK, Vaidya AB: A mechanism for the synergistic antimalarial action of atovaquone and proguanil. *Antimicrob Agents Chemother*, 1999; 43: 1334–39
36. Rolan PE, Mercer AJ, Tate E et al: Disposition of atovaquone in humans. *Antimicrob Agents Chemother*, 1997; 41: 1319–21
37. Dunay IR, Heimesaat MM, Bushrab FN et al: Atovaquone Maintenance Therapy Prevents Reactivation of Toxoplasmic Encephalitis in a Murine Model of Reactivated Toxoplasmosis. *Antimicrob Agents Chemother*, 2004; 48: 4848–54
40. Elsheikha HM, Khan NA: Protozoa traversal of the blood brain barrier to invade the central nervous system. *FEMS Microbiol Rev*, 2010; 34: 532–53
41. Kankova S, Sulc J, Flegr J: Increased pregnancy weight gain in women with latent Toxoplasmosis and RhD-positivity protection against this effect. *Parasitology*, 2010; 137: 1773–79