

Case Report

Severe Bilateral Photophobia and Unilateral Abducens Nerve Palsy: An Unusual Presentation of Herpes Zoster Ophthalmicus

Ian Seddon^a Keith Skolnick^b

^aCollege of Osteopathic Medicine, Nova Southeastern University, Fort Lauderdale, FL, USA;

^bFort Lauderdale Eye Institute, Plantation, FL, USA

Keywords

Herpes zoster ophthalmicus · Photophobia · Painful ophthalmoplegia · Abducens nerve palsy · Corticosteroids

Abstract

Herpes zoster ophthalmicus (HZO) is an uncommon neurocutaneous condition resulting from reactivation of the varicella zoster virus in the ophthalmic division of the trigeminal nerve. Typical presentation of HZO includes a characteristic painful vesicular dermatomal rash. However, the appearance of isolated neurologic complications in the absence of ocular findings has not been previously emphasized. We observed a 47-year-old female patient with established HZO who presented with 1 week of worsening bilateral photophobia and double vision following completion of antiviral treatment. Her motility examination revealed near-complete abduction deficit of her left eye with no other signs of neurologic deficit. Slit lamp biomicroscopy, magnetic resonance imaging, and all laboratory tests were negative. After 2 tapering cycles of oral corticosteroid treatment, her photophobia resolved, and ophthalmoplegia significantly improved. The failure of antiviral therapy in preventing our patient's neurologic sequelae highlights the importance of concurrent steroid therapy in suspected HZO patients. Furthermore, the resolution of symptoms following administration of systemic glucocorticoids supports consideration of HZO complications as immune-mediated. Finally, the unusual presentation of bilateral photophobia in the absence of ocular inflammation warrants further investigation into the pathogenesis of HZO.

© 2021 The Author(s).
Published by S. Karger AG, Basel

Introduction

Herpes zoster ophthalmicus (HZO) is a sight-threatening condition that occurs when varicella zoster virus (VZV) reactivates along the ophthalmic division (V1) of the trigeminal nerve. While the most typical manifestation of HZO is limited to the periorbital region with pain and a cutaneous rash, over 50% of patients will also demonstrate inflammatory involvement of ocular, orbital, and – on rare occasion – neural tissues [1].

With an annual estimated incidence between 100,000 and 200,000 cases in the USA each year, it is critical for clinicians to know how to quickly identify and treat the various complications of HZO [2]. Here, we describe a case of HZO presenting with delayed sequelae of bilateral photophobia and diplopia without evidence of ocular inflammation.

Case Report

A 47-year-old Caucasian female patient presented with 1 week of worsening bilateral photophobia and horizontal double vision. The photophobia was preceded by left retro-orbital pain that was gradually worsening and constant. There was no change in vision, nausea, or vomiting. The patient had been recently diagnosed with HZO limited to the V1 distribution on her left side and had completed a 10-day course of valacyclovir 2 weeks before. Her past medical history includes CREST syndrome, thyroid disease, hypertension, hyperlipidemia, lactose intolerance, and gluten insensitivity.

On clinical examination, her vital signs and mental status were within normal limits. She was a well-appearing middle-aged woman in significant distress. She arrived with her left eye patched shut. Her eyelids had to be manually retracted to perform the ocular examination due to her severe photophobia. The patient's cranial nerve examination exhibited a complete abduction deficit of her left eye consistent with an abducens nerve palsy. The remainder of the neurologic examination was normal with intact adduction, elevation, and depression of the left eye. Both pupils were equal, round, and responsive to light. No facial sensory or motor loss in the distribution of the trigeminal or facial nerves was detected.

Examination of the patient's left ocular adnexa revealed lesions along the forehead and scalp that were consistent with her prior diagnosis of HZO. She reported persistent facial and scalp pain in the distribution of the V1 branch of the trigeminal nerve, indicative of postherpetic neuralgia. However, slit lamp examination revealed no conjunctivitis, keratitis, or iritis, and staining yielded no corneal lesions. Fundoscopy was normal.

A tentative diagnosis of Tolosa-Hunt syndrome (THS) was made. The patient was referred for urgent brain magnetic resonance imaging (MRI) and medical workup at Westside Regional Hospital. Complete blood count, comprehensive metabolic panel, and erythrocyte sedimentation rate were within normal limits, with mild elevation of C-reactive protein. Cranial and orbital MRI with and without contrast revealed no abnormalities.

The neurologist started her on 50 mg pregabalin and naproxen QD for her postherpetic neuralgia. A tapering course of oral methylprednisolone (Medrol®) was initiated to treat her presumed THS. Topical corticosteroid drops (Lotemax®) were prescribed TID OU in an attempt to treat her ocular discomfort, despite the lack of keratoconjunctivitis.

Left eye pain significantly improved within days of starting treatment; however, on 2-week follow-up, the severe photophobia remained, and ocular motility examination only revealed 30% improvement of her abduction deficit. She was started on a tapering oral regimen of prednisone 30 mg BID for 2 days, 20 mg BID for 2 days, and then 10 mg BID for 2 days. Within 2 weeks, the patient reported complete resolution of the photophobia and improved left gaze. However, improvement of her binocular horizontal diplopia was more

gradual, with abduction deficit persisting 4 weeks (shown in Fig. 1) and 7 weeks later (shown in Fig. 2).

Discussion

HZO accounts for nearly 20% of the estimated 1 million cases of herpes zoster that occur in the USA each year [2]. Although HZO is defined as the reactivation of VZV in the ophthalmic distribution of the trigeminal nerve V1, 50% of all cases have direct ocular involvement, and significant neurologic complications can occur [1]. Diagnosis is usually made clinically, requiring both a history of a prior VZV infection with the characteristic painful rash in V1 dermatomal distribution. Initial evaluation of our patient met these conditions.

The delayed onset of photophobia and diplopia following completion of antiviral treatment mandated further evaluation to rule out coexisting conditions. Isolated abducens nerve palsy in the absence of a relative afferent pupillary defect pointed to the cavernous sinus as the location of the lesion. Our differential included a cerebral mass and THS, which is a rare cause of painful ophthalmoplegia due to idiopathic granulomatous inflammation of the cavernous sinus. However, neuroimaging showed no radiologic evidence of inflammation within the cavernous sinus, which is a required criterion for diagnosing THS, albeit a controversial one [3–5]. Nevertheless, given the atypical association of HZO with external ocular motor palsies and the lingering presence of periorbital lesions in the distribution of the ophthalmic nerve (V1), we believe her diplopia was associated with HZO [6].

While photophobia is a common symptom of herpes zoster infection, our patient did not manifest the ocular examination findings that would normally cause photophobia such as keratitis or iritis. Administration of topical corticosteroids did not improve her photophobia, pointing to a more neurologic source. Furthermore, her photophobia was bilateral and severe, and positively responded to systemic glucocorticoid treatment, which indicates an inflammatory etiology localized to the central nervous system and its surrounding structures. The current literature reports no instances of HZO-related photophobia independent of ocular complications, making this a unique presentation of HZO [7].

A weakness of this case report is that a lumbar puncture was not obtained for serologic and PCR testing of her cerebrospinal fluid. Diagnosis of HZO can be made clinically, but several

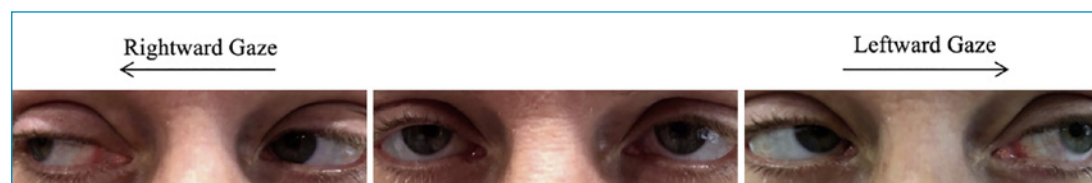


Fig. 1. Ocular motor findings 4 weeks after initiation of corticosteroid treatment. The patient demonstrates left abducens nerve palsy with 50% improvement from original deficit.

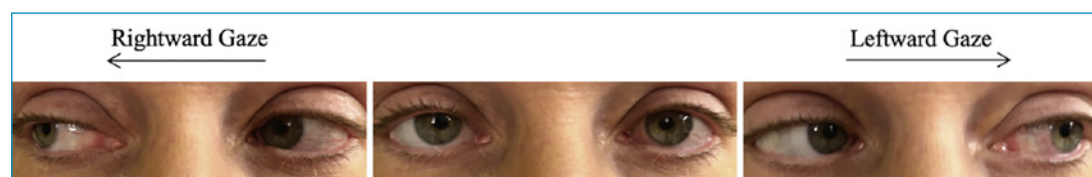


Fig. 2. Ocular motor findings 7 weeks after initiation of corticosteroid treatment. The patient demonstrates left abducens nerve palsy with 90% improvement from original deficit.

guidelines recommend molecular confirmation for cases with ocular or neurologic complications [8]. However, given her benign diagnostic workup in addition to the prompt resolution of pain following initiation of steroid treatment, further invasive investigation was deemed unnecessary.

The mechanism behind HZO-associated complications is unknown with theories ranging from direct viral invasion to secondary inflammation extending to nearby neurologic and vascular structures. Administration of systemic antivirals has been shown to improve patient prognosis, seemingly supporting a virally mediated pathogenesis [9, 10]. However, there is growing evidence that antiviral therapy combined with systemic corticosteroids may be more effective in treating the sequelae of HZO [11]. In a recent retrospective study, 9 of 12 patients with HZO-related optic neuropathy experienced improved visual outcomes after receiving adjuvant corticosteroid therapy [12]. Furthermore, there are multiple reports of delayed onset ophthalmoplegia after antiviral treatment, indicating that antiviral therapy alone may not be sufficient to prevent the neurologic complications of HZO [13].

While cranial MRI failed to show signs of inflammation, our case seems to support the inflammatory theory based on the positive response to steroids following antiviral therapy. Additionally, the delayed onset of her symptoms following antiviral therapy points to the potential utility of dual therapy with antivirals and steroids when treating HZO.

Conclusion

HZO is a debilitating manifestation of herpes zoster that occurs in 10–20% of cases in the USA [1]. As the incidence of herpes zoster increases due to an aging population, much is still unknown about its pathophysiology and manifestations. Although this patient was diagnosed with HZO and completed antiviral treatment, isolated neurologic complications still developed weeks later. For want of other etiologies, we believe these complications can be attributed to the HZO infection. This case strengthens the association of HZO with immune-mediated complications by highlighting a positive response to systemic corticosteroids. The failure of antiviral therapy in preventing our patient's neurologic sequelae accents the importance of concurrent steroid therapy in suspected HZO patients. Additionally, our patient's unusual presentation of bilateral photophobia in the absence of ocular inflammation prompts further study into the pathogenesis of HZO and the potential spread of inflammation into intracranial structures such as the meninges.

Statement of Ethics

Verbal and written informed consent was obtained from the patient for publication of this case report and all accompanying images.

Conflict of Interest Statement

The authors have no conflicts of interest to declare.

Funding Sources

The authors have no funding or grant support to declare.

Author Contributions

All authors collected and interpreted the patient clinical findings. I.S. and K.S. contributed to the writing and editing of the manuscript. I.S. reviewed the literature. All authors were involved with final approval and agreed to be accountable for the integrity of the manuscript.

References

- 1 Kedar S, Jayagopal LN, Berger JR. Neurological and ophthalmological manifestations of varicella zoster virus. *J Neuroophthalmol*. 2019 Jun;39(2):220–31.
- 2 Rolain M, Trese MGJ, Rooney DM, Krishnan A, Stec L, Granadier RJ. The case of the droopy eyelid and frozen globe. *Eyenet Mag*. 2020 Aug;24(8):35–7.
- 3 Headache classification committee of the international headache society (IHS). The international classification of headache disorders. 3rd edition. *Cephalalgia*. 2018 Jan;38(1):1–211.
- 4 Podgorac A, Zidverc-Trajkovic J, Jovanovic Z, Ristic A, Radojicic A, Pavlovic A, et al. Tolosa-Hunt syndrome: is it really necessary to show granuloma? The report of eight cases. *Vojnosanit Pregl*. 2015 Dec;74:180.
- 5 Hao R, He Y, Zhang H, Zhang W, Li X, Ke Y. The evaluation of ICHD-3 beta diagnostic criteria for Tolosa-Hunt syndrome: a study of 22 cases of Tolosa-Hunt syndrome. *Neurol Sci*. 2015 Mar;36(6):899–905.
- 6 Marsh RJ, Dulley B, Kelly V. External ocular motor palsies in ophthalmic zoster: a review. *Br J Ophthalmol*. 1977 Nov;61(11):677–82.
- 7 Schaftenaar E, Meenken C, Baarsma GS, McIntyre JA, Verjans GM, Peters RP. Early- and late-stage ocular complications of herpes zoster ophthalmicus in rural South Africa. *Trop Med Int Health*. 2016 Mar;21(3):334–9.
- 8 Werner R, Nikkels A, Marinović B, Schafer M, Czarnecka-Operacz M, Agius A, et al. European consensus-based (S2k) Guideline on the management of herpes zoster: guided by the European Dermatology Forum (EDF) in cooperation with the European Academy of Dermatology and Venereology (EADV), Part 1: diagnosis. *J Eur Acad Derm Venereol*. 2017 Jan;31(1):9–19.
- 9 Pascual-Prieto J, Benito-Pascual B, Hernández-García E, Domingo-Gordo B, Gómez-de-Liaño R. Oculomotor nerve palsy in herpes zoster ophthalmicus: presentation of 4 cases. Parálisis oculomotoras en el contexto de una reactivación del virus varicela-zóster: a propósito de 4 casos. *Arch Soc Esp Ophthalmol*. 2020 Aug;95(8):404–7.
- 10 Catron T, Hern HG. Herpes zoster ophthalmicus. *West J Emerg Med*. 2008 Aug;9(3):174–6.
- 11 Haargaard B, Lund-Andersen H, Milea D. Central nervous system involvement after herpes zoster ophthalmicus. *Acta Ophthalmol*. 2008 Nov;86(7):806–9.
- 12 Kaufman AR, Myers EM, Moster ML, Stanley J, Kline LB, Golnik KC. Herpes zoster optic neuropathy. *J Neuroophthalmol*. 2018 Jun;38(2):179–89.
- 13 Osman SA. Successful oral treatment of third cranial nerve palsy and optic neuritis from neglected herpes zoster in an immunocompetent patient. *Am J Ophthalmol Case Rep*. 2020 Oct;20:100953.