

Occult lipomatosis of the nerve as part of macrodystrophia lipomatosa: illustrative case

Tomas Marek, MD,^{1,3} Kimberly K. Amrami, MD,² and Robert J. Spinner, MD¹

Departments of ¹Neurologic Surgery and ²Radiology, Mayo Clinic, Rochester, Minnesota; and ³First Faculty of Medicine, Charles University, Prague, Czech Republic

BACKGROUND Macrodystrophia lipomatosa (MDL) is characterized by progressive overgrowth affecting soft tissues and bony structures and is part of lipomatous overgrowth syndromes. MDL has been associated with lipomatosis of the nerve (LN), an adipose lesion of nerve that has a pathognomonic magnetic resonance imaging (MRI) appearance as well as a mutation in the *PIK3CA* gene. The authors present a case of occult LN in the setting of MDL.

OBSERVATIONS A 2-year-old boy with progressive soft tissue overgrowth of his proximal right lower extremity was initially diagnosed with neurofibromatosis type 1 (NF1). At our institution, NF1 as well as other overgrowth syndromes including *PTEN* hamartoma tumor syndrome were excluded. He was diagnosed as having so-called MDL. Upon reinterpretation of the patient's MRI studies, short-segment LN involving the proximal sciatic nerve and part of lumbosacral plexus was identified. He underwent 2 debulking/liposuction procedures for soft tissue overgrowth. Genetic testing of tissue revealed a mutation in *PIK3CA*.

LESSONS Thorough clinical examination (for signs of overgrowth) as well as an MRI study of the entire neural pathway is a critical part of the diagnostic workup to evaluate for LN. The authors believe that an increasing association of LN, even when occult, will emerge that will explain many cases with marked nerve-territory overgrowth.

<https://thejns.org/doi/abs/10.3171/CASE22463>

KEYWORDS fibrolipomatous hamartoma; lipomatosis of the nerve; lipofibromatous hamartoma; macrodactyly; macrodystrophia lipomatosa; overgrowth

Macrodystrophia lipomatosa (MDL) is a rare condition characterized by progressive overgrowth of soft tissues and/or bony structures. MDL has been associated with lipomatosis of the nerve (LN) with distal nerve-territory overgrowth^{1,2} and is part of *PIK3CA* related overgrowth spectrum (PROS) disorders; however, it lacks other associated abnormalities such as vascular malformations or developmental delay that can be seen in other syndromes associated with overgrowth such as Klippel-Trenaunay or CLOVES (congenital lipomatous overgrowth, vascular malformations, epidermal nevis, spinal/skeletal anomalies/scoliosis).^{3,4} The term MDL is usually reserved for cases with significant overgrowth (including soft tissue overgrowth such as lipomas and lipomatous infiltration of skeletal muscles and overgrowth of the affected bony structures), often affecting the entire limb, typically in combination with distal

overgrowth such as 1 or more digits referred to as macrodactyly. Nerve-territory overgrowth has been reported in 62% of cases of LN.² *PIK3CA* has become associated with MDL/LN cases in recent years; in contrast, intraneural or (isolated) extraneural lipomas are not associated with overgrowth or this genetic mutation.^{3,5} There are, however, no definite criteria for a definition of MDL that would be widely used in the literature.^{1,5} Furthermore, there is also significant inconsistency in the literature with regard to LN cases. The term LN was established in 2002;⁶ however, it is still reported under various names, such as fibrolipomatous hamartoma, lipofibromatous hamartoma, fibrolipoma, lipofibroma, as well as MDL.^{5,7-12} Some authors also suggest that MDL is a separate entity from LN.¹³ There are anecdotal cases of idiopathic overgrowth syndromes that were retrospectively found to have associated LN.¹⁴

ABBREVIATIONS LN = lipomatosis of the nerve; MDL = macrodystrophia lipomatosa; MRI = magnetic resonance imaging; NF1 = neurofibromatosis type 1; PROS = *PIK3CA*-related overgrowth spectrum.

INCLUDE WHEN CITING Published January 9, 2023; DOI: 10.3171/CASE22463.

SUBMITTED October 26, 2022. **ACCEPTED** November 29, 2022.

© 2023 The authors, CC BY-NC-ND 4.0 (<http://creativecommons.org/licenses/by-nc-nd/4.0/>).

We present a case of progressive lipomatous overgrowth (MDL) in a child who was misdiagnosed with neurofibromatosis type 1 (NF1) and who was found to have radiological evidence of occult LN of the lumbosacral plexus/proximal sciatic nerve and a *PIK3CA* mutation explaining the nerve-territory overgrowth. We believe that other patients with MDL or with idiopathic overgrowth syndromes have unrecognized LN.

Illustrative Case

A 2-year-old boy presented to our institution with progressive soft tissue overgrowth involving his right hip and thigh that was first noticed when he was approximately 8 months old. His prenatal and immediate postnatal history and family history were unremarkable. He was examined at an outside institution. Testing included several imaging studies including ultrasound of the abdomen and pelvis and magnetic resonance imaging (MRI) of the right thigh. He was also found to have several café-au-lait spots. Based on all his initial workup, a clinical diagnosis of presumed NF1 was suggested.

The patient was subsequently referred to the Mayo Clinic to be examined by our multidisciplinary team, which included a neurosurgeon, a neurologist, a plastic surgeon, an orthopedist, and a clinical geneticist. His physical examination was notable for overgrowth of his proximal right lower extremity (Fig. 1) and several café-au-lait spots without other cutaneous stigmata of NF1. Neurological evaluation was notable for decreased interest in daily activities; however, no neurological deficits were found. A differential diagnosis of *PTEN* hamartoma tumor syndrome was also suggested. Genetic testing of a blood sample for NF1 as well mutations in the *PTEN* gene was negative. Repeat MRI was performed, which revealed lipomatous overgrowth of the soft tissues of the right gluteal region, anterior, lateral, and posterior thigh, as well as fatty infiltration of the gluteal musculature and the tensor fasciae latae. There was a lipoma between the vastus lateralis of the quadriceps and its fascia, causing mass effect on the muscle. This lipoma was found to be contiguous with the lipomatous lesion centered within the gluteal region. The muscle itself was otherwise radiographically unremarkable (i.e., no overgrowth, lipomatous infiltration, or denervation changes). The patient also had a dumbbell-shaped lipoma extending from the

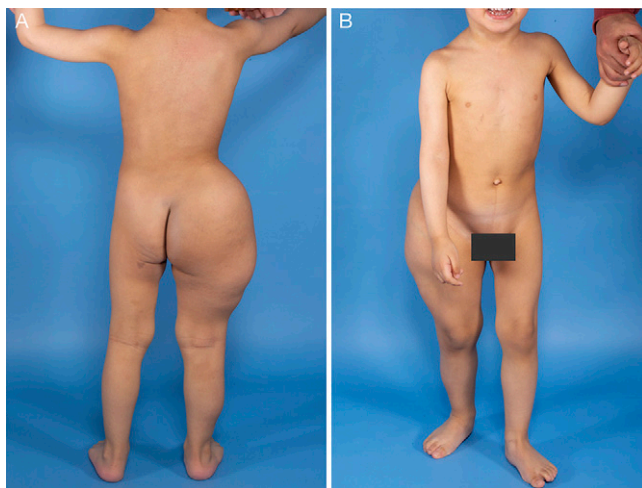

FIG. 1. Clinical images, posterior (A) and anterior (B) views, showing overgrowth of the proximal right lower extremity, most pronounced in the posterior and lateral aspects.

thigh proximally into the pelvis and compressing the sciatic nerve. The distal extent of the soft tissue overgrowth was approximately to the midcalf; however, only subcutaneous soft tissue was affected without any muscle involvement. Also identified was LN involving the right S1 and S2 spinal nerves up to the neural foramen and the proximal sciatic nerve to just distally the sciatic notch (Figs. 2 and 3). No definite bony overgrowth was identified.

Two debulking/liposuction procedures of the right proximal extremity were performed 3 months apart, with approximately 500 mL of aspirate being obtained during each liposuction of the right gluteal region and thigh for a total of 1000 mL. Genetic testing of the liposuction aspirate revealed a mutation in *PIK3CA* (additional genes that were tested included *ABL1*, *AKT1*, *ALK*, *APC*, *ATM*, *BRAF*, *CDH1*, *CDKN2A*, *CSF1R*, *CTNNA1*, *EGFR*, *ERBB2*, *ERBB4*, *EZH2*, *FBXW7*, *FGFR1*, *FGFR2*, *FGFR3*, *FLT3*, *GNA11*, *GNAQ*, *GNAS*, *HNF1A*, *HRAS*, *IDH1*, *IDH2*, *JAK2*, *JAK3*, *KDR*, *KIT*, *KRAS*, *MET*, *MLH1*, *MPL*, *NOTCH1*, *NPM1*, *NRAS*, *PDGFRA*, *PTPN11*, *RB1*, *RET*, *SMAD4*, *SMARCB1*, *SMO*, *SRC*, *STK11*, *TP53*, and *VHL*, which were all negative). The patient's postoperative course was uneventful, and he was doing well on his last follow-up visit 6 weeks after the last procedure before traveling home.

Discussion

Observations

We believe that MDL represents an extreme form of LN with distal nerve-territory overgrowth. As such, MDL fits into the spectrum of adipose lesions of nerve, which includes LN as well as intraneural lipoma (in its pure encapsulated form, that is distinct from LN, although sometimes incorrectly named) and extraneural lipoma. MRI is not only pathognomonic for diagnosing adipose lesions of nerve but distinguishing them from one another: LN typically has a so-called spaghetti-like appearance in the longitudinal plane or coaxial cable-like appearance in the axial plane; intraneural lipoma is a well-encapsulated fatty mass within the epineurium of nerve; and an extraneural lipoma is a well-encapsulated fatty mass that is extrinsic to nerve (although it can, on occasion, cause compression).^{11,15} No definitive treatment exists; however, treatment strategies can include observation only or various surgical procedures to improve function and/or cosmesis such as nerve decompression or debulking. In many cases, multiple surgeries are performed for recurring

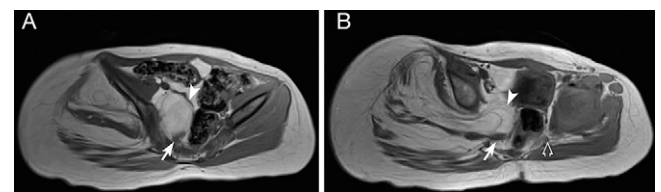


FIG. 2. LN of the right sciatic nerve and associated nerve-territory overgrowth. (A) Axial T1-weighted MR image of the pelvis showing an enlarged right sciatic nerve (arrow) and associated distal nerve-territory overgrowth and lipomatosis of the right gluteal region. Although a subtle finding, extra fat can be appreciated between the enlarged nerve fascicles. Also visible is the proximal end of the dumbbell-shaped lipoma protruding into the pelvis and compressing and displacing the sciatic nerve (arrowhead). (B) Axial T1-weighted MR image of the pelvis just inferiorly to panel A again showing the enlarged right sciatic nerve (arrow). The normal-sized sciatic nerve can be seen on the left (hollow arrowhead) for comparison. The dumbbell-shaped lipoma (arrowhead) as well as the soft tissue overgrowth of the right gluteal region can be seen.

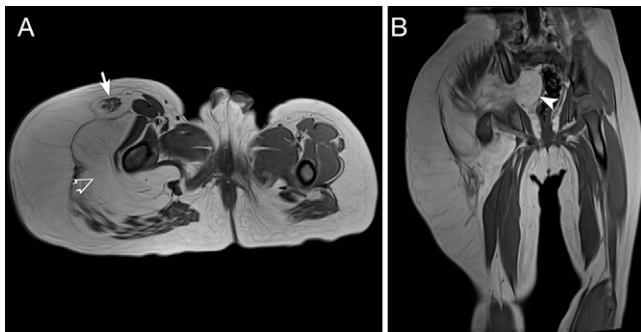


FIG. 3. (A) Axial T1-weighted MR image of the bilateral proximal thighs showing the soft tissue overgrowth of the right proximal thigh. This includes the lipoma that is centered within the right gluteal region and extends into the plane between the vastus lateralis and its fascia (*hollow arrowhead*). The amount of overgrowth involving the tensor fasciae latae (*arrow*) and the subcutaneous tissues of the lateral proximal thigh can be appreciated as well, especially when compared with the contralateral side. **(B)** Coronal T1-weighted MR image of the pelvis and bilateral proximal lower extremities where the soft tissue overgrowth of the right gluteal region and proximal thigh can be again appreciated on a different plane. The dumbbell-shaped lipoma protruding into the pelvis is again appreciated (*arrowhead*).

overgrowth.¹⁶ Several drugs are also under active investigation for PROS disorders.¹⁷ As summarized in our recent review of the world's literature (and updated for this review), we have identified 153 cases of MDL (i.e., reported using this term): 79 cases with documented LN and 74 cases that do not comment on nerve abnormality.^{1,2,13,18–33} Overgrowth was most commonly reported with LN of the median nerve at the wrist, followed by plantar nerves. The cases that did not comment on nerve involvement, however, lacked of the site of the suspected lesion, yet alone imaging proximally to the lesion. Thus, nerve involvement was not fully investigated^{2,19,21,23,26–29,31} and therefore nerve involvement could have been present. It has been shown that LN can demonstrate so-called skip lesions, can be subtle enough that it is missed on MRI examinations, or can involve multiple nerves and be bilateral (e.g., bilateral median nerve involvement), although the majority of LN cases reported in the world's literature affect only 1 nerve territory.^{2,5,34,35} Some state that the vast majority of cases are within the nerve territory, and only a few are so-called diffuse or without any definite LN identified.³⁰ Others who suggest that the overgrowth might not be restricted to only the affected nerve by LN did not image appropriately (i.e., to include proximal nerves).³³ Although difficult to prove retrospectively on outside cases, we hypothesize that LN occurring proximally is responsible for the dramatic nerve-territory overgrowth in a fair proportion of these cases. The inconsistency in terminology that is used in the literature when reporting adipose lesions of the nerve (especially LN and MDL) helps fuel confusion among authors and is one of the major obstacles in researching these cases.

Our patient could therefore be understood as having an extreme form of LN with significant progressive distal nerve-territory overgrowth (i.e., MDL), and we advocate for using the term LN with distal nerve-territory overgrowth over MDL. Overgrowth in our case included a large dumbbell-shaped extraneural lipoma in the sciatic notch compressing the sciatic nerve. The nerve-territory overgrowth was manifested by enlargement and fatty infiltration of the gluteal

musculature, overgrowth of the subcutaneous soft tissues of the right thigh (most pronounced posterolaterally), and extending to midcalf, and fatty infiltration of the tensor fasciae latae. The lipomatous mass was centered within the gluteal musculature and its spread lateral to the vastus lateralis could be explained by the path of least resistance, known to occur in other tumors.³⁶ All these findings can be explained by the concept of distal nerve-territory overgrowth,⁵ as the LN extended from the S1 and S2 nerves into the lumbosacral plexus and proximal sciatic nerve. The relatively short segment of LN was easily missed due to the focus on the large tumor and the nerve's displacement; however, the nerve itself was significantly enlarged when compared with the contralateral side, which can be another clue when establishing the final diagnosis. The LN was only identified on specific reinterpretation of the MR images, given the existing diagnosis of MDL and the *PIK3CA* mutation. This case was reminiscent of one of our recent cases of unrecognized LN of a femoral nerve that was diagnosed with "idiopathic overgrowth syndrome" for many years.¹⁴ The proximal spinal nerve involvement without intradural extension was concordant with findings of our other recent case of LN of the brachial plexus with distal nerve-territory overgrowth, which, at autopsy, showed *PIK3CA* mutations.^{37,38} Our patient reported herein was misdiagnosed as having NF1 based on the café-au-lait spots and the misinterpretation of the lipoma as a neurofibroma on MRI. Other overgrowth syndromes such as *PTEN* hamartoma tumor syndrome were considered and dismissed.

Lessons

We believe that so-called MDL is part of the spectrum of LN, with markedly pronounced associated distal nerve-territory overgrowth. Cases that report MDL as a separate entity (i.e., without the identification of LN) frequently do not comment on the nerves and/or image the entire nerve pathway of the affected body part. Our case illustrates that misdiagnosis can also occur due to not recognizing the presence of subtle LN, even when the proximal nerves are included on MRI. Although not all idiopathic cases of distal overgrowth are LN with nerve-territory overgrowth, LN could be the underlying cause more frequently than previously thought. The fact that many different terms are used in the literature when reporting cases of LN with or without nerve-territory overgrowth (including MDL) causes significant confusion and creates obstacles in researching this peculiar pathologic entity.

References

1. Syed A, Das S, Abdul-Rashid AH, Wan-Ahmad-Kamal W, Jamil K. Toe macrodactyly, macrodystrophia lipomatosa, fibrolipomatous hamartoma and lipomatosis of nerve. Are they similar? A case report. *Malays Orthop J.* 2022;16(2):136–139.
2. Marek T, Spinner RJ, Syal A, Mahan MA. Strengthening the association of lipomatosis of nerve and nerve-territory overgrowth: a systematic review. *J Neurosurg.* 2019;132(4):1286–1294.
3. Blackburn PR, Milosevic D, Marek T, et al. *PIK3CA* mutations in lipomatosis of nerve with or without nerve territory overgrowth. *Mod Pathol.* 2020;33(3):420–430.
4. Keppler-Noreuil KM, Rios JJ, Parker VE, et al. *PIK3CA*-related overgrowth spectrum (PROS): diagnostic and testing eligibility criteria, differential diagnosis, and evaluation. *Am J Med Genet A.* 2015;167A(2):287–295.
5. Marek T, Mahan MA, Carter JM, et al. What's known and what's new in adipose lesions of peripheral nerves? *Acta Neurochir (Wien).* 2021;163(3):835–842.

6. Fletcher CD, Unni KK, Mertens F, eds. *Pathology and Genetics of Tumours of Soft Tissue and Bone* (Vol. 4). IARC; 2002.
7. Johnson RJ, Bonfiglio M. Lipofibromatous hamartoma of the median nerve. *J Bone Joint Surg Am*. 1969;51(5):984–990.
8. Silverman TA, Enzinger FM. Fibrolipomatous hamartoma of nerve. A clinicopathologic analysis of 26 cases. *Am J Surg Pathol*. 1985;9(1):7–14.
9. Donley BG, Neel M, Mitias HM. Neural fibrolipoma of the foot: a case report. *Foot Ankle Int*. 1996;17(11):712–713.
10. Yamauchi T, Yoshii T, Sempuku T. Whether to excise a lipofibroma of the median nerve. *Scand J Plast Reconstr Surg Hand Surg*. 2009;43(6):346–349.
11. Marek T, Amrami KK, Mahan MA, Spinner RJ. Intraneural lipomas: institutional and literature review. *Acta Neurochir (Wien)*. 2018;160(11):2209–2218.
12. Feriz H. Makrodystrophia lipomatosa progressiva. *Virchows Arch Pathol Anat Physiol Klin Med*. 1926;260(2):308–368.
13. Sumarwoto T, Hadinoto SA, Idulhaq M, Santoso A, Abimanyu DR. Surgical management of macrodystrophia lipomatosa, a rare case report of the left hand middle finger macrodactyly. *Int J Surg Case Rep*. 2021;85:106181.
14. Marek T, Howe BM, Amrami KK, Taunton MJ, Spinner RJ. Unrecognized lipomatosis of the femoral nerve and nerve-territory overgrowth. *Clin Anat*. 2018;31(8):1210–1214.
15. Marom EM, Helms CA. Fibrolipomatous hamartoma: pathognomonic on MR imaging. *Skeletal Radiol*. 1999;28(5):260–264.
16. Marek T, Spinner RJ, Syal A, Wahood W, Mahan MA. Surgical treatment of lipomatosis of nerve: a systematic review. *World Neurosurg*. 2019;128:587–592.e2.
17. Canaud G, Hammill AM, Adams D, Vikkula M, Keppler-Noreuil KM. A review of mechanisms of disease across PIK3CA-related disorders with vascular manifestations. *Orphanet J Rare Dis*. 2021;16(1):306.
18. Baba K, Kashiwagi S, Nemoto M, Takeda A, Fukumoto K, Uchinuma E. A patient with macrodystrophia lipomatosa bilaterally affecting the entire upper extremity: reporting of a rare case and literature review. *Case Reports Plast Surg Hand Surg*. 2021;8(1):1–7.
19. Biswas DN, Dhali A, Parvin S, Singh A, Dhali GK. Macrodystrophia lipomatosa: a rare cause of bilateral lower limb gigantism. *Cureus*. 2021;13(10):e18986.
20. Cotter C, Elias D, Pruneddu S. Macrodystrophia lipomatosa of the left hallux. *Clin Exp Dermatol*. 2021;46(5):974–976.
21. Galea Wismayer M, Sant K, Giordmaina R, McNally M. Osteomyelitis in heterotopic ossification in a patient with congenital gigantism of the leg. *J Bone Jt Infect*. 2021;6(5):141–145.
22. Gunasekaran K, Sundareswaran N, Gopinath G. A child with enlarged extremities—a case of macrodystrophia lipomatosa. *Indian J Dermatol*. 2020;65(5):409–413.
23. Ilyas M, Ahmad Z, Choh N. Macrodystrophia lipomatosa: a rare form of localized gigantism. *Natl Med J India*. 2020;33(4):250.
24. Jacobs CJ, Vreeburg M, de Die-Smulders CEM, Staal HM, Lauwers T. Surgical management for isolated macrodactyly in an adult PIK3CA mutant. *JPRAS Open*. 2020;26:86–90.
25. Jakkepally S, Viswanathan VK, Shetty AP, Pushpa BT, Kanna RM, Rajasekaran S. Macrodystrophia lipomatosa of thoracic spine causing progressive neurodeficit: a case report and review of literature. *JBJS Case Connect*. 2021;11(2).
26. Kavecian I, Obrenovic M, Privrodski B, Kavecian DE, Golusin Z. Unilateral type of macrodystrophia lipomatosa of the thumb, index finger, and thenar. *Balkan Med J*. 2019;36(1):60–61.
27. Malla S, Razik A, Das CJ. Macrodystrophia lipomatosa of the foot. *BMJ Case Rep*. 2019;12(5):e229464.
28. Oh SJ. Macrodystrophia lipomatosa of bilateral hands and the left upper limb with syndactyly. *Arch Plast Surg*. 2019;46(4):392–393.
29. Paul BJ, Raveendran AV. An adolescent with progressive enlargement of digits: case report and proposed diagnostic criteria for macrodystrophia lipomatosa. *Sultan Qaboos Univ Med J*. 2018;18(4):e553–e556.
30. Prabhu CS, Madhavi K, Amogh VN, Panwala HK, Sathyakumar K. Macrodystrophia lipomatosa: a single large radiological study of a rare entity. *J Clin Imaging Sci*. 2019;9:4.
31. Silvério-António M, Romão VC, Polido-Pereira J. Late presentation of macrodystrophia lipomatosa—a rare, impressive diagnosis. *Rheumatology (Oxford)*. 2021;61(1):469–470.
32. Southard EJ, Sands AK, Boyajian DA, Siczka E, Bryk E, Vigorita VJ. Macrodystrophia lipomatosa of the foot: a case report of MRI and histologic findings including Pacinian corpuscle abnormalities. *JBJS Case Connect*. 2021;11(2).
33. Yadav T, Mirza G, Khera PS, Garg P. Macrodystrophia lipomatosa with fibrolipomatous hamartoma of medial plantar nerve and lipomatosis of thigh. *Sudan J Paediatr*. 2020;20(1):62–67.
34. Wehrli L, Saheb-Al-Zamani M, Khanna M, Lax MJ, Anastakis DJ. Lipomatosis of nerve: more than a focal distal disease. *Plast Reconstr Surg*. 2018;142(1):148–151.
35. Marek T, Amrami KK, Spinner RJ, Mahan MA. Bilateral nerve involvement in lipomatosis of nerve. *J Surg Orthop Adv*. 2021;30(1):44–49.
36. Robinson E, Bleakney RR, Ferguson PC, O'Sullivan B. Oncodiagnosis panel: 2007: multidisciplinary management of soft-tissue sarcoma. *Radiographics*. 2008;28(7):2069–2086.
37. Marek T, Mahan MA, Carter JM, Amrami KK, Atkinson JLD, Spinner RJ. Can lipomatosis of the nerve occur or extend intradurally? *World Neurosurg*. 2019;129:e555–e560.
38. Ebner BA, Eschbacher KL, Jack MM, Dragana M, Spinner RJ, Giannini C. Brachial plexus lipomatosis with perineurial pseudoonion bulb formation: result of a mosaic PIK3CA mutation in the para-axial mesoderm state. *Brain Pathol*. 2022;32(4):e13057.

Disclosures

The authors report no conflict of interest concerning the materials or methods used in this study or the findings specified in this paper.

Author Contributions

Conception and design: Amrami, Spinner. Acquisition of data: all authors. Analysis and interpretation of data: all authors. Drafting of the article: all authors. Critically revising the article: Marek, Spinner. Reviewed submitted version of the manuscript: Marek, Spinner. Approved the final version of the manuscript on behalf of all authors: Marek. Administrative/technical/material support: Spinner. Study supervision: Amrami, Spinner.

Correspondence

Tomas Marek: Mayo Clinic, Rochester, MN. marek.tomas@mayo.edu.