



RESEARCH

Open Access

Accuracy of electronic apex locators to detect root canal perforations with inserted metallic posts: an ex vivo study

Benjamín Briseño Marroquín^{1,5*}, Claudia Cortazar Fernández³, Irene Schmidtman⁴, Brita Willershausen¹ and Fernando Goldberg²

Abstract

Introduction: The detection of possible root canal perforations caused during a metal post placement is frequently difficult to diagnose. The aim of this study was to investigate the accuracy of apex locators to diagnose such perforations.

Materials and methods: Thirty mesiolingual root canals of extracted mandibular molars were instrumented (30/.04) and a post space was prepared. A root canal perforation was intentionally made at the bi-furcation ($n = 15$). Metal posts were cemented in 15 perforated and 15 non-perforated root canals. The teeth roots were embedded in an agar-agar solution. The resulting measurements ("short" or "beyond" the apex) disclosed if a perforation could be identified with five different apex locators (ProPex II, Elements Apex Locator, Apex NRG, Raypex 5 and Raypex 6). The sensitivity and specificity (95% interval confidence) were calculated.

Results: All devices excluded the absence of perforations (100% with 95% confidence interval [78%; 100%] specificity). The Apex NRG and Raypex 6 detected all perforations (100% with 95% confidence interval [78%; 100%] sensitivity). The ProPex II, Elements Apex Locator, and Raypex 5 detected 14 out of 15 perforations (93% with 95% confidence interval [68%; 100%] sensitivity).

Conclusions: All devices determined root canal perforations, due to metallic posts, within clinical acceptable ranges.

Keywords: Root perforation, Metal post, Diagnosis, Apex locators

Introduction

Despite technological advancements in endodontic techniques, endodontic mishaps such as root perforations during access preparation, root canal instrumentation, or preparation for post space are not unusual [1,2]. Root perforations compromise the success of endodontic therapy and have been regarded as, and probably are still, one of the most unpleasant accidents to deal with during re-treatment [3,4]. Occasionally, a clinician will be challenged with the fact that a radiological diagnose of patient with non-acute clinical symptomatology shows that

the tooth has been previously endodontically treated, a post has been placed and the crown restored without evidence of a root perforation caused during the post insertion. A root perforation is defined as an artificial opening in the tooth crown or root area creating a communication between the root canal system with the periodontal tissues or oral cavity [5]. Iatrogenic root perforations are frequently caused by inappropriate post space preparation and have been classified as one of the most common types of root perforations [6] occurring approximately between 2 to 12% of the endodontically treated teeth [2,7]. The time elapsed between perforation and treatment [3,8,9], perforation size and location [10,11] play an important role when treating the affected site [3]. The treatment possibilities [4,5,11] as well as the post-treatment outcome of a root perforation [12] are

* Correspondence: briseno@uni-mainz.de

¹Department of Operative Dentistry, Johannes Gutenberg University Medical Center, Mainz, Germany

⁵Poliklinik für Zahnerhaltung, Langenbeckstr. 1, Mainz 55131, Germany

Full list of author information is available at the end of the article

decisive for their prognosis. Strömberg et al. [4] examined teeth that had been treated with different treatment modalities, such as a root-end resection, root amputation or hemisection and suggested a root perforation classification depending on the perforation location. In practice however, the indications for surgical correction of root perforations are being reduced by the improved non-surgical management of perforations with mineral trioxide aggregate type cements [13-15] and by the use of implants.

Root perforations, especially in the buccolingual aspect of the root are difficult to diagnose radiographically [16,17]. Since Sunada [18] introduced an electronic device to locate the apical foramen various reports [16,17,19] advocate the use of an apex locator as a tool to detect root perforations. Different authors [19-21] have suggested the employment of an apex locator to detect a root perforation when a metal post is placed. If effective, this precaution would allow the clinician to plan the endodontic re-treatment; thus, tooth disassembling prior to being astounded by the circumstances and having to immediately implement adequate treatment precautions. Thus, the aim of this study was to investigate with an ex-vivo model the accuracy of different electronic apex locators when diagnosing root perforations due to placement of metal posts.

Materials and methods

An access cavity was prepared on 30 freshly extracted human first and second mandibular molars. Teeth with wide open apices or incomplete root development, root fracture or previous root canal treatments were excluded. Only mesiolingual root canals with an independent entrance at the pulp chamber floor and corresponding foramen were prepared to an instrument size 30/.04 (ProFile;

Denstply Maillefer/Ballaigues, Switzerland). The actual working length of the mesiolingual root canals was determined when the tip of a K-type file size 10 (VDW/Munich, Germany) could microscopically (20x; Leica MZ6/Leica Microsystems, Wetzlar, Germany) be observed as it reached the physiological foramen [22]. The straight segment of the mesiolingual root canals was then prepared to receive a metallic post (Cytco-K/L50A; Maillefer Denstply/Ballaigues, Switzerland) with a Cytco-K drill (C 170 K 0 L50; Maillefer Denstply/Ballaigues, Switzerland). The teeth were then divided at random into two groups of 15 each. In one group a metallic post was conventionally cemented (Ketac Cem; 3 M Espe/Seefeld, Germany). In the other group a perforation in the bi-furcation area at the border between the coronal and middle thirds was intentionally made with a LN Bur #6 (ØISO 012; Maillefer Denstply/Ballaigues, Switzerland). The metallic posts were cemented with Ketac Cem (3 M ESPE/Seefeld, Germany) in the perforated root canals in such a way that the post tip segment was inserted beyond the perforation borders, thus allowing a contact with the periradicular tissue simulating media (Figure 1).

The teeth were fixed with wax in plastic tubes leaving the complete root length inserted in an solidified (20 min) agar-agar solution, which had a constant pH of 7.3 and simulated the periradicular tissue [19,23]. A lateral orifice in the plastic tubes allowed the placement of the negative rod of the electronic apex locators (Figure 1). The electronic measurements to diagnose the perforations were made by establishing a contact between the metal post and the EAL electrode by one operator in a blind manner (n = 30). It was expected that the measurements of the mesiolingual root canals with the metal posts indicated a "short measurement" when no perforation was present

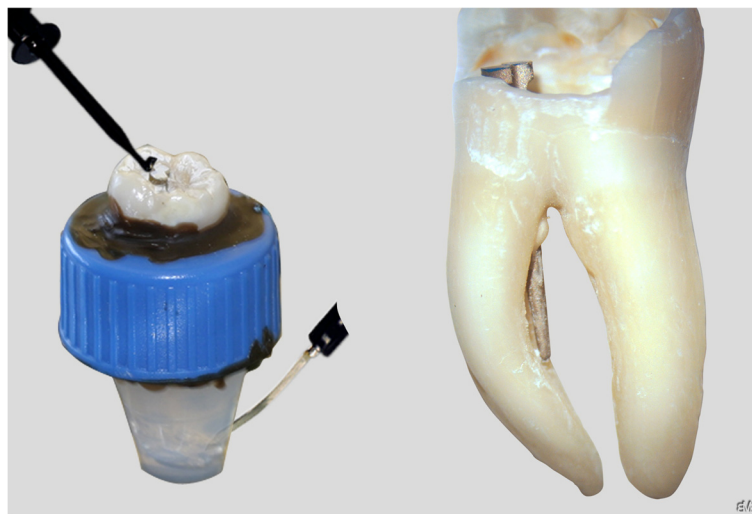


Figure 1 Fixation device showing the root tooth placed in a plastic tube in an agar-agar solution and with both apex locator electrodes (left) and a maxillary molar with a perforated root canal through a metal post (right).

(n = 15) and a “beyond the apex” measurement when a perforation was existent (n = 15). The measurements were made with the Elements Apex Locator (SybronEndo/ Orange CA, USA), ProPex II (Densply Maillefer/Ballaigues, Switzerland), Apex NRG (Medic Energy, Tel Aviv, Israel) and Raypex 5 and Raypex 6 (VDW, Munich, Germany). The readings “short” or “beyond” the apex were made according to the respective display of the different EAL’s. All perforation diagnose measurements were made with each EAL at once. The sensitivity and specificity with respect to the gold standard and exact 95% confidence intervals for sensitivity and specificity were determined. Kappa statistics were computed to assess inter-device agreement when evaluating the presence or absence of root perforations between the different devices (SAS 9.3/2002–2010 SAS Institute Inc., Cary, NC, USA [25] and Multirater Kappa/SAS-Macro (Chen et al. 2005).

Results

In all 15 mesiolingual root canals in which the metal post was within the root canal limits, all electronic devices showed a “short measurement”; thus, accurately excluding perforations when they were not present (100% specificity; 95% confidence interval [78%; 100%]). In the other group in which the post was placed beyond the perforation the Apex-NRG and Raypex 5 were able to detect all perforations (100% sensitivity; 95% confidence interval [78%; 100%]). The ProPex II, Elements Apex Locator and Raypex 6 showed 14 measurements “beyond the apex” and one “short measurement”; thus diagnosing 14 of 15 perforations and resulting in a 93% sensitivity (95% confidence interval [68%; 100%]) (Table 1). The calculated inter-device (Table 2) agreements showed to be high.

Discussion

Root canal perforations are most of the time procedural errors and represent a serious treatment complication [3,4] that compromises the health of the periradicular tissues and adversely influences the retention of the

Table 1 All methods excluded perforations when they were not present (100% specificity; 95% confidence interval [78%; 100%])

Device	Sensitivity with 95% confidence interval	Specificity with 95% confidence interval
ProPex II	93% [68%;100%]	100% [78%; 100%]
Elements Apex Locator	93% [68%;100%]	100% [78%; 100%]
Apex NRG	100% [78%; 100%]	100% [78%; 100%]
RayPex 5	100% [78%; 100%]	100% [78%; 100%]
RayPex 6	93% [68%;100%]	100% [78%; 100%]

The Apex NRG and RayPex 5 also detected all perforations (100% sensitivity; 95% confidence interval [78%; 100%]). The ProPex II, Elements Apex Locator, and RayPex 6 detected 14 of 15 perforations (93% sensitivity; 95% confidence interval [68%;100%]).

Table 2 Results of the inter-device agreement which proved to be high

Device 1	Device 2	κ with 95% confidence interval where possible
Pro Pex II	Elements Apex Locator	0.86 [0.69; 1.00]
Pro Pex II	Apex NRG	0.93 [0.81; 1.00]
Pro Pex II	RayPex 5	0.93 [0.81; 1.00]
Pro Pex II	RayPex 6	0.86 [0.69; 1.00]
Elements Apex Locator	Apex NRG	0.93 [0.81; 1.00]
Elements Apex Locator	RayPex 5	0.93 [0.81; 1.00]
Elements Apex Locator	RayPex 6	0.86 [0.69; 1.00]
Apex NRG	RayPex 5	1.00
Apex NRG	RayPex 6	0.93 [0.81; 1.00]
RayPex 5	Raypex 6	0.93 [0.81; 1.00]

tooth [3,26,27]. The detection of root perforations by means of an electronic apex locator has been in vitro [16,17] and in vivo [19] investigated. Even though the devices investigated by these researchers are from older generations, they are all in agreement, that root perforations can be confidentially diagnosed by means of an apex locator. Mesial root canals of mandibular molars were chosen for sake of research parameters standardization and since often the entrance morphology of distal root canal is quite oval; thus, making it difficult to accurately prepare the space for a prefabricated metal post. A limitation of this in vitro investigation method could be that it would be burdensome to extrapolate the results to different clinical conditions with the one investigated. However, the use an in vitro research method allows the possibility to investigate a relative high number of samples under the same parameters and reproducible conditions; thus, enabling a reliable statistical analysis. The employment of an agar-agar solution as embedding media was chosen since the methodology used in this investigation is an established and frequently employed one [23,28-31]. Different authors report that the use of alginate as embedding media showed a higher accuracy tendency [32] or a statistical significant higher accuracy [33] when compared with other embedding media such as agar-agar. However, in this last report the accuracy was not only embedding media but also apex locator dependent. Thus, the probability that using a different embedding media, such as alginate, could lead to different results is given and should be investigated.

In recent years non-surgical treatment [34,35] of root perforations has been facilitated by the use of magnification and illumination. Yet, the clinical and radiological diagnosis of root perforations is inherently complex [16,17].

Unfortunately, there is a lack of evidence-based research concerning the diagnosis of root perforations, in which a metal post has been placed, upon which treatment decisions can be based. Chong and Pitt Ford [20] suggested the use of an electronic apex locator as an aide to determine perforations in such clinical cases. It is possible that this method is widely used in clinical practice, yet, to the best of our knowledge, there are no scientific reports concerning such reliability. Different authors [16,17,19] have suggested the possibility to diagnose root perforations with apex locators. However, due to the different clinical conditions and the intrinsic limitations of clinical case reports, they can only be compared to a certain extent with the results of this investigation. Although the sensitivities obtained in this investigation were high, some EALs they did not reach 100%. The false measurements with the different apex locators were made in different teeth. A research methodological error can be excluded since the Raypex 6 and Apex NRG reached 100% sensitivity. Thus, it becomes a difficult task to point out a logical explanation for this situation. However, the sensitivity and specificity shown in the results suggest that any of the devices investigated are clinically reliable to diagnose these type of perforations.

A self-evident limitation of this method is that apex locators will not be able to detect a perforation when a fiber glass or a similar post has been inserted. Furthermore, the operator should be aware of the possibility that the luting cement could completely isolate the post from the periradicular tissues; thus, such clinical situation could compromise an accurate perforation diagnosis. Although the root perforations in this investigation had a specific location, we are of the opinion that the detection of root perforations in which a metal post has been placed, either in the apical, middle or coronal root third could be as well diagnosed by means of apex locators. The method is simple; nonetheless, the removal of restoration materials surrounding the coronal part of the metal post, which could act as an isolating material, should be meticulously undertaken in order to be able to establish a stable contact between the apex locator electrode and metal post. The early detection during endodontic re-treatment of a root canal perforation caused by metal post would improve the clinical decision-making for both operator and patient.

Conclusions

Under the conditions and with the electronic devices employed in this study we were able to determine a non-existent root canal perforation in all cases (100% specificity; -/-). The ProPex II, Elements Apex Locator and Raypex 6 had a 93% and the Apex NRG and Raypex 5 a 100% sensitivity (+/+). The high specificity and sensitivity and inter-device agreements obtained when diagnosing root perforations with a metal post placed in this

investigation allow to recommend the use of an apex locator when diagnosing root perforations caused during the placement of a metal post.

Competing interests

We also assure that all authors of this manuscript have any potential competing interests in the last five years. This manuscript was founded by the institutional organizations of the authors and that the Department of Operative Dentistry of Mainz will finance this manuscript in case of acceptance.

The authors do not hold shares or stocks or are applying for a patency in any organization that could profit from this manuscript.

The authors deny any non-financial competing interest of any kind in relation to this manuscript.

Authors' contributions

BBM and FG conceived of the study, and participated in its design and coordination. CCF carried out the specimens tests. BW participated in the design of the study and performed the statistical analysis. All authors read and approved the final manuscript.

Acknowledgment

We would like to express our appreciation to Dr. Hans-Willi Herrmann from Bad-Kreuznach, Germany, for giving us a valuable recommendation for this paper during a professional discussion.

Author details

¹Department of Operative Dentistry, Johannes Gutenberg University Medical Center, Mainz, Germany. ²Department of Endodontics, School of Dentistry, USAL-AOA, Buenos Aires, Argentina. ³Universidad Autónoma de Nuevo León, Monterrey, Nuevo León, Mexico. ⁴Institute of Medical Biometrics, Epidemiology and Informatics, Johannes Gutenberg University Medical Center, Mainz, Germany. ⁵Poliklinik für Zahnerhaltung, Langenbeckstr. 1, Mainz 55131, Germany.

Received: 23 October 2014 Accepted: 12 December 2014

Published online: 23 December 2014

References

- Abbott PV: Analysis of a referral-based endodontic practice: part 2. Treatment provided. *J Endod* 1994, **20**:253–257.
- Farzaneh M, Abitbol S, Friedman S: Treatment outcome in endodontics: the Toronto study. Phases I and II: orthograde retreatment. *J Endod* 2004, **30**:627–633.
- Seltzer S, Sinai I, August D: Periodontal effects of root perforations before and during endodontic procedures. *J Dent Res* 1970, **49**:332–339.
- Strömberg T, Hasselgren G, Bergstedt H: Endodontic treatment of traumatic root perforations in man. A clinical and roentgenological follow-up study. *Sven Tandlak Tidsskr* 1972, **65**:457–466.
- Jew RC, Weine FS, Keene JJ, Smulson MH: A histologic evaluation of periodontal tissues adjacent to root perforations filled with Cavit. *Oral Surg Oral Med Oral Pathol* 1982, **54**:124–135.
- Kvinnslund I, Oswald RJ, Halse A, Grønningaeter AG: A clinical and roentgenological study of 55 cases of root perforation. *Int Endod J* 1989, **22**:75–84.
- Kerekes K, Tronstad L: Long-term results of endodontic treatment performed with a standardized technique. *J Endod* 1979, **5**:83–90.
- Beavers RA, Bergenholtz G, Cox CF: Periodontal wound healing following intentional root perforations in permanent teeth of Macaca mulatta. *Int Endod J* 1986, **19**:36–44.
- Bhaskar SN, Rappaport HM: Histologic evaluation of endodontic procedures in dogs. *Oral Surg Oral Med Oral Pathol* 1971, **31**:526–535.
- Balla R, LoMonaco CJ, Skribner J, Lin LM: Histological study of furcation perforations treated with tricalcium phosphate, hydroxylapatite, amalgam, and life. *J Endod* 1991, **17**:234–238.
- Himmel VT, Brady J, Weir J: Evaluation of repair of mechanical perforations of the pulp chamber floor using biodegradable tricalcium phosphate or calcium hydroxide. *J Endod* 1985, **11**:161–165.
- Juárez Broon N, Monteiro Bramante C, de Assis GF, Antunes Bortoluzzi E, Bernardineli N, Gomes de Moraes I, Brandão Garcia R: Healing of root

- perforations treated with mineral trioxide aggregate (MTA) and Portland cement. *J Appl Oral Sci* 2006, **14**:305–311.
13. Torabinejad M, Parirokh M: Mineral trioxide aggregate: a comprehensive literature review-Part II: leakage and biocompatibility investigations. *J Endod* 2010, **36**:190–202.
 14. Parirokh M, Torabinejad M: Mineral trioxide aggregate: a comprehensive literature review-Part III: clinical applications, drawbacks, and mechanism of action. *J Endod* 2010, **36**:400–413.
 15. da Silva GF, Guerreiro-Tanomaru JM, Sasso-Cerri E, Tanomaru-Filho M, Cerri PS: Histological and histomorphometrical evaluation of furcation perforations filled with MTA, CPM and ZOE. *Int Endod J* 2011, **44**:100–110.
 16. Fuss Z, Assoline LS, Kaufman AY: Determination of location of root perforations by electronic apex locators. *Oral Surg Oral Med Oral Pathol Oral Radiol Endod* 1996, **82**:324–329.
 17. Kaufman AY, Fuss Z, Keila S, Waxenberg S: Reliability of different electronic apex locators to detect root perforations in vitro. *Int Endod J* 1997, **30**:403–407.
 18. Sunada I: New method for measuring the length of the root canal. *J Dent Res* 1962, **41**:375–387.
 19. Nahmias Y, Aurelio JA, Gerstein H: Expanded use of the electronic canal length measuring devices. *J Endod* 1983, **9**:347–349.
 20. Chong BS, Pitt Ford TR: Apex locators in endodontics: which, when and how? *Dent Update* 1994, **21**:328–330.
 21. Kaufman AY, Keila S: Conservative treatment of root perforations using apex locator and thermatic compactor-case study of a new method. *J Endod* 1989, **15**:267–272.
 22. Briseño Marroquín B, El-Sayed MAA, Willershausen-Zönnchen B: Morphology of the physiological foramen: I. Maxillary and mandibular molars. *J Endod* 2004, **30**:321–328.
 23. Briseño Marroquín B, Fralich S, Goldberg F, Willershausen B: Influence of instrument size on the accuracy of different apex locators: an in vitro study. *J Endod* 2008, **34**:698–702.
 24. Fleiss JL, Levin B, Paik MC: *Statistical Methods for Rates and Proportions*. 3rd edition. Hoboken: John Wiley & Sons; 2003.
 25. Sinai IH: Endodontic perforations: their prognosis and treatment. *J Am Dent Assoc* 1977, **95**:90–95.
 26. Fuss Z, Trope M: Root perforations: classification and treatment choices based on prognostic factors. *Endod Dent Traumatol* 1996, **12**:255–264.
 27. Ebrahim AK, Yoshioka T, Kobayashi C, Suda H: The effects of file size, sodium hypochlorite and blood on the accuracy of Root ZX apex locator in enlarged root canals: an in vitro study. *Aust Dent J* 2006, **51**:153–157.
 28. Fouad AF, Rivera EM, Krell KV: Accuracy of the Endex with variations in canal irrigants and foramen size. *J Endod* 1993, **19**:63–67.
 29. Nahmias Y, Aurelio JA, Gerstein H: An in vitro model for evaluation of electronic root canal length measuring devices. *J Endod* 1987, **13**:209–214.
 30. Nekoofar MH, Sadeghi K, Sadighi Akha E, Akha ES, Namazikhah MS: The accuracy of the Neosono Ultima EZ apex locator using files of different alloys: an in vitro study. *J Calif Dent Assoc* 2002, **30**:681–684.
 31. Baldi JV, Victorino FR, Bernardes RA, G de Moraes I, M Bramante C, B Garcia R, Bernardineli N: Influence of embedding media on the assessment of electronic apex locators. *J Endod* 2007, **33**:476–479.
 32. Chen E, Kaing S, Mohan H, Ting S-Y, Wu J, Parashos P: An ex vivo comparison of electronic apex locator teaching models. *J Endod* 2011, **37**:1147–1151.
 33. Bargholz C: Perforation repair with mineral trioxide aggregate: a modified matrix concept. *Int Endod J* 2005, **38**:59–69.
 34. Mente J, Hage N, Pfefferle T, Koch MJ, Geletneky B, Dreyhaupt J, Martin N, Staehle HJ: Treatment outcome of mineral trioxide aggregate: repair of root perforations. *J Endod* 2010, **36**:208–213.

Submit your next manuscript to BioMed Central and take full advantage of:

- Convenient online submission
- Thorough peer review
- No space constraints or color figure charges
- Immediate publication on acceptance
- Inclusion in PubMed, CAS, Scopus and Google Scholar
- Research which is freely available for redistribution

Submit your manuscript at
www.biomedcentral.com/submit

