

Atlantoaxial instability in a case of Maroteaux–Lamy syndrome

ABSTRACT

A relatively rare report of an 8-year-old girl with Maroteaux–Lamy syndrome that is Type VI mucopolysaccharidosis who presented with symptoms of spastic quadriplegia related to atlantoaxial instability is presented. Atlantoaxial stabilization resulted in rapid and sustained neurological recovery.

Keywords: Atlantoaxial instability, Maroteaux–Lamy syndrome, mucopolysaccharidosis

INTRODUCTION

Mucopolysaccharidoses are a rare group of lysosomal storage disorders characterized by the inability of the body to metabolize glycosaminoglycans leading to their accumulation in different body tissues.^[1,2] Maroteaux–Lamy syndrome is Type VI mucopolysaccharidosis (MPS–VI) and is caused by the deficiency of galactosamine–4 sulfatase (arylsulfatase B).^[1–7] The deficiency causes the accumulation of partially degraded dermatan sulfate in cells of the body, especially connective tissue. This abnormal deposition leads to various skeletal abnormalities and multiorgan dysfunction. Craniovertebral anomalies associated with mucopolysaccharidosis include atlantoaxial dislocation, odontoid hypoplasia, and upper cervical stenosis. Whereas atlantoaxial dislocation is more commonly seen in patients with Hurler's syndrome and Morquio's disease, it is less frequently seen in patients with Maroteaux–Lamy syndrome.^[4–7] We present a case of Maroteaux–Lamy syndrome with atlantoaxial instability treated by atlantoaxial fixation.

CASE REPORT

An 8-year-old girl who was small for her age, presented with complaints of progressive weakness and stiffness of all four limbs for about 4 years. Her weight was 13 kg and

height was 89 cm, both were three standard deviations below that expected of her age. She was unable to walk for the last 8 months. There were no sensory complaints. There was difficulty in breathing and speaking full sentences due to the shortness of breath. She had been diagnosed with a case of Maroteaux–Lamy syndrome at the age of 3 years. On examination, she had spastic Grade 3–4/5 quadriplegia. There were short neck and fixed flexion deformity of the fingers of both hands. Magnetic resonance imaging and computed tomography of the craniovertebral junction showed hypoplasia of the odontoid, peri-odontoid ligamentous hypertrophy, and mobile-reducible atlantoaxial instability. The atlantoaxial instability was more of “vertical” variety.^[8] There was evidence of Goel Type 1 facet instability meaning thereby that on lateral profile imaging with neutral head posture the facet of the atlas

ABHIDHA SHAH¹, NEHA JADHAV¹, SASWAT DANDPAT¹, ATUL GOEL^{1,2}

¹Department of Neurosurgery, K.E.M. Hospital and Seth G.S. Medical College, ²Lilavati Hospital and Research Centre, Mumbai, Maharashtra, India

Address for correspondence: Prof. Atul Goel, Department of Neurosurgery, K.E.M. Hospital and Seth G.S. Medical College, Parel, Mumbai - 400 012, Maharashtra, India. E-mail: atulgoel62@hotmail.com

Submitted: 15-Jan-21


Accepted: 17-Jan-21

Published: 04-Mar-21

This is an open access journal, and articles are distributed under the terms of the Creative Commons Attribution-NonCommercial-ShareAlike 4.0 License, which allows others to remix, tweak, and build upon the work non-commercially, as long as appropriate credit is given and the new creations are licensed under the identical terms.

For reprints contact: WKHLRPMedknow_reprints@wolterskluwer.com

How to cite this article: Shah A, Jadhav N, Dandpat S, Goel A. Atlantoaxial instability in a case of Maroteaux–Lamy syndrome. *J Craniovert Jun Spine* 2021;12:91–4.

Access this article online	
Website: www.jcvjs.com	Quick Response Code 
DOI: 10.4103/jcvjs.JCVJS_5_21	

was displaced anterior to the facet of the axis^[9] [Figure 1]. Apart from her craniovertebral instability she also had a host of other systemic abnormalities. She had macrocephaly with short stature, bilateral corneal clouding, coarse facial features and large ears. The wrists on both sides were hyperextensible with dysostosis multiplex of limbs. There was no mental retardation. Her audiometry revealed a bilateral conductive hearing loss. On two-dimensional Echo, there was thickened myxomatous mitral valve with mild mitral regurgitation, speckled myocardium, septal hypertrophy, and an ejection fraction of 50%. An ultrasound of the abdomen confirmed the presence of umbilical hernia with bowel herniation with muscle dehiscence of 18 mm. Skeletal survey showed a shortening of long bones of the upper limb with the pointing of metaphysis. There was thoracic kyphoscoliosis. There was also bilateral irregularity of the head of the femur with bullet-shaped feet and diffuse osteopenia. X-ray of the skull showed dolichocephaly with thinning of the cortex.

Atlantoaxial stabilization was done using the techniques described by us earlier and summarized here.^[10,11] The patient was placed in a prone position after the application of Gardner Wells traction tong. Visual inspection and manual manipulation of bones showed a highly mobile and unstable atlantoaxial joint. The atlantoaxial joints were exposed widely on both sides widely amidst venous bleeding. The articular cartilage was widely denuded and bone graft was stuffed into the articular cavity. A standard C1 lateral mass and C2 pedicle screw fixation was performed bilaterally. As described earlier in our article, the vertebral artery was mobilized inferiorly and laterally to insert C2 screw.^[12] The screw purchase was satisfactory. The muscles attached to the C2 spinous process were cut and the host bone of posterior elements of atlas and axis were decorticated to make it a suitable recipient for the bone graft. The patient improved in her stiffness and weakness in the immediate postoperative period. Her breathing became better and she was able to speak clearly. Postoperative imaging showed satisfactory stabilization of the craniovertebral junction [Figure 1]. At follow-up of 18 months the patient is doing well, she can walk unaided and carry out her routine activities.

DISCUSSION

Mucopolysaccharidoses have been known to be associated with a host of spinal abnormalities including that of the craniovertebral junction.^[1,2] There are 7 known types of mucopolysaccharidoses that have been classified according to their enzyme deficits.^[1,2] They have the

autosomal recessive inheritance. The basic defect is in the enzyme that is essential for the degradation of glycosaminoglycans or mucopolysaccharides. This leads to an accumulation of glycoasmainoglycans in the lysosomes in various abdominal organs, the cardiovascular system, the central nervous system, and the skeletal system. Clinical manifestations include short height, short and wide thorax, macrocephaly, characteristic facial features, hypermobile joints, short limbs, and abnormally wide spacing among the teeth (micro-odontia).^[1-7] With the recent advent of enzyme and bone marrow therapy, the prognosis of the disorder has changed toward the better.

Spinal abnormalities are a common component in patients with Mucopolysaccharidoses. The frequent abnormalities that are seen in these children include deficiency of the anterior and middle column of the spine that gives rise to platyspondyly, presence of an anterior peak, coined or beaked vertebrae, and kyphoscoliosis.

Hurler's syndrome (MPS-I) and Morquio's syndrome (MPS-IV) have been known to be more frequently associated with atlantoaxial instability. Maroteaux-Lamy syndrome is generally associated with stenosis at the level of the foramen magnum or upper cervical canal stenosis presumably due to the thickening of the posterior longitudinal ligament and is one of the major clinical complications of MPS VI. Storage of glycosaminoglycans in the dura mater and supporting ligaments, kyphoscoliosis, and cervical bony stenosis are thought to be the main causes of myelopathy in these patients. Atlantoaxial instability is rare.^[4-7] The clinical manifestations of Hurler's syndrome and Maroteaux Lamy syndrome are quite similar, however, patients with Hurler's syndrome have mental retardation and patients with Maroteaux Lamy syndrome have normal intelligence.

Several authors have questioned the role of prophylactic surgery in asymptomatic patients with odontoid hypoplasia in patients with MPS VI (Maroteaux-Lamy syndrome) as the risk of sudden neurological worsening due to instability is rare unlike in patients with Hurler's and Morquio's syndrome.^[3-5] Controversy also exists on the type of surgery that should be performed. Some authors recommend craniocervical decompression whereas others recommend decompression with a spinal fusion.^[1-7] Remondino *et al.* presented a series of 52 patients with spinal lesions and mucopolysaccharidoses treated by them.^[2] Two of these patients had Maroteaux-Lamy syndrome, but none of them had atlantoaxial instability. In a series of 9 patients of Maroteaux-Lamy syndrome treated by Thorne *et al.*, six

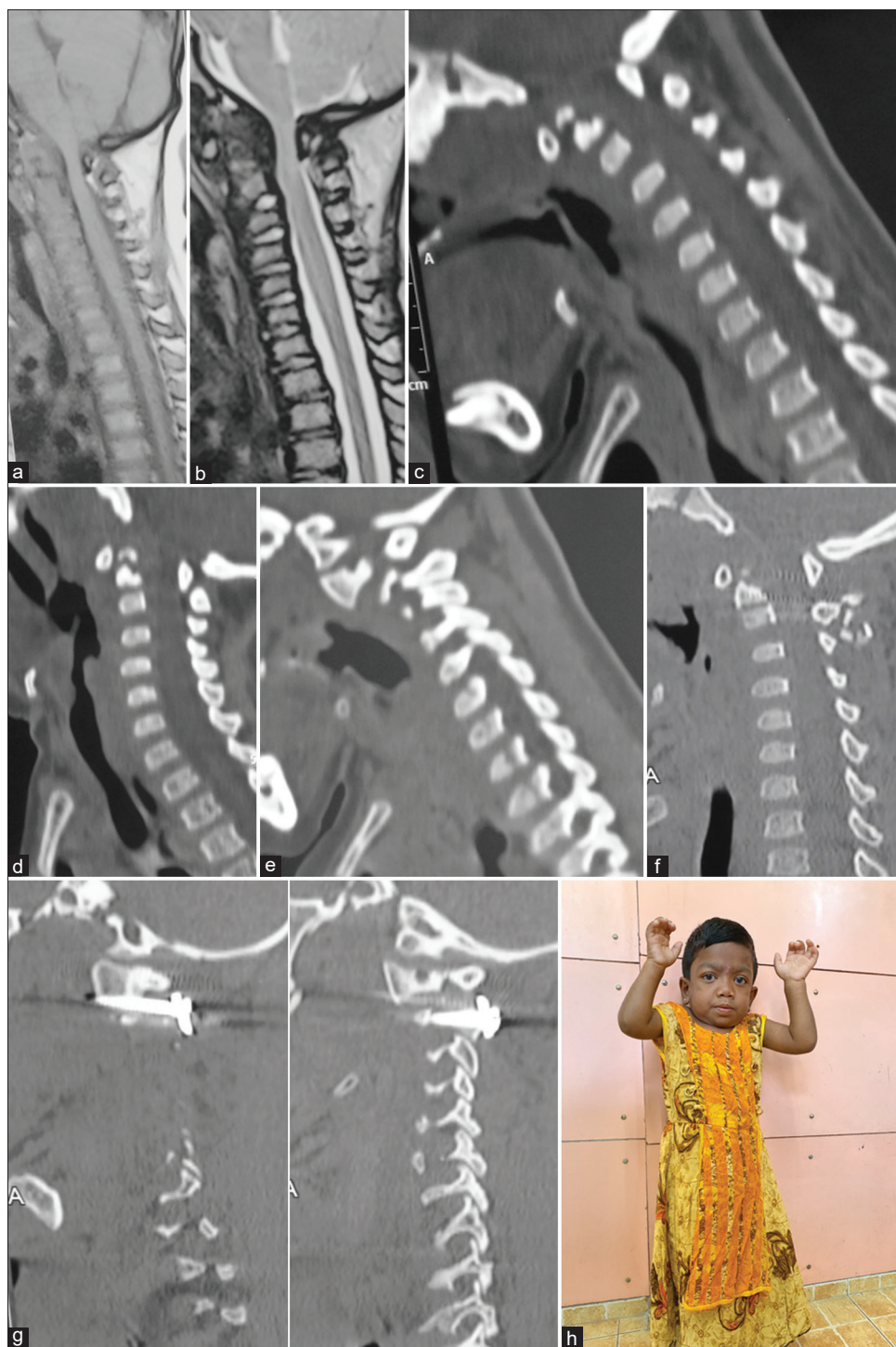

Figure 1: (a) T1-weighted magnetic resonance imaging showing hypoplastic odontoid process with ill-defined periodontoid tissue. (b) T2-weighted magnetic resonance imaging showing compression of neural structures at the craniocervical junction. (c) Computed tomography scan with the head in flexed position showing the hypoplastic odontoid process and atlantoaxial instability. (d) Computed tomography scan with the head in extended position showing “vertical reduction” of atlantoaxial instability. (e) Computed tomography scan with the cut passing through the facets showing Type 1 atlantoaxial facetal instability. (f) Postoperative computed tomography scan showing atlantoaxial fixation in aligned position. (g) Postoperative computed tomography scan showing the implant. (h) Follow up profile image of the patient (with permission)

patients had cervical canal stenosis and one of these patients had associated atlantoaxial instability.^[4] The patients were treated essentially with only spinal decompression with an additional spinal fusion.

In the presented case, there was odontoid hypoplasia with atlantoaxial instability. The periodontoid soft-tissue ligamentous hypertrophy and reduced bone content of the odontoid process were suggestive of both bone and

soft-tissue abnormality and indicated the presence of chronic instability. The child was successfully treated by segmental atlantoaxial stabilization.

CONCLUSION

Atlantoaxial instability is a rare feature in patients with Maroteaux–Lamy syndrome. A segmental atlantoaxial fixation can lead to gratifying neurological improvement in these patients.

Declaration of patient consent

The authors certify that they have obtained all appropriate patient consent forms. In the form, the legal guardian has given his consent for images and other clinical information to be reported in the journal. The guardian understands that names and initials will not be published and due efforts will be made to conceal identity, but anonymity cannot be guaranteed.

Financial support and sponsorship

Nil.

Conflicts of interest

There are no conflicts of interest.

REFERENCES

1. Krenzlin H, Ta-Chih T, Lampe C, Lampe C, Knuf M, Horn P, *et al.* Stand-alone craniocervical decompression is feasible in children with mucopolysaccharidosis type I, IVA, and VI. *Spine J* 2018;18:1455-9.
2. Remondino RG, Tello CA, Noel M, Wilson AF, Galaretto E, Bersusky E, *et al.* Clinical manifestations and surgical management of spinal lesions in patients with mucopolysaccharidosis: A report of 52 cases. *Spine Deform* 2019;7:298-303.
3. Vougioukas VI, Berlis A, Kopp MV, Korinthenberg R, Spreer J, van Velthoven V. Neurosurgical interventions in children with Maroteaux–Lamy syndrome. Case report and review of the literature. *Pediatr Neurosurg* 2001;35:35-8.
4. Thorne JA, Javadpour M, Hughes DG, Wraith E, Cowie RA. Craniovertebral abnormalities in Type VI mucopolysaccharidosis (Maroteaux–Lamy syndrome). *Neurosurgery* 2001;48:849-52.
5. Horovitz DD, Magalhães Tde S, Pena e Costa A, Carelli LE, Souza e Silva D, de Linhares e Riello AP, *et al.* Spinal cord compression in young children with type VI mucopolysaccharidosis. *Mol Genet Metab* 2011;104:295-300.
6. Mut M, Cila A, Varli K, Akalan N. Multilevel myelopathy in Maroteaux–Lamy syndrome and review of the literature. *Clin Neurol Neurosurg* 2005;107:230-5.
7. Lampe C, Lampe C, Schwarz M, Müller-Forell W, Harmatz P, Mengel E. Craniocervical decompression in patients with mucopolysaccharidosis VI: Development of a scoring system to determine indication and outcome of surgery. *J Inherit Metab Dis* 2013;36:1005-13.
8. Goel A, Shah A, Rajan S. Vertical mobile and reducible atlantoaxial dislocation. Clinical article. *J Neurosurg Spine* 2009;11:9-14.
9. Goel A. Goel's classification of atlantoaxial "facetial" dislocation. *J Craniovertebr Junction Spine* 2014;5:3-8.
10. Goel A, Desai KI, Muzumdar DP. Atlantoaxial fixation using plate and screw method: A report of 160 treated patients. *Neurosurgery* 2002;51:1351-6.
11. Goel A, Laheri VK. Plate and screw fixation for atlanto-axial dislocation. (Technical report). *Acta Neurochir (Wien)* 1994;129:47-53.
12. Goel A, Rangnekar R, Shah A, Rai S, Vutha R. Mobilization of the vertebral artery-surgical option for C2 screw fixation in cases with "high riding" vertebral artery. *Oper Neurosurg (Hagerstown)* 2020;18:648-51.