

Case Report

Open Access

## Chondrosarcoma of the spine: A rare case with unusual presentation

John Panelos<sup>1</sup>, Spyridon Voulgaris<sup>2</sup>, Evangelos Michos<sup>2</sup>, Michael Doukas<sup>1</sup>, Konstantinos Charalabopoulos<sup>3</sup> and Anna Batistatou\*<sup>1</sup>

Address: <sup>1</sup>Department of Pathology University of Ioannina Medical School, Ioannina, Greece, <sup>2</sup>Department of Neurosurgery, University of Ioannina Medical School, Ioannina, Greece and <sup>3</sup>Department of Physiology, Clinical Unit, University of Ioannina Medical School, Ioannina, Greece

Email: John Panelos - [jpanel@cc.uoi.gr](mailto:jpanel@cc.uoi.gr); Spyridon Voulgaris - [svoulg@cc.uoi.gr](mailto:svoulg@cc.uoi.gr); Evangelos Michos - [abatista@cc.uoi.gr](mailto:abatista@cc.uoi.gr); Michael Doukas - [abatista@cc.uoi.gr](mailto:abatista@cc.uoi.gr); Konstantinos Charalabopoulos - [kcharala@cc.uoi.gr](mailto:kcharala@cc.uoi.gr); Anna Batistatou\* - [abatista@cc.uoi.gr](mailto:abatista@cc.uoi.gr)

\* Corresponding author

Published: 30 October 2006

Received: 04 August 2006

*Diagnostic Pathology* 2006, **1**:39 doi:10.1186/1746-1596-1-39

Accepted: 30 October 2006

This article is available from: <http://www.diagnosticpathology.org/content/1/1/39>

© 2006 Panelos et al; licensee BioMed Central Ltd.

This is an Open Access article distributed under the terms of the Creative Commons Attribution License (<http://creativecommons.org/licenses/by/2.0>), which permits unrestricted use, distribution, and reproduction in any medium, provided the original work is properly cited.

### Abstract

Chondrosarcoma is the third most common primary malignancy of bone, affecting primarily the pelvic and shoulder girdles and being extremely rare in the spine. Herein, we present a case of a 65-year-old woman with a rare chondrosarcoma of the spine, who presented with clinical symptoms from the lung metastasis. The neoplasm was grade II and exhibited overexpression of the p53 tumor suppressor protein. The latter has been associated with a high propensity for distant metastases.

### Background

Chondrosarcoma is a malignant tumor composed entirely of hyaline cartilage matrix and chondrocytes [6,12]. It is the third most common primary malignant neoplasm of bone after myeloma and osteosarcoma. The majority of patients are older than 50 years, with a peak of incidence in the fifth to seventh decade of life. More than two thirds of cases involve the bones of the pelvis, the shoulder and the proximal ends of femur and humerus [12]. Chondrosarcoma is extremely rare in the spine [1,10,11].

### Case Presentation

A 65-year-old woman, non smoker, visited our hospital with a 6-month history of persistent dry cough. Radiographic examination revealed the presence of a solitary nodule of the lung (right upper field), with morphologic features more consistent with metastasis. The patient mentioned a persistent, mild lumbar pain for the last two

years and she had received nonsteroidal anti-inflammatory drugs. Upon a detailed physical examination a barely palpable mass at the lumbar area was noted. The reflexes of the lower extremities were normal. Laboratory examination showed no abnormalities, and all tumor markers had normal values. Magnetic resonance imaging (MRI) and CT-scan revealed an ill-defined osteolytic lesion of the L 5 vertebra with a splotch calcification, cortical permeation and extension to the surrounding soft tissues. In chest CT-scan the lung nodule was of similar consistency. An attempt to biopsy the lung nodule was made, but the material obtained was insufficient for diagnosis.

The patient underwent surgery in the spine, due to the danger of collapse of the L5 vertebra and the mass was excised.

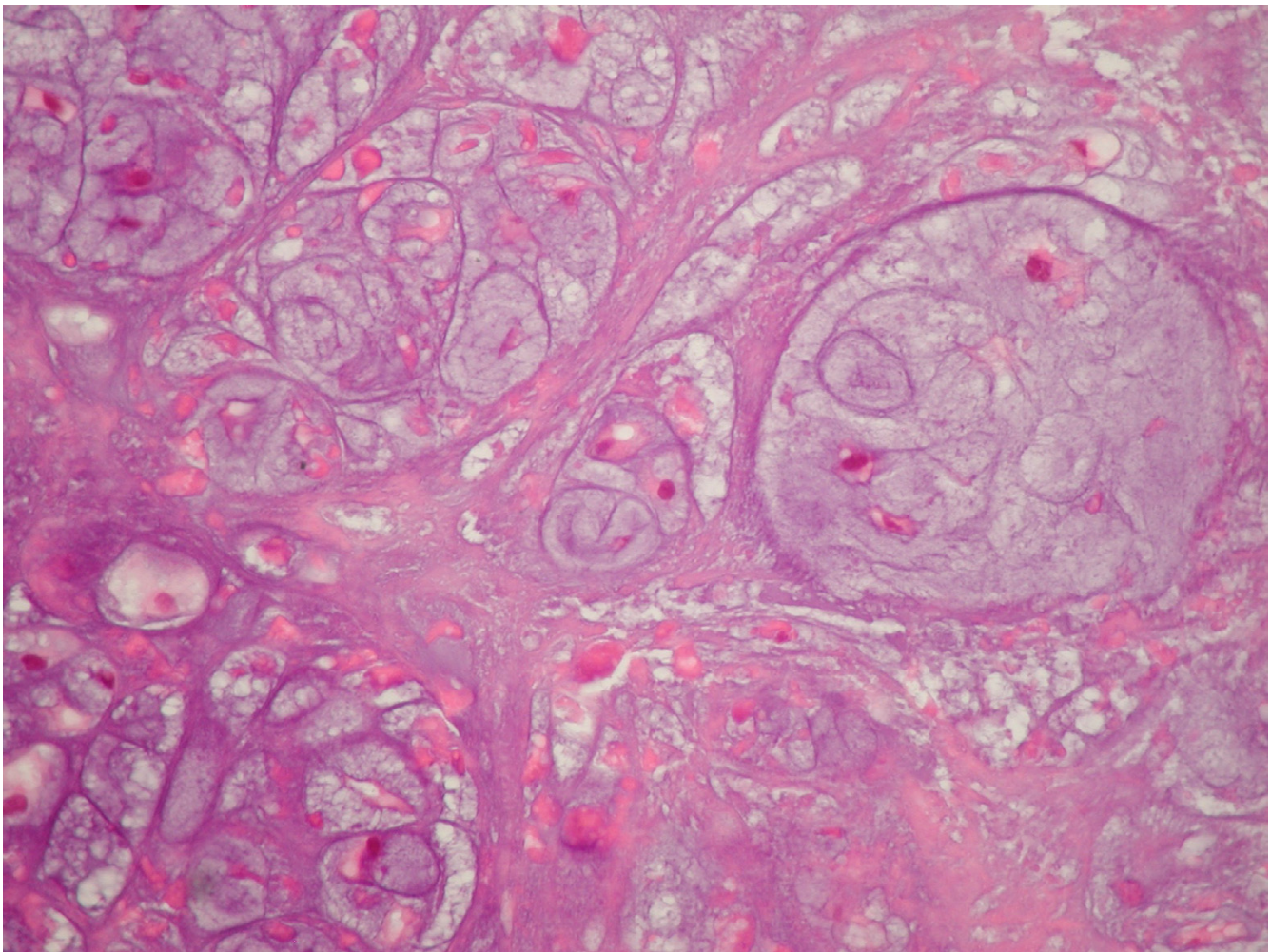
The histopathological examination revealed a moderately cellular multilobular neoplasm with chondroid and myxoid matrix and focal necrosis. Under high power view, multicellular lacunae of chondrocytes with moderate nuclear pleomorphism and hyperchromasia were observed (Fig. 1). Mitotic figures were numerous. The tumor was diagnosed as chondrosarcoma, grade II. On immunohistochemical examination > 25 % of the neoplastic cells exhibited nuclear immunoreactivity for the tumor suppressor protein p53 (Fig. 2). Furthermore < 1 % of the neoplastic cells were in cell cycle, as estimated with the immunohistochemical marker MIB-1 (ki-67) (Fig. 3).

The patient underwent radiotherapy and is alive one year later.

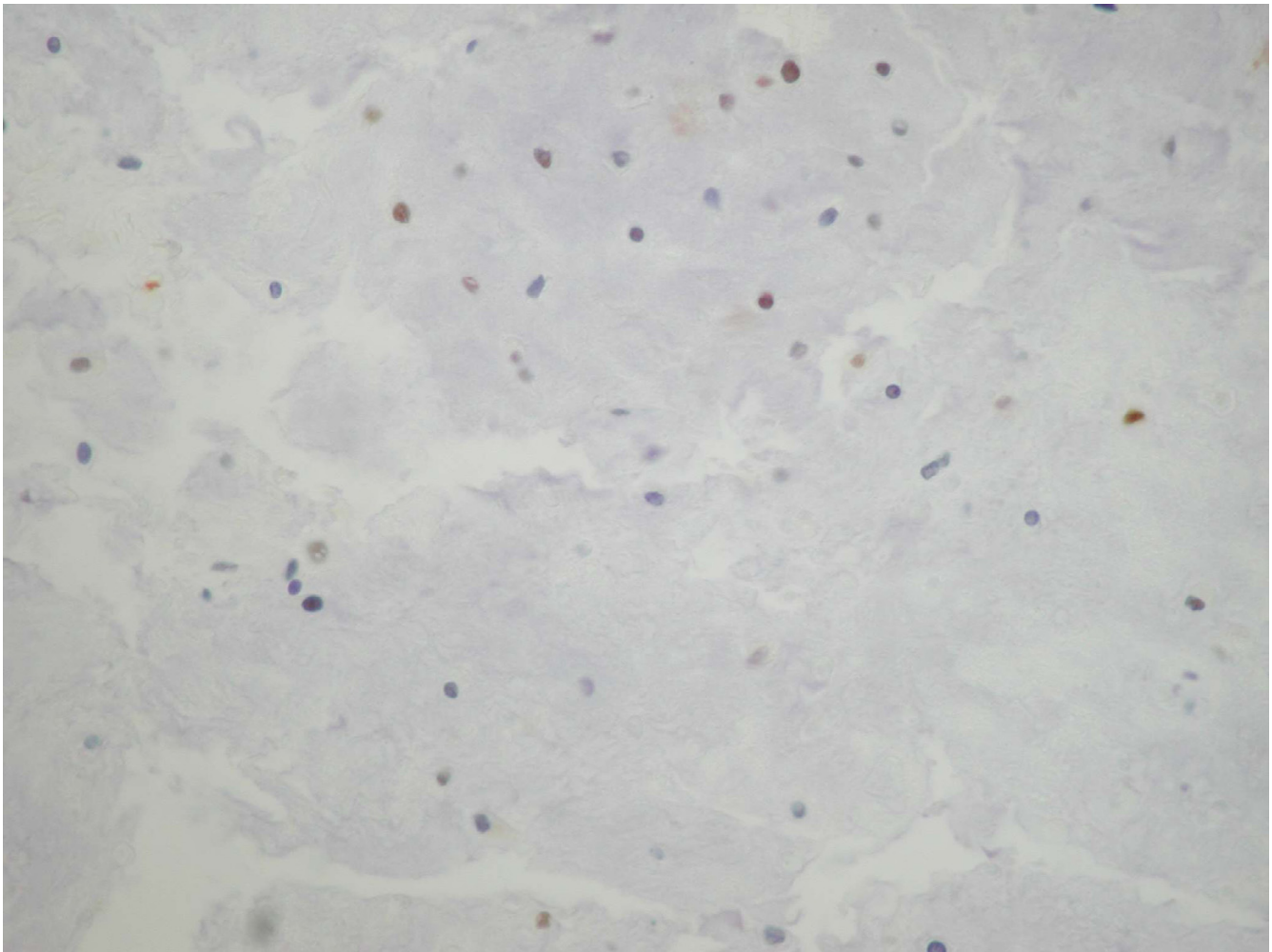
## Discussion

The incidence of chondrosarcoma of the spine is reported to be 4–10% of all chondrosarcomas and 12% of all malignant neoplasms of the spine [1,10,11]. The main symptom is pain and sensory or motor deficit. The diagnosis is difficult, particularly from needle biopsy material, therefore open biopsy is recommended. The microscopic features of chondrosarcoma of the spine are similar with those of the most common appendicular tumors.

Chondrosarcomas are locally aggressive tumors with limited potential for metastasis. When metastases occur, they generally involve the lungs and appear late in the course of the disease. Wide surgical resection is the treatment of choice. Chondrosarcomas are divided into three grades according to the nuclear size, nuclear staining (hyperchromasia) and cellularity [4]. Many studies have shown the significance of grading of chondrosarcoma in predicting



**Figure 1**  
Multilobular neoplasm with chondroid matrix and nuclear pleomorphism (haematoxylin and eosin X400).



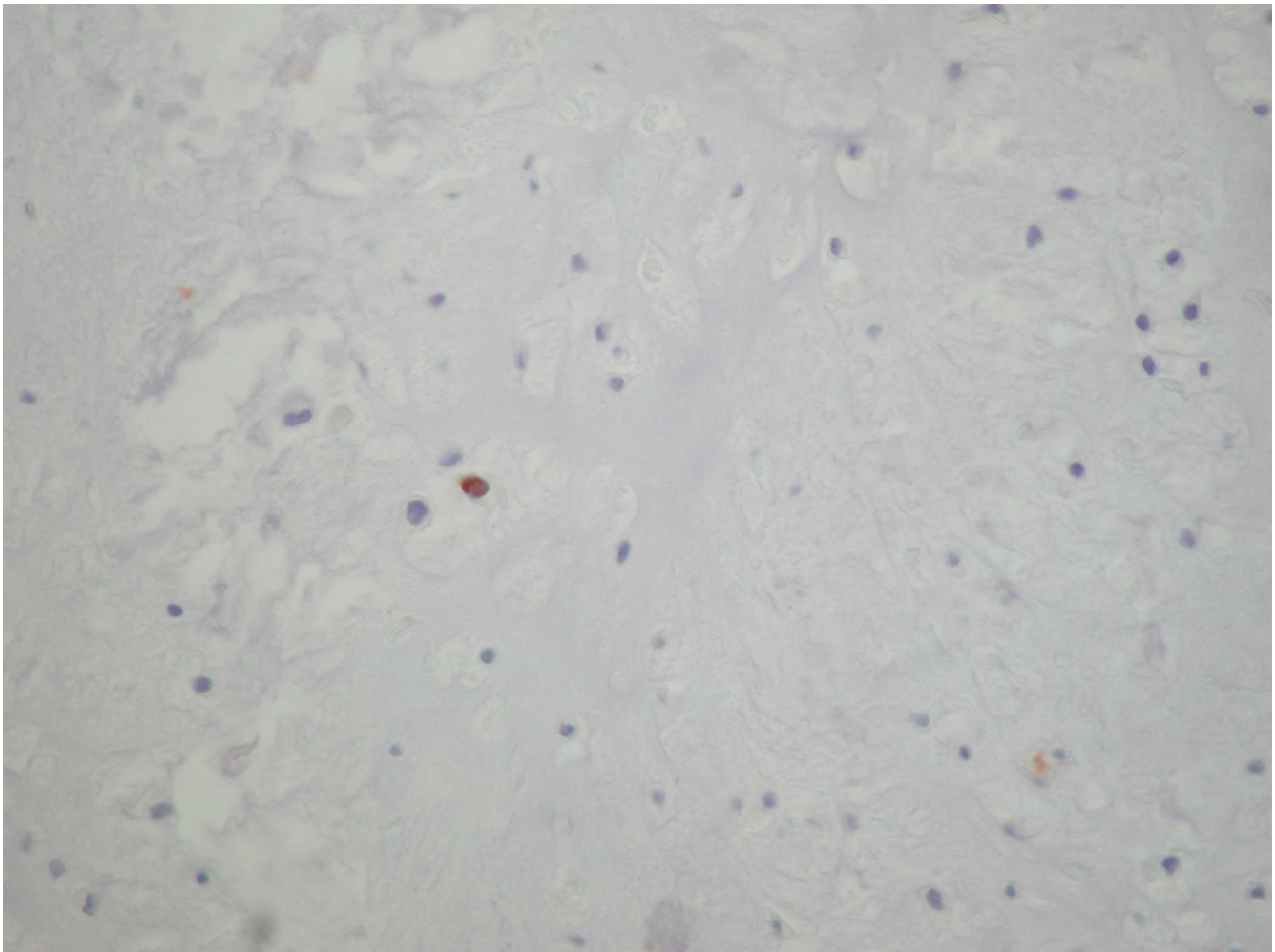
**Figure 2**  
Increased nuclear immunoreactivity for p53 (DABX400).

the tumor behaviour and prognosis. Indeed, histological grade is the most important single predictor of local recurrence and metastasis.

Cytogenetic analyses have demonstrated a strong correlation between chromosomal abnormalities and histologic grade. Of the proto-oncogenes only the *c-met* gene which encodes for a transmembrane tyrosine kinase has been shown to be associated with the development of cartilaginous tumors [13]. Of the tumor suppressor genes, several studies have shown that altered patterns of p53 expression and TP53 mutations are detected primarily in high-grade, advanced tumors. The TP53 gene appears to be inactivated late in the course of chondrosarcoma and may be associated with disease progression. [2,3,7,12]. Altered p53 status has been correlated with high propensity for local recurrence and distant metastases even in grade I and grade II chondrosarcomas, indicating that it may repre-

sent a predictor of aggressive behavior that is independent of grade [8]. Furthermore, in a recent study, overexpression of p53 and Ki-67 in high-grade chondrosarcomas has been correlated with an unfavorable outcome [5]. The development and progression of malignant neoplasms has been associated with the production of different molecules, such as growth factors, that can be identified as biological markers as well. In chondrosarcomas, besides p53 and Ki-67, the expression of growth factors, i.e. TGF $\beta$  and PDGF and of VEGF has been associated with more aggressive behavior [5].

This is the first report on the p53 expression in a spinal chondrosarcoma. It is interesting that in our case, which presented initially with symptomatology from the lung metastasis, we noted p53 immunostaining in a high percentage of neoplastic cells. Thus, it appears that in spinal chondrosarcomas, similar to the appendiceal ones, the



**Figure 3**  
Rare nuclear immunoreactivity for MIB-1 (ki-67) (DABX400).

metastatic potential may be correlated with altered p53 status. Further studies, with a series of spinal chondrosarcomas and possibly with the use of tissue microarrays [9] are needed for definite conclusions.

#### Competing interests

The author(s) declare that they have no competing interests.

#### Authors' contributions

JP, KC and AB have been involved in conceiving and drafting the manuscript. JP and MD have been involved in the literature search. EM and SV have worked-up and treated the patient. All authors read and approved the final manuscript.

#### References

1. Austin JP, Urie MM, Cardenosa G, Munzenrider JE: **Probable causes of recurrence in patients with chondroma and chondrosarcoma of the base of skull and cervical spine.** *Int J Radiat Oncol Biol Phys* 1993, **25**:439-444.
2. Coughlan B, Feliz A, Ishida T, Czerniak D, Dorfman HD, et al.: **p53 expression and DNA ploidy of cartilage lesions.** *Hum Pathol* 1995, **26**:620-624.
3. Dobashi Y, Sugimura H, Sato A, Hirabayashi T, Kanda H, Kitagawa T, Kawaguchi N, Imamura T, Machinami R: **Possible association of p53 overexpression and mutation with high-grade chondrosarcoma.** *Diagn Mol Pathol* 1993, **2**:257-63.
4. Evans HL, Ayala AG, Romsdahl MM: **Prognostic factors in chondrosarcoma of the bone: a clinicopathological analysis with emphasis on histologic grading.** *Cancer* 1977, **40**:818-831.
5. Falcone G, Rossi ED, Maccauro G, de Santis V, Rosa MA, Capelli A, Fadda G: **Diagnostic relevance of the immunohistochemical detection of growth factors in benign and malignant cartilaginous tumors.** *Appl Imm Mol Morphol* 2006, **14**:334-340.
6. Fletcher CDM, Unni KK, Mertens F: **Pathology and Genetics of Tumours of Soft Tissue and Bone.** *WHO Classification of Tumors* 2002:247-254.
7. Nawa G, Ueda T, Mori S, Yoshikawa H, Fukuda H, Ishiguro S, Funai H, Uchida A: **Prognostic significance of Ki67 (MIB1) proliferation index and p53 over-expression in chondrosarcomas.** *Int J Cancer* 1996, **69**:86-91.
8. Oshiro Y, Chaturvedi V, Hayden D, Nazeer T, Johnson M, Johnston DA, Ordenez NG, Avala AG, Czerniak B: **Altered p53 is associ-**

- ated with aggressive behavior of chondrosarcoma. *Cancer* 1998, **83**:2324-2334.
9. Pires Ar, Andreiuolo FM, Souza SR: **TMA for all: A new method for the construction of tissue microarrays without recipient paraffin block using custom-built needles.** *Diagn Pathol* 2006 in press.
  10. Sakayama K, Kawatani Y, Kidani T, Sugawara Y, Miyazaki T, Fujibuchi T, Yamamoto H: **Dumbbell-shaped chondrosarcoma that primarily developed in the cervical spine: a case report.** *J Orthop Sci* 2004, **9**:166-170.
  11. Shives TC, McLeod RA, Unni KK, Schray MF: **Chondrosarcoma of the Spine.** *J Bone Joint Surg Am* 1989, **71**:1158-1165.
  12. Terek RM, Healey JH, Garin-Chesa P, Mak S, Huvos A, Albino AP: **p53 mutations in chondrosarcoma.** *Diagn Mol Pathol* 1998, **7**:51-56.
  13. Unni KK, Inwards CY, Bridge JA, Kindblom L-G, Wold LE: **Tumors of the Bones and Joints.** *AFIP Atlas of Tumor Pathology* 2005:73-86.

Publish with **BioMed Central** and every scientist can read your work free of charge

*"BioMed Central will be the most significant development for disseminating the results of biomedical research in our lifetime."*

Sir Paul Nurse, Cancer Research UK

Your research papers will be:

- available free of charge to the entire biomedical community
- peer reviewed and published immediately upon acceptance
- cited in PubMed and archived on PubMed Central
- yours — you keep the copyright

Submit your manuscript here:  
[http://www.biomedcentral.com/info/publishing\\_adv.asp](http://www.biomedcentral.com/info/publishing_adv.asp)

