

# A Sporadic Neonatal Case of Epidermolysis Bullosa Simplex Generalized Intermediate with *KRT5* and *KRT14* Gene Mutations

Hiroyuki Wakiguchi, MD, PhD<sup>1</sup> Shunji Hasegawa, MD, PhD<sup>1</sup> Shinji Maeba, MD, PhD<sup>1</sup>  
Sasagu Kimura, MD<sup>1</sup> Satoko Ito, MD<sup>2</sup> Hiroshi Tateishi, MD, PhD<sup>2</sup> Kazuhiro Ueda, MD, PhD<sup>3</sup>  
Shouichi Ohga, MD, PhD<sup>1</sup>

<sup>1</sup>Department of Pediatrics, Graduate School of Medicine, Yamaguchi University, Ube, Yamaguchi, Japan

<sup>2</sup>Division of Pediatrics, JCHO Tokuyama Central Hospital, Shunan, Yamaguchi, Japan

<sup>3</sup>Division of Pediatrics, Michigami Hospital, Hikari, Yamaguchi, Japan

Address for correspondence Shunji Hasegawa, MD, PhD, Department of Pediatrics, Graduate School of Medicine, Yamaguchi University, 1-1-1 Minamikogushi, Ube, Yamaguchi 755-8505, Japan (e-mail: shunji@yamaguchi-u.ac.jp).

Am J Perinatol Rep 2016;6:e108–e111.

## Abstract

### Keywords

- ▶ epidermolysis bullosa simplex
- ▶ *KRT5*
- ▶ *KRT14*
- ▶ mutation
- ▶ newborn

**Background** Epidermolysis bullosa simplex (EBS) is a rare genodermatosis resulting from multiple gene mutations, including *KRT5* and *KRT14*. The clinical expression of the mechanobullous skin fragility disease has not been fully explained by the genotype.

**Case Description** An 11-day-old Japanese newborn infant was hospitalized because of herpetiform skin blistering on the feet, which expanded systemically after birth. There was no evidence of virus infection. The biopsied skin lesion showed a blister on the lamina densa without keratin clumps, indicating a diagnosis of EBS-generalized intermediate. We punctured the blisters to remove the contents daily, which led to no exacerbation or infection. The genetic study determined that the patient carried double substitutions of *KRT5* c.1424A > G (p.E475G) and *KRT14* c.1237G > A (p.A413T). The asymptomatic mother and sister carried the *KRT14* substitution, but the healthy father had no substitution of the *KRT* gene.

**Conclusion** This is the first report of EBS-generalized intermediate in a newborn with de novo *KRT5* gene mutation and *KRT14* gene polymorphism, and no familial history of epidermolysis. Neonatal blistering due to EBS requires optimal skin management after excluding infectious and immunobullous diseases.

Epidermolysis bullosa simplex (EBS) is a rare genodermatosis resulting from *TGM5*, *DSP*, *JUP*, *PKP1*, *KRT5*, *KRT14*, *EXPH5*, *PLEC*, or *DST* gene mutations. The mechanobullous skin fragility disease is characterized by cytolysis of basal keratinocytes and intraepidermal blistering.<sup>1,2</sup> EBS is classified into three major types of disease based on distinctive clinical features of *KRT5* and *KRT14* gene mutations.<sup>3,4</sup> In patients with the EBS-localized variant (EBS-loc and Weber–Cockayne type), bullous lesions may present as late as the third decade of life, but they are confined to the hands and feet. In patients with the EBS-generalized intermediate variant (EBS-gen

intermed and Köebner type), widespread blistering, with occasional involvement of the oral mucosa and nails, begin from infancy. The EBS-generalized severe variant (EBS-gen sev and Dowling–Meara type) is the most severe form in newborns, presenting with generalized blistering of the skin, which is accompanied by oral mucosa bullae and nail shedding.<sup>3,4</sup> Neonatal herpes simplex virus infection is a critical diagnosis to differentiate from systemic EBS occurring in newborns with no familial history of blistering.

We present a newborn infant with EBS-gen intermed who had systemic blistering after birth. He had no family history of

received  
July 12, 2015  
accepted after revision  
November 13, 2015

DOI <http://dx.doi.org/10.1055/s-0035-1570386>.  
ISSN 2157-6998.

Copyright © 2016 by Thieme Medical Publishers, Inc., 333 Seventh Avenue, New York, NY 10001, USA.  
Tel: +1(212) 584-4662.

License terms



genodermatosis but carried the *KRT5* and *KRT14* gene substitutions. A family study determined that de novo *KRT5*, but not the *KRT14* substitution, was the pathognomonic finding for the disease. The early genetic study and skin management successfully controlled the systemic blistering.

**Case Description**

An 11-day-old Japanese newborn infant was transferred to the neonatal intensive care unit because of systemic skin blisters. He was the second-born child of healthy, unrelated Japanese parents, and there was no familial history of blistering. He was normal and delivered vaginally, weighing 3,380 g at 40 weeks of gestation and was suspected of having EBS because of localized skin blistering on the feet at birth. There was no evidence of bacterial, viral, and fungal infections, including the herpes simplex virus and varicella virus, along with immunobullous diseases according to the diagnostic algorithm of blisters and erosions in newborns.<sup>5</sup> One day after birth, the skin lesions extended to the infant’s face, hands, and feet after mechanical stresses. Nikolsky sign was positive. He had blisters in the oral membranes, which tended to heal without scars. Eleven days after birth, the blisters became generalized, followed by blistering on the head, neck, upper and lower limbs, nipples, navel, and buttocks (→Fig. 1A, B).

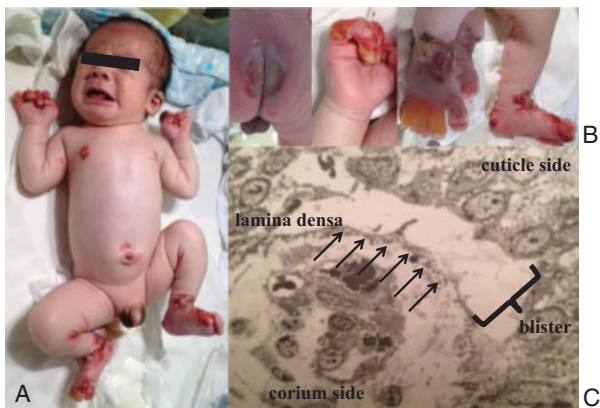On admission, a skin biopsy of the blisters was performed with electron microscopy. It showed a blister on the lamina densa without keratin clumps (→Fig. 1C). We excluded gastrointestinal (no bloody stool), respiratory (neither symptoms nor radiographic findings), and ocular (neither symptoms nor clinical findings) involvement. These findings led to the diagnosis of EBS-gen intermed. We treated him as follows. Smooth materials were chosen for his bed sheets to avoid mechanical stress. A nipple comprised a soft material for cleft palate was selected for his nursing bottle. Vaseline was applied to his skin to reduce friction. We punctured the blisters and removed the contents daily. Bullous lesions remained, but they did not become widespread. Because of no exacerbation, he was discharged from the hospital 72 days

after birth. Subcutaneous injections of inactivated vaccines (*Haemophilus influenzae* type b, *Pneumococcus*, diphtheria, pertussis, tetanus, and polio) and live vaccines (measles, rubella, and varicella) precipitated no skin blistering. His generalized skin blisters were controlled without exacerbation and cutaneous union. He showed normal growth and development, including the development of teeth at 1 year old.

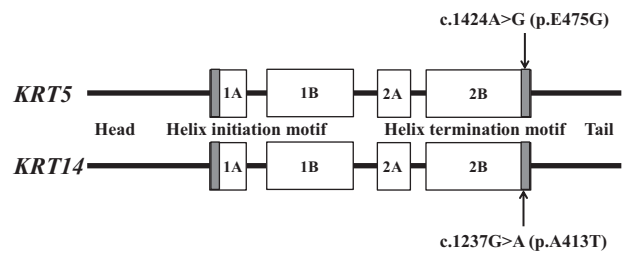
The genetic study of proband determined double substitutions of c.1424A > G (p.E475G) in the *KRT5* gene and c.1237G > A (p.A413T) in the *KRT14* gene (→Fig. 2). The infant’s father carried neither the *KRT5* gene mutation nor the *KRT14* gene substitutions. However, his mother and sister had c.1237G > A in the *KRT14* gene, but not the *KRT5* gene mutation (→Fig. 3). His parents and elder sister showed no skin disease.

**Discussion**

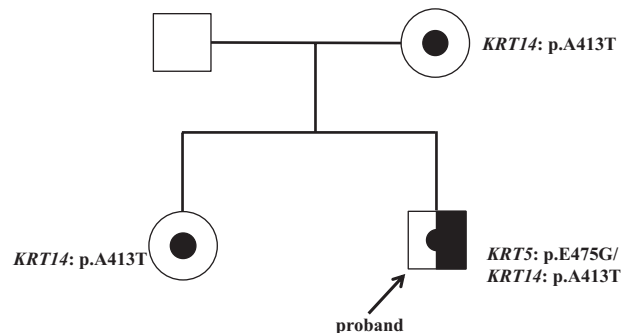
We found an EBS-gen intermed newborn infant with *KRT5* and *KRT14* gene substitutions and unaffected family members. Systemic EBS should be distinguished from other ominous diseases of neonatal blistering, including the herpes simplex virus infection. The shapes, size, and distribution of blisters as well as a positive family history are important for the diagnosis of EBS. In the present case, the clinical expressions and findings of electron microscopy showed a blister on the lamina densa without keratin clumps, which led to the diagnosis of EBS-gen intermed.<sup>6,7</sup>



**Fig. 1** Clinical presentation and electron microscopy of the patient with epidermolysis bullosa simplex. (A) Blisters at 11 days old. (B) Blistering of the buttocks, right hand, and feet. (C) Ultrastructural features of the proband’s lesional skin sample show a blister on the lamina densa. There are no apparent keratin clumps.



**Fig. 2** Mutation sites of the patient with epidermolysis bullosa simplex. The N- and C-terminus of the α-helical rod domain (white boxes, 1A, 1B, 2A, and 2B) are the helix initiation and termination motifs, respectively (gray boxes). The arrows denote the positions of the point mutation in *KRT5* and *KRT14* in the patient.



**Fig. 3** Pedigree of the patient with epidermolysis bullosa simplex.

This document was downloaded for personal use only. Unauthorized distribution is strictly prohibited.

Because of no cure for EBS, careful management is required to prevent the formation of new blisters and infections.<sup>8</sup> We chose smooth materials for his bed sheets and a soft nipple for his nursing bottle, and applied petroleum jelly to his skin, which all helped reduce friction on his skin and oral mucosa. In our observation, puncturing the blisters daily to remove the contents, including old keratins, may have accelerated wound healing. Effective care during the newborn period prevents long-lasting cosmetic and functional complications.

The incidence of de novo mutation in patients with EBS reportedly ranges from 37 to 58%.<sup>9–11</sup> In patients with EBS-gen intermed, de novo mutations may develop more frequently (~70%).<sup>9–11</sup> Our patient had two substitutions of c.1424A > G (p.E475G) in the *KRT5* gene and c.1237G > A (p.A413T) in the *KRT14* gene. The asymptomatic mother and sister carried c.1237G > A in the *KRT14* gene, but not the *KRT5* gene mutation. Clinical investigation did not reveal minor trauma-induced blisters on their hands and feet. The *KRT5* substitution has been reported in patients with EBS-gen sev, but not in the other types of EBS.<sup>12</sup> Histopathology did not show circinate blisters and keratin clumps that are characteristic of EBS-gen sev.<sup>6,7</sup> In addition, his blisters were not localized in the hands and feet as in the case of EBS-loc.<sup>3</sup>

This is the first report of EBS-gen intermed due to *KRT5* c.1424A > G. The PolyPhen-2 program (<http://genetics.bwh.harvard.edu/pph2/>) predicted that c.1424A > G in *KRT5* and the c.1237G > A polymorphism were probably causing damage to protein function with a score of 0.854 and 0.964, respectively (benign: 0.00–0.20, possibly damaging: 0.20–0.85, probably damaging: 0.85–1.00). The c.1237G > A in *KRT14* may contribute, if any, to the early expression of our patient as a modifier of EBS. The substitution c.1237G > A in *KRT14* may be a polymorphism<sup>2</sup> or an unknown pairwise transcriptional regulation of *KRT5* and *KRT14* genes may exist, although heterozygous mutation of *KRT5* c.1424A > G alone can dominantly cause clinical manifestations of EBS.<sup>1</sup> Wertheim-Tysarowska et al<sup>13</sup> reported that a 3-year-old patient with EBS-gen intermed had the coexistence of c.1412G > A (p.R471H) in *KRT5* and c.815T > C (p.M272T) in *KRT14* mutations. The proband's father and mother had c.815T > C in *KRT14* and c.1412G > A in *KRT5*, respectively, and both were diagnosed as having EBS-loc. They concluded that c.1412G > A in *KRT5* may act in a dominant-negative manner and the mutation leads to mild skin fragility when present alone, but in the presence of a mutation in the other keratin, it exacerbates the symptoms. On the contrary, the genotype–phenotype correlations of EBS have been reported to rely heavily on “the mutation location” in either *KRT5* or *KRT14*.<sup>14</sup> Mutations altering highly conserved residues located within the helix termination motifs in *KRT5* are overwhelmingly associated with EBS-gen sev. Patients with EBS-gen intermed and EBS-loc are more frequently caused by *KRT14* mutations than *KRT5* mutations in the helix termination motifs.<sup>14</sup> The present patient carried *KRT5* and *KRT14* mutations in the helix termination motifs (► **Fig. 2**). These results suggested that c.1424A > G in *KRT5* led to EBS-gen

sev when present alone, but in the presence of c.1237G > A in *KRT14*, it alleviated the symptoms.

## Conclusion

We reported the first newborn infant with EBS-gen intermed carrying the de novo *KRT5* gene mutation and *KRT14* gene polymorphism. The neonatal diagnosis of EBS is critical if there is no useful information on the family history.

### Competing Interests

The authors declare that they have no competing interests.

### Consent

Informed consent was obtained from the patient's legal guardian for publication of this case report.

### Acknowledgments

We thank Prof. Masahiko Muto, Dr. Michiya Yamaguchi, and Dr. Kishiko Matsumoto (Department of Dermatology, Yamaguchi University Graduate School of Medicine) for performing the genetic study.

## References

- 1 Chamcheu JC, Virtanen M, Navsaria H, Bowden PE, Vahlquist A, Törmä H. Epidermolysis bullosa simplex due to *KRT5* mutations: mutation-related differences in cellular fragility and the protective effects of trimethylamine N-oxide in cultured primary keratinocytes. *Br J Dermatol* 2010;162(5):980–989
- 2 Natsuga K, Nishie W, Smith BJ, et al. Consequences of two different amino-acid substitutions at the same codon in *KRT14* indicate definitive roles of structural distortion in epidermolysis bullosa simplex pathogenesis. *J Invest Dermatol* 2011;131(9):1869–1876
- 3 Premaratne C, Klingberg S, Glass I, Wright K, Murrell D. Epidermolysis bullosa simplex Dowling-Meara due to an arginine to cysteine substitution in exon 1 of keratin 14. *Australas J Dermatol* 2002;43(1):28–34
- 4 Fine JD, Bruckner-Tuderman L, Eady RA, et al. Inherited epidermolysis bullosa: updated recommendations on diagnosis and classification. *J Am Acad Dermatol* 2014;70(6):1103–1126
- 5 Nischler E, Klausegger A, Huttner C, et al. Diagnostic algorithm of blisters and erosions in newborns. *Dermatol Res Pract* 2009;2009:320403
- 6 Anton-Lamprecht I, Schnyder UW. Epidermolysis bullosa herpetiformis Dowling-Meara. Report of a case and pathomorphogenesis. *Dermatologica* 1982;164(4):221–235
- 7 Fine JD, Eady RA, Bauer EA, et al. Revised classification system for inherited epidermolysis bullosa: Report of the Second International Consensus Meeting on diagnosis and classification of epidermolysis bullosa. *J Am Acad Dermatol* 2000;42(6):1051–1066
- 8 Gonzalez ME. Evaluation and treatment of the newborn with epidermolysis bullosa. *Semin Perinatol* 2013;37(1):32–39
- 9 Bolling MC, Lemmink HH, Jansen GH, Jonkman MF. Mutations in *KRT5* and *KRT14* cause epidermolysis bullosa simplex in 75% of the patients. *Br J Dermatol* 2011;164(3):637–644
- 10 Kang TW, Lee JS, Kim SE, Oh SW, Kim SC. Novel and recurrent mutations in Keratin 5 and 14 in Korean patients with

- Epidermolysis bullosa simplex. *J Dermatol Sci* 2010;57(2): 90–94
- 11 Minakawa S, Nakano H, Nakajima K, et al. Mutational analysis on 16 Japanese population cases with epidermolysis bullosa simplex. *J Dermatol Sci* 2013;72(3):330–332
- 12 Lane EB, Rugg EL, Navsaria H, et al. A mutation in the conserved helix termination peptide of keratin 5 in hereditary skin blistering. *Nature* 1992;356(6366):244–246
- 13 Wertheim-Tysarowska K, Sota J, Kutkowska-Każmierczak A, Woźniak K, Bal J, Kowalewski C. Coexistence of KRT14 and KRT5 mutations in a Polish patient with epidermolysis bullosa simplex. *Br J Dermatol* 2014;170(2): 468–469
- 14 Coulombe PA, Kerns ML, Fuchs E. Epidermolysis bullosa simplex: a paradigm for disorders of tissue fragility. *J Clin Invest* 2009;119(7): 1784–1793