

# Relapse of Atypical Hemolytic Uremic Syndrome During Pregnancy in a Patient on Eculizumab Maintenance Treatment: A Case Report

Authors' Contribution:  
Study Design A  
Data Collection B  
Statistical Analysis C  
Data Interpretation D  
Manuscript Preparation E  
Literature Search F  
Funds Collection G

ABCDEF 1 **Francesco Fontana**  
BC 1 **Geatano Alfano**  
B 1 **Ermelinda Bardhushi**  
BD 1 **Giulia Ligabue**  
EF 1 **Silvia Giovanella**  
B 2 **Isabella Neri**  
DE 1 **Gianni Cappelli**

1 Surgical, Medical and Dental Department of Morphological Sciences, Section of Nephrology, University of Modena and Reggio Emilia, Modena, Italy  
2 Department of Mother-Infant, University of Modena and Reggio Emilia, Modena, Italy

**Corresponding Author:** Francesco Fontana, e-mail: francesco.fontana@unimore.it  
**Conflict of interest:** None declared

**Patient:** Female, 28  
**Final Diagnosis:** Relapse of atypical hemolytic uremic syndrome during pregnancy  
**Symptoms:** Anemia • edema • hemolysis • oliguria  
**Medication:** —  
**Clinical Procedure:** —  
**Specialty:** Nephrology

**Objective:** Rare disease  
**Background:** Atypical hemolytic uremic syndrome (aHUS) is a genetic disorder with uncontrolled complement activation leading to systemic thrombotic microangiopathy; kidneys are almost invariably involved. Eculizumab has dramatically improved the prognosis of aHUS and affected women in the childbearing age are more likely to consider pregnancy, even if this could represent a risk for disease reactivation. Pregnancies in women with aHUS during Eculizumab treatment have been reported, with no cases of aHUS relapse.





**Case Report:** We report the case of a female patient affected by aHUS with no specific gene mutations who had a pregnancy-associated aHUS relapse at 26-weeks of gestation during maintenance Eculizumab treatment. The patient developed stage II acute kidney injury and microangiopathic hemolytic anemia. Delivery by cesarean section at week 27, plasma exchange sessions and several supplemental Eculizumab administrations were required. After appropriate treatment, the patient partially recovered kidney function; the baby had a prolonged stay in the intensive care unit and showed no signs of neurologic damage.

**Conclusions:** Previous reports indicated that pregnancy-related aHUS relapses were unlikely in women undergoing Eculizumab treatment. Based on our case, we suggest caution in counselling pregnancy in women with aHUS treated with Eculizumab, especially in the absence of pathogenic mutations in complement-regulating genes. Clinicians should be aware of possible aHUS relapse in pregnancy during Eculizumab treatment.

**MeSH Keywords:** Complement Inactivating Agents • Hemolytic-Uremic Syndrome • Pregnancy

**Abbreviations:** aHUS – atypical hemolytic uremic syndrome; TMA – thrombotic microangiopathy; PEX – plasma exchange; PNH – paroxysmal nocturnal hemoglobinuria; LDH – lactate dehydrogenase; CFH – complement factor H; MCP – membrane cofactor protein; CFI – complement factor I; CFB – complement factor B; THBD – thrombomodulin; CKD – chronic kidney disease; AKI – acute kidney injury

**Full-text PDF:** <https://www.amjcaserep.com/abstract/index/idArt/916994>

 2350  1  1  26



## Background

Atypical hemolytic uremic syndrome (aHUS) is a genetic disorder caused by defects in regulation of the complement cascade [1]. Uncontrolled activation of the complement system leads to systemic thrombotic microangiopathy (TMA) [2]. Endothelial damage typically affects renal microvasculature; nevertheless, other organs can also be involved [3]. Atypical hemolytic uremic syndrome can occur at any age. Prognosis prior to currently available treatments have been reported to be poor with more than 50% of patients dying or reaching end stage renal disease within 3 to 5 years from onset [4].

Plasma exchange (PEX) or infusion has long been considered the gold standard treatment for aHUS [3]. Starting from 2009, Eculizumab, a recombinant humanized monoclonal antibody which binds with high affinity to C5 blocking the generation of pro-inflammatory C5a and C5b-9, has been used in patients with aHUS [5]. Eculizumab inhibits complement-mediated TMA and has been associated with significant time-dependent improvement in renal function in patients with aHUS [2].

Disease penetrance of aHUS is highly incomplete, and a pathogenic mutation can be identified in only 40–60% of cases [6]. The clinical expression of the condition is commonly triggered by infections and pregnancy [7]. Since pregnancy can be a cause of TMA reactivation, it has traditionally been discouraged in women with aHUS [7,8]. However, the availability of Eculizumab has dramatically improved the outcomes of aHUS, and affected women in the childbearing age are more likely to consider pregnancy.

Eculizumab has been used during pregnancy in women with paroxysmal nocturnal hemoglobinuria (PNH) [9]. Very scarce reports support its use in pregnancy in women with aHUS, and little is known about fetal and maternal outcomes.

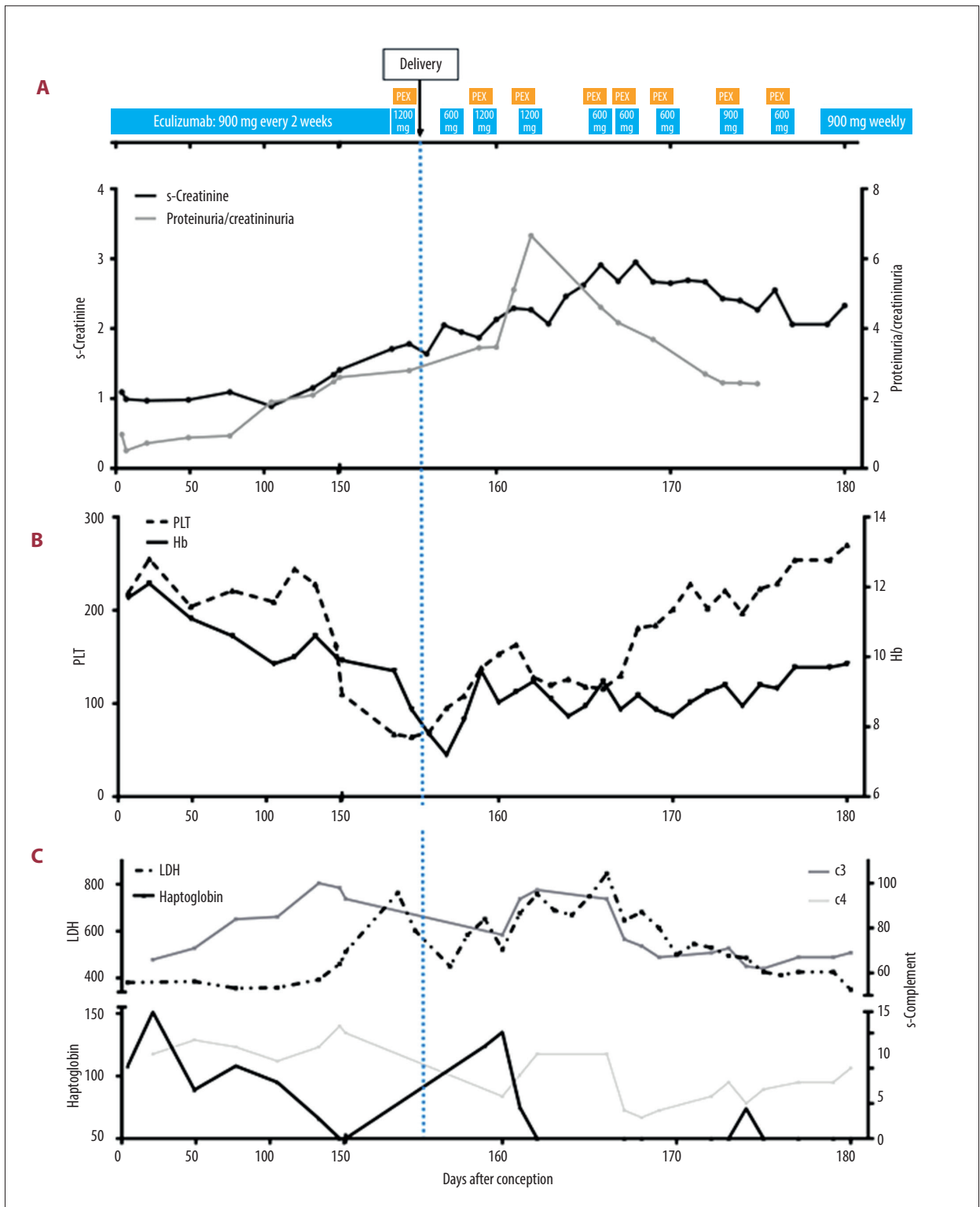
## Case Report

We report the case of a young Caucasian female diagnosed with aHUS at the age of 28 years. She had been previously healthy, and she had no family history for TMA. She initially presented to the emergency department with hemoptysis and arterial hypertension. Her laboratory examinations showed anemia (hemoglobin 9.2 g/dL), decreased platelet count (14 000/uL), increased lactate dehydrogenase (LDH) levels (3600 U/L), elevated serum creatinine (1.68 mg/dL), and reduced C3/C4 levels (73/6 mg/dL). ADAMST-13 activity was normal, and no antibodies directed against ADAMST-13 were encountered. She had no history of diarrhea, and stool cultures for bacteria were negative. A diagnosis of aHUS was suspected, and plasma exchange was immediately started and

then continued on a daily basis, with improvement in hematological parameters. Since worsening kidney function (serum creatinine reached 2.37 mg/dL for eGFR 27 mL/minutes estimated with CKD-EPI equation) and proteinuria were observed, a kidney biopsy was performed; histological analysis showed a picture of TMA. After 22 PEX sessions and completion of appropriate vaccination schedule, the patient was started on intravenous Eculizumab (600 mg every week for 1 month, then 900 mg every 2 weeks). Dramatic clinical improvement was observed: platelet count normalized, signs of hemolysis gradually disappeared (normal serum LDH and haptoglobin levels) and kidney function recovered. Genetic analysis was performed with Next Generation Sequencing. No mutations predisposing to aHUS were encountered in CFH (complement factor H), MCP (membrane cofactor protein), CFI (complement factor I), C3, CFB (complement factor B), and THBD (thrombomodulin) genes. Nevertheless, she was determined to be a carrier of 2 polymorphisms in CFH and one in MCP genes, which are more frequently observed in aHUS patients.

The patient was maintained on 900 mg Eculizumab infusion every 2 weeks. Her clinical picture remained stable with no signs of hemolysis, normal platelet count, only moderate complement consumption, mild kidney dysfunction with chronic kidney disease (CKD) stage II (eGFR 60–75 mL/minutes estimated with CKD-EPI equation), and proteinuria/creatininuria around 0.5. Arterial hypertension was successfully treated with a combination of drugs including a renin inhibitor.

At 42 months from the initiation of Eculizumab, the patient became pregnant. As depicted in Figure 1, her serum creatinine decreased to a nadir of 0.8 mg/dL at 20 weeks of gestation, and then stabilized at 1.1 mg/dL; her proteinuria/creatininuria levels increased up to 2; her serum complement levels remained substantially stable, and there were no signs of intravascular hemolysis (normal platelet count, lactate dehydrogenase levels, haptoglobin levels). She developed worsening hypertension despite multiple drugs combination treatment starting from 26 weeks of gestation, and therapy was adjusted; from the 20<sup>th</sup> week, she complained about peripheral edema. A diagnosis of pre-eclampsia superimposed on chronic pre-existing hypertension and CKD was made. Since no features of severe pre-eclampsia were present, a conservative management was attempted. Fetal weight and length were appropriate for gestational age, with no evident organ abnormalities on ultrasound. Starting from 26 weeks of gestation, a decrease in serum haptoglobin was detected at the laboratory examinations. At the end of the 26<sup>th</sup> week of gestation, she noted worsening of peripheral edema and urine output reduction and was admitted to the obstetric ward. Blood pressure was 140/100 mmHg. Laboratory tests showed acute kidney injury (AKI) stage II according to AKI classification [10] (serum creatinine 1.67 mg/dL), anemia, high serum LDH, and low platelet.



**Figure 1.** Trends of serum creatinine (A, dark-grey line), proteinuria/creatininuria (A, light grey line), platelets (B, dashed black line), hemoglobin (A, continuous black line), serum C3 (C, dark-grey line), serum C4 (C, light-grey line), and serum lactate dehydrogenase (C, dashed black line) during pregnancy. PLT – platelets; Hb – hemoglobin; LDH – lactate dehydrogenase.

Eculizumab was administered at the dose of 1200 mg; induction of fetal pulmonary maturation was started. On day 27 weeks+0, after a PEX session, a cesarean section was performed and the patient delivered a low birth weight premature male baby (weight 827 grams) normal for gestational age, who was immediately transferred to the intensive care unit. The patient developed worsening AKI (zenith serum creatinine 2.7 mg/dL). She maintained reduced serum C3 and C4 levels, and low serum haptoglobin. In the following days, the patient was treated with 8 PEX sessions and administration of supplemental Eculizumab after every session, as reported in Figure 1. The clinical picture started to improve with resolution of the hemolysis and slow improvement of renal function. After discharge, treatment was continued with weekly Eculizumab infusion at the dose of 900 mg. At 1 month from delivery, the patient is doing well, her serum creatinine was 1.6 mg/dL for an eGFR of 42 mL/minute (CKD-EPI), proteinuria/creatininuria was 0.66, serum C3/C4 were 81/18 mg/dL, hemoglobin was 11.1 g/dL, platelets and haptoglobin were normal. The baby had a prolonged stay in the intensive care unit. He showed no signs of neurologic damage and he was included in a specific follow-up program.

## Discussion

Pregnancy in patients with aHUS represents a challenge to the clinician, given the high risk of TMA reactivation and other complications. Current consensus states that each pregnancy should be considered individually and carefully planned [11]. Indeed, overall knowledge on the ideal care in these patients is scarce. Pregnancy always represents a potential trigger for TMA relapse in women with aHUS, as *per se* elicits complement activation. Complement mediated immune attack can occur at the placental level with the potential risk of fetal damage. Moreover, during delivery, inflammation, release of fetal cells, infections, and hemorrhage can lead to systemic activation of the alternative complement pathway [12].

Eculizumab has been used in pregnant patients with PNH, with excellent results [9]. Preliminary data from PNH patients suggest that its use might be safe, at least in the short term, for the fetus [13].

We searched PubMed database for English language reports from inception until February 2018 using the following search terms: “Eculizumab” AND “hemolytic uremic syndrome” AND “pregnancy”.

Literature data about the positive use of Eculizumab for the treatment of pregnancy-associated aHUS appear quite solid [14]. Furthermore, Ardissino et al. [7] reported a case of a 26-year-old woman with aHUS due to a homozygous

mutation in CFH, previously treated with PEX, who developed a relapse of aHUS at 17 weeks of gestation. She was treated with Eculizumab from 26 weeks of gestation and eventually gave birth to a healthy female baby by cesarean section.

There is scarce available data about pregnancy in women previously diagnosed with aHUS and on maintenance treatment with Eculizumab. Servais et al. [8] reported 5 pregnancies in 3 patients with aHUS with ongoing Eculizumab treatment. All 3 patients had a mutation in complement genes responsible for aHUS (1 heterozygous CFH mutation, 1 heterozygous C3 mutation, and 1 heterozygous CFI mutation plus a rare C3 variant). For all 3 patients, births occurred by cesarean section between 29 and 34 weeks of gestation. The authors reported 1 in utero death and 2 cases of fetal growth retardation. In addition, 2 neonates had prolonged hospital stay. Of note, the only fetal death occurred in a pregnancy where the mother had advanced CKD (stage IV, eGFR 28 mL/minute). Described maternal complications included 1 case of HELLP syndrome and 2 cases of pre-eclampsia; no relapses of aHUS were reported in the post-partum period. The authors reported to have increased Eculizumab dose in all pregnancies in response to incomplete C5 inhibition (estimated by measurement of complement activity enzyme) or elevation of CH50. Although Eculizumab might cross the placenta, its levels should not be high enough to block complement cascade. Eculizumab was not detected in umbilical cords or neonate plasma samples in 2 of the patients described in their study [8]. Recently, a successful pregnancy in a kidney transplantation patient who was receiving maintenance Eculizumab for aHUS has been reported [15]. In that case, moderate pre-eclampsia and fetal growth faltering were present from week 28 of gestation, and a cesarean delivery was scheduled at week 32 of gestation.

Our patient had a spontaneous pregnancy during maintenance Eculizumab treatment with normal fetal development, complicated by pre-eclampsia by week 20 of gestation and aHUS relapse at week 26 of gestation. A form of pre-eclampsia with severe features and HELLP syndrome were considered the differential diagnosis [16,17]; nevertheless, the previous history of aHUS and the absence of elevation of ALT/AST enzymes oriented the diagnosis towards an aHUS relapse. She had several risk factors for the development of pre-eclampsia, namely pre-existing hypertension [18] and chronic kidney disease [19]. Given the lack of signs of TMA, she was initially maintained throughout the first 26 weeks of pregnancy with her usual Eculizumab dose (900 mg intravenously every 2 weeks). After detection of TMA reactivation, she was treated with supplemental Eculizumab, PEX, and immediate cesarean delivery.

Unfortunately, we could not measure complement activity or Eculizumab blood levels in our patient. Nevertheless, although CH50 activity has been directly related to intravascular

**Table 1.** Data from 6 pregnancies during eculizumab treatment in women with aHUS.

Pregnancy	Author	Age (years)	Time from Eculizumab start and pregnancy (months)	s-Creatinine [mg/dL], (eGFR [mL/min]) before pregnancy	s-Creatinine [mg/dL] during pregnancy	pr/cr during pregnancy	s-Creatinine [mg/dL] at delivery	pr/cr at delivery	Fetal (neonatal) complications	Birth weight (g)	Maternal complications
1	Servais et al. [8]	31	6	1.9 (32)	1.5	N.a.	1.9	1.5	(Prolonged hospital stay)	1550	HELLP syndrome
2	Servais et al. [8]	33	18	1.6 (40)	1.3	N.a.	1.3	0.8		2500	
3	Servais et al. [8]	29	12	1.5 (45)	1.4	N.a.	2.7	6.8	Growth retardation (prolonged hospital stay)	1410	
4	Servais et al. [8]	26	12	2.3 (28)	n.a.	N.a.			In utero death		Pre-eclampsia
5	Servais et al. [8]	27	17	2.2 (29)	1.8	N.a.	1.9	1.3	Growth retardation	1070	Pre-eclampsia
6	Fontana et al.	31	42	1.2 (60)	0.89 (86)	1.9	1.78	2.8	(Prolonged hospital stay)	827	Pre-eclampsia, aHUS relapse

pr/cr – proteinuria/creatininuria. Fetal growth retardation defined as fetal size below 10<sup>th</sup> percentile.

hemolysis and circulating free Eculizumab levels in patients with PNH [20], there is no definitive prove that its measurement can predict a relapse of aHUS [21,22], and its levels has been reported to be not reliable to tailor Eculizumab optimization [23]. Furthermore, CH50 levels gradually increase during pregnancy from 10% to 50%, complicating its correct interpretation in this context [12,24]. It is possible that our patient had inadequate complement blockage due to altered pharmacokinetics of Eculizumab during pregnancy, related to modifications in total plasma volume, plasma protein, and organ blood flow. We believe that, based on our negative experience, therapeutic drug monitoring of Eculizumab will be fundamental in future similar cases in order to ensure adequate maintenance treatment [25].

Cumulative available data on pregnancy during Eculizumab treatment in aHUS are summarized in Table 1. Median time from start of Eculizumab treatment to pregnancy according to available reports was 18 months.

Eculizumab treatment apparently prevents relapse of aHUS during and immediately after pregnancy in women with known complement-regulating genes mutations, even though current knowledge is based only on isolated case reports. Possibly, an increase in the maintenance dose of Eculizumab during pregnancy and immediately after delivery could be warranted, although data robust enough to define a clear recommendation are lacking.

On the other hand, we report the first case of aHUS relapse in a pregnant woman in maintenance treatment with Eculizumab. It should be noted that the patient had no pathogenic mutation for aHUS in complement-regulating genes. It is widely known

that aHUS can be explained by the presence of specific mutations in complement genes only in 40–60% of cases [6], and Eculizumab treatment is generally used with proved efficacy in patients with a diagnosis of aHUS with no specific gene mutation [2]. Given the rarity of the condition itself, the paucity of data about pregnancy in these patients and the difficulty in performing clinical trials in this setting, we believe that it is important to report the association of aHUS without specific gene mutation and pregnancy-associated relapse of TMA despite maintenance Eculizumab administration.

Women with aHUS in maintenance treatment with Eculizumab present a high risk for eclampsia and HELLP syndrome. In the absence of clear signs of ongoing TMA, mechanisms leading to pre-eclampsia and its related syndrome are possibly unconnected to complement activation and might be secondary to pre-existing CKD. Indeed, women with kidney dysfunction are known to be at higher risk for pre-eclampsia, eclampsia, and HELLP [19]. Pregnancies in women with aHUS treated with Eculizumab appear to be at risk for fetal growth restriction and intrauterine death. These complications could be attributed to pre-existing kidney dysfunction, as the association between intrauterine growth retardation, poor fetal outcome and maternal CKD is well known [19].

There is no information available about long-term effects of maternal Eculizumab administration during pregnancy in neonates and infants; nevertheless, high rates of fetal survival have been reported in pregnancies in patients with PNH treated with Eculizumab [9]. Reassuringly, Eculizumab treatment during pregnancy has been reported to not impair the complement function in the newborn [26].



## Conclusions

In summary, we report the case of pregnancy-associated aHUS relapse in a patient undergoing maintenance Eculizumab treatment. Previous reports of 3 women with aHUS with known complement-regulating genes mutations described no episodes of TMA during pregnancy under maintenance Eculizumab treatment. Our patient had no pathogenic mutations in complement-regulating genes. Clinicians should be aware of possible aHUS relapse in pregnancy during Eculizumab treatment. Monitoring of Eculizumab blood levels and complement activity (CH50) is desirable to guide clinical decisions [25]. However, optimal biomarker for Eculizumab treatment monitor is currently unknown. Also, the lack of evidence of the optimal Eculizumab

dose and administration interval during pregnancy must be considered and addressed in future research. Further studies are needed in order to clarify the association between the absence of known mutations in complement genes and aHUS reactivation in pregnancy during Eculizumab therapy.

## Acknowledgement

We acknowledge Teresa Carbone, RN, for her valuable help in the follow-up of the patient.

## Conflict of interests

None.

## References:

1. Noris M, Remuzzi G: Atypical hemolytic-uremic syndrome. *N Engl J Med*, 2009; 361(17): 1676–87
2. Legendre CM, Licht C, Muus P et al: Terminal complement inhibitor eculizumab in atypical hemolytic-uremic syndrome. *N Engl J Med*, 2013; 368(23): 2169–81
3. Loirat C, Frémeaux-Bacchi V: Atypical hemolytic uremic syndrome. *Orphanet J Rare Dis*, 2011; 6(1): 60
4. Frémeaux-Bacchi V, Fakhouri F, Garnier A et al: Genetics and outcome of atypical hemolytic uremic syndrome: A nationwide French series comparing children and adults. *Clin J Am Soc Nephrol*, 2013; 8(4): 554–62
5. Gruppo RA, Rother RP: Eculizumab for congenital atypical hemolytic-uremic syndrome. *N Engl J Med*, 2009; 360(5): 544–46
6. Bresin E, Rurali E, Caprioli J et al: Combined complement gene mutations in atypical hemolytic uremic syndrome influence clinical phenotype. *J Am Soc Nephrol*, 2013; 24: 475–86
7. Ardissino G, Wally Ossola M, Maria Baffero G et al: Eculizumab for atypical hemolytic uremic syndrome in pregnancy. *Obstet Gynecol*, 2013; 122(2, PART 2): 487–89
8. Servais A, Devillard N, Frémeaux-Bacchi V et al: Atypical haemolytic uraemic syndrome and pregnancy: outcome with ongoing eculizumab. *Nephrol Dial Transplant*, 2016; 31(12): 2122–30
9. Kelly RJ, Höchsmann B, Szer J et al: Eculizumab in pregnant patients with paroxysmal nocturnal hemoglobinuria. *N Engl J Med*, 2015; 373(11): 1032–39
10. Kellum J a, Lameire N, Aspelin P et al: KDIGO clinical practice guideline for acute kidney injury. *Kidney Int Suppl*, 2012; 2(1): 1–138
11. Fakhouri F, Verce C, Frémeaux-Bacchi V: Obstetric nephrology: AKI and thrombotic microangiopathies in pregnancy. *Clin J Am Soc Nephrol*, 2012; 7(12): 2100–6
12. Fakhouri F, Roumenina L, Provot F et al: Pregnancy-associated hemolytic uremic syndrome revisited in the era of complement gene mutations. *J Am Soc Nephrol*, 2010; 21(5): 859–67
13. Kelly R, Arnold L, Richards S et al: The management of pregnancy in paroxysmal nocturnal haemoglobinuria on long term eculizumab. *Br J Haematol*, 2010; 149(3): 446–50
14. Huerta A, Arjona E, Portoles J et al: A retrospective study of pregnancy-associated atypical hemolytic uremic syndrome. *Kidney Int*, 2018; 93(2): 450–59
15. Duval A, Olgne J, Cognard N et al: Pregnancy in a kidney transplant woman under treatment with eculizumab for atypical hemolytic uremic syndrome: Is it safe? *Kidney Int Rep*, 2019; 4(5): 733–39
16. Bruel A, Kavanagh D, Noris M et al: Hemolytic uremic syndrome in pregnancy and postpartum. *Clin J Am Soc Nephrol*, 2017; 12(8): 1237–47
17. Stefanovic V: The extended use of eculizumab in pregnancy and complement activation – associated diseases affecting maternal, fetal and neonatal kidneys-the future is now? *J Clin Med*, 2019; 8(3): pii: E407
18. Roberts JM, Redman CWG, Global Pregnancy Collaboration: Global pregnancy collaboration symposium: Prepregnancy and very early pregnancy antecedents of adverse pregnancy outcomes: overview and recommendations. *Placenta*, 2017; 60: 103–9
19. Wiles KS, Nelson-Piercy C, Bramham K: Reproductive health and pregnancy in women with chronic kidney disease. *Nat Rev Nephrol*, 2018; 14(3): 165–84
20. Peffault de Latour R, Frémeaux-Bacchi V, Porcher R et al: Assessing complement blockade in patients with paroxysmal nocturnal hemoglobinuria receiving eculizumab. *Blood*, 2015; 125(5): 775–83
21. Noris M, Galbusera M, Gastoldi S et al: Dynamics of complement activation in aHUS and how to monitor eculizumab therapy. *Blood*, 2014; 124(11): 1715–26
22. Ardissino G, Tel F, Sgarbanti M et al: Complement functional tests for monitoring eculizumab treatment in patients with atypical hemolytic uremic syndrome: An update. *Pediatr Nephrol*, 2018; 33(3): 457–61
23. Kerboua KE, Haiba F, Batouche D: C3: CH50 ratio as a proposed composite marker for eculizumab monitoring in atypical hemolytic uremic syndrome: Preliminary results. *J Immunoassay Immunochem*, 2017; 38(2): 178–89
24. Girardi G: Complement inhibition keeps mothers calm and avoids fetal rejection. *Immunol Invest*, 2008; 37(5): 645–59
25. Wehling C, Amon O, Bommer M et al: Monitoring of complement activation biomarkers and eculizumab in complement-mediated renal disorders. *Clin Exp Immunol*, 2017; 187(2): 304–15
26. Hallstensen RF, Bergseth G, Foss S et al: Eculizumab treatment during pregnancy does not affect the complement system activity of the newborn. *Immunobiology*, 2015; 220(4): 452–59