

HOSTED BY



ELSEVIER

Contents lists available at ScienceDirect

## The Egyptian Heart Journal

journal homepage: [www.elsevier.com/locate/ehj](http://www.elsevier.com/locate/ehj)

## Original Article

## Tissue characterization of non-culprit intermediate coronary lesions in non ST elevation acute coronary syndromes



Helmy Hassan Elghawaby\*, Mohamed Ashraf Shawky, Ahmed Hossam Mowafi, Akram Mohamed Abd-elbary, Farouk Mostafa Faris

Critical Care Medicine, Faculty of Medicine, Cairo University, Egypt

## ARTICLE INFO

## Article history:

Received 5 December 2016

Accepted 8 May 2017

Available online 16 June 2017

## Keywords:

ACS: Acute coronary syndrome

Intermediate lesions

IVUS: Intravascular ultrasound

Vulnerable plaques

MHz: Mega Hertz

## ABSTRACT

**Background:** Disruption of vulnerable plaques is the most common cause of acute coronary syndromes. Intravascular ultrasound facilitates cross-sectional imaging of coronary arteries. We aimed at using IVUS to investigate the morphology and tissue characteristics of atherosclerotic plaques of non-culprit intermediate coronary lesions in non-ST elevation ACS setting.

**Methods:** IVUS assessment of sixty-one intermediate coronary lesions in twenty-eight patients with the diagnosis of Non ST elevation acute coronary syndromes. Ultrasound signals were obtained by an IVUS system using a 40-MHz catheter.

**Results:** Mean age was  $53.2 \pm 9.1$  years. Males = 20 (71.4%). Smoking in 17 (60.7%), hypertension in 16 (57.1%), Dyslipidemia in 12 (42.9%) and DM in 8 (28.6%). Culprit vessels represent 42% of affected vessels. Sixty-one intermediate lesions were detected. Twenty-nine lesions in culprit vessels and thirty-two lesions in non-culprit vessels with higher lipidic content in lesions of culprit vessels ( $P < 0.001$ ) while a higher calcific content in lesions of non-culprit vessels ( $P < 0.001$ ). Higher calcific content of proximal more than distal lesions ( $P = 0.048$ ). Negative remodeling in 55.7% of lesions.

**Conclusions:** A higher lipidic content in lesions of culprit vessels, while the lesions of non-culprit vessels were more calcific. Higher calcific content of proximal more than distal lesions was defined as well.

© 2017 Egyptian Society of Cardiology. Production and hosting by Elsevier B.V. This is an open access article under the CC BY-NC-ND license (<http://creativecommons.org/licenses/by-nc-nd/4.0/>).

## 1. Introduction

Most acute coronary syndromes are believed to be due to the loss of integrity of a protective covering over an atherosclerotic plaque; this occurs with plaque rupture when the fibrous cap overlying the plaque gets disrupted or with erosion when the endothelial lining of the plaque is disturbed. This disruption of the protective covering allows blood to come in contact with the highly thrombogenic contents of the plaque, which promotes the formation of luminal thrombus.<sup>1–3</sup>

Plaque rupture, usually of a precursor lesion known as a 'vulnerable plaque' or 'thin-cap fibroatheroma', is the leading cause of thrombosis. Less-frequent aetiologies are erosion and eruptive calcified nodules, which are occasionally identified in older individuals.<sup>4</sup>

Pathologic intimal thickening is characterized by extracellular lipid pools rich in hyaluronan and proteoglycans with the absence

of smooth muscle cells and inflammatory cells. The lipid pools tend to develop in the deeper intimal layers near the arterial media. Early calcification is frequently observed within the areas of lipid pools and likely results from the death of smooth muscle cells. Pathologic intimal thickening along with fibro-atheromas can be considered a prelude to plaque erosion.<sup>5</sup>

Postmortem studies have shown that coronary thrombi superimposed on eroded plaques contains a higher density of myeloperoxidase-positive cells than thrombi superimposed on ruptured plaques. It is hypothesized that a selective accumulation of hyaluronan and proteoglycans in eroded plaques may promote de-endothelialization and platelet thrombus formation along with accumulation of circulating neutrophils and monocyte-expressing myeloperoxidase, which may further lead to endothelial cell death and thus promote thrombus formation.<sup>6,7</sup>

It became apparent that 2 key processes are involved in the growth of advanced plaques: (1) outward expansion of the arterial wall and (2) subclinical plaque rupture of hemodynamically insignificant lesions, where the thrombus is incorporated into the lesion, resulting in greater luminal narrowing.<sup>8</sup>

Peer review under responsibility of Egyptian Society of Cardiology.

\* Corresponding author.

E-mail address: [elghawaby@yahoo.com](mailto:elghawaby@yahoo.com) (H.H. Elghawaby).

<http://dx.doi.org/10.1016/j.ehj.2017.05.003>

1110-2608/© 2017 Egyptian Society of Cardiology. Production and hosting by Elsevier B.V.

This is an open access article under the CC BY-NC-ND license (<http://creativecommons.org/licenses/by-nc-nd/4.0/>).

Intravascular ultrasound (IVUS) provides detailed qualitative and quantitative cross-sectional coronary imaging and provides a more comprehensive assessment of the atherosclerotic plaques with a high sensitivity and specificity for detecting intracoronary calcium.<sup>9</sup>

Also, IVUS has been shown to detect features associated with plaque vulnerability, such as an eccentric pattern; the presence of an echolucent core, probably representing the lipid-rich core; the presence of thrombi<sup>10–13</sup>; lumen narrowing<sup>12</sup>; and a spotty pattern of calcifications.<sup>14</sup>

## 2. Aim of the work

To define tissue characteristics of atherosclerotic plaques of non-culprit intermediate coronary lesions in patients with non ST segment elevation acute coronary syndromes.

## 3. Patients and methods

This observational study analyzed tissue characteristics of non-culprit intermediate coronary lesions of culprit and non-culprit vessels in patients with unstable angina pectoris and non ST elevation MI who underwent coronary angiography preparatory for percutaneous coronary intervention (PCI). The study was conducted at the Critical Care Department, Cairo University.

Twenty-eight patients were enrolled from January 2014 to June 2015. The institutional ethics committee approved the protocol, and informed consent was obtained from all patients.

Exclusion criteria were acute myocardial infarction specifically ST elevation myocardial infarction (STEMI), cardiogenic shock, bleeding disorders, previous CABG, instent restenosis and renal impairment.

Coronary angiography was performed within 24–72 h after the onset of ACS. The diagnostic angiograms were obtained using Digital Imaging and Communications in Medicine (DICOM)-compatible digital systems: Siemens AG model No. 07555126, Germany & Philips CV20, Netherland.

Culprit vessel was defined as the coronary artery underlying the atherosclerotic event identified by the association of pre and inter-crisis electrocardiographic changes and echocardiographic left ventricular segment kinetics anomalies.

We used intravascular ultrasound iLab TM System 1.2 Ultrasound Imaging System 90539386-01A, 2009 – Boston Scientific Corporation – USA. Imaging was performed using a 40 MHz, 6 F compatible catheters (ATLANTIS SR Pro) to characterize the coronary arterial tissue.

An intracoronary nitroglycerin was administered for the prevention of coronary spasm. Images were captured at an interval of 0.5 mm using a motorized pull-back system. Then the segment with the minimum lumen area was evaluated in each plaque.

The measurements were performed according to the guidelines of the American College of Cardiology for the acquisition, measurement and reporting of IVUS studies<sup>15</sup> by two experienced IVUS readers. In the conventional IVUS analysis, cross-sectional images were quantified for lumen cross-sectional area (LCSA), external elastic membrane (EEM) cross-sectional area (CSA), atheroma CSA and plaque burden using the software included with the IVUS system.

Qualitative assessment showed either soft (echolucent) plaques, fibrous plaques, calcific plaques and mixed Plaques.<sup>15</sup>

After acquisition of the color-coded maps, the percentage fibrous area (fibrous area/plaque area), the percentage lipid area (lipid area/plaque area) and the percentage calcific area were automatically counted by use of commercially available computer software (iMAP).

The remodeling index was defined as the ratio of EEM CSA at the measured lesion (minimum luminal site) to reference EEM CSA (the average of the proximal and distal reference segments). Remodeling index > 1 means positive remodeling while Remodeling index < 1 means negative remodeling<sup>15</sup>

### 3.1. Statistical analysis

Precoded data were entered on the computer using “Microsoft Office Excel Software” program (2010) for windows. Data were then transferred to the Statistical Package of Social Science Software program, version 21 (SPSS) to be statistically analyzed. Data were summarized using mean, standard deviation, median and inter quartile range for quantitative variables and frequency and percentage for qualitative ones. Comparison between groups was performed using independent sample *t*-test or one way ANOVA with Tukey's post hoc test for quantitative variables and Chi-squared or Fisher's exact test for qualitative ones. P values less than 0.05 were considered statistically significant, and less than 0.01 were considered highly significant.

## 4. Results

This study included twenty-eight patients with the diagnosis of non ST elevation acute coronary syndromes with the following demographic and clinical data as shown in Table 1.

Culprit vessels represent 42.1% while non-culprit vessels represent 57.9% of total affected vessels. Visual assessment and quantitative coronary angiography showed 61 non-culprit intermediate lesions. 30 lesions were present in the proximal segments, 23 lesions in the midsegment and 8 lesions in the distal segments of the affected vessels. 29 lesions in culprit vessels and 32 lesions in non-culprit vessels.

Quantitative assessment of intermediate lesions by IVUS is shown in Table 2

Interestingly, IVUS showed statistically significant higher lipidic content in lesions of culprit vessels ( $P < 0.001$ ) while there was a statistically significant higher calcific content in lesions of non-culprit vessels ( $P < 0.001$ ) as in Fig. 1.

**Table 1**  
Clinical and demographic data of study population.

	Range	Mean ± SD
Age	35–71	53.2 ± 9.1 years
Body mass index	19–31	23.4 ± 2.9
TIMI risk score	1–6	3.1 ± 1.4
Laboratory results		
Hemoglobin (gm%)	10–15	12.4 ± 1.7
Creatinine (mg/dl)	0.6–1.6	1.0 ± 0.2
Cholesterol (mg/dl)	130–246	175.1 ± 30.4
	Frequency (n=28)	Percentage
<i>Gender</i>		
Male	20	71.4
Female	8	28.6
<i>Risk factors</i>		
Smoking	17	60.7
Diabetes Mellitus	8	28.6
Hypertension	16	57.1
Dyslipidemia	12	42.9
+ve family history	6	21.4
<i>History of CAD</i>		
Previous MI	10	35.7
Previous PCI	14	50
<i>Clinical diagnosis</i>		
Unstable angina	23	82.1
NSTEMI	5	17.9

**Table 2**  
Quantitative IVUS measurements of intermediate lesions structure.

Component percentage (%)	Range	Mean ± SD
Fibrotic	39.0–71.0	52.5 ± 6.56
Lipidic	10.0–36.0	22.9 ± 6.58
Necrotic	7.0–21.0	13.4 ± 3.41
Calcific	2.0–32.0	11.1 ± 6.44

Post hoc Tukey test revealed that the lesions in the proximal segments of the coronary vessels had significantly higher calcific content than the lesions in distal segments ( $P = 0.048$ ) as shown in Fig. 2.

Negative remodeling had been shown in 34 lesions (55.7%) and positive remodeling in 27 lesions (44.3%).

Figs. 3 and 4 show examples of the lesions included in the study.

**5. Discussion**

Many techniques for the tissue characterization of plaque composition have been developed using mathematical analyses of ultrasound signals.<sup>16</sup>

There are several reports showing the details of the plaques that caused acute coronary syndrome by use of conventional IVUS. It was reported that 30% of ruptured plaques were hypo-echoic, 31% hyperechoic, and 39% mixed plaque.<sup>16</sup>

Several studies of acute coronary syndrome patients showed that the incidence of plaque rupture, plaque erosion, and calcified nodule was 64.3%, 26.8%, and 8.0%, respectively. Plaque erosion and calcified nodules had more fibrous plaque ( $p < 0.001$  and  $p < 0.001$ ) and less thin-cap fibroatheroma ( $p < 0.001$  and  $p < 0.001$ ).<sup>2,17–20</sup>

The concept of lesion vulnerability has changed the clinical approach to diagnosing and treating coronary artery disease, since the odds of an adverse event are not directly related to the severity of coronary artery stenosis.<sup>21,22</sup>

Despite its sectional design, the present study illustrates the morphological difference of intermediate lesions of culprit and non-culprit vessels, as lesions of culprit vessels showed significantly higher lipidic content with significantly lower calcific content than lesions in non-culprit vessels.

These results goes in hand with the study done by Yamagishi et al.<sup>10</sup> who examined 12 intermediate coronary lesions in ACS patients showed an echolucent zone within the plaque in 10 of 12 sites. A calcified plaque was present at five coronary sites.

On the contrary, In Pundziute et al.<sup>23</sup>, 97 Coronary plaques were examined by IVUS in 25 ACS patients. Structure of these lesions

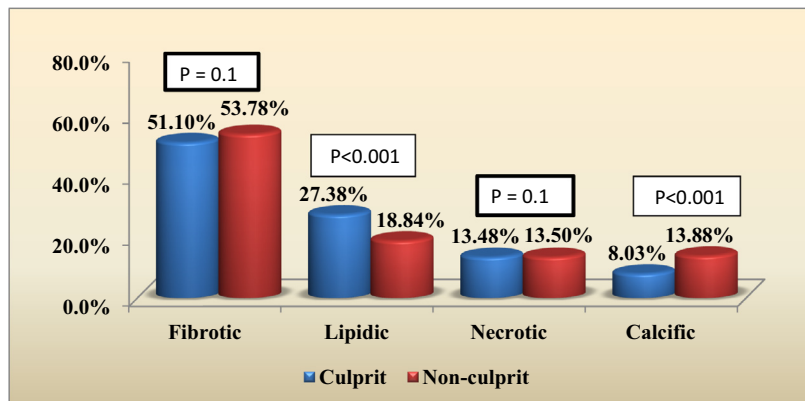


Figure 1. Lesions structure in culprit and non-culprit vessels.

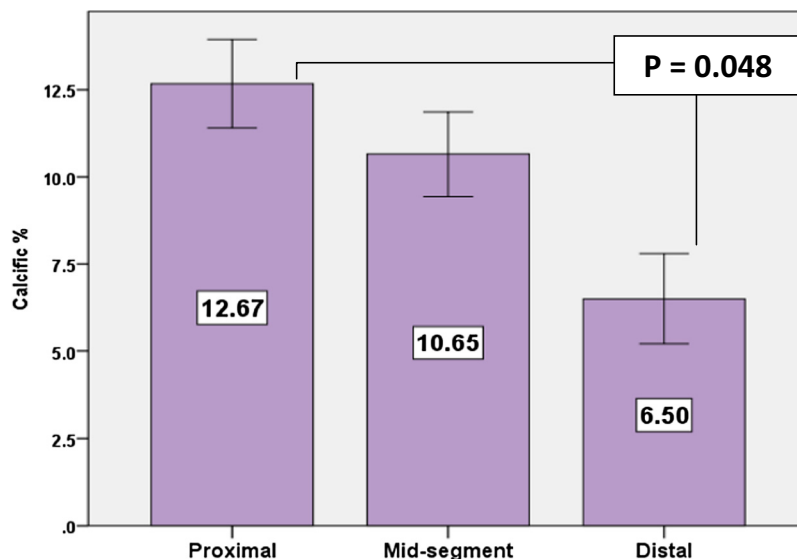


Figure 2. Structure of lesions in different coronary segments.

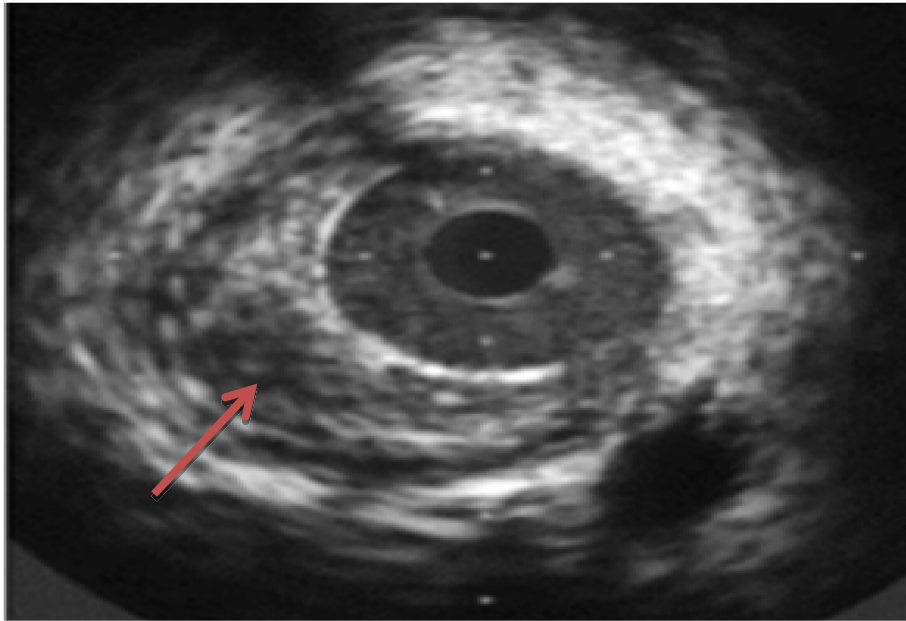


Figure 3. Intermediate lesion with high lipid content.

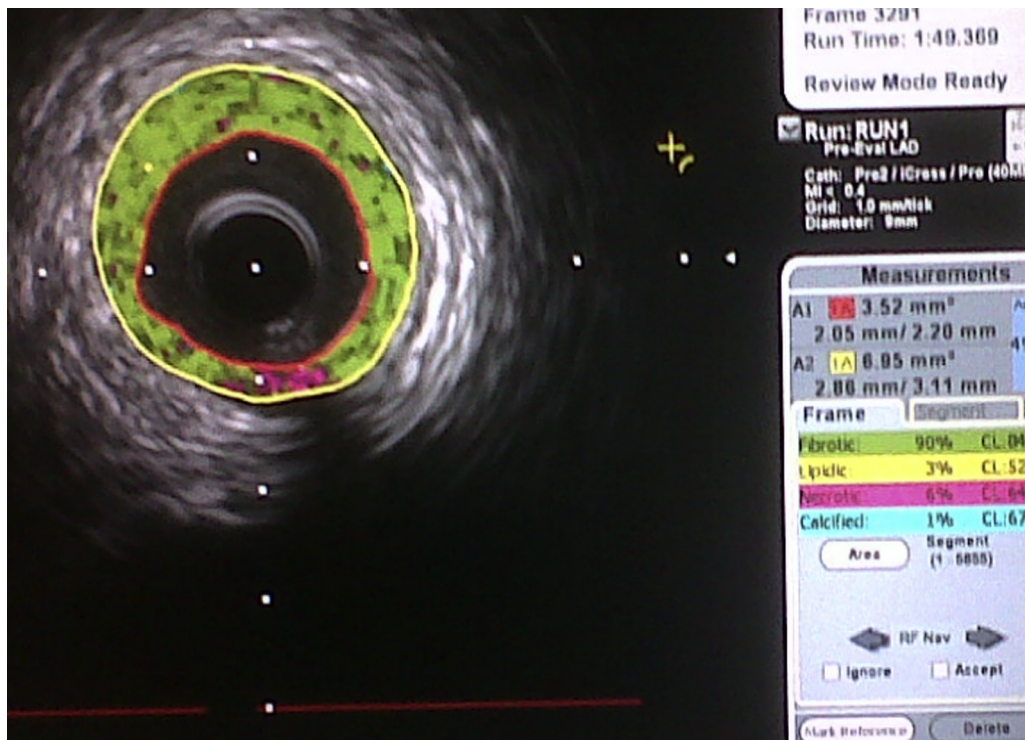


Figure 4. Color coding (iMAP) of one of lesions.

showed more fibrotic structure than fatty content followed by less necrotic and calcific components. Also, no differences were observed between plaque composition in culprit and non-culprit arteries on VH IVUS. Plaques of the two groups of arteries showed no differences in the amount of fibrotic tissue, fibro-fatty tissue, dense calcium and necrotic core. This may be due to the use of different devices with different technology and subsequent specificity and sensitivity.

The tendency of advanced plaques to develop preferentially in the proximal locations of coronary arteries has been explained by

the low shear stress conditions generated in areas with tortuosity or many branches. Low shear stress may induce the migration of lipid and monocytes into the vessel wall leading to the progression of the lesion toward a plaque with high risk of rupture.<sup>24</sup>

In our study, most of lesions were located in the proximal segments of the examined arteries [30 lesions (49.2%)]. Other studies confirm this assumption as follows:

In Koo et al.<sup>25</sup>, 85 lesions (32%) out of 267 intermediate lesions were located more often in proximal segments of the coronary arteries.

In Fernandes et al.<sup>26</sup>, 53 lesions (90%) of total 59 intermediate lesions were located in proximal segments of the arteries.

In a human autopsy study, Cheruvu et al.<sup>27</sup> reported that 50% of TCFAs were present within the first 22 mm of the left anterior descending and left circumflex arteries and the first 31 mm of the right coronary artery.

In another ex vivo study using histology, IVUS, and OCT, Kume et al.<sup>28</sup> reported that 70% of TCFAs clustered in the first 30 mm of a coronary artery.

In a 3-vessel grayscale IVUS study, Hong et al.<sup>29</sup> evaluated the axial location of plaque rupture in 392 patients; plaque ruptures occurred mainly in proximal segments of the left anterior descending coronary artery, the proximal half of the left circumflex, and the proximal and distal segments of right coronary artery.

In a subsequent IVUS analysis, Ando et al.<sup>30</sup> also reported that 83% of TCFAs were located mainly within 40 mm of the coronary ostium.

Recent study showed that all lesions derived from or related to plaque rupture show positive remodeling, which may represent an important surrogate for detecting lesion vulnerability.<sup>8</sup> Conversely, lesions of total occlusion or erosion exhibited negative remodeling.<sup>31</sup>

In our study, most of intermediate lesions showed negative remodeling.

This is consistent with the results of Fernandes et al.<sup>26</sup> and Koo et al.<sup>25</sup> which showed that most of lesions showed negative remodeling.

A recent study of 112 acute coronary syndrome patients, in which both optical coherence tomography and intravascular ultrasound were performed, showed that more than one-half of lesions had negative remodeling.<sup>17</sup>

On the other hand, Yamagishi et al.<sup>10</sup> examined 12 patients with ACS. Positive remodeling was observed in 7 of 12 coronary sites. This may be due to small sample size.

Another clinical study by Motoyama et al.<sup>32</sup> has reported a potential usefulness of CT angiography to identify vulnerable plaques that have not yet ruptured in patients who have not experienced an acute coronary event. Among a total of 1059 patients who underwent CT angiography, positive remodeling was identified in 45 patients. Of the 45 patients, 10 (22.2 percent) developed ACS over a mean follow-up of 27 months. This study suggests that coronary lesions showing positive remodeling on CT angiography are at a higher risk of future acute coronary events.

## 6. Conclusion

We concluded that there is a higher lipidic content in lesions of culprit vessels, while the lesions of non-culprit vessels were more calcific. Higher calcific content of proximal more than distal lesions was defined as well.

## Funding

This research received no specific grant from any funding agency in the public, commercial, or not-for-profit sectors.

## Declaration of conflicting interests

The Authors declare that there is no conflict of interest.

## References

- Virmani R, Kolodgie FD, Burke AP, et al. Lessons from sudden coronary death: a comprehensive morphological classification scheme for atherosclerotic lesions. *Arterioscler. Thromb. Vasc. Biol.* 2000;20:1262.
- Ino Y, Kubo T, Tanaka A, et al. Difference of culprit lesion morphologies between ST-segment elevation myocardial infarction and non-ST-segment elevation acute coronary syndrome: an optical coherence tomography study. *JACC Cardiovasc Interv.* 2011;4:76.
- Kubo T, Tanaka A, et al. Difference of culprit lesion morphologies between ST-segment elevation myocardial infarction and non-ST-segment elevation acute coronary syndrome: an optical coherence tomography study. *JACC Cardiovasc Interv.* 2011;4:76.
- Yahagi K, Kolodgie FD, Otsuka F, et al. Pathophysiology of native coronary, vein graft, and in-stent atherosclerosis. *Nat Rev Cardiol.* 2016;13:79.
- Kolodgie FD, Burke AP, Nakazawa G, Virmani R. Is pathologic intimal thickening the key to understanding early plaque progression in human atherosclerotic disease? *Arterioscler Thromb Vasc Biol.* 2007;27:986.
- Ferrante G, Nakano M, Prati F, et al. High levels of systemic myeloperoxidase are associated with coronary plaque erosion in patients with acute coronary syndromes: a clinicopathological study. *Circulation.* 2010;122:2505.
- Kramer MC, Rittersma SZ, de Winter RJ, et al. Relationship of thrombus healing to underlying plaque morphology in sudden coronary death. *J Am Coll Cardiol.* 2010;55:122.
- Finn Alope V, Nakano Masataka, Narula Jagat, et al. Concept of vulnerable/unstable plaque. *Arterioscler Thromb Vasc Biol.* 2010;30:1282–1292.
- Xu Y, Mintz GS, Tam A, et al. Prevalence, distribution, predictors, and outcomes of patients with calcified nodules in native coronary arteries: a 3-vessel intravascular ultrasound analysis from Providing Regional Observations to Study Predictors of Events in the Coronary Tree (PROSPECT). *Circulation.* 2012;126:537.
- Yamagishi M, Terashima M, Awano K, et al. Morphology of vulnerable coronary plaque: insights from follow-up of patients examined by intravascular ultrasound before an acute coronary syndrome. *J Am Coll Cardiol.* 2000;35:106.
- Kotani J, Mintz GS, Castagna MT, et al. Intravascular ultrasound analysis of infarct-related and non-infarct-related arteries in patients who presented with an acute myocardial infarction. *Circulation.* 2003;107:2889–2893.
- Fujii K, Kobayashi Y, Mintz GS, et al. Intravascular ultrasound assessment of ulcerated ruptured plaques. A comparison of culprit and nonculprit lesions of patients with acute coronary syndromes and lesions in patients without acute coronary syndromes. *Circulation.* 2003;108:2473–2478.
- Hong MK, Mintz GS, Lee CW, et al. Comparison of coronary plaque rupture between stable angina and acute myocardial infarction. A three-vessel intravascular ultrasound study in 235 patients. *Circulation.* 2004;110:928–933.
- Ehara S, Kobayashi Y, Yoshiyama M, et al. Spotty calcification typifies the culprit plaque in patients with acute myocardial infarction: an intravascular ultrasound study. *Circulation.* 2004;110:3424–3429.
- Mintz GS, Nissen SE, Anderson WD, et al. American college of cardiology clinical expert consensus document on standards for acquisition, measurement and reporting of intravascular ultrasound studies. a report of the american college of cardiology task force on clinical expert consensus documents. *J. Am. Coll. Cardiol.* 2001;1478–1492.
- Sano Keiji, Kawasaki Masanori, Ishihara Yoshiyuki, et al. Assessment of vulnerable plaques causing acute coronary syndrome using integrated backscatter intravascular ultrasound. *J. Am. Coll. Cardiol.* 2006;47.
- Higuma T, Soeda T, Abe N, et al. A combined optical coherence tomography and intravascular ultrasound study on plaque rupture, plaque erosion, and calcified nodule in patients with st-segment elevation myocardial infarction: incidence, morphologic characteristics, and outcomes after percutaneous coronary intervention. *JACC Cardiovasc Interv.* 2015;8:1166.
- Hong YJ, Jeong MH, Choi YH, et al. Differences in intravascular ultrasound findings in culprit lesions in infarct-related arteries between ST segment elevation myocardial infarction and non-ST segment elevation myocardial infarction. *J. Cardiol.* 2010;56:15.
- Stone GW, Maehara A, Lansky AJ, et al. A prospective natural-history study of coronary atherosclerosis. *N. Engl. J. Med.* 2011;364:226.
- Kubo T, Maehara A, Mintz GS, et al. The dynamic nature of coronary artery lesion morphology assessed by serial virtual histology intravascular ultrasound tissue characterization. *J. Am. Coll. Cardiol.* 2010;55:1590.
- Naghavi M, Libby P, Falk E, et al. From vulnerable plaque to vulnerable patient: a call for new definitions and risk assessment strategies: Part I. *Circulation.* 2003;108:1664–1672.
- Iglehart JK. Health care on the hill—democrats set the agenda. *N. Engl. J. Med.* 2007;356:1–4.
- Pundziute Gabija, Schuijf Joanne D, Wouter Jukema J, et al. Evaluation of plaque characteristics in acute coronary syndromes: non-invasive assessment with multi-slice computed tomography and invasive evaluation with intravascular ultrasound radiofrequency data analysis. *Eur. Heart J.* 2008;29:2373–2381.
- Di Mario C, Gorge G, Peters R, et al. Clinical application and image interpretation in intracoronary ultrasound. Study group on intracoronary imaging of the working group of coronary circulation and of the subgroup on intravascular ultrasound of the working group of echocardiography of the european society of cardiology. *Eur. Heart J.* 1998;19:207–229.
- Koo Bon-Kwon, Yang Hyoung-Mo, Doh Jun-Hyung, et al. Optimal intravascular ultrasound criteria and their accuracy for defining the functional significance of intermediate coronary stenoses of different locations. *JACC: Cardiovascular Intervention.* 2011;4:803–811.
- Fernandes Marlos R, Silva Guilherme V, Caixeta Adriano, et al. Assessing intermediate coronary lesions: angiographic prediction of lesion severity on intravascular ultrasound. *Journal of invasive cardiology.* 2007;19:412–416.

27. Cheruvu PK, Finn AV, Gardner C, et al. Frequency and distribution of thin-cap fibroatheroma and ruptured plaques in human coronary arteries: a pathologic study. *J Am Coll Cardiol.* 2007;50:940–949.
28. Kume T, Okura H, Yamada R, et al. Frequency and spatial distribution of thin-cap fibroatheroma assessed by 3-vessel intravascular ultrasound and optical coherence tomography: an ex vivo validation and an initial in vivo feasibility study. *Circ J.* 2009;73:1086–1091.
29. Hong MK, Mintz GS, Lee CW, et al. The site of plaque rupture in native coronary arteries: a three-vessel intravascular ultrasound analysis. *J Am Coll Cardiol.* 2005;46:261–265.
30. Ando H, Amano T, Matsubara T, et al. Comparison of tissue characteristics between acute coronary syndrome and stable angina pectoris. An integrated backscatter intravascular ultrasound analysis of culprit and nonculprit lesions. *Circ J.* 2011;75:383–390.
31. Burke AP, Kolodgie FD, Farb A, et al. Morphological predictors of arterial remodeling in coronary atherosclerosis. *Circulation.* 2002;105:297–303.
32. Motoyama S, Sarai M, Harigaya H, et al. Computed tomographic angiography characteristics of atherosclerotic plaques subsequently resulting in acute coronary syndrome. *J Am Coll Cardiol.* 2009;54:49.