

Hepatoid Adenocarcinoma of the Lung Responsive to Frontline Combination Chemotherapy With Immunotherapy: Case Report



Galina G. Lagos, MD,^a Jarett L. Feldman, MD,^b Anjali Saqi, MD, MBA,^c Catherine A. Shu, MD^{a,*}

^aDivision of Hematology/Oncology, Department of Medicine, Columbia University Irving Medical Center, New York, New York

^bHematology and Oncology, Westmed Medical Group, Purchase, New York

^cDepartment of Pathology and Cell Biology, Columbia University Irving Medical Center, New York, New York

Received 14 October 2020; revised 3 December 2020; accepted 6 December 2020

Available online - 16 December 2020

ABSTRACT

Hepatoid adenocarcinoma of the lung (HAL) is a rare extrahepatic tumor characterized by histologic features of hepatocellular carcinoma. The standard treatment for non-resectable HAL has not been established, though traditionally, these tumors have been treated with platinum-based chemotherapy. Here, we report the use of combination chemotherapy and immunotherapy in a patient presenting with metastatic HAL and an elevated alpha-fetoprotein. The patient had an excellent clinical, radiographic, and biomarker response. This case supports the use of chemo-immunotherapy, which is now the standard of care first-line treatment in NSCLC, for HAL.

© 2020 The Authors. Published by Elsevier Inc. on behalf of the International Association for the Study of Lung Cancer. This is an open access article under the CC BY-NC-ND license (<http://creativecommons.org/licenses/by-nc-nd/4.0/>).

Keywords: Hepatoid adenocarcinoma; Chemo-immunotherapy; Tumor mutation burden; Case report

Case Report

A 54-year-old man with a 25-pack-year smoking history presented with several months of cough and dyspnea in March 2020. Computed tomography of the chest, abdomen, and pelvis revealed a right lower lobe mass, multiple right-sided pleural masses, large pleural effusion, extensive lymphadenopathy, and a right fifth rib lytic lesion (Fig. 1). Positron emission tomography scan revealed fluorodeoxyglucose avidity of these lesions, and a left adrenal gland and an inferior right scapular lesion. No liver lesions were identified. Brain

magnetic resonance imaging revealed no evidence of intracranial disease.

He underwent a biopsy of a right pleural mass. Pathologic examination revealed diffuse sheets and solid nests of neoplastic cells with abundant granular cytoplasm and prominent nucleoli. Rare cells had intracytoplasmic vacuoles suggestive of adenocarcinoma. The diagnosis on the basis of morphologic and immunohistochemical (IHC) staining pattern (Table 1 and Fig. 2) was consistent with hepatoid adenocarcinoma (HAC). Programmed death-ligand 1 (PD-L1) expression as measured by the 22C3 pharmDx assay (Dako, Carpinteria, CA) was less than 5%.

FoundationOne CDx (Foundation Medicine) was used for comprehensive genomic profiling (Table 1). The tumor mutation burden (TMB) was 20 mutations per

*Corresponding author.

Disclosure: Dr. Saqi reports receiving personal fees from Genentech/Roche, the American Society of Clinical Oncology, PeerView, and Bristol Myers Squibb and has an issued Medical Apparatus and Method for Collecting Biological Samples patent. Dr. Shu reports receiving personal fees from AstraZeneca, Boehringer Ingelheim, and Genentech. The remaining authors declare no conflict of interest.

Address for correspondence: Catherine A. Shu, MD, Thoracic Medical Oncology, Columbia University Medical Center, Herbert Irving Pavilion, 161 Fort Washington Ave., New York, NY 10032. E-mail: cas2145@cumc.columbia.edu

Cite this article as: Lagos GG, et al. Hepatoid Adenocarcinoma of the Lung Responsive to Frontline Combination Chemotherapy With Immunotherapy: Case Report. JTO Clin Res Rep 2:100130

© 2020 The Authors. Published by Elsevier Inc. on behalf of the International Association for the Study of Lung Cancer. This is an open access article under the CC BY-NC-ND license (<http://creativecommons.org/licenses/by-nc-nd/4.0/>).

ISSN: 2666-3643

<https://doi.org/10.1016/j.jtocrr.2020.100130>

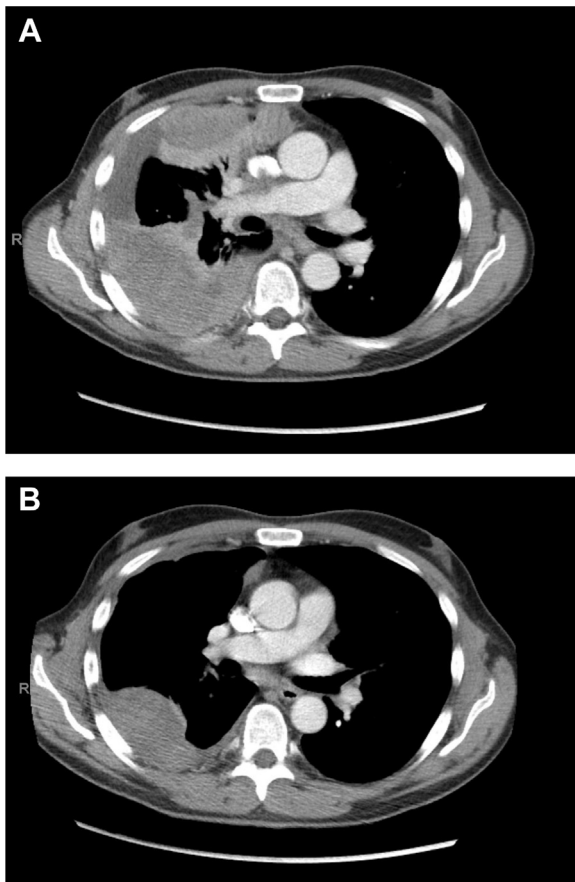


Figure 1. CT scan of the chest with contrast before and during treatment. (A) Baseline scan revealed a 4 cm mass and 2.1 cm nodule in the right lower lobe, multiple right-sided pleural masses measuring up to 14 cm, pleural effusion, and mediastinal and hilar lymphadenopathy. (B) CT scan after three cycles of carboplatin, paclitaxel, and pembrolizumab, which revealed a marked decrease in the pleural-based masses (i.e., 2.8 cm × 2.8 cm, previously 7.6 cm × 5.3 cm) and in the mediastinal lymphadenopathy (i.e., 1.7 cm × 1.3 cm, previously 4.3 cm × 4.1 cm). CT, computed tomography.

megabase. The baseline serum α -fetoprotein (AFP) was 13,702 ng/mL (range: 0.5–8.0 ng/mL).

He started carboplatin, paclitaxel, and pembrolizumab. After three cycles, imaging revealed a marked decrease in the size of the multiple pleural-based nodules and mediastinal lymphadenopathy (Fig. 1). AFP downtrended to 2.1 ng/mL. Clinically, his breathing improved, and treatment was well-tolerated. At the time of article submission, the patient continues on maintenance pembrolizumab and has received treatment for a total of 7 months.

Discussion

HAC are rare tumors of extrahepatic origin with histologic features of hepatocellular carcinoma (HCC). Most arise in the gastrointestinal tract and approximately 5% in the lung.¹ HAC of the lung (HAL) is

Table 1. Immunohistochemistry and Next-Generation Sequencing Results

IHC Stain	Positive	Negative
CK7	P	
CK20	R	
AFP	R	
Hep Par-1	+	
Arginase-1	+	
Glypican-3	P	
CDX-2	+	
MOC31	+	
TTF-1 (nuclear) ^a		-
p40		-
SALL4		-
SMARCA4		-
PD-L1	<5%	
Histochemical Stain		
Mucicarmine	+	
Genomic Alterations from FoundationOne CDx		
CDKN2A L65_H66insL		
MCL1 amplification		
SMARCA4 A562fs ^a 51		
STAG2 E86		
STK11 H107R		
TP53 P142L		
TP53 H179D		
TSC1 Q109		

^aWeak, patchy cytoplasmic TTF-1 staining was noted (clone 8G7G3/1; Roche Diagnostics).

AFP, α -fetoprotein; IHC, immunohistochemical; P, patchy staining; PD-L1, programmed death-ligand 1; R, rare cell.

associated with poor prognosis and heightened mortality. With fewer than 50 HALs reported, limited data exist regarding its epidemiology and optimal treatment. Patients are typically men, heavy smokers, with a median age of 63.6 years, and most are diagnosed at an advanced stage.² Though there are IHC differences between HAC and HCC, such as a lack of CDX-2 staining in HCC, there are insufficient data to conclude that IHC can definitively segregate the two.^{1,3} In addition, positive staining for AFP or elevated serum AFP is common but not required.¹

Most patients with advanced HAL receive first-line platinum-based chemotherapy, although a standard regimen is not established. The reported survival for patients with unresectable HAL has generally been 6 to 11 months. Alternative approaches have included tyrosine kinase inhibitors for patients with driver mutations and sorafenib added to chemotherapy.¹ Immunotherapy has been trialed after progression on chemotherapy. A patient with Lynch syndrome received third-line durvalumab with a partial response after 4 cycles but developed infectious complications.⁴ On progression after adjuvant chemoradiation, another patient received nivolumab but

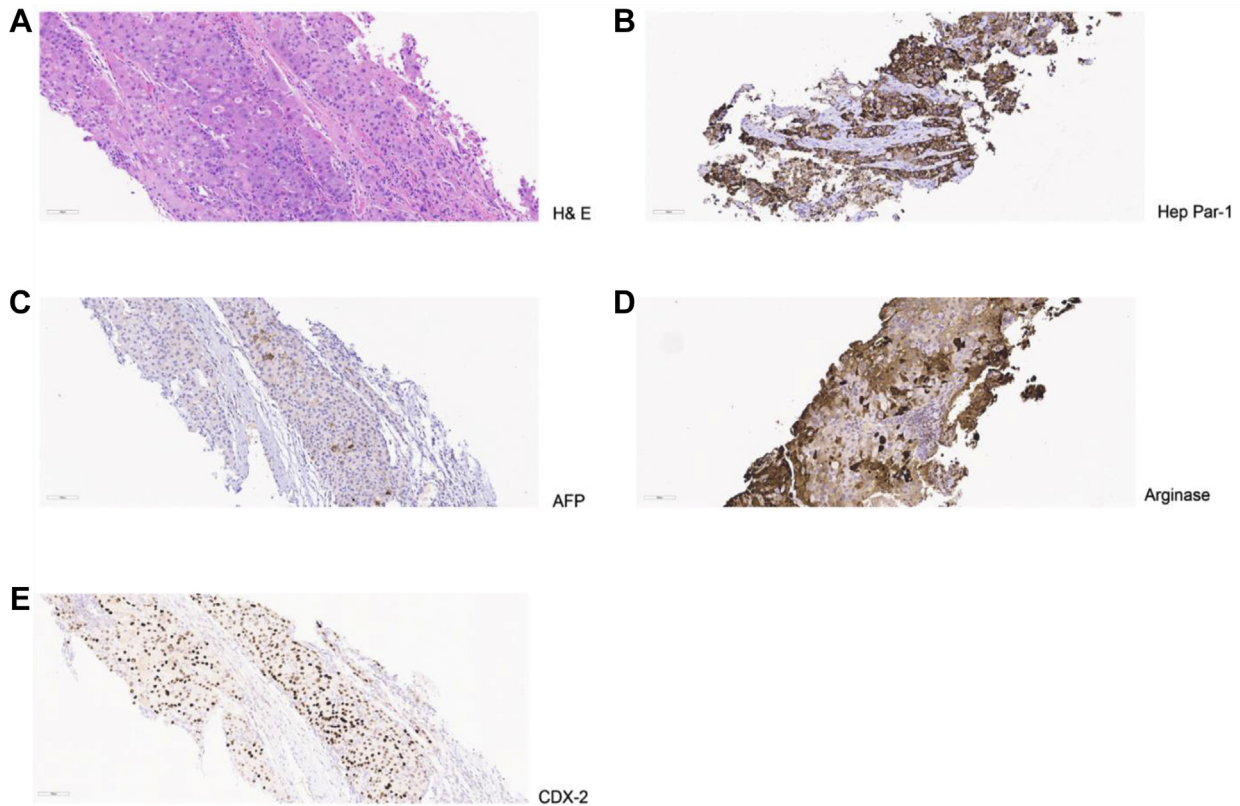


Figure 2. Pathologic findings. (A) H&E ($\times 20$) staining illustrates diffuse sheets and solid nests of neoplastic cells with abundant granular cytoplasm and prominent nucleoli, resembling HCC. Few cells had intracytoplasmic vacuoles suggestive of adenocarcinoma. No bile was seen. Immunohistochemistry is notable for staining with (B) Hep-Par1, (C) AFP, and (D) arginase, which are frequently associated with a hepatocellular origin. (E) CDX-2, which is most often associated with gastrointestinal origin, was diffusely positive. AFP, α -fetoprotein; H&E, hematoxylin and eosin; HCC, hepatocellular carcinoma.

progressed after five cycles.¹ In a third case, pembrolizumab was used for a patient with PD-L1 greater than 50% after frontline chemotherapy, with an initial response but eventual progression after 10 cycles.⁵

To our knowledge, this is the first case to be reported using combination chemotherapy with immunotherapy for HAL. This is especially critical given these combinations have mostly surpassed chemotherapy as the new standard first-line treatment in NSCLC. It is worth noting the patient's disparate serum and IHC AFP, and low PD-L1 and high TMB, which may be the driving force behind his response. Interestingly, SMARCA4-deficient thoracic tumors are often associated with high TMB.⁶ We also note that AFP can be a valuable tumor marker in these cases and may be used to follow-up the response.

Consent

The patient provided informed consent to the publication of this article.

References

1. Tonyali O, Gonullu O, Ozturk MA, Kosif A, Civi OG. Hepatoid adenocarcinoma of the lung and the review of the literature. *J Oncol Pharm Pract.* 2020;26:1505-1510.
2. Ayub A, Nunez Lopez O, Booth A, Okereke I. Pulmonary hepatoid adenocarcinoma. *J Thorac Cardiovasc Surg.* 2019;158:e139-e140.
3. Dabbs DJ. *Diagnostic Immunohistochemistry: Theranostic and Genomic Applications.* 5th ed. Philadelphia, PA: Elsevier; 2018.
4. Basse V, Schick U, Guéguen P, et al. A mismatch repair-deficient hepatoid adenocarcinoma of the lung responding to anti-PD-L1 durvalumab therapy despite no PD-L1 expression. *J Thorac Oncol.* 2018;13:e120-e122.
5. El Khoury A, El Khoury M, De Luca R. Immunotherapeutic approach to a case of advanced hepatoid adenocarcinoma of the lung. *memo.* 2019;12:272-277.
6. Rekhtman N, Montecalvo J, Chang JC, et al. SMARCA4-deficient thoracic sarcomatoid tumors represent primarily smoking-related undifferentiated carcinomas rather than primary thoracic sarcomas. *J Thorac Oncol.* 2020;15:231-247.