



## CASE REPORT

# Non-Invasive Diagnosis of a Facial Tumor Using Dermoscopy and Successful Treatment with 595 nm Pulsed Dye Laser

Ga Ram Ahn, Guk Jin Jeong, Su Jung Park, Kui Young Park, Seong Jun Seo, Hae Woong Lee<sup>1</sup>Department of Dermatology, Chung-Ang University Hospital, Seoul, <sup>1</sup>Louis Dermatology Clinic, Guri, Korea

Clear cell acanthoma (CCA) is an uncommon, benign epithelial tumor presenting as a well-defined, slow-growing solitary nodule. The diagnosis of CCA is usually based on clinical and histopathological evaluation of the tumor. However, when such type of benign tumor occurs on an exposed area, a biopsy is not always the best diagnostic option since it may leave scar. The recent advent of dermoscopy has offered an accurate and non-invasive method to diagnose CCA without resorting to skin biopsy. A 40-year-old male presented with a shiny, erythematous-to-brown, flattened nodule on the left cheek. Dermoscopic examination revealed a 'string of pearls' vascular pattern, a characteristic dermoscopic feature of CCA. Under the clinical and dermoscopic impression of CCA, a 595 nm pulsed dye laser (PDL) therapy targeting the vascular tissue in the superficial dermis of the lesion was chosen for a minimally invasive treatment. After repeated sessions of PDL, an optimal cosmetic outcome was achieved and no recurrence was recorded during the follow-up period. Herein, we report a case of presumed CCA which was successfully diagnosed and treated by utiliz-

ing non-invasive modalities. (*Ann Dermatol* 33(3) 275 ~ 277, 2021)

**-Keywords-**

Clear cell acanthoma, Dermoscopy, Facial acanthoma, Pulsed dye laser

**INTRODUCTION**

Clear cell acanthoma (CCA) usually appears as a shiny, red-colored papule or nodule, ranging in size from 3 to 20 mm. It may be covered with a thin crust and surrounded by a collarette of 'wafer-like' scales. Invasive removal have been preferred such as excision, curettage, electrofulguration, cryotherapy, and CO<sub>2</sub> laser ablation<sup>1</sup>.

When such dermatosis occurs on the face, the patient is likely to be apprehensive about the invasive procedures, like biopsy or an operative removal, which may result in irreversible scarring. Therefore, non-invasive methods for both the diagnostic and treatment processes are especially valuable in such cases. In this report, we describe a patient with CCA who was presumptively diagnosed and treated using the non-invasive modalities of dermoscopy and pulsed dye laser (PDL), respectively.

**CASE REPORT**

A 40-year-old Asian male presented at our clinic with a slowly growing nodule on the left side of his face. The nodule was well-demarcated, 5-mm sized in diameter, shiny erythematous-to-brown colored, and flattened with minimal scaling (Fig. 1A). Since he refused to undergo a biopsy for cosmetic concern, dermoscopy was applied for

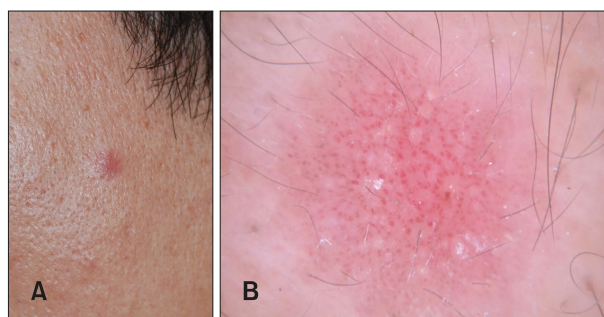
Received May 3, 2019, Revised December 26, 2019, Accepted for publication January 20, 2020

**Corresponding author:** Kui Young Park, Department of Dermatology, Chung-Ang University Hospital, 102 Heukseok-ro, Dongjak-gu, Seoul 06973, Korea. Tel: 82-2-6299-1525, Fax: 82-2-6299-1718, E-mail: kyky@caumc.or.kr  
ORCID: <https://orcid.org/0000-0001-5965-1754>

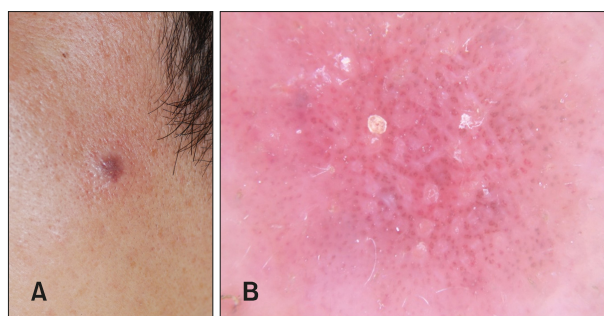
Hae Woong Lee, Louis Dermatology Clinic, 72 Jangja-daero, Guri 11948, Korea. Tel: 82-31-553-7522, Fax: 82-31-553-7522, E-mail: louiskin@naver.com  
ORCID: <https://orcid.org/0000-0001-7688-1172>

This is an Open Access article distributed under the terms of the Creative Commons Attribution Non-Commercial License (<http://creativecommons.org/licenses/by-nc/4.0>) which permits unrestricted non-commercial use, distribution, and reproduction in any medium, provided the original work is properly cited.

Copyright © The Korean Dermatological Association and The Korean Society for Investigative Dermatology



**Fig. 1.** (A) Clinical photograph of the lesion during initial visit. (B) Dermoscopic image of the lesion showing the typical 'string of pearls' vascular pattern, indicating a diagnosis of clear cell acanthoma.

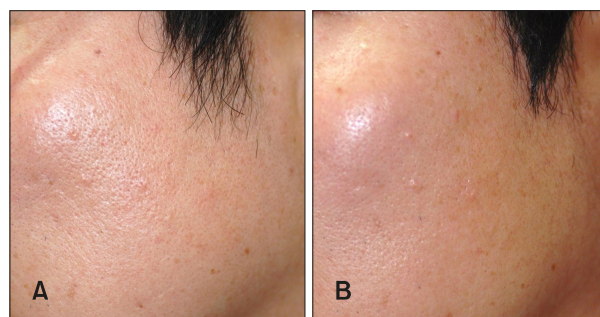


**Fig. 2.** (A) Clinical photograph taken immediately following the pulsed dye laser treatment. (B) Dermoscopic image showing purpuric changes in vascular puncta of the clear cell acanthoma lesion.

detailed examination. On applying slight pressure during the dermoscopic examination, the background blanched to a pinkish-color, and its prominent vascular puncta were defined more clearly, revealing fine red dots with a reticular arrangement ('pearl necklace' or 'string of pearls' pattern) (Fig. 1B). Based on these findings, the lesion was presumptively identified as a CCA.

Considering the patient's concerns about iatrogenic scarring, 595-nm wavelength PDL (Vbeam perfecta<sup>®</sup>; Syneron Inc., San Francisco, CA, USA) was chosen as a treatment modality. The parameters were suitably modulated from initial setting (13 J/cm<sup>2</sup> energy, 20 ms duration), until a mild purpuric response was observed (10 J/cm<sup>2</sup> energy, 3 ms duration) (Fig. 2A). The bright-red colored vascular puncta turned violaceous following PDL therapy (Fig. 2B).

The lesion regressed markedly, and the patient was satisfied with the cosmetic outcome. There was no evidence of recurrence during routine follow-up at 8 and at 26 months after treatment (Fig. 3).



**Fig. 3.** Clinical photograph on routine follow-up. At 8 months (A) and at 26 months (B) after pulsed dye laser treatment.

## DISCUSSION

The characteristic dermoscopic findings of CCA include red dots, globules, and glomeruloid vessels arranged in a linear or serpiginous manner. In fully developed lesions, these vessels coalesce to form a symmetrical reticular pattern resembling a 'pearl necklace'<sup>2</sup> or a 'string of pearls'<sup>3</sup>. The "string of pearls" appearance differs from the appearance of psoriasis wherein vessels are homogeneously and regularly distributed and are not in a line<sup>4</sup>. Although this pattern is highly specific to CCA, it has also been reported in non-CCA lesions, including lichen-planus-like keratosis (LPLK) and seborrheic keratosis<sup>4,5</sup>. Although biopsy is considered the gold standard method for diagnosing skin lesions, it is invasive and can result in a permanent scar. Hence, confirmatory biopsy might be avoided in patients who are young or for those who have concerns about permanent scarring, especially in the facial area. Our patient refused all invasive procedures and sought a non-surgical approach for both diagnosis and treatment. Dermatologists should thus provide alternative non-invasive methods for diagnosis and treatment of skin lesions. In this regard, dermoscopy can be a useful supplemental tool<sup>6,7</sup>. Given that the lesion was a solitary, erythematous, and brown shiny papule, clinical examination favored a diagnosis of CCA. Moreover, considering the patient's young age, we could rule out other diseases with dermoscopic features similar to CCA, such as LPLK and seborrheic keratosis. Hence, we presumptively diagnosed the lesion as CCA. Moreover, the detection of the dilated blood vessels through a dermoscope indicates that it is possible for the external laser beam to reach the enhanced superficial microvasculature. The favorable clinical efficacy of PDL for CCA substantiates the findings of a previous clinical study that demonstrated the efficacy of PDL for psoriasis<sup>8</sup>. It was based on the evidence that microvascular changes occur before T-cell infiltration and epidermal hyperplasia in psoriatic plaque formation<sup>9-11</sup>. Like psoriasis, CCA have been sug-

gested as a localized form of psoriasiform dermatitis<sup>1</sup> due to its histopathologic similarity<sup>3</sup> with same cytokeratin expression profile to psoriatic plaques<sup>12,13</sup>. Therefore, we could surmise that a selective destruction of the dilated dermal microvasculature led to the regression of the CCA lesion.

A limitation of this study is that we did not describe both patterns, i.e., patterns obtained with and without the application of pressure. When pressure is applied during dermoscopic examination, the vascular structures may disappear<sup>14</sup>. Therefore, dermoscopy should be performed carefully to avoid the loss of the vessel structures; the use of ultrasound gel for immersion will be encouraged in the future.

In the present case, dermoscopy was a useful tool for diagnosing CCA in a non-invasive manner, while providing information for the selection of the non-invasive modality. Moreover, the successful treatment of lesions presumptively diagnosed as CCA using PDL could be utilized in other such cases to achieve optimal aesthetic outcomes. To our knowledge, this is the first report describing a patient with presumed CCA who was successfully treated with PDL. We share our experience with the expectation that the present case may provide dermatologists with fresh insights into the practical applications of various non-invasive techniques.

## ACKNOWLEDGMENT

We received the patient's consent form about publishing all photographic materials. We thank the patient for granting permission to publish this information.

## CONFLICTS OF INTEREST

The authors have nothing to disclose.

## FUNDING SOURCE

None.

## DATA SHARING STATEMENT

The data that support the findings of this study are available from the corresponding author upon reasonable request.

## ORCID

Ga Ram Ahn, <https://orcid.org/0000-0002-5696-4699>

Guk Jin Jeong, <https://orcid.org/0000-0002-2379-0370>  
 Su Jung Park, <https://orcid.org/0000-0001-9314-6401>  
 Kui Young Park, <https://orcid.org/0000-0001-5965-1754>  
 Seong Jun Seo, <https://orcid.org/0000-0003-2915-839X>  
 Hae Woong Lee, <https://orcid.org/0000-0001-7688-1172>

## REFERENCES

1. Tempark T, Shwayder T. Clear cell acanthoma. *Clin Exp Dermatol* 2012;37:831-837.
2. Cunha DG, Kassuga-Roisman LEBP, Silveira LKCB, Macedo FC. Dermoscopic features of clear cell acanthoma. *An Bras Dermatol* 2018;93:449-450.
3. Paolino G, Donati P, Ferrari A, Panetta C, Buccini P, Donati M, et al. Clinicopathological and dermoscopic features of angio-ecrine hyperplasia in clear cell acanthoma. *J Am Acad Dermatol* 2016;74:1259-1261.e3.
4. Zalaudek I, Hofmann-Wellenhof R, Argenziano G. Dermoscopy of clear-cell acanthoma differs from dermoscopy of psoriasis. *Dermatology* 2003;207:428; author reply 429.
5. Espinosa AED, Akay BN, González-Ramírez RA. "String of pearls pattern": report of three cases of non clear-cell acanthoma. *An Bras Dermatol* 2017;92(5 Suppl 1):142-144.
6. Yim JH, Kang IH, Shin MK, Lee MH. Differences among dermoscopic findings in Riehl's melanosis of the cheek and neck. *Ann Dermatol* 2019;31:460-463.
7. Moon J, Kim M, Park JS, Lee J, Mun JH. Terra firma-forme dermatosis developed after thyroidectomy: clinical and dermoscopic features. *Ann Dermatol* 2018;30:499-501.
8. Bovenschen HJ, Erceg A, Van Vlijmen-Willems I, Van De Kerkhof PC, Seyger MM. Pulsed dye laser versus treatment with calcipotriol/betamethasone dipropionate for localized refractory plaque psoriasis: effects on T-cell infiltration, epidermal proliferation and keratinization. *J Dermatolog Treat* 2007;18:32-39.
9. Braverman IM, Yen A. Ultrastructure of the capillary loops in the dermal papillae of psoriasis. *J Invest Dermatol* 1977; 68:53-60.
10. Goodfield M, Hull SM, Holland D, Roberts G, Wood E, Reid S, et al. Investigations of the 'active' edge of plaque psoriasis: vascular proliferation precedes changes in epidermal keratin. *Br J Dermatol* 1994;131:808-813.
11. Pinkus H, Mehregan AH. The primary histologic lesion of seborrheic dermatitis and psoriasis. *J Invest Dermatol* 1966; 46:109-116.
12. Ohnishi T, Watanabe S. Immunohistochemical characterization of keratin expression in clear cell acanthoma. *Br J Dermatol* 1995;133:186-193.
13. Zedek DC, Langel DJ, White WL. Clear-cell acanthoma versus acanthosis: a psoriasiform reaction pattern lacking tricholemmal differentiation. *Am J Dermatopathol* 2007;29: 378-384.
14. Braun RP, Oliviero M, Kolm I, French LE, Marghoob AA, Rabinovitz H. Dermoscopy: what's new? *Clin Dermatol* 2009;27:26-34.