

Supernumerary teeth: Report of four unusual cases

ARUN KUMAR, RITU NAMDEV, LOKESH BAKSHI, SAMIR DUTTA

Abstract

Supernumerary tooth denotes duplication of tooth in the normal series. It is a developmental anomaly and has been argued to arise from multiple etiologies. These teeth may remain embedded in the alveolar bone or can erupt into the oral cavity. The supernumerary tooth might cause esthetic and/or functional problems, especially if it is situated in the maxillary anterior region. Complications reported were delayed or prevented eruption of succedaneous teeth, displacement or rotation, crowding of the affected region, abnormal diastema, dilacerations, cystic formation, and sometime eruption into the nasal cavity. In this case report, four unusual cases of supernumerary teeth that resulted in varying degrees of disturbances in permanent dentition are presented. Conservative surgical intervention and light orthodontic forces were used to bring the teeth into normal position with minimal disturbance to the surrounding oral structures.

Keywords: Mesiodens, supernumerary teeth, succedaneous teeth

Introduction

Supernumerary teeth denotes as teeth formed in excess of the normal dental formula.^[1] It can be single or multiple, unilateral or bilateral, malformed morphologically or normal in size and shape, and erupted or impacted.^[2-4] In the primary dentition, the incidence is said to be 0.3% to 0.8% and in the permanent dentition 1.5% to 3.5%.^[5] The prevalence of supernumerary teeth in the general Caucasian population ranges between 1% to 3%,^[6] with prevalence of 2.7% and 3.4% among Japanese^[7] and Hong Kong^[8] Chinese populations, respectively. There appeared to be an increased frequency for males of nearly 2 : 1,^[2,9] and more than 90% of all supernumeraries occur in the maxilla with a strong predilection for the premaxilla.^[2] Maxillary anterior supernumerary may erupt into the oral cavity or remain unerupted. It is found that approximately 25% are erupted, while rests are unerupted.^[10]

The etiology of the supernumerary teeth still remains unclear. "Phylogenetic process of atavism,"^[11] the "dichotomies of the tooth bud,"^[12] hereditary, and a combination of genetic and environmental factors-unified etiologic explanation^[13]

have been suggested. A hyperactive dental lamina is where the localized and independent hyperactivity of dental lamina is the most accepted cause for the development of the supernumerary teeth.^[1,12] However, the presence of supernumerary teeth may be part of developmental disorders such as Cleft lip and palate, Cleidocranial dysostosis, Gardner's syndrome, Ellis-Van Creveld syndrome, Ehlers-Danlos syndrome, Incontinentia Pigmenti, and Tricho-Rhino-Phalangeal syndrome.^[2]

Generally, supernumerary teeth can be classified as either supplemental or rudimentary. Supplemental teeth have morphology similar to a tooth of the normal dentition, while rudimentary teeth are small, conical, or tuberculate. The term mesiodens denotes a supernumerary tooth located between the maxillary central incisors.^[14] Single supernumeraries occur in 76% to 86% of cases, double supernumeraries in 12% to 23% of cases, and multiple supernumeraries in less than 1% of cases.^[2,15,16]

Most of the supernumerary teeth are asymptomatic. However, mesiodens that remains unerupted causes over-retained maxillary primary incisors, delayed or ectopic eruption of permanent central incisors, displacement and rotation of adjacent teeth,^[17] crowding, development of median diastema,^[2,18] eruption into the floor of the nasal cavity,^[1] and less frequently formation of primordial or follicular cysts^[19] with significant bone destruction, and root resorption of adjacent teeth.^[2] When these complications are anticipated, surgical removal of the supernumerary tooth followed by orthodontic treatment is indicated. Early surgical intervention is preferred treatment to prevent clinical problems and to minimize further complications.

The case report documented four unusual cases of supernumerary teeth presented as multiple non syndromic supernumeraries in the premaxilla, supernumerary tooth with

Department of Pedodontics, Government Dental College, Rohtak, Haryana, India

Correspondence: Dr. Ritu Namdev, Department of Pedodontics, Government Dental College, Rohtak, Haryana, India
E-mail: ritunamdev@rediffmail.com

| Access this article online | |
|---|--|
| Quick Response Code:  | Website: www.contempclindent.org |
| | DOI: 10.4103/0976-237X.95110 |

macrodontia of permanent incisor, inverted mesiodens, and supernumerary causing concomitant extrusion and intrusion of adjacent teeth.

Case Reports

Case 1

A 12-year-old boy reported to the Department of Pedodontics and Preventive Dentistry, Rohtak, with the chief complaint of delayed eruption in relation to upper left front teeth and irregular arrangement of those present. A thorough general examination was carried out to rule out the presence of any syndrome. Medical and family histories were non-contributory. Intraoral examination revealed permanent dentition with a supernumerary tooth, made up of more than one cusp or tubercle present palatal to 11 displacing it in a labial direction. Furthermore, a soft tissue buldge was seen associated with unerupted 21 labially [Figure 1a]. Radiographic examination revealed presence of another supernumerary in relation to 21 hindering its eruption [Figure 1b]. Buccal object rule was applied and tooth was

found to be in palatal position. On consultation, it was decided to remove both the supernumerary, surgically wait till eruption of 21, followed by orthodontic alignment of remaining upper teeth. Following extraction [Figure 1c], 21 erupt spontaneously within 3 months. Orthodontic treatment was started to align the incisors [Figure 1d]. The patient is now under regular review regarding future-fixed orthodontic treatment.

Case 2

A 12-year-old boy presented with a chief complaint relating to unesthetic appearance of upper front teeth. Medical and family histories were unremarkable. Dental history revealed exfoliation of 63 four days back. Intraoral examination showed permanent dentition, except with retained 53. Supernumerary tooth (conical in shape) was located in between two central incisors displacing 11 labially and distally resulted in slight palatal displacement of 12 [Figure 2a]. Crown structure of 11 appears somewhat larger than its normal-appearing counterpart tooth, i.e., 21. Radiographic examination disclosed presence of a mesiodens

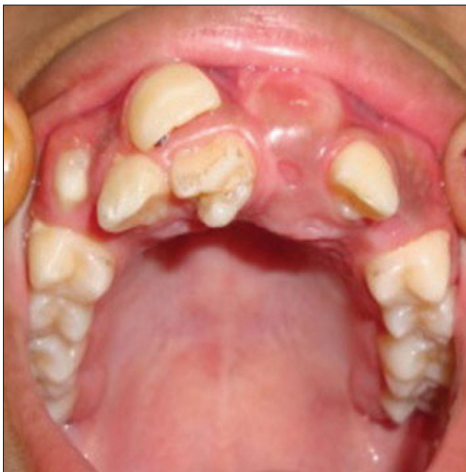

Figure 1a: Preoperative view showing upper anterior supernumerary (tuberculate type)

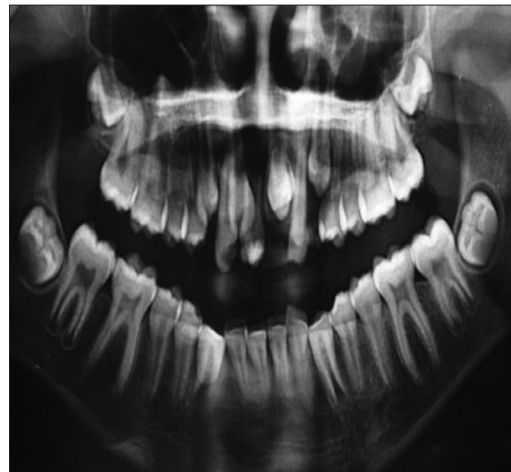


Figure 1b: OPG showing impacted midline supernumerary hindering eruption of 21

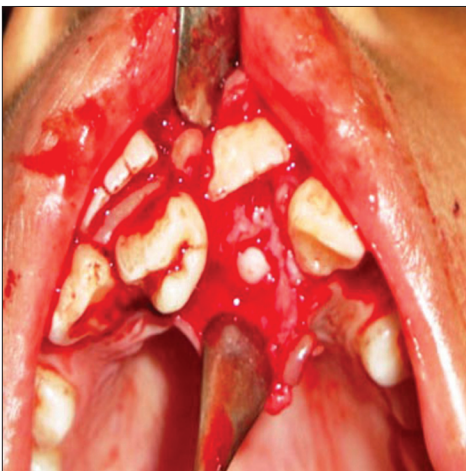

Figure 1c: Surgical exposure of impacted supernumerary

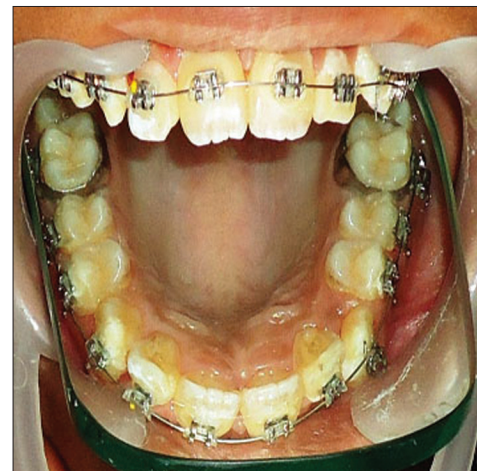


Figure 1d: Postoperative view showed well-aligned incisors

(conical) with completed root formation causing displacement of 11 distally [Figure 2b]. Treatment plan consisted of removal of mesiodens and retained right primary canine followed by orthodontic intervention. Nance palatal arch was placed. Initially, orthodontic treatment consisted of bracketing erupted upper teeth 15-25, except for 12. On further follow ups when 11 had moved mesially sufficiently, creating space for 12, it was banded and bracketed subsequently. Patient was maintained on follow ups and showed a satisfactorily outcome without complications [Figures 2c and 2d].

Case 3

A 9-year-old boy presented with displaced upper front teeth. Medical and family histories were unremarkable. Intraoral examination showed mixed dentition with a mesiodens, conical in type caused rotation and impaction of upper left and right central incisors, respectively. On palpation, a prominent soft tissue elevation was seen associated with unerupted 11, labially as well as palatally. Right lateral incisor was erupting in rotated position in palatal direction from its mesial half [Figure 3a]. Radiographic examination

revealed another supernumerary tooth with completed root formation, inverted in alignment wedged between a clinically noted mesiodens and 11, hindering its eruption [Figure 3b]. Using buccal object rule, the tooth was found to be located palatally. Treatment was instituted to surgically extract both the supernumeraries [Figure 3c] and to facilitate alignment and space closure using upper arch 2 by 4 fixed orthodontic therapy. After banding and bracketing 11, 12, 21, and 22, initially a ligature wire was placed in between 11 and 21 followed by continuous elastic chain to allow space closure [Figure 3d]. The early treatment goals were achieved without complication and the patient is under regular review.

Case 4

A 12-year-old boy reported with complaint of an extra tooth in between two upper front teeth causing an unesthetic appearance. Medical, dental, and family histories were not significant. Intraoral examination revealed permanent dentition with the presence of a mesiodens deviating 21 labially and cervically. There was mild extrusion in relation to 11 and palatal inclination of mesial half of 22 [Figure

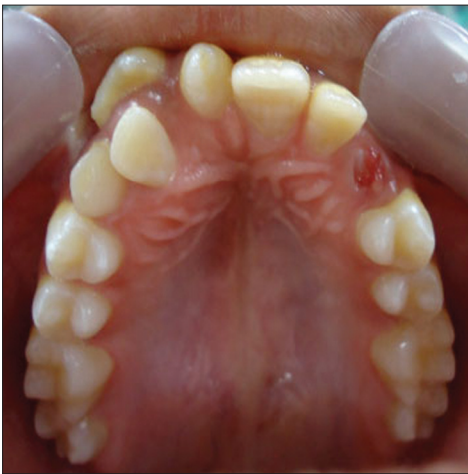

Figure 2a: Preoperative view showing conical supernumerary resulted in displacement of 11

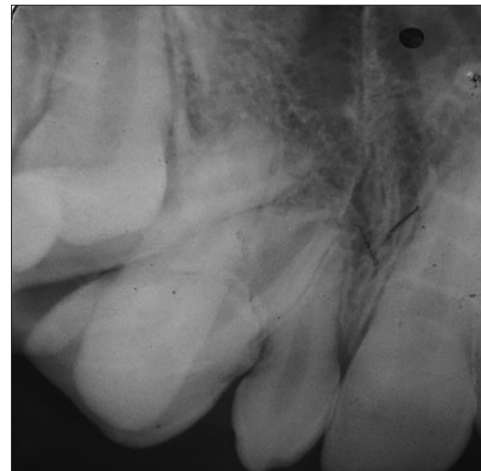

Figure 2b: IOPA showing midline supernumerary

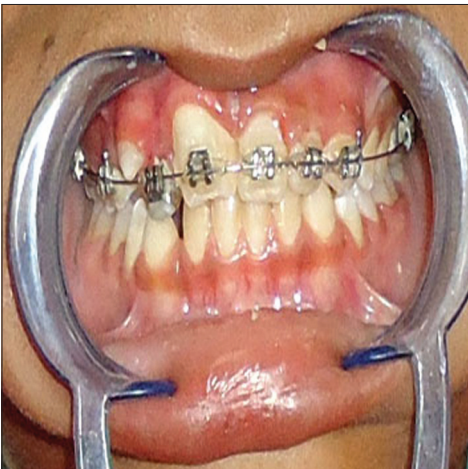

Figure 2c: Postoperative view showing aligned incisors

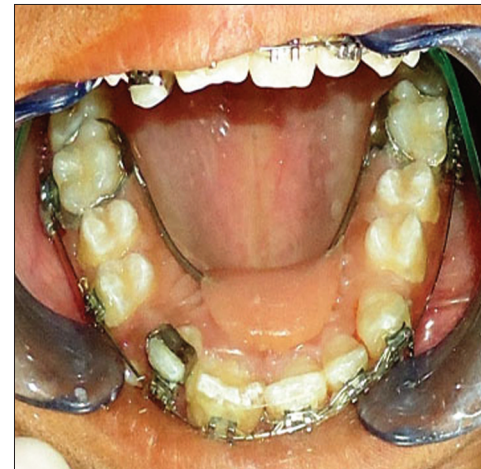

Figure 2d: Postoperative view

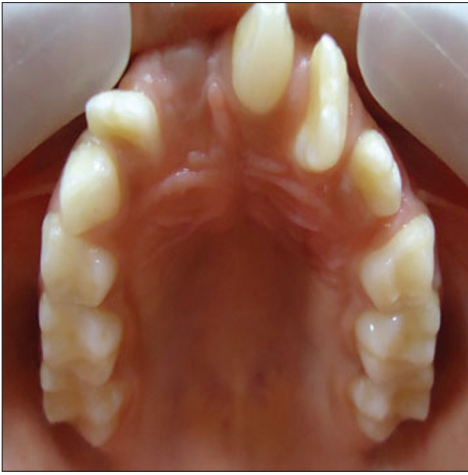

Figure 3a: Preoperative view showing rotation and impaction of upper central incisors

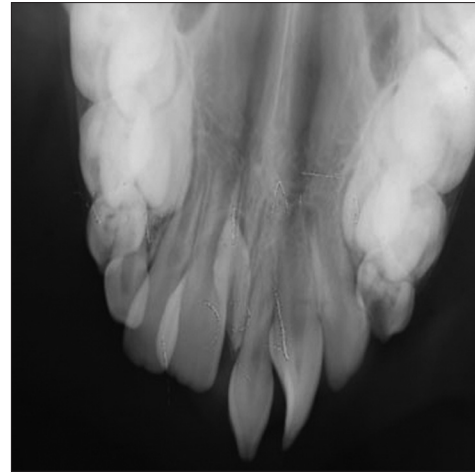


Figure 3b: Maxillary occlusal view showing inverted mesiodens

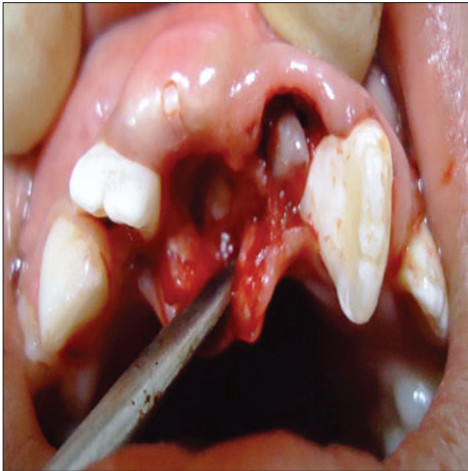


Figure 3c: Showing surgical removal of supernumerary

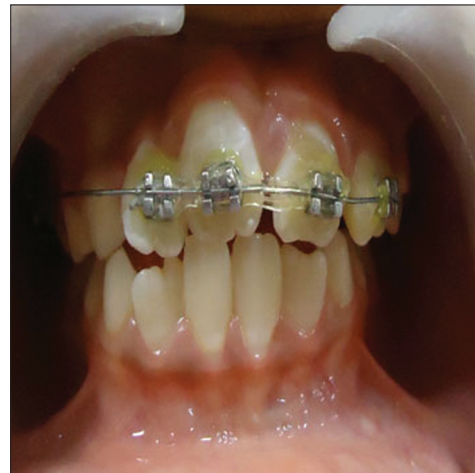


Figure 3d: Postoperative view

4a]. Radiographic examination showed presence of conical supernumerary wedged between upper two central incisors [Figure 4b]. Treatment involved extraction of the mesiodens, subsequently followed by upper 2 by 4 fixed orthodontic therapy. A midline diastema resulted after extraction of mesiodens. Brackets were placed on 11, 12, 21, and 22, followed by banding over 16 and 26 [Figure 4c]. A ligature wire was tied in between 11 and 21 that facilitate space closure. Also, continuous elastic chain was applied over bracketed teeth, changed on follow-up visits. Six to eight months postoperatively, both central incisors were well aligned; closing diastema [Figure 4d] and patient was kept on follow up with removable retention appliance.

Discussion

The origin of different types of supernumerary teeth remains speculative. Multiple tuberculate supernumerary teeth occurring in the absence of any syndrome have rarely been reported.^[1] They have more than one cusp; appear either alone or in pairs usually palatal to the permanent

incisors and very often obstructs their eruption.^[20] It is speculated that they represent a third dentition and thus are different in origin from supplemental teeth. Yusof,^[21] in a literature review of multiple supernumerary teeth occurring in the absence of a syndrome, found the anterior maxilla to be an unusual site for this occurrence as found. Similar findings were reported in case 1 where two supernumerary teeth; both tuberculate in type, one erupted and other impacted, were found in upper anterior region that resulted in delayed eruption and displacement of 21 and 11, respectively.

Few cases reported^[22,23] fusion of a supernumerary with successor teeth, complete or incomplete. Unusual larger or bulbous crown structure of 11 as depicted in case 2 might have been because of fusion between a supernumerary and a permanent tooth bud.

Rajab and Hamdan^[2] and Liu *et al.*^[24] stated that supernumerary teeth are frequently normally orientated. In contrast, case 3 reported inverted orientation of an unerupted supernumerary tooth. Our findings were supported by Tay *et al.*^[25] who

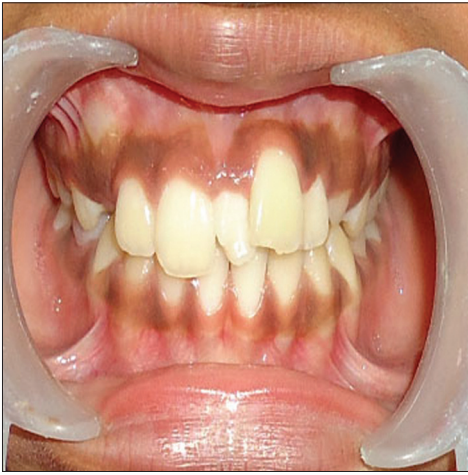

Figure 4a: Preoperative view showing midline supernumerary causing concomitant extrusion and intrusion

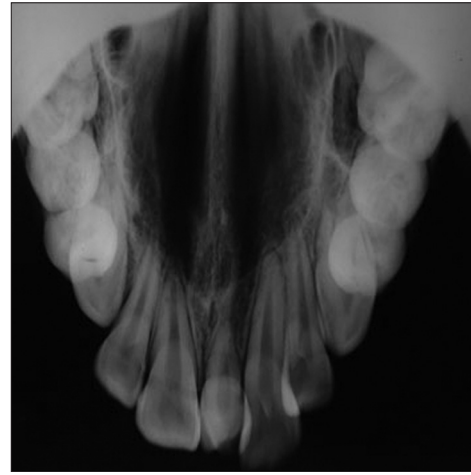


Figure 4b: Maxillary occlusal view showing mesiodens

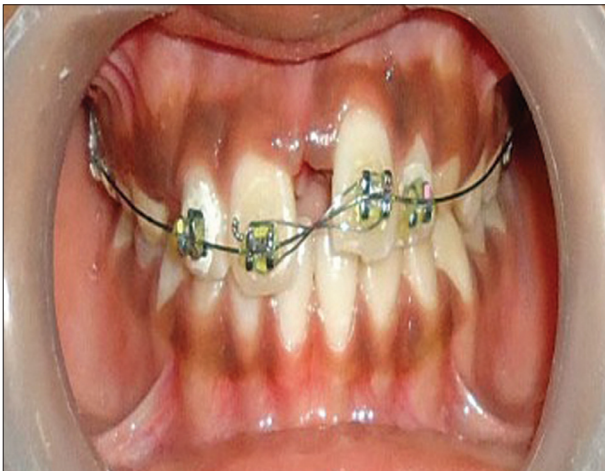

Figure 4c: Showing fixed 2 by 4 orthodontic therapy

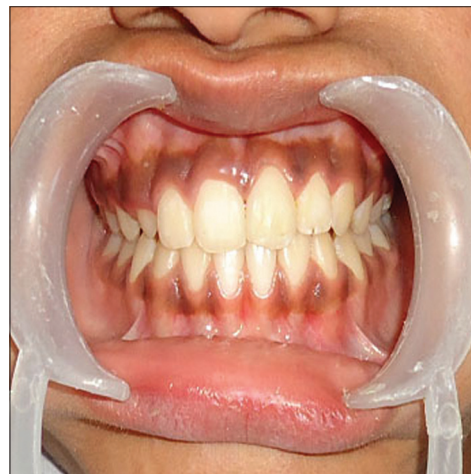

Figure 4d: Postoperative view

studied unerupted maxillary anterior supernumerary teeth and observed that most cases are in an inverted position. Furthermore, in case 4, concomitant intrusion as well as extrusion was noted in relation to upper central incisors by a mesiodens, often not reported.

It is essential to enumerate and identify the teeth present clinically and radiographically before a definitive diagnosis and treatment plan regarding supernumerary teeth can be formulated. Radiographs played an important role to rule out the presence of impacted supernumerary teeth or other associated anomalies. Furthermore, buccal object rule serves as an essential criteria and helpful in defining an accurate position of a supernumerary tooth, either buccal or palatal, as used in case 1 and 3. Timing of interceptive treatment should be as soon as possible following clinical detection of an abnormal eruption pattern. If a significant delay, i.e., more than six months in the eruption of maxillary central incisors with respect to its antimere was noted, the presence of mesiodens should be suspected and investigated radiographically. A panoramic radiograph is a most useful

screening radiograph in such situations as it shows all areas of the maxilla and mandible.

Controversy exists regarding the optimal treatment of delayed eruption due to supernumerary involvement. The options include removal of the supernumerary only, removal of the supernumerary, and orthodontic treatment to re-establish sufficient space, with or without surgical exposure of the unerupted tooth at the time of supernumerary tooth removal. Gomes *et al.*^[17] verified that the most common treatment of choice was surgery followed by orthodontic therapy, i.e., in 62.0% of cases.

A surgical removal of a mesiodens after diagnosis is indicated.^[15,26] It is in the best interest of the patient to have the tooth removed immediately on discovery unless the surgery would be unjustifiably hazardous to the adjacent structures. Furthermore, an immediate surgical removal was indicated after diagnosis because intra- or postoperative complications were less likely to occur. In the present cases, there was a very low risk of iatrogenic damage to adjacent permanent incisors root according to the clinical

and radiographic findings since root development of the central incisors was complete. Also, surgical procedure was simple; patients were cooperative and are more receptive to surgical management under local anesthesia and thus easier to manage. However, when unerupted teeth are symptom less, do not appear to affect dentition in any way, it is best to be left in place and kept under observation.^[2] The potential disadvantages associated with this deferred surgical plan include loss of eruptive force of adjacent teeth, loss of space and crowding of the affected arch, and possible midline shifts. In their study, 23 children aged less than 11 years and 17 aged greater than 11 years at the time of supernumerary removal, Hogstrum and Andersson^[9] found no evidence of root resorption, loss of vitality, or disturbance of root development during the three-year follow-up period. However, clinical complications were seen in 88.5% of the patients with ST, with displacement and failure of eruption being the most frequent.^[5] Moreover, a possible relationship between ST and other developmental anomalies, such as dens evaginatus and talon cusps, has been proposed. ST premolars appeared to be more prevalent in Chinese children with dens evaginatus than in the general population.^[27]

In the present case reported, supernumerary teeth resulted in varying degrees of orthodontic problems, i.e., rotation, crowding, displacement, and delayed eruption of permanent incisors necessitating surgical removal; facilitate spontaneous eruption of the permanent central incisors.

Spontaneous eruption following supernumerary removal is suggested to be in the range of 54% to 75%.^[28] In case 1 and 3, spontaneous eruptions occur within 3 months after eruption. DiBiase^[28] suggests that most teeth experiencing delayed eruption will spontaneously erupt within 18 months of supernumerary removal alone, provided the delayed tooth is not excessively displaced and have a potential to erupt. Furthermore, if the roots of the incisors are completely or nearly formed, there may be diminution of eruptive potential that will necessitate orthodontic treatment,^[29] as carried out in the present cases.

Whenever supernumerary teeth are diagnosed, single or multiple, a decision regarding the appropriate management should be made carefully. In our opinion, the clinical management of multiple supernumerary teeth poses a great challenge to clinicians. Therefore, it is important to initiate appropriate consultation and each case should be individually assessed.

Conclusion

Supernumerary teeth are relatively common and present a variety of complications. The clinician should have thorough knowledge of signs suggesting the presence of supernumerary teeth including non- or delayed eruption, alterations in the eruptive pattern, diastema formation,

midline shift, and crowding. On appropriate diagnosis, early intervention is required in the form of surgical or orthodontic treatment and combination in order to minimize unwanted side effects to the developing dentition. The cases described above represent a small sample of the possible presentations for cases involving supernumerary teeth.

References

1. Primosch RE. Anterior supernumerary teeth assessment and surgical intervention in children. *Pediatr Dent* 1981;3:204-14.
2. Rajab LD, Hamdan MA. Supernumerary teeth: Review of the literature and a survey of 152 cases. *Int J Paediatr Dent* 2002;12:244-54.
3. Gibson N. A late developing mandibular premolar supernumerary tooth. *Aust Dent J* 2001;46:51-2.
4. Umweni AA, Osunbor GE. Non-syndrome multiple supernumerary teeth in Nigerians. *Odontostomatol Trop* 2002;25:43-8.
5. Mason C, Azam N, Holt RD, Rule DC. A retrospective study of unerupted maxillary incisors associated with supernumerary teeth. *Br J Oral Maxillofac Surg* 2000;38:6.
6. Cherrick HM. Radiology in the diagnosis of oral pathology in children. *Pediatr Dent* 1982;3:424.
7. Niswander JD, Sujaku C. Congenital anomalies of teeth in Japanese children. *Am J Phys Anthropol* 1963;21:569-74.
8. Davis PJ. Hypodontia and hyperdontia of permanent teeth in Hong Kong school children. *Community Dent Oral Epidemiol* 1987;15:218-20.
9. Hogstrum A, Andersson L. Complications related to surgical removal of anterior supernumerary teeth in children. *ASDC J Dent Child* 1987;54:341-3.
10. Mc Kibben DR, Brearley LJ. Radiographic determination of the prevalence of selected dental anomalies in children. *J Dent Child* 1971;38:390-8.
11. Smith JD. Hyperdontia: Report of a case. *J Am Dent Assoc* 1969;79:1191-2.
12. Liu JF. Characteristics of premaxillary supernumerary teeth: A survey of 112 cases. *ASDC J Dent Child* 1995;62:262-5.
13. Brook AH. A unifying etiological explanation for anomalies of human tooth number and size. *Archs Oral Biol* 1984;29:373-8.
14. Sykaras SN. Mesiodens in primary and permanent dentitions. *Oral Surg* 1975;39:870-4.
15. Scheiner MA, Sampson WJ. Supernumerary teeth: A review of the literature and four case reports. *Aust Dent J* 1997;42:160-5.
16. Zhu JF, Marcushamer M, King LD, Henry JR. Supernumerary and congenitally absent teeth: A literature review. *J Clin Pediatr Dent* 1996;20:87-95.
17. Gomes CO, Drummond SN, Jham BC, Abdo EN, Mesquita RA. A survey of 460 supernumerary teeth in Brazilian children and adolescents. *Int J Paediatr Dent* 2008;18:98-106.
18. Galas MM, Garcia A. Retention of permanent incisors by mesiodens: A familiar affair. *Br Dent J* 2000;188:63-4.
19. Dinkar AD, Dawasaz AA, Shenoy S. Dentigerous cyst associated with multiple mesiodens. A case report. *J Indian Soc Pedod Prev Dent* 2007;25:56-9.
20. Foster TD, Taylor GS. Characteristics of supernumerary teeth in the upper central incisor region. *Dental Pract* 1969;20:8-12.
21. Yusuf WZ. Non-syndrome multiple supernumerary teeth: Literature review. *J Can Dent Assoc* 1990;56:147-9.
22. Kayalibay H, Uzamis M, Akalin A. The treatment of a fusion between the maxillary central incisor and supernumerary tooth: Report of a case. *J Clin Pediatr Dent* 1996;20:237-40.
23. Yang Y, Xia X, Wang W, Qin M. Uncommon fusion of teeth and lateral periodontal cyst in a Chinese girl: A case report. *Oral Surg Oral Med Oral Pathol Oral Radiol Endod* 2011;112:e18-20.
24. Liu DG, Zhang WL, Zhang ZY, Wu YT, Ma XC. Three dimensional evaluations of supernumerary teeth using cone-beam computed

- tomography for 487 cases. *Oral Surg Oral Med Oral Pathol Oral Radiol Endod* 2007;103:403-11.
25. Tay F, Pang A, Yuen S. Unerupted maxillary anterior supernumerary teeth: Report of 204 cases. *ASDC J Dent Child* 1984;51:289-94.
 26. Giancotti A, Grazzini F, De Dominicis F, Romanini G, Arcuri C. Multidisciplinary evaluation and clinical management of mesiodens. *J Clin Ped Dent* 2002;26:233-7.
 27. Cho SY, Ki Y, Chu V, Chan J. Concomitant developmental dental anomalies in Chinese children with dens evaginatus. *Int J Paediatr Dent* 2006;16:247-51.
 28. DiBiase D. The effects of variations in tooth morphology and position on eruption. *Dent Pract* 1971;22:95-108.
 29. Graber TM. *Orthodontics*. Philadelphia: W.B. Saunders Co; 1996. p. 327.

How to cite this article: Kumar A, Namdev R, Bakshi L, Dutta S. Supernumerary teeth: Report of four unusual cases. *Contemp Clin Dent* 2012;3:S71-7.

Source of Support: Nil. **Conflict of Interest:** None declared.

Announcement

Android App



Download
iPhone, iPad
application

FREE

A free application to browse and search the journal's content is now available for Android based mobiles and devices. The application provides "Table of Contents" of the latest issues, which are stored on the device for future offline browsing. Internet connection is required to access the back issues and search facility. The application is compatible with all the versions of Android. The application can be downloaded from <https://market.android.com/details?id=comm.app.medknow>. For suggestions and comments do write back to us.