

CASE REPORT

 OPEN ACCESS

An uncommon case of sarcomatoid urothelial carcinoma in covered bladder exstrophy

Carlo Pavone^a, Marco Vella^a, Dario Fontana^a, Cristina Scalici Gesolfo^a, Sebastiano Oieni^b, Francesca Toia^b and Adriana Cordova^b

^aDepartment of Surgical, Oncological and Oral Sciences, Section of Urology, University of Palermo, Palermo, Italy; ^bDepartment of Surgical, Oncological and Oral Sciences, Plastic and Reconstructive Surgery, University of Palermo, Palermo, Italy

ABSTRACT

We report a case of a woman affected by covered exstrophy, uterus didelphys and external genital malformation presenting with advanced bladder cancer. After neoadjuvant therapy and anterior pelvic exenteration, the abdominal wall was reconstructed with a pedicled myocutaneous muscle-sparing vastus lateralis flap.

ARTICLE HISTORY

Received 24 July 2015
Accepted 14 March 2016

KEYWORDS

Bladder cancer; bladder exstrophy; cystectomy; vastus lateralis flap

Introduction

The covered exstrophy is an extremely rare variant of exstrophy–epispadias complex wherein the incomplete closure of the anterior abdominal wall does not include the skin; the entirety of the skin guarantees an easier management and lower distress comparing with the classic bladder exstrophy.[1] If the bladder exstrophy is rare, with an incidence ranging from 2 to 5 cases per 100,000 live births and a male to female ratio of 2.3:1,[2] the cover exstrophy is even more rare.

The risk to develop a bladder cancer in patients with bladder exstrophy is significantly higher than the age-matched population, and some studies estimate this risk is as high as 700-fold greater.[3,4] Bladder cancer in exstrophic bladder is generally a high undifferentiated carcinoma, more often adenocarcinoma resembling a colorectal carcinoma, rarely a squamous carcinoma, or urothelial carcinoma.[5] In the event of cancerization, besides a radical cystectomy and a urinary derivation, an abdominal reconstruction is required if skin is involved.

Pedicled flaps are the best choice to restore full thickness defect of the lower abdominal wall. Usually these flaps are harvested from the tight as myocutaneous or fasciocutaneous flaps and most of them are based on the system of the circumflex femoral artery.

The most used flaps are the tensor fascia lata (TSL) [6] and the anterolateral thigh flap.[7–9] Less used for this kind of reconstruction are the rectus femoris and the vastus lateralis flap.[10,11]

The gracilis Flap [12,13] has also been used in abdominal reconstruction, but it belongs to a different arterial system, less used in this type of reconstruction.

The VAC therapy is an option to repair septic wound of the abdomen with a second-intentions healing.[14]

The aim of this paper is to report a case of a cancerization of covered exstrophy and its surgical management. Because of the oncological resection, we removed the tumor with a full thickness demolition of the lower abdominal wall and pubic region. The reconstruction was made with a pedicle myocutaneous vastus lateralis muscle sparing flap [15] that included in the flap a portion of Fascia Lata. It represents a safe and versatile option for morphofunctional reconstruction of large abdominal defects.

Clinical report

A 47-year-old Caucasian woman with a known-covered exstrophy, uterus didelphys, and external genital malformations (Figure 1), that did not affect her ability to

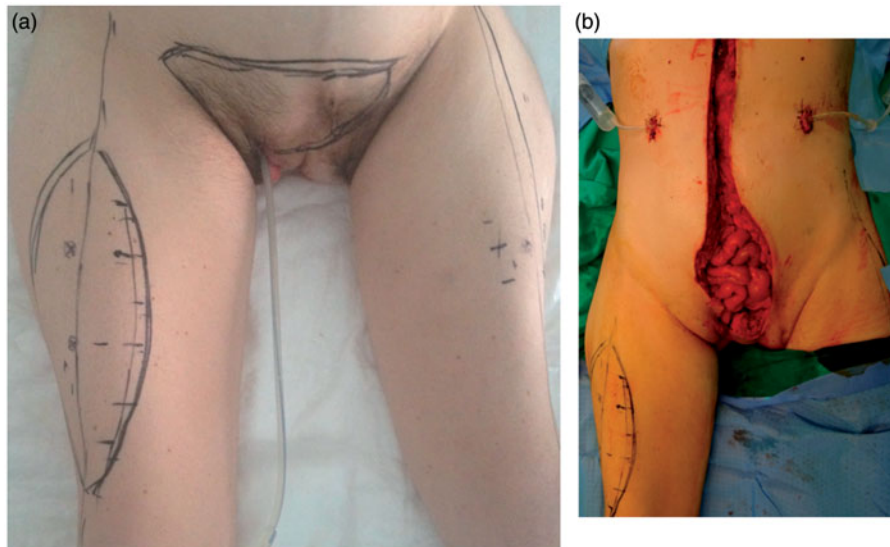


Figure 1. Preoperative view (a) and large abdominal wall defect after resection of the tumor (b).

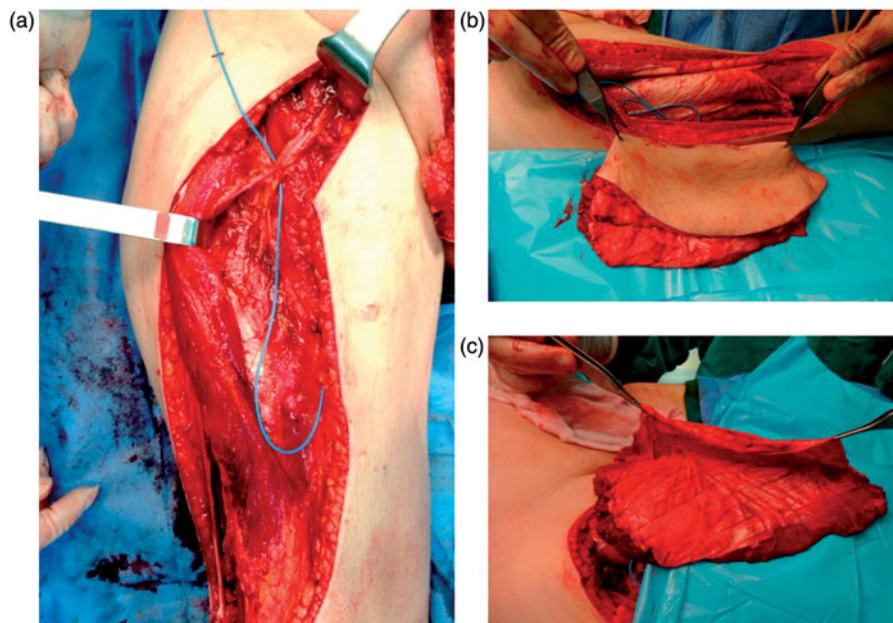


Figure 2. Intraoperative view showing the musculo-cutaneous muscle-sparing vastus lateralis flap including a portion of fascia lata (b and c) and the pedicle of the flap (a).

procreate (two caesarean sections), presented with recurrent macroscopic haematuria. CT scan showed a left third grade hydronephrosis associated to a dysmorphic bladder, with a endoluminal neof ormation of 10 cm of maximum diameter with irregular margins which appeared strictly in contact with the near organs and extending up to the abdominal skin.[16] After a trans-urethral biopsy (TUR-B) showing an infiltrating urothelial high-grade carcinoma (*ImmuneHistoChemical exam [HIC]: Pankeratin AE1/3+ CK7+ CK20-*), based on the rapid tumor growth, a neoadjuvant chemotherapy based on cisplatin and gemcitabine was performed. No clinical response was obtained and the CT scan

showed a worsening of local invasion. As a radical surgical excision was still achievable, a radical cystectomy with a wide iliac-obturator lymphadenectomy and bilateral urostomy was then performed.

The suprapubic skin was removed and the defect was reconstructed by a right myocutaneous vastus lateralis muscle-sparing flap. A neobladder was not reconstructed.[1-4] Cranially to the bispinoiliac line, the rectus abdominis muscles were sutured along the midline, while caudally, a full-thickness defect extended from the abdomen to the vaginal orifice (10 × 16 cm; Figure 1). The size of the demolition required the use of a vascularized tissue to cover the exposed intestine.

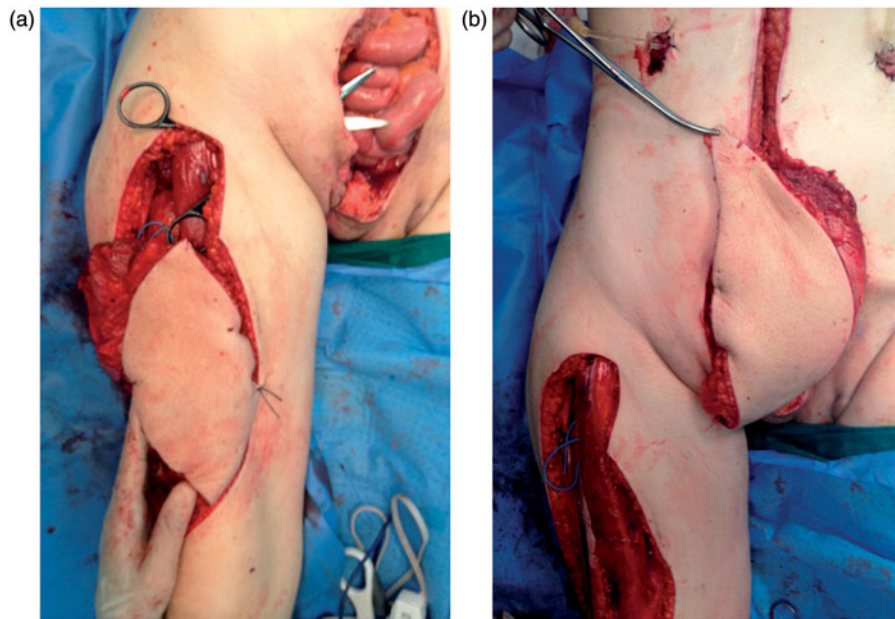


Figure 3. The tunnel in the inguinal region (a) and the inseting of the flap (b).

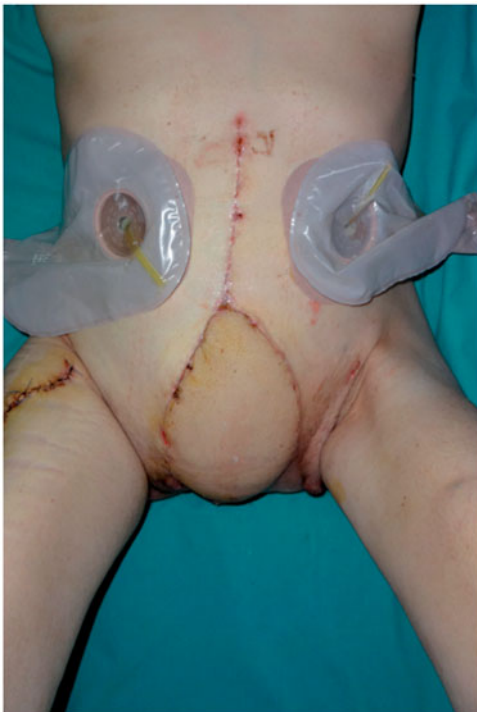

Figure 4. Final intraoperative view.

The vascularized muscular tissue allows a functional reconstruction of the abdominal wall.

The advanced stage of the tumor and the lower expectative of life required a fast and safe reconstruction so we decided to use a myocutaneous vastus lateralis muscle-sparing flap from the right thigh.[15] Only the superficial partition of the VL was harvested, preserving its nerve supply, and a portion of the fascia lata was included in the flap. The flap was passed

under the rectus femoris muscle and a subcutaneous tunnel to reach the defect (Figure 2). The fascia lata and the vastus lateralis aponeurosis were sutured laterally to the residual abdominal fascia and cranially to the rectus abdominis muscles. The VL filled the dead space in the pelvic floor and was sutured to the upper border of the vagina and its skin island provided an additional resurfacing layer (Figure 3). Postoperative period was uneventful, and the flap showed no sign of ischemia or infection. The early postoperative result is shown in Figure 4.

The pathological examination staged the disease as sarcomatoid urothelial carcinoma pT4N1. Six months later, the patient developed a local recurrence. CT scan also showed a multidistrict metastatic disease and eight months after surgery the woman died.

Discussion

Exstrophy of the bladder is part of a spectrum of anomalies involving the urinary tract, the genital tract, the musculoskeletal system, and sometimes the intestinal tract. Despite an acceptable quality of life can be achieved with modern reconstructive technique, the disease is burdened by a high incidence of bladder cancer. Adenocarcinoma is the most common histological type in bladder exstrophy, accounting not only for over 90% of all carcinoma in these patients, but also squamous cell carcinoma or urothelial carcinoma may develop.[17] The woman we observed had a locally advanced sarcomatoid urothelial carcinoma. To obtain a radical treatment, removal of a part of the abdominal wall was necessary. The selection of

reconstructive techniques in cases of patients with a short-life expectancy must be targeted to a very fast healing that gives them the possibility of receiving early adjuvant therapies with a good quality of life. To repair the defects and cover the exposed bowel, vascularized tissues are the first choice. In this case, we have harvested a myocutaneous vastus lateralis muscle-sparing flap, a safe and useful, yet not popular, option.

In literature, several techniques have been described for the reconstruction of the abdominal wall by local flaps. The pedicled TFL used to be the workhorse to repair abdominal wall defects but it is often bulky and poorly vascularized. The ALT flap allows to reconstruct big defects, but due to the lack of a muscular component in the flap, it does not allow for a functional reconstruction.

Vacuum-assisted closure (VAC) therapy may gradually close the abdominal wall defects over the bowels generating granulation tissue that can be grafted. This technique requires long time of healing, is associated to an elevated risk of fistula formation when the VAC is in direct contact with bowel, and does not allow functional reconstruction of the abdominal wall.

We have often used the myocutaneous vastus lateralis flap in the repair of the head and neck defects after cancer resection and we believe it is a very versatile and reliable flap, both free and pedicled.

The anterolateral thigh area donor site is ideal for the repair of abdominal wall because it remains outside the areas of scarring due to any previous abdominal operations.

The vastus lateralis myocutaneous flap can cover large defects (up to 20 × 10 cm); the possibility of including a large portion of the fascia lata helps to strengthen and stabilize the abdominal wall.

The selective harvest of only a partition of the vastus lateralis reduces morbidity of the donor site. The intermediate and deep partitions of the vastus lateralis remain *in situ* and the innervation of the other heads of the quadriceps remains intact.

The vascular pedicle is constant in course, length, and caliber.

The flap is tunneled under rectus femoris muscle so as to facilitate the inseting of the flap and reduce the possibility of twisting or compression of the pedicle.

There are no big disadvantages connected to the use of this flap, one of which could be the necessity to use a skin graft to cover the donor site when the skin portion of the flap is larger than 8–10 cm.

This technique allowed for a functional reconstruction of the abdominal wall, that would have prevented the development of future incisional hernias should

the patient had a longer survival. Unfortunately, the fate of the patient was not favorable and, because of the advanced disease, the woman died eight months after surgery with evidence distant metastases.

Conclusion

Bladder exstrophy is a predisposing factor for the development of not only advanced bladder cancer, usually adenocarcinoma but, as the case we report, also undifferentiated urothelial carcinoma. Patients with bladder exstrophy, even in the covered form, must be followed in order to early diagnose the malignant disease as treatment of advanced disease remains challenging. It often requires full-thickness excision of the abdominal wall and a subsequent reconstructive procedure. A myocutaneous vastus lateralis muscle-sparing flap is a safe and versatile option for morphofunctional reconstruction of large abdominal defects.

Disclosure statement

The authors report no conflicts of interest. The authors alone are responsible for the content and writing of this article.

References

- [1] Sahoo SP, Gangopadhyay AN, Sinha CK, et al. Cover exstrophy: a rare variant of classical bladder exstrophy. *Scand J Urol Nephrol.* 1997;31:103–106.
- [2] Nelson CP, Dunn RL, Wei JT. Contemporary epidemiology of bladder exstrophy in the United States. *J Urol.* 2005;173:1728–1731.
- [3] Smeulders N, Woodhouse CR. Neoplasia in adult exstrophy patients. *BJU Int.* 2001;87:623–628.
- [4] Nielsen K, Nielsen KK. Adenocarcinoma in exstrophy of the bladder – the last case in Scandinavia? A case report and review of literature. *J Urol.* 1983;130:1180–1182.
- [5] Sharma PK, Pandey PK, Vijay MK, et al. Squamous cell carcinoma in exstrophy of the bladder. *Korean J Urol.* 2013;54:555–557.
- [6] Rifaat MA, Abdel Gawad WS. The use of tensor fascia lata pedicled flap in reconstructing full thickness abdominal wall defects and groin defects following tumor ablation. *J Egypt Natl Canc Inst.* 2005;17:139–148.
- [7] Kayano S, Sakuraba M, Miyamoto S, et al. Comparison of pedicled and free anterolateral thigh flaps for reconstruction of complex defects of the abdominal wall: review of 20 consecutive cases. *J Plast Reconstr Aesthet Surg.* 2012;65:1525–1529.
- [8] Kimata Y, Uchiyama K, Sekido M, et al. Anterolateral thigh flap for abdominal wall reconstruction. *Plast Reconstr Surg.* 1999;103:1191–1197.

- [9] Contedini F, Negosanti L, Pinto V, et al. Reconstruction of a complex pelvic perineal defect with pedicled anterolateral thigh flap combined with bilateral lotus petal flap: a case report. *Microsurgery*. 2015;35:154–157.
- [10] Lin SJ, Butler CE. Subtotal thigh flap and bioprosthetic mesh reconstruction for large, composite abdominal wall defects. *Plast Reconstr Surg*. 2010;125:1146–1156.
- [11] LoGiudice JA, Haberman K, Sanger JR. The anterolateral thigh flap for groin and lower abdominal defects: a better alternative to the rectus abdominis flap. *Plast Reconstr Surg*. 2014;133:162–168.
- [12] Pavlov VN, Bakirov AA, Kabirov IR, et al. Pelvic floor reconstruction after pelvic evisceration using gracilis musculocutaneous flap. *Urologia*. 2015;3:39–42.
- [13] Broyles JM, Sarhane KA, Tuffaha SH, et al. Reconstruction of large abdominal wall defects using neurotized vascular composite allografts. *Plast Reconstr Surg*. 2015;136:728–737.
- [14] Nolff MC, Layer A, Meyer-Lindenberg A. Negative pressure wound therapy with instillation for body wall reconstruction using an artificial mesh in a Dachshund. *Aust Vet J*. 2015;93:367–372.
- [15] Toia F, D'Arpa S, Brenner E, et al. Segmental anatomy of vastus lateralis: guidelines for muscle-sparing flap harvest. *Plast Reconstr Surg*. 2015;135:185–198.
- [16] Pavone C, Di Trapani D, Serretta V, et al. Transurethral ultrasonography, CT scan, nuclear magnetic resonance (NMR) imaging and pathological control in staging and follow up of invasive bladder carcinoma. *Prog Clin Biol Res*. 1998;260:251–263.
- [17] Somak Roy, Parwani AV. Adenocarcinoma of the urinary bladder. *Arch Pathol Lab Med*. 2011;135:1601–1605.