



Original Article

Extracapsular approach for arthroscopic treatment of femoroacetabular impingement: clinical and radiographic results and complications[☆]



Bruno Dutra Roos^{*}, Milton Valdomiro Roos, Antero Camisa Júnior, Ezequiel Moreno Ungaretti Lima, Diego Paulo Gyboski, Lucas Schirmer Martins

Hospital Ortopédico de Passo Fundo, Passo Fundo, RS, Brazil

ARTICLE INFO

Article history:

Received 23 April 2014

Accepted 1 August 2014

Available online 3 July 2015

Keywords:

Femoroacetabular impingement/diagnosis
Femoroacetabular impingement/etiology
Femoroacetabular impingement/treatment
Arthroscopy

ABSTRACT

Objectives: To evaluate the clinical and radiographic results and complications relating to patients undergoing arthroscopic treatment for femoroacetabular impingement by means of an extracapsular approach.

Methods: Between January 2011 and March 2012, 49 patients (50 hips) underwent arthroscopic treatment for femoroacetabular impingement, performed by the hip surgery team of the Orthopedic Hospital of Passo Fundo, Rio Grande do Sul. Forty patients (41 hips) fulfilled all the requirements for this study. The mean follow-up was 29.1 months. The patients were assessed clinically by means of the Harris Hip score, as modified by Byrd (MHHS), the Non-Arthritic Hip score (NAHS) and the internal rotation of the hip. Their hips were also evaluated radiographically, with measurement of the CE angle, dimensions of the joint space, alpha angle, neck-head index, degree of arthrosis and presence of heterotopic ossification of the hip.

Results: Out of the 41 hips treated, 31 (75.6%) presented good or excellent clinical results. There was a mean postoperative increase of 22.1 points for the MHHS, 21.5 for the NAHS and 16.4° for the internal rotation of the hip ($p < 0.001$). Regarding the radiographic evaluation, correction to normal values was observed for the alpha angle and neck-head index, with a mean postoperative decrease of 32.9° and mean increase of 0.10, respectively ($p < 0.001$).

Conclusion: Arthroscopic treatment of femoroacetabular impingement by means of an extracapsular approach presented satisfactory clinical and radiographic results over a mean follow-up of 29.1 months, with few complications.

© 2014 Sociedade Brasileira de Ortopedia e Traumatologia. Published by Elsevier Editora Ltda. All rights reserved.

[☆] Work performed at the Hospital Ortopédico de Passo Fundo, Centro de Estudos Ortopédicos, Faculdade de Medicina, Universidade de Passo Fundo, Passo Fundo, RS, Brazil.

^{*} Corresponding author.

E-mail: brunodroos@gmail.com (B.D. Roos).

<http://dx.doi.org/10.1016/j.rboe.2015.06.011>

2255-4971/© 2014 Sociedade Brasileira de Ortopedia e Traumatologia. Published by Elsevier Editora Ltda. All rights reserved.

Abordagem extracapsular para tratamento artroscópico de impacto femoroacetabular: resultados clínicos, radiográficos e complicações

R E S U M O

Palavras-chave:

Impacto
femoroacetabular/diagnóstico
Impacto
femoroacetabular/etiologia
Impacto
femoroacetabular/tratamento
Artroscopia

Objetivos: Avaliar os resultados clínicos e radiográficos e as complicações relativos a pacientes submetidos a tratamento artroscópico de impacto femoroacetabular com o uso da abordagem extracapsular.

Métodos: Entre janeiro de 2011 e março de 2012, 49 pacientes (50 quadris) foram submetidos a tratamento artroscópico de impacto femoroacetabular pela Equipe de Cirurgia do Quadril do Hospital Ortopédico de Passo Fundo (RS). Preencheram todos os requisitos necessários para este trabalho 40 pacientes (41 quadris). O seguimento médio foi de 29,1 meses. Os pacientes foram avaliados pelo Harris Hip Score modificado por Byrd (MHHS), Non-Arthritic Hip Score (NAHS) e quanto à rotação interna do quadril. Também foram avaliados radiograficamente. Aferiu-se o ângulo CE, a dimensão do espaço articular, o ângulo alfa, o índice colo-cabeça, o grau de artrose e a presença de ossificação heterotópica do quadril.

Resultados: Dos 41 quadris tratados, 31 (75,6%) apresentaram resultados clínicos bons ou excelentes. Observou-se um aumento médio pós-operatório de 22,1 pontos para o MHHS, 21,5 para o NAHS e 16,4° na rotação interna do quadril ($p < 0,001$). Quanto à avaliação radiográfica, observou-se correção para índices considerados normais do ângulo alfa e índice colo-cabeça, com diminuição média de 32,9° e aumento médio pós-operatório de 0,10, respectivamente ($p < 0,001$).

Conclusão: O tratamento artroscópico do impacto femoroacetabular com o uso da abordagem extracapsular apresentou resultados clínicos e radiográficos satisfatórios em seguimento médio de 29,1 meses, com poucas complicações.

© 2014 Sociedade Brasileira de Ortopedia e Traumatologia. Publicado por Elsevier Editora Ltda. Todos os direitos reservados.

Introduction

Femoroacetabular impingement (FAI) is today recognized as a frequently occurring condition of hip pain among the young population, with possible degenerative consequences. Both of the known mechanisms for impingement (cam or inclusion and pincer or impaction) are related to pain, restriction of the range of motion and diminished tolerance of exercise among the individuals affected.¹⁻⁷ Several studies have now suggested that some of the hip osteoarthritis cases that previously were considered to be idiopathic are secondary to FAI.¹⁻³

Conservative treatment can be attempted first and consists of modification of high-impact physical activities, avoidance of load-bearing activities associated with excessive flexional and torsional movements (which would increase the demand on the joint) and lastly, use of anti-inflammatory drugs.^{4,7} When the conservative treatment only brings temporary relief, surgical treatment is indicated.^{4,7} Some authors have stated that because this is a mechanical pathological condition, delaying surgical treatment of FAI may not be beneficial for the patient. However, there is still no consensus in the literature in relation to this matter.¹⁻⁷

In 1988, Dorfmann et al.⁸ described subdivision of the hip joint into two compartments limited by the acetabular labrum: the central and peripheral compartments. Within this concept, the compartments are accessed arthroscopically in different manners. The central compartment is accessed through application of traction to the lower limb in order to allow inspection of the intra-articular space.⁸ More recently,

the lateral compartment of the hip was described such that this enabled viewing of the peritrochanteric space and the sciatic nerve.⁹

Arthroscopic treatment of FAI has been widely disseminated because this presents rapid rehabilitation and provides good access to the hip joint. Some forms of arthroscopic access to this pathological condition have been described in the literature. What differentiates these methods is the joint compartment that would be accessed first. The approach with an initial access to the central compartment is the form most commonly described.⁴⁻⁷ In arthroscopic approaches with initial access to the peripheral compartment (intracapsular and extracapsular approaches), after first accessing this compartment, traction is applied to the limb in order the view the central compartment.¹⁰⁻¹³

The objective of the present study was to evaluate the clinical and radiographic results and complications relating to patients undergoing arthroscopic treatment for FAI using an extracapsular approach.

Materials and methods

The patients included in the present study underwent arthroscopic treatment for FAI, performed by the hip surgery group consecutively between January 2011 and March 2012. Over this period, 49 patients underwent this treatment and all the operations were performed by the same surgeon (BDR). The exclusion criteria for this study were as follows: patients with FAI of pincer type alone (four cases); patients who underwent

arthroscopic treatment with initial access to the central compartment (four cases); loss from follow-up (one case); follow-up less than 12 months (no cases). All the patients were called back for reassessment. This study was approved by the research ethics committee.

In accordance with the criteria established, 40 patients fulfilled all the necessary requisites. Of these, 36 (87%) were male. The mean age was 36.12 years (SD=9.1; range: 21-47 years). The right hip was operated in 20 cases (48.78%) and the left hip in 21 cases (51.21%). One case was treated bilaterally, at different times.

Regarding clinical matters, the patients were evaluated before and after the operation using the Harris Hip Score, as modified by Byrd¹⁴ (MHHS), Non-Arthritic Hip Score¹⁵ (NAHS) and the degree of internal rotation of the hip affected (with the use of a goniometer for measurements).

From the Harris Hip Score as modified by Byrd,¹⁴ the results were stratified as poor (MHHS < 70 points), fair (MHHS 70-79 points), good (MHHS 80-89 points) and excellent (MHHS 90-100).⁴

All the patients were evaluated by means of radiographs (anteroposterior (AP) view of the pelvis with the patient standing upright, Dunn 45°, Dunn 90° and Lequesne false profile),¹⁶ and also magnetic resonance imaging (MRI) in order to diagnose chondral and labral lesions. FAI of pincer type was diagnosed through measuring the degree of coverage of the femoral head and acetabular version on AP radiographs of the pelvis in the upright standing position and Lequesne false profile. FAI of cam type was defined as an alpha angle greater than 50° on Dunn 45° radiographs.¹⁷

The following were measured before the operation: Tönnis¹⁸ classification for coxarthrosis; center-edge angle (θ_{CE}); dimension of the smallest joint space in millimeters in AP view of the pelvis in the upright standing position^{16,18}; alpha angle, as described by Meyer in Dunn 45° view¹⁷ (θ_{α}); and head-neck index (HNI) in Dunn 90° view.¹⁶ Late in the post-operative period, to make comparisons with the preoperative measurements, the dimension of the smallest joint space in millimeters (θ_{α}) was measured. In addition, the presence of heterotopic ossification of the hip was evaluated in accordance with Brooker et al.¹⁹ To avoid inter and intraobserver errors, the measurements were followed up by two surgeons from the hip group. In the event of discordance of more than 3° in the angular measurements or 1 mm in the minimum joint space, a new evaluation was made, this time by a third surgeon, and from this a consensus was reached regarding the measurement. It was considered that the mean magnification of the AP radiographs of the pelvis was 15%, and this was quantified on the equipment at the hospital service.

The statistical method used for analyzing the paired variables (MHHS, NAHS, internal rotation, θ_{α} and HNI before and after the operation) was the Mann-Whitney test. The results were considered to be statistically significant when $p < 0.05$.

Surgical technique-extracapsular arthroscopic approach

The extracapsular approach initially accessed the peripheral compartment and, just like the arthroscopic approach with

initial access to the central compartment, it could be performed with the patient in the supine or lateral decubitus position. Standard equipment for hip arthroscopy, such as 30° and 70° viewing devices, specific cannulae, radiofrequency, shavers, radioscopy and a traction table were used.

The extracapsular approach followed the access to the peripheral compartment described by Sampson¹⁰ and Horisberger et al.¹¹ This technique became popular in Spain under the name "from outside to inside".¹² It is differentiated from the intracapsular approach¹³ (which begins in the peripheral compartment internally to the joint capsule) since it starts externally to the hip capsule.

With the hip extended and using two arthroscopic portals, the anterior joint capsule and iliocapsularis muscle were dissected using radiofrequency and a shaver, until adequate exposure had been achieved. Identification of the reflex portion of the rectus femoris muscle marked the location of the acetabular labrum (Fig. 1). Capsulotomy was then performed longitudinally as far as the femoral neck, which may also be extended as necessary during the operation (Fig. 2). Capsulectomy was then performed, followed by femoral and/or acetabular osteochondroplasty. The limb was placed under traction at the time of inspection of the central compartment and labral refixation when necessary, in accordance with Fryer and Domb²⁰ (Fig. 3). After the procedure, suturing of the capsule could be done if necessary.

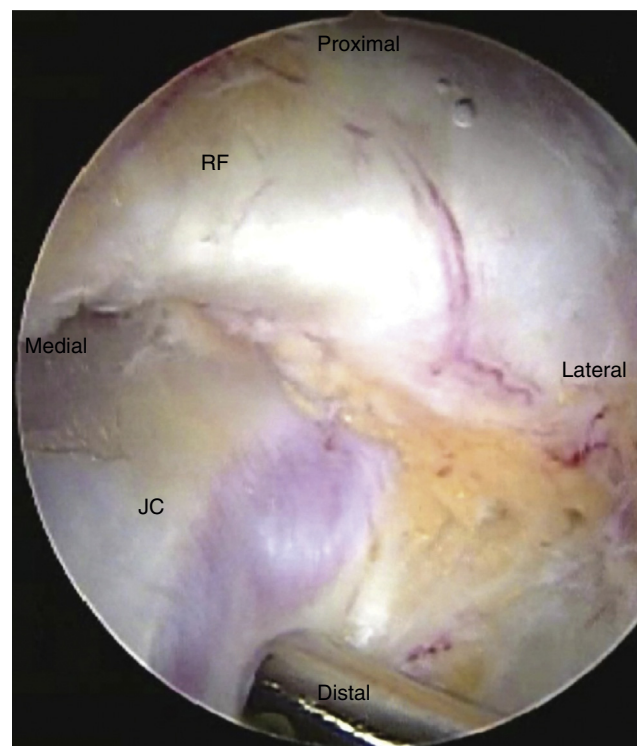


Fig. 1 – Arthroscopic image of the left hip during operation to treat FAI, by means of an extracapsular approach. Exposure of the joint capsule (JC) and identification of the reflex portion of the rectus femoris muscle (RF). The anatomical location of this muscle generally marks the proximity of the labrum of the hip, below the capsule.

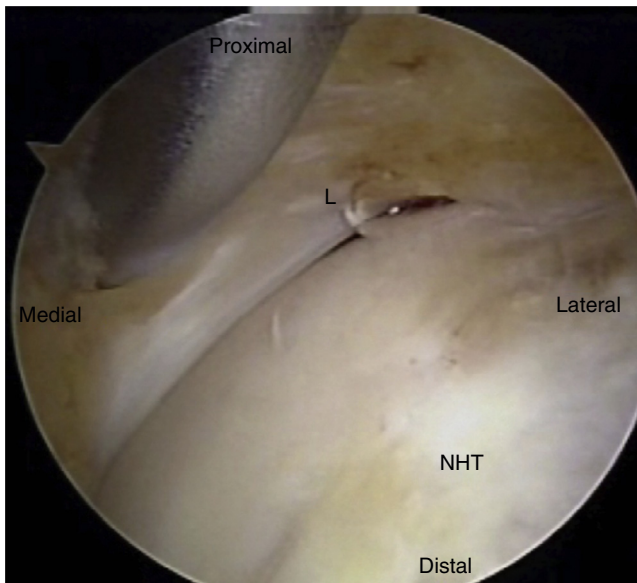


Fig. 2 – Image during operation, after the capsule has been opened, identifying the labrum of the hip (L) and the femoral neck-head transition (NHT).

After the operation, we advised that weight could be partially borne on the limb, with use of two crutches for three weeks. Following this, full-weight-bearing was allowed. Exercises on a bicycle or in a swimming pool were started 15 days after the operation. Physiotherapy for strengthening of the hip flexor and abductor muscles was started three weeks after the

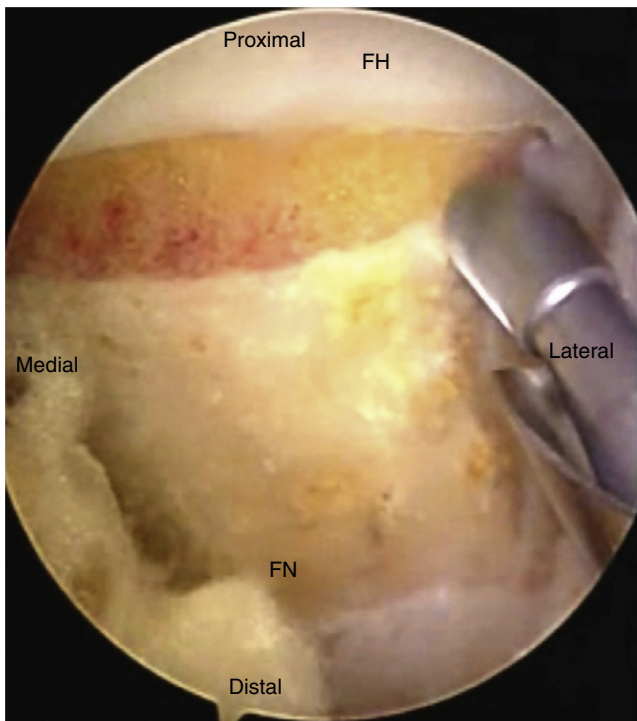


Fig. 3 – Image during operation showing resection of the cam-type deformity and identifying the femoral head (FH) and femoral neck (FN).

operation. The rehabilitation can be changed according to the patient's state of pain. We used prophylaxis against heterotopic ossification consisting of naproxen for 30 days.

The main theoretical advantages of arthroscopic approaches with initial access to the peripheral compartment are the lower risk of iatrogenic injury to the labrum and joint cartilage, shorter time under traction and ease of access to the joint when the traction on the limb does not allow initial access to the central compartment (prominent anterior acetabular wall or presence of an ossified labrum).¹⁰⁻¹³

Results

In relation to the evaluation of the MHHS clinical score, the preoperative mean was 65 points (SD = 9.8; range: 38–77 points) and the postoperative mean was 88 points (SD = 11; range: 60–100 points), i.e. with a postoperative increase in the mean of 22.1 points. In accordance with the criteria established, 31 cases (75.60%) presented good or excellent clinical results, 8 (19.51%) had fair results and three (7.31%) had poor results. Regarding the NAHS clinical score, the preoperative mean was observed to be 68.8 points (SD = 12.5; range: 45–80 points) and the postoperative mean was 92.5 points (SD = 10; range: 60–100 points), i.e. with a postoperative increase in the mean of 21.5 points. The internal rotation measurements on the hip presented a preoperative mean of 5° (SD = 10°; range: –15° to 30°) and a postoperative mean of 20° (SD = 12.5°; range: 5° to 40°), i.e. with a postoperative increase in the mean of 16.4°. It was seen that there were statistically significant differences ($p < 0.001$) in the MHHS and NAHS clinical scores and hip internal rotation measurements, from before to after the operation.

Twenty-nine hips (70.73%) were classified as presenting FAI of cam type and twelve (28.27%) as FAI of mixed type. During the arthroscopic surgical treatment, 20 cases (48.78%) underwent femoral osteochondroplasty alone. In the remaining 21 cases (51.21%), this was associated with other complementary procedures such as: acetabular osteochondroplasty in the mixed FAI cases (12 cases; 29.26%); debridement of the labrum (seven cases; 17.07%); acetabular chondral microfracture in Outerbridge grade 4 chondral lesions (four cases; 9.75%); and labral refixation as indicated by Fry and Domb²⁰ (five cases; 12.19%). The mean length of follow-up was 29.1 months (SD = 12.4; range: 12–36 months).

In relation to the preoperative radiographic evaluation, 13 cases (31.7%) were classified as arthrosis of Tönnis grade 0; 21 (51.21%) as Tönnis 1; 7 (17.07%) as Tönnis 2; and none as Tönnis 3. The mean θ_{CE} was 35.78° (27°–46°). None of the patients presented θ_{CE} less than 25° (suggestive of developmental dysplasia of the hip). The preoperative mean for the measurement of the smallest joint space was 3.31 mm (range: 2–4 mm) and there was no statistically significant difference in comparison with the late postoperative measurement ($p = 1.000$). None of the patients presented preoperative measurements of the smallest joint space that were less than 2 mm. Regarding θ_{α} , a mean postoperative reduction of 32.9° was shown, with a preoperative mean of 76° (SD = 11°; range: 60°–88°) and a postoperative mean of 44° (SD = 12.5°; range: 32°–55°). There was a mean increase in HNI of 0.10, with a preoperative mean of 0.10 (SD = 0; range: 0.06–0.14) and a postoperative mean of 0.20

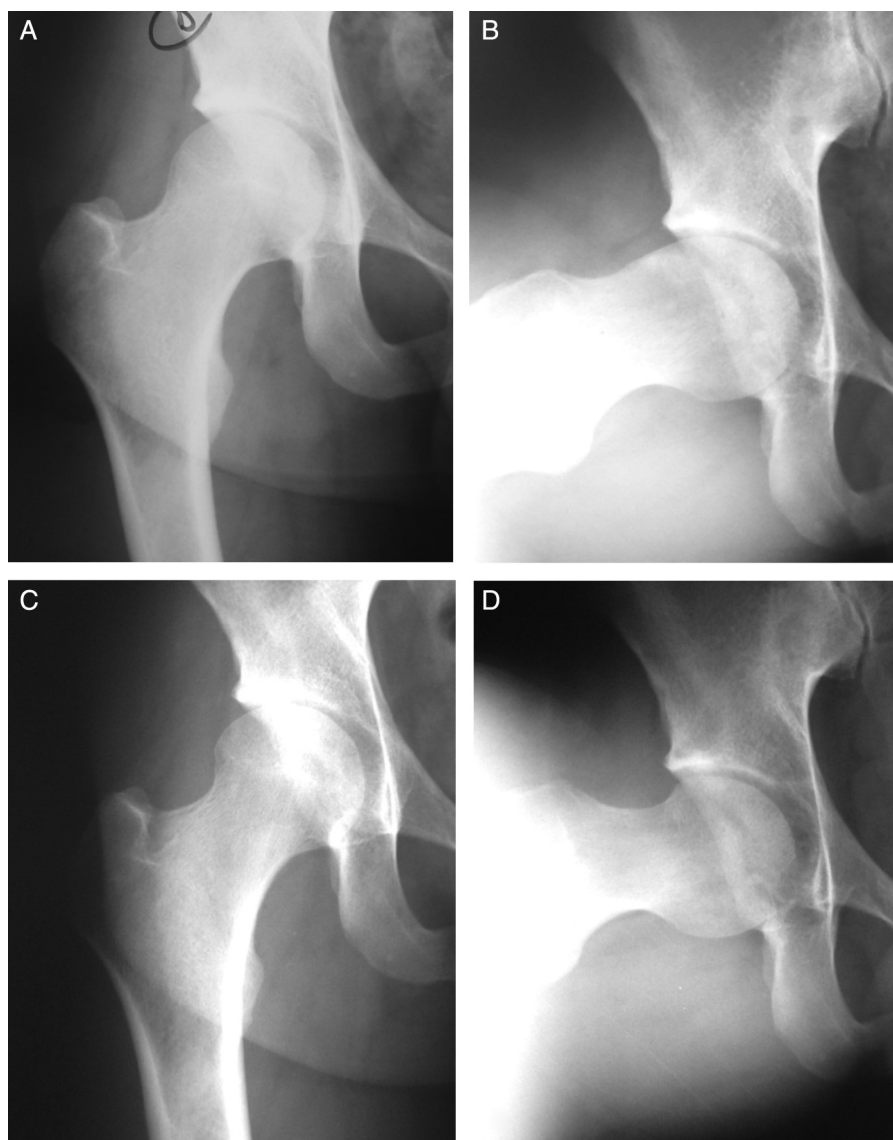


Fig. 4 – Male patient aged 32 years. Preoperative internal rotation of 5°. (A, B) Preoperative radiographs showing FAI of cam type, θ_{CE} : 27° and θ_{α} : 68°. (C, D) Radiographs produced 3 years and 2 months after the operation, in which femoral osteochondroplasty had been performed in association with labral debridement. The patient evolved well, to internal rotation of 18°, with normalization of θ_{α} .

(SD = 0.1; range: 0.16–0.32). Statistically significant differences ($p < 0.001$) between the preoperative and postoperative measurements of θ_{α} and HNI were observed. In late postoperative assessments, no heterotopic ossification was observed in 36 cases (87.80%), while four cases (9.75%) presented ossification classified as grade 1 by Brooker¹⁹ and one case (2.43%) as grade 3 (Table 1).

As complications, we found one case (2.43%) of deep vein thrombosis, one case (2.43%) of heterotopic ossification classified as grade 3 by Brooker¹⁹ and one case (2.43%) of transitory paresthesia of the pudendal nerve (with regression 2 months after the operation). Two cases (4.87%) presented persistent pain, and one of these now has been indicated for total hip arthroplasty. Both of these cases were patients with arthrosis of Tönnis grade 2 (Figs. 4 and 5).

Discussion

The surgical treatment of FAI is based on remodeling the proximal femur and acetabulum, along with treatment of the chondral and labral lesions, with the aim of diminishing the impingement of the femur on the edge of the acetabulum and consequently improving the range of motion of the hip.¹⁻⁴

Results from surgical treatment of FAI have been presented in the literature by several authors. The techniques used have ranged from the classical open approach of Ganz to arthroscopic anterior approaches (Smith-Petersen, Hueter, etc.) or combinations of arthroscopic techniques and an anterior mini-approach.^{1-7,10-13} In a general manner, the results have

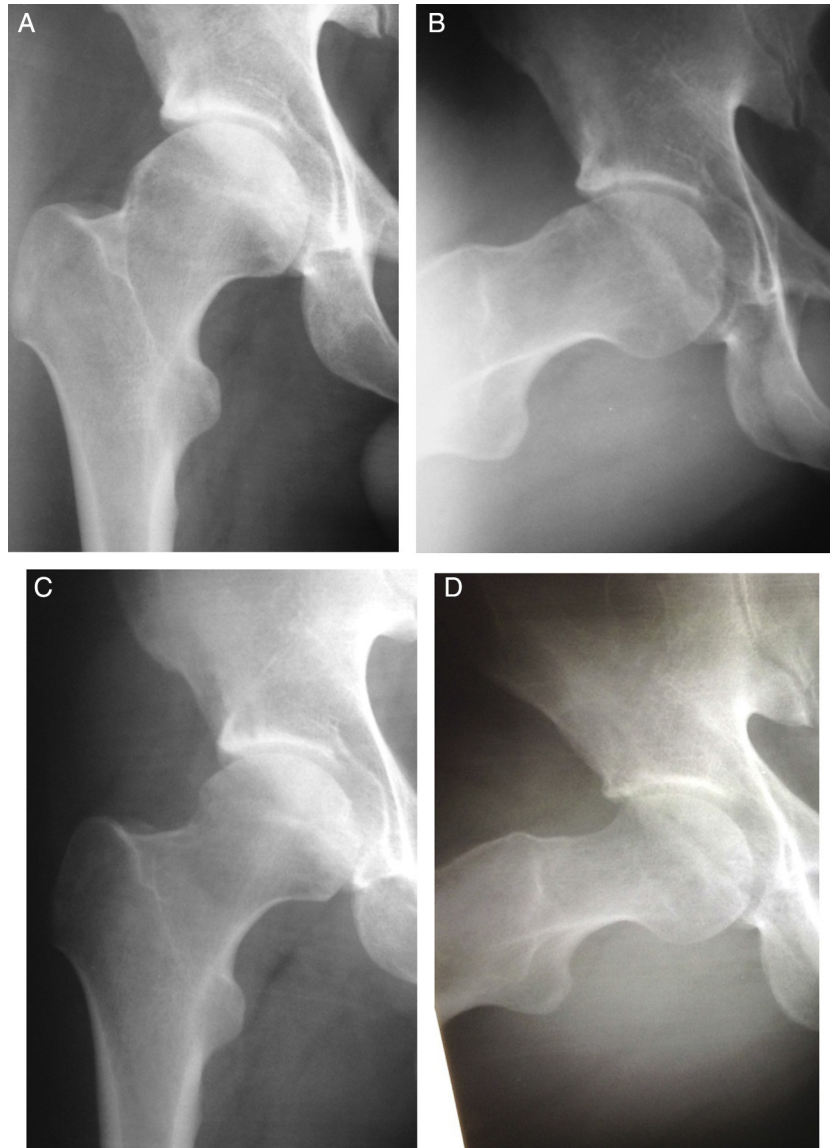


Fig. 5 – Male patient aged 37 years. Internal rotation of 0°. (A, B) Preoperative radiographs showing FAI of mixed type, θ_{CE} : 32°, θ_{α} : 78° and crossing of the acetabular lines. (C, D) Radiographs produced 1 year and 3 months after the operation, in which femoral osteochondroplasty had been performed in association with labral refixation. The patient evolved well, to internal rotation of 15°, with normalization of θ_{α} .

been positive with regard to symptom relief and improvement of hip mobility and the level of physical activity, and these suggest that over the long term, the joint will be preserved.¹⁻⁴

Among the traditional techniques for treating FAI, the hip dislocation technique described and popularized by Ganz et al.³ is currently considered to be the gold standard for treating this pathological condition. This technique provides wide access to the acetabulum and femur for repairing anatomical abnormalities and is also considered to be a safe technique that enables preservation of the vascularization of the femoral head. However, the accompanying rehabilitation period is long, in comparison with arthroscopic techniques,²¹ and complications such as pseudarthrosis of osteotomy of the greater trochanter may occur, with the possibility of the need for a new surgical intervention to remove the synthesis material.^{1-4,21,22}

Arthroscopic treatment of FAI has become widely disseminated because the subsequent rehabilitation is fast and because this method provides good access to the hip joint.^{1,4-7,10-13} A few types of arthroscopic approach toward this pathological condition have been described, and what differentiates them is the compartment that will be accessed first. Approaches with initial access to the central compartment are the type that is most commonly described.⁴⁻⁷ Arthroscopic approaches with initial access to the peripheral compartment (intracapsular and extracapsular approaches) access this compartment first, followed by application of traction to the limb in order to view the central compartment.¹⁰⁻¹³ The complications from arthroscopic treatment of the hip generally relate to the duration of the traction that is used to expose the joint and to the incisions that are made for

Table 1 – Comparison between preoperative and postoperative clinical and radiographic measurements.

Evaluation			Interquartile range	p
MHHS	Preoperative	65.0	9.8	<0.001
	Postoperative	88.0	11.0	
NAHS	Preoperative	68.8	12.5	<0.001
	Postoperative	92.5	10.0	
IR	Preoperative	5.0	10.0	<0.001
	Postoperative	20.0	12.5	
$\theta\alpha$	Preoperative	76.0	11.0	<0.001
	Postoperative	44.0	12.5	
mm	Preoperative	3.0	1.0	1.000
	Postoperative	3.0	1.0	
HNI	Preoperative	0.10	0.0	<0.001
	Postoperative	0.20	0.1	

MHHS, modified Harris Hip score; NAHS, non-arthritis hip score; IR, internal rotation of the hip; $\theta\alpha$, alpha angle; mm, dimension of smallest joint space in millimeters; HNI, head-neck index.

constructing the portals. For example, these complications may include injury to the lateral femoral cutaneous nerve or, more rarely, to the pudendal and sciatic nerves (0–12.9%).^{1-7,10-13}

Phillipon et al.⁶ used the arthroscopic technique with initial access to the central compartment to treat FAI in 112 patients, with a mean follow-up of 2.3 years, and found that there was a mean increase in the MHHS of 24 points, without complications. In a recent paper, Byrd and Jones⁴ used the same technique on 100 hips, with a minimum follow-up of 2 years, and found that 79% of the results were good or excellent, with complications observed in 3% of the cases. In the Brazilian literature, Polesello et al.⁷ published the results from 28 hips that were treated arthroscopically, with a mean follow-up of 27 months, among which 15% were good and 85% were excellent, without complications.

Dienst et al.²³ published the results from 48 patients who underwent arthroscopic treatment of FAI by means of an intracapsular approach (i.e. with initial access to the peripheral compartment), with a mean follow-up of 18 months. It was found that the NAHS showed a mean increase of 21 points; there were few complications (4.2%); and there was one case of conversion to total hip arthroplasty. Horisberger et al.¹¹ applied the extracapsular arthroscopic technique to 105 hips in 88 patients, with a mean follow-up of 2.3 years, and found a mean postoperative increase in NAHS of 28 points, with a complications comprising neuropraxia of the sciatic or pudendal nerve in 1.9% and neuropraxia of the lateral cutaneous nerve of the thigh in 11%. In 8.6% of the cases, there was a need to convert to hip arthroplasty.

In our study, we obtained results similar to those described in the literature. We observed postoperative improvements in the clinical evaluations on the patients, such that they achieved adaptations to levels that are considered to be normal in relation to the radiographic patterns measured, with maintenance of the joint space. We need to follow up these patients for a longer time in order to affirm whether the clinical results and joint preservation after the operation will continue to be satisfactory.

The limitations of the present study were the small number of patients, the predominance of male patients and the short mean length of follow-up (29.1 months).

It is important to emphasize that affirmation that chondral preservation in the hip joint has been achieved after surgical correction of FAI still remains a matter of controversy in the literature. A longitudinal study by Hartofilakidis et al.,²⁴ with follow-up of up to 40 years among asymptomatic patients with the morphology of FAI, demonstrated that even without treatment, evolution to osteoarthritis does not occur invariably (82.3% did not present arthritis after a mean follow-up of 18.5 years). Better understanding of the natural history of this pathological condition and identification of the morphotypes of FAI that have a higher chance of evolving to coxarthrosis can be expected to provide answers to the very many questions that currently exist and to help in future improvement of the best indications for its treatment.

Conclusion

The clinical and radiographic results from arthroscopic treatment of FAI using an extracapsular approach were satisfactory over a mean follow-up of 29.1 months, with few complications.

Conflicts of interest

The authors declare no conflicts of interest.

REFERENCES

- Matsuda DK, Carlisle JC, Arthurs SC, Wiekrs CH, Phillipon MJ. Comparative systematic review of the open dislocation, mini-open, and arthroscopic surgeries for femoroacetabular impingement. *Arthroscopy*. 2011;27(2):252–69.
- Ganz R, Parvizi J, Beck M, Leuning M, Noltzi H, Siebenrock KA. Femoroacetabular impingement: a cause for osteoarthritis of the hip. *Clin Orthop Relat Res*. 2003;(417):112–20.
- Ganz R, Gill TJ, Gautier E, Ganz K, Krugel N, Berlemann U. Surgical dislocation of the adult hip. A technique with full access to the femoral head and acetabulum without the risk of avascular necrosis. *J Bone Joint Surg Br*. 2001;83(8):1119–24.
- Byrd JW, Jones KS. Arthroscopic management of femoroacetabular impingement: minimum 2-year follow-up. *Arthroscopy*. 2011;27(10):1379–88.
- Byrd JW. Hip arthroscopy utilizing the supine position. *Arthroscopy*. 1994;10(3):275–80.
- Phillipon MJ, Briggs KK, Yen KM, Kuppertsmit DA. Outcomes following hip arthroscopy for femoroacetabular impingement with associated chondrolabral dysfunction: minimum two years follow up. *J Bone Joint Surg Br*. 2009;91(1):16–23.
- Polesello GC, Queiroz MC, Ono NK, Honda EK, Guimarães RP, Ricioli Junior W. Tratamento artroscópico do impacto femoroacetabular. *Rev Bras Ortop*. 2009;44(3):230–8.
- Dorfmann H, Boyer T, Henry P, De Bie B. A simple approach to hip arthroscopy. *Arthroscopy*. 1988;4(2):2.
- Voos JE, Rudzki JR, Shindle MK, Martin H, Kelly BT. Arthroscopic anatomy and surgical techniques for peritrochanteric space disorders in the hip. *Arthroscopy*. 2007;23(11), 1246.e1-5.

10. Sampson TG. Arthroscopic treatment of femoroacetabular impingement. *Tech Orthop.* 2005;20(1):56-62.
11. Horisberger M, Brunner A, Herzog RF. Arthroscopic treatment of femoroacetabular impingement of the hip: a new technique to access the joint. *Clin Orthop Relat Res.* 2010;468(1):182-90.
12. Margalet E, Mediavilla I, Marín O. Nuevo abordaje artroscópico de la cirugía de cadera: técnica out-inside. *Cuadernos Artroscopia.* 2010;41(1):27.
13. Dienst M, Seil R, Kohn DM. Safe arthroscopic access to the central compartment of the hip. *Arthroscopy.* 2005;21(12):1510-4.
14. Guimarães RP, Alves DPL, Azuaga TL, Ono NK, Honda E, Polesello GC, et al. Tradução e adaptação transcultural do Harris Hip Score modificado por Byrd. *Acta Ortop Bras.* 2010;18(6):339-42.
15. Christensen CP, Althausen PL, Mittleman MA, Lee JA, McCarthy JC. The nonarthritic hip score: reliable and validated. *Clin Orthop Relat Res.* 2003;7(406): 5-83.
16. Clohisy JC, Carlisle JC, Beaulé PE, Kim YJ, Trousdale RT, Sierra RJ, et al. A systematic approach to the plain radiographic evaluation of the young adult hip. *J Bone Joint Surg Am.* 2008;90 Suppl4:47-66.
17. Meyer DC, Beck M, Ellis T, Ganz R, Leunig M. Comparison of six radiographic projections to assess femoral head/neck asphericity. *Clin Orthop.* 2006;(445):181-5.
18. Busse J, Gasteiger W, Tönnis D. A new method for roentgenologic evaluation of the hip joint – the hip factor. *Arch Orthop Unfallchir.* 1972;72(1):1-9.
19. Brooker AF, Bowermann JW, Robinson RA, Riley RH Jr. Ectopic ossification following total hip replacement. Incidence, and method of classification. *J Bone Joint Surg Am.* 1973;55(8):1629-32.
20. Fry R, Domb B. Labral base re-fixation in the hip: rationale and technique for an anatomic approach to labral repair. *Arthroscopy.* 2010;26 9 suppl:S81-9.
21. Botser IB, Smith TW, Nasser R, Domb BG. Open surgical dislocation versus arthroscopy for femoroacetabular impingement: a comparison of clinical outcomes. *Arthroscopy.* 2011;27(2):270-8.
22. Beck M, Leuning M, Parvizi J, Boutier V, Wyss D, Ganz R. Anterior femoroacetabular impingement: part II. Midterm results of surgical treatment. *Clin Orthop Relat Res.* 2004;(418):67-73.
23. Dienst M, Kusma M, Steimer O, Holzhoffer O, Kohn D. Arthroscopic resection of the cam deformity of femoroacetabular impingement. *Oper Orthop Traumatol.* 2010;22(1):29-43.
24. Hartofilakidis G, Bardakos NV, Babis GC, Georgiades G. An examination of the association between different morphotypes of femoroacetabular impingement in asymptomatic subjects and the development of osteoarthritis of the hip. *J Bone Joint Surg Br.* 2011;93(5):580-6.