



Original Article

A retrospective study of titanium elastic stable intramedullary nailing in displaced mid-shaft clavicle fractures[☆]



Rajesh Govindasamy*, Saravanan Kasirajan,
Jimmy Joseph Meleppuram, Fawas Thonikadavath

Vinayaka Missions Medical College and Hospital, Department of Orthopaedics, Pondy, India

ARTICLE INFO

Article history:

Received 13 June 2016

Accepted 21 July 2016

Available online 30 December 2016

Keywords:

Clavicle
Fracture fixation
Intramedullary
Bone nails
Titanium

ABSTRACT

Objective: The aim of this study is to analyze the functional outcome following titanium elastic stable intra-medullary nailing (ESIN) for displaced mid-shaft clavicular fractures (DMCF).

Methods: A retrospective study of 60 patients between March 2009 and March 2015 was conducted. Patients were selected based on the inclusion criteria. Six patients were lost during follow up. Out of the remaining 54 patients, there were 39 males and 15 females. The mean age was 30.6 years. The functional outcome was analyzed using the Constant score, rate of bone union, complication, and earliest time of return to work.

Results: All fractures united well, with an average time of 7.5 weeks. Follow-up period ranged between 12 months and 18 months (average, 14 months). 24 out of 54 patients had closed nailing, while 30 had minimal open reduction. The average size of ESIN was 2 mm (range, 1.5–3 mm). The average Constant score was 97.8 (range, 95–99). There were no major complications, but minor complications occurred, viz. skin irritation in 15 patients, temporary paresthesia in five patients, and three patients who developed superficial infections. One case had implant migration and perforation at the lateral cortex, and one case had delayed union. There were few implant-related problems, as the authors used a standard protocol to remove it after radiological union. All patients returned to work within 10 weeks of the post-operative period.

Conclusion: ESIN is a safe, minimally invasive, engenders rapid healing with good cosmesis, and provides an excellent functional outcome in terms of patient satisfaction, with fewer complications.

© 2016 Sociedade Brasileira de Ortopedia e Traumatologia. Published by Elsevier Editora Ltda. This is an open access article under the CC BY-NC-ND license (<http://creativecommons.org/licenses/by-nc-nd/4.0/>).

[☆] Work performed in the Vinayaka Missions Medical College and Hospital, Department of Orthopaedics, Pondy, India.

* Corresponding author.

E-mail: drgortho@yahoo.com (R. Govindasamy).

<http://dx.doi.org/10.1016/j.rboe.2016.07.005>

2255-4971/© 2016 Sociedade Brasileira de Ortopedia e Traumatologia. Published by Elsevier Editora Ltda. This is an open access article under the CC BY-NC-ND license (<http://creativecommons.org/licenses/by-nc-nd/4.0/>).

Estudo retrospectivo de haste intramedular estável elástica de titânio em fraturas deslocadas do terço médio da clavícula

R E S U M O

Palavras-chave:

Clavícula
Fixação de fratura
Intramedular
Hastes ósseas
Titânio

Objetivo: O objetivo deste estudo é analisar o desfecho funcional após o uso de haste intramedular estável elástica de titânio (HIEET) em fraturas deslocadas do terço médio da clavícula (FDMC).

Métodos: Realizou-se um estudo retrospectivo de 60 pacientes entre março de 2009 e março de 2015. Os pacientes foram selecionados com base nos critérios de inclusão. Houve perda de seguimento de seis pacientes. Dos 54 pacientes restantes, 39 eram homens e 15 mulheres. A média de idade foi de 30,6 anos. O desfecho funcional foi analisado pela escala de Constant, taxa de união óssea, taxa de complicação e tempo de retorno ao trabalho.

Resultados: Todas as fraturas apresentaram boa união, em uma média de 7,5 semanas. O período de acompanhamento variou entre 12 e 18 meses (média: 14 meses). Em 24 dos 54 pacientes usou-se redução fechada com hastes intramedulares; nos outros 30, foi utilizada a redução aberta com fixação mínima. O tamanho médio da HIEET foi de 2 mm (variação: 1,5-3 mm). A média da escala de Constant foi 97,8 (variação: 95-99). Nenhum paciente apresentou complicações de grande porte, mas algumas complicações de pequeno porte foram observadas, a saber: irritação da pele em 15 pacientes, parestesia temporária em cinco pacientes e infecções superficiais em três pacientes. Observou-se um caso de migração do implante e perfuração no córtex lateral; um caso teve união atrasada. A taxa de problemas relacionados ao implante foi baixa, uma vez que os autores usaram um protocolo padrão para removê-lo após a união radiológica. Todos os pacientes retornaram ao trabalho em até dez semanas após a cirurgia.

Conclusão: A HIEET é um método seguro, minimamente invasivo, que gera cicatrização rápida com boa cosmesis e proporciona um excelente resultado funcional em termos de satisfação do paciente, com menos complicações.

© 2016 Sociedade Brasileira de Ortopedia e Traumatologia. Publicado por Elsevier Editora Ltda. Este é um artigo Open Access sob uma licença CC BY-NC-ND (<http://creativecommons.org/licenses/by-nc-nd/4.0/>).

Introduction

The shoulder joint functions as a closed chain mechanism and constitutes four joints. Two among the four joints articulate with the clavicle. Therefore any clavicle fracture affects the whole shoulder girdle. The clavicle is the first bone to ossify and it is one of the commonest bones to be fractured (2.6–5% of all fractures).¹ Approximately 80% of fractures occur in the mid-shaft, as it is a transition zone between the flattened lateral part and tubulo-triangular medial part as well as it is also the thinnest segment which is relatively unprotected as it is not stabilized by any ligaments.²

A fall or direct blow to the shoulder is the most common mechanism of injury for any clavicle fracture. The mid-shaft fractures, tend to shorten when displaced. It is due to the combined working of the sternocleidomastoid pulling the medial fragment superiorly and posteriorly, and the pectoralis major, the deltoid and gravity pulling the lateral fragment inferiorly and anteriorly. This results in net displacement and shortening of the fracture (Fig. 1). More than 50% of clavicle fractures are displaced.² The overall frequency of non-union in undisplaced fractures is about 5% and it is higher in displaced fractures approximately 15.1%.³

As nature has endowed clavicle with excellent reparative powers, these fractures are treated conservatively in general,

but two-third of DMCF will end up in some degree of malunion with shortening and symptoms.⁴

The clavicle length plays an important role to maintain anatomical relationship and function of the shoulder girdle.⁴ So early surgical treatment in DMCF improves the functional outcome by decreasing the rates of nonunion and symptomatic malunion. So surgery has been indicated for fractures which are completely displaced, which has skin perforation, having shortening of more than 20 mm, neurovascular injury, bilateral fractures and floating shoulder.⁵

The standard treatment of DMCF is plate osteosynthesis as it restores length and anatomical alignment, also the implant is mechanically stronger but has its own complications.⁵ Intramedullary fixation has emerged as an excellent alternative since it behaves as an internal splint by sharing load and maintains alignment without rigid fixation.⁵

Intramedullary fixation for clavicular fractures was first described by Peroni⁶ in 1950. The devices include, Kirschner wire, Rush pins, Knowles pin, Steinman pin, Haige pin, Rockwood pins and Titanium elastic nails.^{5,7-9} Titanium ESIN can block itself in the bone and provide a three point fixation within the S shaped clavicle. Some studies have shown, there is a spectrum of complications and technical difficulties associated with this procedure.¹⁰

Our study is to evaluate this DMCF treated by titanium ESIN. We analyzed (1) union rate, (2) functional outcome using

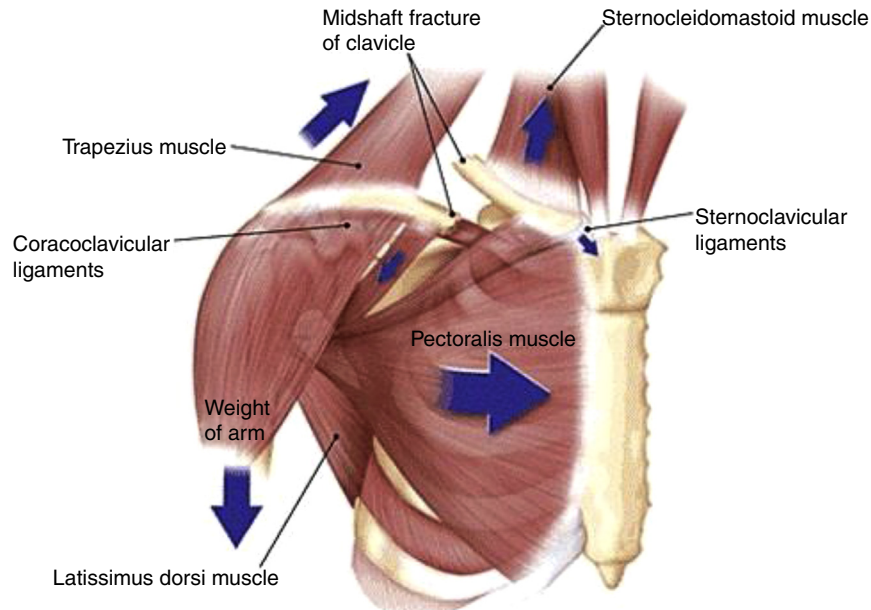


Fig. 1 – Displaced mid shaft clavicle fracture.

Constant Score,¹¹ (3) earliest time for return to work, (4) complications.

Materials and methods

A retrospective review of a cohort of 60 unilateral DMCF treated at our institution between March 2009 and March 2015, treated with titanium ESIN was carried out. Six patients were lost during follow up. Out of the remaining 54 patients there were 39 males (72%) and 15 females (28%) in our study. There were 28 left sided fractures and 26 right sided fractures. The mean age was 30.6 years (range: 23–50 years). Commonest mode of injury was due to fall on the shoulder either due to road traffic accidents ($n=35$) or fall from height ($n=19$). Our study included all DMCF classified according to Orthopaedic Trauma Association (OTA) Classification.¹² We had 26 patients with type A fractures and 28 patients with type B fractures.

Inclusion criteria

Skeletally mature patients with diaphyseal mid-shaft fractures with more than 20 mm of displacement of either type A (simple fracture two segment) or type B (fracture with bending wedge) of OTA classifications within seven days of injury.

Exclusion criteria

(1) Open fractures, (2) floating shoulder, (3) proximal or distal fractures, (4) neurovascular injuries, (5) fractures presenting after one week of injury, (6) patients with pre-existing sub-acromial pathology, (7) co-morbidities with risk of anaesthesia and surgery, (8) surgical techniques other than ESIN, (9) grossly comminuted fractures – type C (OTA), (10) non-union, and (11) malunion.

Surgical technique

Having got the informed written consent and prophylactic antibiotics, the patient under general anaesthesia was positioned in a supine beach chair position with a folded towel over the medial border of the affected shoulder. The injured part was prepared and draped from the midline to the upper arm. Care was taken to ensure the sterno-clavicular joint accessibility for the entry and was confirmed using an image intensifier. The size of the nail was measured using the following formula $-0.4X$ canal diameter in mm.⁹

A small incision was made over the skin 1 cm lateral to medial end of the clavicle. The subcutaneous fat was incised along with platysma. The pectoral fascia was divided in line with the skin incision followed by careful elevation of the underlying musculature from the clavicle. Then for insertion of the nail an entry point was made by Awl in the anterior cortex of the bone and 3.2 mm drill was used for further entry. Titanium nail was bent to about 15 degree to facilitate insertion, the T-handle was used to push and rotate the nail into the medullary cavity under fluoroscopic control until it reached the fracture site (Fig. 2A–D).

Attempt was made for close reduction of the fracture by using two percutaneously introduced pointed reduction clamps. If the fracture could not be reduced by closed means, then a small separate vertical incision was used at the fracture site to aid fracture reduction. Vertical incision (mini open) technique was used as it was parallel to the Langer's lines and minimized the risk of damage to supraclavicular nerves, to avoid dysesthesia of skin and scar neuromas. The nail was then advanced manually until it was just medial to the acromioclavicular joint. Accurate manoeuvring of nail tip was necessary under fluoroscopic control to avoid penetration of thin dorsal cortex. After adequate engagement in the lateral segment, the fracture was compressed and the nail was cut

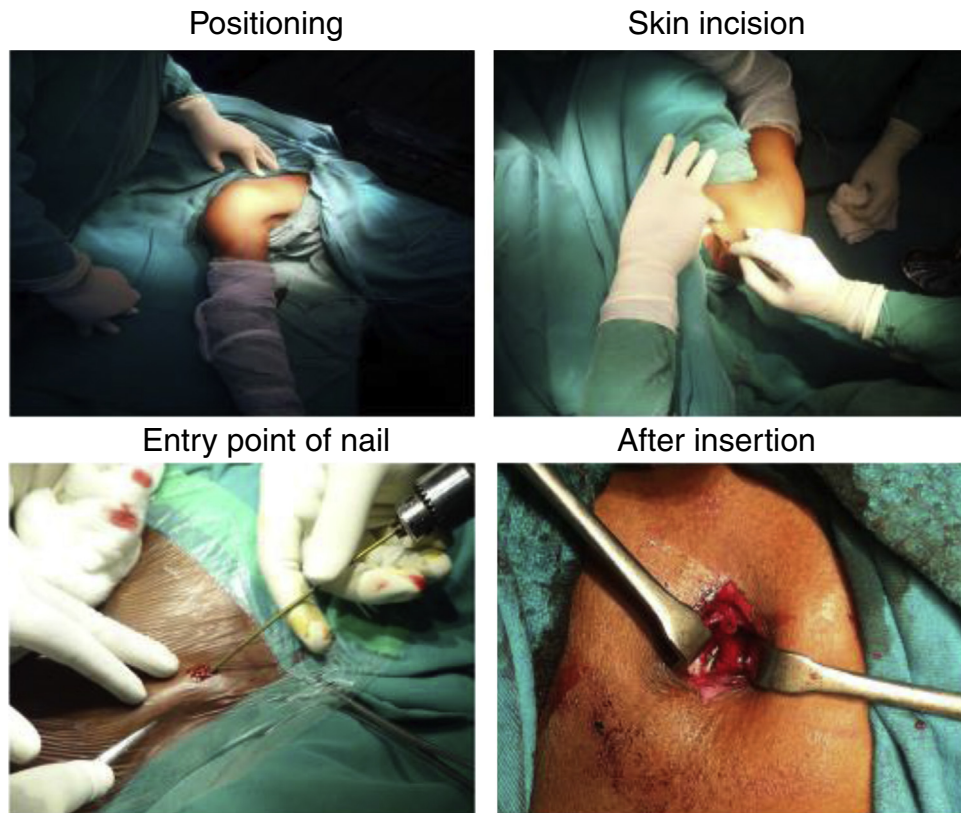

Fig. 2 – Surgical technique. (A) Positioning; (B) skin incision; (C) entry point of nail; (D) after insertion.

after little bent closed to the entry point on the medial side and buried under skin to minimize soft tissue irritation as well as for an easy extraction in future. The fascia and skin were closed in layers.

Post operative protocol

Post operatively patients were kept in a sling, and they were discharged the very next day after post operative check X-rays and encouraged for early shoulder mobilization with pendular exercises. Suture removal was done on the tenth day. Active range of movement exercises were initiated. The shoulder sling was discarded at the end of three weeks, overhead activity was allowed only after fourth week. Activities of daily living were started thereafter, but those requiring lifting of heavy weights were delayed until union was achieved.

All patients were reviewed at second, fourth and sixth week, third and sixth month after surgery at the outpatient department, at each visit the patients were accessed clinico-radiologically for primary and secondary outcomes. We routinely removed the nails after six months with complete radiological union, which was defined as visible bridging callus or complete obliteration of fracture lines. All patients were further followed up for one year to a maximum follow up of two years.

As there were no clavicle trauma scores the functional outcome was evaluated using Constant Score.¹¹ We looked for any complications in our study. Major complications were: those requiring additional surgery to revise or remove

the fixation as a result of nonunion, malunion, deep seated infections and breakage of implant. Minor complications were those do not require additional surgery, such as superficial infections, implant irritation, migration, scar neuromas and neurovascular problems.^{13,14}

Results

At the end of the study we had 54 patients, who returned for clinical and radiological follow up. Average clinical follow up was 14 months (range 12–18 months). All fractures united with a mean time of 7.5 weeks (7–10 weeks). We had one case of delayed union (Figs. 3–6) and the fracture united at the end of 10 weeks with immobilization, without need of any additional procedures such as bone grafting.

Out of 54 patients, the average ESIN size was 2 mm (1.5–3 mm). In most cases, we used 2 mm nails, only in five cases with minimal comminution we used 3 mm nails to increase stability. We did Mini open technique in 30 patients (55%), in the rest 24 patients (45%) we performed closed technique.

We did not have any major complications in our study which needed additional surgical procedures. We had minor complications, the most common complications being medial skin irritation in fifteen patients (27%) at the site of nail entry. In three cases (5.6%) there was superficial infection at the nail entry site, which got settled with oral antibiotics. In one case, we had implant migration with perforation at the lateral end (Fig. 7), in this we did nail extraction at the lateral end. Five

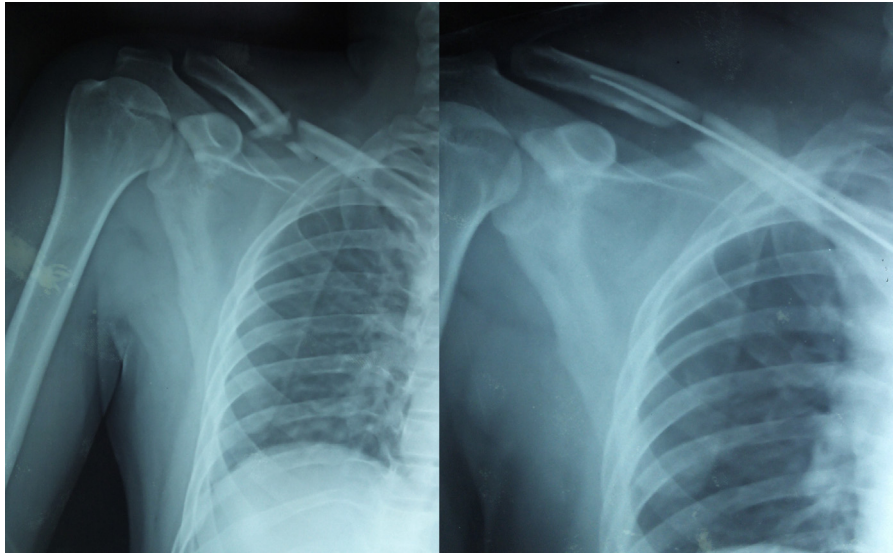


Fig. 3 – OTA type B fracture fixed with ESIN through Mini open technique. ESIN, elastic stable intramedullary nailing.

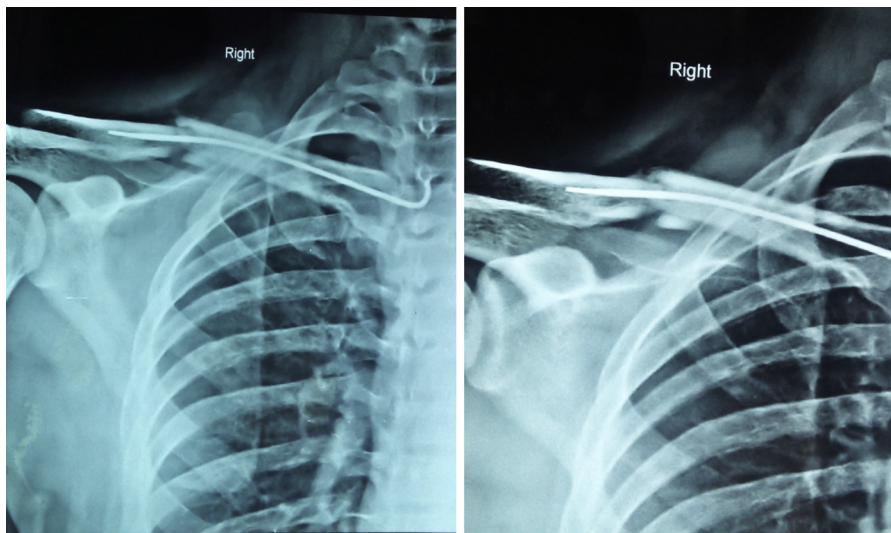


Fig. 4 – Fracture went for delayed union with ESIN in situ. ESIN, elastic stable intramedullary nailing.

patients (9.2%) had temporary paraesthesia which got settled in two weeks. In our study, we did not have much implant related problems as we had a standard protocol to remove it after radiological union at six months.

We compared the final clavicular lengths after full radiological union and implant removal. In OTA type B fractures, in six cases (21%) we had clavicular shortening of 1 cm. In four cases (14%) we had 0.5 cm shortening. We did not have much significant shortening in OTA type A fractures.

All patients returned to work within 10 weeks of post operative period. The functional outcome was evaluated by using Constant score at each follow up. All patients with one year follow up were included in the study, the average Constant score was 97.8(Max-99, Min-95). Statistical data of constant score in our study had standard deviation 2.4, sample variance=5.7, standard error=0.25, skewness = -0.57 and the study was considered as significant ($p \leq 0.05$).

Discussion

Traditionally, from Hippocratic era, mid shaft clavicle fractures were treated conservatively.¹⁵ Numerous closed treatment options have been described to immobilize and align the fracture. Almost all authors thought maintaining the alignment after closed reduction of DMCF is a wishful thinking.¹⁶ The closed treatment methods include, simple sling or a figure of eight bandage. It has a very high rate of nonunion and malunion.³ Two third of the conservatively managed DMCF will end up in some degree of malunion. Shortening of about 1.4-2 cm has been reported to be critical deficit for development of a symptomatic malunion. This results in pain, loss of strength, rapid fatigability, paraesthesia of the arm and hand, problems with sleeping on the back and cosmetic complaints.⁴

The reported incidence of unsatisfactory outcome after closed treatment of DMCF varied from 4.4 to 31%.^{4,17,18}

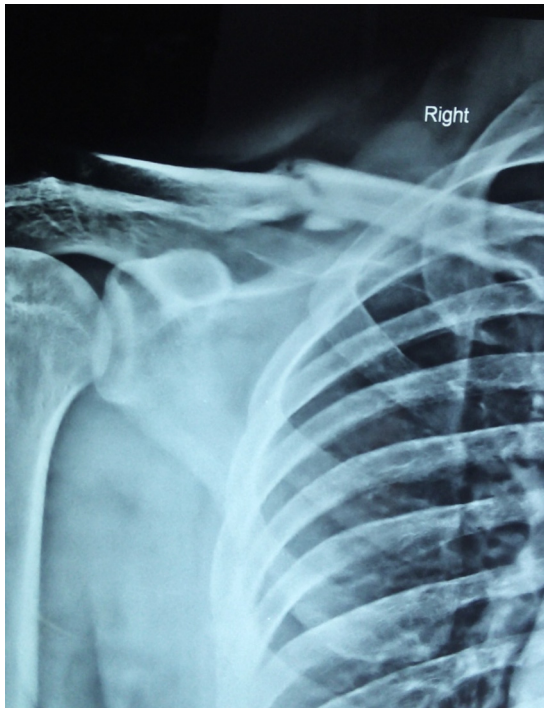


Fig. 5 – Fracture united eventually and underwent implant removal.



Fig. 6 – Patient had a good functional outcome with a constant score of 97.

The most common symptom is residual pain during activity or even at rest and loss of strength. The symptoms are mainly due to shortened lever arm of the shoulder girdle which changes the orientation of the glenoid with winging of scapula. Change in orientation of glenoid increases the shearing force across the shoulder joint, resulting in protraction as well as tilt of scapula can result in pain during lying on the back.^{19,20}

The shortened clavicle has a negative effect on muscle tendon tension resulting in loss of strength and endurance.^{20,21} It also changes the resting angle of the sternoclavicular joint

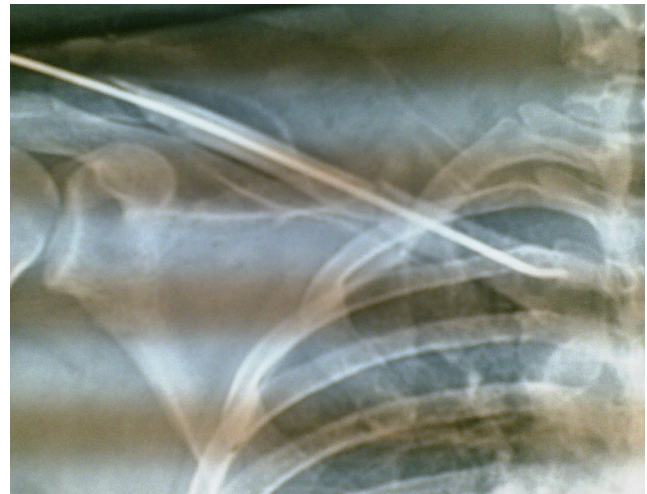

Fig. 7 – Lateral migration of ESIN. ESIN, elastic stable intramedullary nailing.

resulting in change of load in both acromioclavicular and sternoclavicular joint with increase incidence of acromioclavicular arthritis.^{17,20} Large callus formation after malunion can lead to neurovascular problems as a result of thoracic outlet syndrome.²²

Anatomically aligned united mid shaft clavicle fracture is always superior over conservatively treated clavicle. The only way to achieve this is an open reduction with internal fixation or a percutaneous procedure. Hence, current recommendation for this fractures is operative fixation.^{4,17,21,23} Plate osteosynthesis,^{23,24} external fixation²⁵ and intramedullary fixation^{9,26-28} have all been described for surgical treatment of clavicle fractures, every modality of surgical intervention has its own pros and cons.

Plating is the gold standard operative procedure for DMCF, as it restores length and alignment anatomically and mechanically even in comminuted fractures by becoming the strongest implant.^{23,24} Studies have shown comminution in clavicle fractures is a negative prognostic indicator.²⁹ Plating is the most discussed and its long term experience in literature is mentioned. It is a less demanding procedure that provides rigid fixation and compression for early rehabilitation. However this technique may require larger incision and extensive exposure which could cause complications such as infections, implant failure, refracture after implant removal, neurovascular injury, nonunion, dysesthesia and keloid scar.^{30,31} A recent report of a prospective randomized trial described an incidence with adverse events of 37%, however the proportion of complications in non-operative group was 63%.²³

The neurovascular damage with screw placement in plating can be reduced by placing it anteroinferiorly, but anterosuperior plating offers a more secure fixation.³² The implant related problems in plating has now been addressed with specifically designed plates with angular stability.^{24,33} Plate fixation is technically easy to perform and long term experience is available. With improved implants, prophylactic antibiotics and better soft tissue handling, plate fixation has been reliable and reproducible technique. Despite experience

and improvement of plate fixation, it is not free of complications. External fixation is rarely used in clavicular fixation. Its absolute indication is only in open clavicle fractures.²⁵

So, another emerging mode of fixation is percutaneous intramedullary fixation with ESIN.^{9,34,35} It is also minimally invasive, conserves fracture haematoma and periosteum that encourages copious callous formation and improve cosmesis. Studies have shown the average time of union is significantly faster as it provides relative stability. It can be done by antero-grade or retrograde technique. Intramedullary fixation with nails or pins has minimally invasive characteristics, including smaller skin incisions, reduced soft tissue stripping, less blood loss, shorter operative time, shorter hospital stay, shorter time for union and few major complications.³⁶ Intramedullary fixation is technically more demanding and operative outcome may be influenced by learning curve of the involved surgeon.^{36,37} It also depends upon the degree how much the implant has to be flexible and small enough to be able to pass through the narrow medullary canal and offer a rigid stability needed for the clavicle. In approximately 50% of cases, an extra incision is needed to facilitate fracture reduction and guide the pin through the fracture site.¹³ This may negatively affect the outcome due to an increase in incision length and fracture healing due to disruption of periosteum and fracture haematoma.

The main complications of ESIN are migration and perforation of device. Although they are minor complications in literature, they are reported to be in range of 5.2–38.8%.^{34,36,38} It is primarily due to inadequately cut medial end of the nail during surgery and secondarily due to clavicular shortening. These complications can be reduced by adequately cutting the nail, use of medial end caps, good anatomical reduction and intra-operative compression and by avoiding shoulder abduction beyond 90 degrees in first two weeks postoperatively.

In our study, we had an excellent union rates in all cases. In one case we had delayed union, in OTA type B fracture, where we did a mini open technique. We did open reduction in 55% of cases which was comparable to other studies.¹³ Incidence of open reduction depends on the learning curve of the surgeon.^{36,37} In our study, the technique was done by two well-trained surgeons. The main complications in our study was medial skin irritation (27%), so we routinely removed the nail after fracture union. In one case, patient had a fall and had an implant migration at the medial end and perforation at the lateral end and the nail was removed through a separate incision at the lateral end after fracture union. All other minor complications such as superficial infections, temporary paraesthesia got settled and our final clavicular shortening was 1 cm in OTA type B fractures, so there was no symptomatic malunion. In our series, the result of shoulder function was assessed by constant scores and was better in comparison to conservatively managed DMCF and in par with other studies with ESIN.^{26,27}

Our study also has limitations, it is a relatively small retrospective series of patients with a mean follow up of fourteen months, we did not compare study with other methods of fixation, our complications were less as we did routine nail removal, we cannot comment regarding symptomatic malunion as we did not have long-term follow up and we excluded OTA type C fractures, where ESIN produces more shortening,

so plate fixation remains the operative procedure of choice as it offers better clavicular length maintenance.⁵

Conclusion

ESIN is a safe, minimally invasive technique in indicated cases. We had favourable results with this technique but needs a lot of expertise. We do not recommend this technique in severely comminuted DMCF.

Conflicts of interest

The authors declare no conflicts of interest.

REFERENCES

1. Postacchini F, Gumina S, Santis P, Albo F. Epidemiology of clavicle fractures. *J Shoulder Elbow Surg.* 2002;11(5):452–6.
2. Nordqvist A, Peterson C. The incidence of fractures of the clavicle. *Clin Orthop Relat Res.* 1994;(300):127–32.
3. Robinson CM, Court-Brown Cm, McQueen MM, Wakefield AE. Estimating the risk of nonunion following nonoperative treatment of a clavicular fractures. *J Bone Joint Surg Am.* 2004;86(7):1359–65.
4. Lazarides S, Zafropoulos G. Conservative treatment of fractures at the middle third of the clavicle. The relevance of shortening and clinical outcome. *J Shoulder Elbow Surg.* 2006;15(2):191–4.
5. Smekal V, Oberladstaetter J, Struve P, Krappinger D. Shaft fractures of the clavicle: current concepts. *Arch Orthop Trauma Surg.* 2009;129(6):807–15.
6. Peroni L. Medullary osteosynthesis in the treatment of clavicle fractures. *Arch Ortop.* 1950;63(4):398–405.
7. Lee YS, Lin CC, Huang CR, Chen CN, Liao WY. Operative treatment of midclavicular fractures in 62 elderly patients: knowles pin versus plate. *Orthopedics.* 2007;30(11):959–64.
8. Mudd CD, Quigley KJ, Gross LB. Excessive complications of open intramedullary nailing of midshaft clavicle fractures with the Rockwood Clavicle Pin. *Clin Orthop Relat Res.* 2011;469(12):3364–70.
9. Mueller M, Rangger C, Striepens N, Burger C. Minimally invasive intramedullary nailing of midshaft clavicular fractures using titanium elastic nails. *J Trauma.* 2008;64(6):1528–34.
10. Millett PJ, Hurst JM, Horan MP, Hawkins RJ. Complications of clavicle fractures treated with intramedullary fixation. *J Shoulder Elbow Surg.* 2011;20(1):86–91.
11. Smith MV, Calfee RP, Baumgarten KM, Brophy RH, Wright RW. Upper extremity-specific measures of disability and outcomes in orthopaedic surgery. *J Bone Joint Surg Am.* 2012;94(3):277–85.
12. O'Neill BJ, Hirpara KM, O'Briain D, McGarr C, Kaar TK. Clavicle fractures: a comparison of five classification systems and their relationship to treatment outcomes. *Int Orthop.* 2011;35(6):909–14.
13. Ferran NA, Hodgson P, Vannet N, Williams R, Evans RO. Locked intramedullary fixation vs plating for displaced and shortened mid-shaft clavicle fractures: a randomized clinical trial. *J Shoulder Elbow Surg.* 2010;19(6):783–9.
14. Chen YF, Zeng BF, Chen YJ, Wang HM, Xue JF, Chai YM, et al. Clinical outcomes of midclavicular fractures treated with titanium elastic nails. *Can J Surg.* 2010;53(6):379–84.

15. Neer CS. Fractures of the clavicle. In: Rockwood CA, Green DP, editors. Fractures in adults. Philadelphia: JB Lippincott; 1984. p. 707-13.
16. Rowe CR. An atlas of anatomy and treatment of midclavicular fractures. Clin Orthop Relat Res. 1968;58:29-42.
17. Hill JM, McGuire MH, Crosby LA. Closed treatment of displaced middle-third fractures of the clavicle gives poor results. J Bone Joint Surg Br. 1997;79(4):537-9.
18. Nowak J, Holgersson M, Larsson S. Sequelae from clavicular fractures are common: a prospective study of 222 patients. Acta Orthop. 2005;76(4):496-502.
19. Andermahr J, Jubel A, Elsner A, Prokop A, Tsikaras P, Jupiter J, et al. Malunion of the clavicle causes significant glenoid malposition: a quantitative anatomic investigation. Surg Radiol Anat. 2006;28(5):447-56.
20. Ledger M, Leeks N, Ackland T, Wang A. Short malunions of the clavicle: an anatomic and functional study. J Shoulder Elbow Surg. 2005;14(4):349-54.
21. McKee MD, Wild LM, Schemitsch EH. Midshaft malunions of the clavicle. J Bone Joint Surg Am. 2003;85(5):790-7.
22. Onstenk R, Malessy MJ, Nelissen RG. Brachial plexus injury due to unhealed or wrongly healed clavicular fracture. Ned Tijdschr Geneesk. 2001;145(50):2440-3.
23. Canadian Orthopaedic Trauma S. Nonoperative treatment compared with plate fixation of displaced midshaft clavicular fractures. A multicenter, randomized clinical trial. J Bone Joint Surg Am. 2007;89(1):1-10.
24. Mullaji AB, Jupiter JB. Low-contact dynamic compression plating of the clavicle. Injury. 1994;25(1):41-5.
25. Schuind F, Pay-Pay E, Andrienne Y, Donkerwolcke M, Rasquin C, Burny F. External fixation of the clavicle for fracture or non-union in adults. J Bone Joint Surg Am. 1988;70(5):692-5.
26. Khalil A. Intramedullary screw fixation for midshaft fractures of the clavicle. Int Orthop. 2009;33(5):1421-4.
27. Kleweno CP, Jawa A, Wells JH, O'Brien TG, Higgins LD, Harris MB, et al. Midshaft clavicular fractures: comparison of intramedullary pin and plate fixation. J Shoulder Elbow Surg. 2011;20(7):1114-7.
28. Liu HH, Chang CH, Chia WT, Chen CH, Tarng YW, Wong CY. Comparison of plates versus intramedullary nails for fixation of displaced midshaft clavicular fractures. J Trauma. 2010;69(6):E82-7.
29. Nowak J, Holgersson M, Larsson S. Can we predict long-term sequelae after fractures of the clavicle based on initial findings? A prospective study with nine to ten years of follow-up. J Shoulder Elbow Surg. 2004;13(5):479-86.
30. Böstman O, Manninen M, Pihlajamäki H. Complications of plate fixation in fresh displaced midclavicular fractures. J Trauma. 1997;43(5):778-83.
31. Poigenfürst J, Rappold G, Fischer W. Plating of fresh clavicular fractures: results of 122 operations. Injury. 1992;23(4):237-41.
32. Kloen P, Werner CM, Stufkens SA, Helfet DL. Anteroinferior plating of midshaft clavicle nonunions and fractures. Oper Orthop Traumatol. 2009;21(2):170-9.
33. Kabak S, Halici M, Tuncel M, Avsarogullari L, Karaoglu S. Treatment of midclavicular nonunion: comparison of dynamic compression plating and low-contact dynamic compression plating techniques. J Shoulder Elbow Surg. 2004;13(4):396-403.
34. Smekal V, Irenberger A, Struve P, Wambacher M, Kralinger FS. Elastic stable intramedullary nailing versus nonoperative treatment of displaced midshaft clavicular fractures - a randomized, controlled, clinical trial. J Orthop Trauma. 2009;23(2):106-12.
35. Jubel A, Andermahr J, Bergmann H, Prokop A, Rehm KE. Elastic stable intramedullary nailing of midclavicular fractures in athletes. Br J Sports Med. 2003;37(6):480-3.
36. Frigg A, Rillmann P, Perren T, Gerber M, Ryf C. Intramedullary nailing of clavicular midshaft fractures with the titanium elastic nail: problems and complications. Am J Sports Med. 2009;37(2):352-9.
37. Witzel K. Intramedullary osteosynthesis in fractures of the mid-third of the clavicle in sports traumatology. Z Orthop Unfall. 2007;145(5):639-42.
38. Jubel A, Andermahr J, Schiffer G, Tsironis K, Rehm KE. Elastic stable intramedullary nailing of midclavicular fractures with a titanium nail. Clin Orthop Relat Res. 2003;(408):279-85.