



## ORIGINAL ARTICLE

# Outcomes in patients undergoing robotic reconstructive uterovaginal anastomosis of congenital cervical and vaginal atresia

Ying Zhang  | Yisong Chen | Keqin Hua

Department of Gynecology, The Obstetrics and Gynecology Hospital of Fudan University, Shanghai, China

**Correspondence**

Dr Keqin Hua, Department of Gynecology, The Obstetrics and Gynecology Hospital of Fudan University, 128 Shenyang RD, Shanghai 200090, China.

Email: huakeqin@gmail.com

**Funding information**

Shanghai Hospital Development Center, Grant/Award Number: SHDC12015117

**Abstract**

**Objective:** To introduce our experience of robotic surgery of reconstructive uterovaginal anastomosis and operative outcomes in congenital cervical and vaginal atresia patients.

**Methods:** Clinical observation and follow-up of four patients with congenital cervical and vaginal atresia who underwent robotic reconstruction of cervix and vagina by SIS (small intestinal submucosa, SIS) graft.

**Results:** Average patient age was  $13.8 \pm 2.2$ . Patients complained of severe periodic abdominal pain. Diagnosis was made according to clinical characteristics, physical examination, MRI and classified by ESHRE/ESGE system. All patients underwent reconstruction of cervix and vagina by uterovaginal anastomosis by SIS graft. Average operation time was  $232.5 \pm 89.2$  min, average blood loss was  $225.0 \pm 95.7$  mL. After surgery, all patients have regular menstruation without pain. Average follow up was 12 months, average vagina length was  $8.9 \pm 0.3$  cm, average vagina width was  $2.9 \pm 0.1$  cm.

**Conclusion:** Robotic assisted reconstruction of cervix and vagina is feasible from our experience, enlarged cases and additional studies are required.

**KEYWORDS**

cervical atresia, robotic surgery, small intestinal submucosa (SIS) graft, uterovaginal anastomosis

## 1 | INTRODUCTION

Congenital cervical atresia including cervical agenesis and cervical dysgenesis<sup>1</sup> is a rare Mullerian abnormality of the female reproductive tract, first reported by Ludwig in 1900.<sup>2</sup> The incidence is about one in every 80 000 to 100 000 births.<sup>3</sup> It is known to be associated with both partial and complete vaginal aplasia and renal anomalies.<sup>4</sup> It is defined as absent or aplasia of the cervix and characterized either by the absolute absence of any cervical tissue or by the presence of severely defected cervical tissue such as cervical cord or cervical fragmentation.<sup>5</sup> It will cause significant morbidity and mortality, if not diagnosed and definitively treated early.

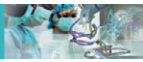The diagnosis was made according to clinical symptom and sign, such as amenorrhea, cyclical abdominal pain and pelvic hematometra. Ultrasound and MRI (magnetic resonance imaging) are the two most important examinations for diagnosis. Different diagnosis include high transverse vaginal septum and imperforate hymen.

There are several classifications of cervical atresia, including the Buttram classification,<sup>6</sup> the American Fertility Society Classification of Mullerian Anomalies,<sup>7</sup> Rock. Congenital uterine cervical anomalies,<sup>8</sup> and ESHRE/ESGE classification.<sup>5</sup>

The etiology of the disease is not very clear. Most uterine anomalies result from a defect in the development or fusion of the paired Mullerian ducts during embryogenesis. Although familial aggregations

This is an open access article under the terms of the Creative Commons Attribution-NonCommercial-NoDerivs License, which permits use and distribution in any medium, provided the original work is properly cited, the use is non-commercial and no modifications or adaptations are made.

© 2017 The Authors The International Journal of Medical Robotics and Computer Assisted Surgery Published by John Wiley & Sons Ltd.



have been reported for some uterine anomalies, it is generally accepted that uterine anomalies result from a polygenic mechanism.<sup>9</sup>

The management of cervical atresia remains controversial because there are no guideline nor carefully designed cohort or randomized trials to support a best surgical practice. Until today, total hysterectomy still offers numerous benefits and is supported as a treatment option by several authors. Uterovaginal anastomosis is the restoration of the genital tract by direct suturing of the isthmus uteri to the vagina. It offers an alternative for patients to maintain menstruation. However, the experience from reconstructive uterovaginal anastomosis is limited. Here, we report four cases of cervical atresia of ESHRE/ESGE classification C4V4 who underwent reconstructive uterovaginal anastomosis with SIS (small intestinal submucosa, SIS) graft by robotic surgery. The purpose of this particular paper is to review the surgical approach in four patients with cervical-vaginal agenesis, and to analyze their operative outcomes after 12 months.

## 2 | METHODS

We enrolled four patients diagnosed with cervical and vaginal atresia (C4V4;ESHRE/ESGE) who underwent robotic assisted reconstruction of cervix and vagina by SIS graft during 2015. This study was approved by the Ethics Committee of the Obstetrics and Gynecology Hospital of Fudan University. Written informed consent for the treatment was obtained from the patient and their parents. Before surgery, all patients were informed about potential risks and benefits of the intervention.

### 2.1 | Clinical manifestation

Average patient age was  $13.8 \pm 2.2$  years. Patients have periodic pain of abdomen for 2 to 24 months. Gynecological examinations showed normal vulva with no vagina or cervix. There was different sized hematometra in the pelvis. Mammary development is Tanner IV to V. Serum hormone levels such as E2, FSH, LH were all within normal range. One patient has a single kidney. MRI confirmed diagnosis of cervical and vaginal atresia. Two patients were classified as U3C4V4 according to ESHRE/ESGE classification, the other two patients were UOC4V4 (Figure 1).

### 2.2 | Surgical procedures

On the day before surgery, all patients received a clear fluid diet and bowel preparation and prophylactic antibiotic therapy (cefotiam and ornidazole) was intravenously administered 30 min before the surgery. All the patients underwent operation at the end of menstruation. The same surgeon (K.H.) and surgical team performed all four procedures.

The Da Vinci robot (Intuitive Surgical, Sunnyvale, CA, USA) was docked in a standard fashion at the foot of the bed, between the legs of the patient. All patients underwent surgery under general anesthesia. The patient was in lithotomy position with both arms tucked comfortably. A Foley catheter was placed to empty the bladder and control urine output after anesthesia. Pneumoperitoneum to 15 mmHg was established with a closed Veress needle insertion, just above the

umbilicus. A 12 mm port was placed 4 cm above the umbilicus for insertion of the robotic videolaparoscope. Two 8 mm robotic trocars were placed bilaterally on the anterior line axillary, 2 cm above the umbilicus. An ancillary 5 mm trocar was placed in the left 8 cm away from the videolaparoscope trocars and the other 12 mm trocar was placed 1 cm above the anterior superior spine point, these two trocars were used by the assistant surgeon. A 30-degree camera was used for the entire procedure.

After docking, the primary surgeon controlled the robot from the console. We use monopolar scissors with Arm 1 on the right side of the patient and bipolar forceps with Arm 2 on the left side. Power setting of about 30 w with either cutting or cautery was used. Vessels smaller than 3 mm were coagulated using monopolar scissors, and bipolar forceps were used with larger vessels.

First, we check out the whole pelvis, because of the obstacle of the low segment of the uterus, all four patients had adhesion and endometriosis. We used the monopolar scissor and bipolar forceps to separate the adhesion and exposed the uterus, ovaries and fallopian.

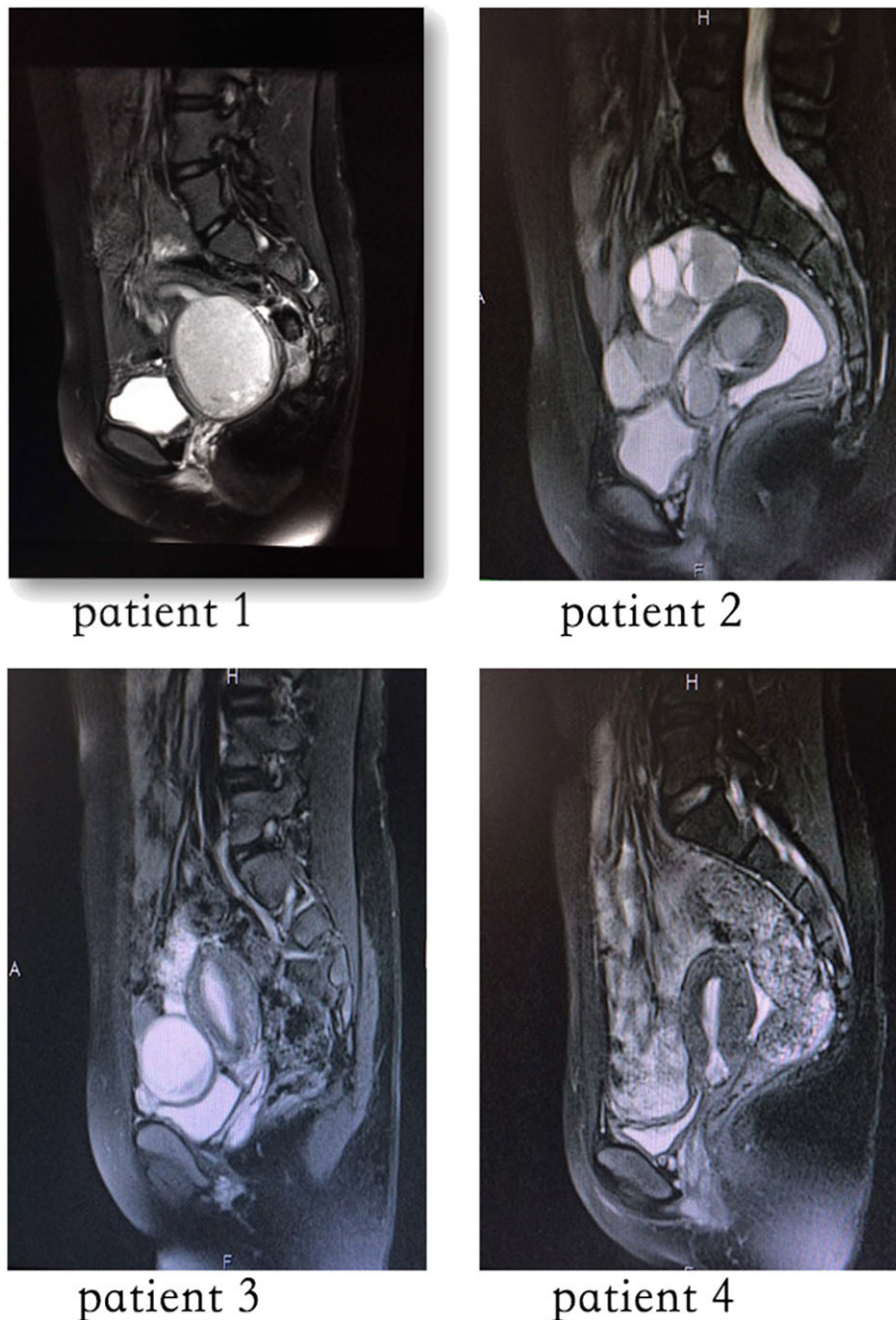
The second stage was to open the peritoneum between the bladder and the low segment of the uterus to separate the bladder and explore the lowest part of the uterus corpus and to verify the diagnosis of cervical atresia and the classification. According to the ESHRE/ESGE system, two of the patients were classified as U3C4V4.

In the third step, we use monopolar scissors to open the lowest part of the haematometra and let the residual blood flow out. Meanwhile, the other surgeon created a neovagina by vaginal surgery. Three hundred millilitres of normal saline containing 2.0 mg of phenylephrine and methylthionium chloride (blue dye) was injected along the anatomical vaginal route between the bladder/the urethra and the rectum. During the injection, one finger of the operator was inserted in the anus, to ensure there was no injury to the rectum. And at the same time, a metal urinary drainage tube was inserted into the urethra and bladder to check for any outflow of the blue dye through the tube, to ensure no injury of the urethra or bladder. Then a midline incision at the vaginal introitus was made, and a 10 cm long, 3 cm wide canal was created using blunt dissection along the anatomical vaginal route. And the top of the canal was opened by monopolar scissors.

A 14-French Foley catheter was cut and connected with a  $\gamma$ -shaped intrauterine device (IUD) (Figure 2). The IUD was made of plastic and copper. The stem of the IUD was connected to the short catheter and inserted into the uterine cavity through the neovagina to keep the newly created cervix patent.

A 20 \*7 cm SIS graft (Surgisis, Cook Medical, Bloomington, IN, USA) was trimmed and sutured with 2/0 PDS II delayed absorbable material (Ethicon, Somerville, NJ, USA) to wrap around a 2.7 cm diameter and 10 cm long vaginal mould (Figure 3).

Step 4 is anastomosis. Change Arm 1 with needle handler. A permanent lower uterine cerclage was performed with a Mersilene tape TM (Ethicon, Somerville, NJ, USA) by continuous suture. We put the graft into the neovagina and anastomosis with the incision of the lowest part of the uterus by continuous sutures using absorbable stitches. From our experience of uterovaginal anastomosis, it is easier to start from the posterior side and robotic suture is more flexible with its' rotation needle handler. After anastomosis, a vaginal mould was then



**FIGURE 1** Magnetic resonance images of the four patients

placed in the neovagina. The lower end of the graft was sutured to the vestibular mucosa separately through vaginal.

For the two patients classified U3C4V4, we performed fusion of uterus to make the uterine cavity spacious. We used monopolar to open both cavity and stitched each anterior and posterior wall continuously with absorbable materials to form a new cavity.

7 days after operation the vaginal mould was exchanged and the neovagina was irrigated with 10% povidone-iodine.

Patients were instructed to wear the vaginal mould for about 12 months in succession. The IUD connected with the catheter was also recommended to be maintained for 12 months. Patients were assessed post-operatively every 3 months, the menstrual

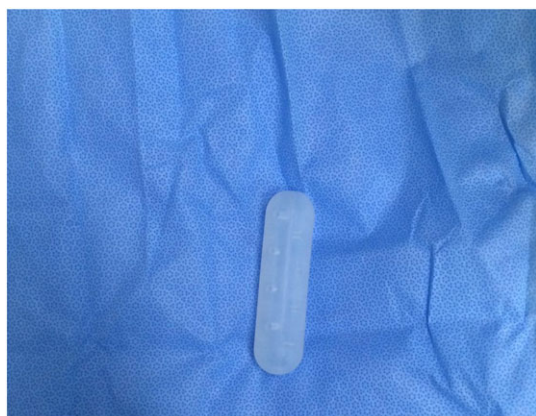pattern and the morphological results of the neovagina were also recorded.

### 3 | RESULTS

All four patients recovered well and reserved their uterus after robotic surgery without any complication. Average operation time was  $232.5 \pm 89.2$  min, average blood loss was  $225.0 \pm 95.7$  mL (Table 1). Hospital days after surgery were  $10 \pm 1.4$ . After surgery, all patients have regular menstruation without periodic pain. Average follow-up was 12 months, average vagina length was  $8.9 \pm 0.3$  cm, vagina width was  $2.9 \pm 0.1$  cm (Table 2). There was no re-admission.



**FIGURE 2** Part of 14-French Foley catheter connected with a y-shaped intrauterine device



**FIGURE 3** Silicone vaginal mould

## 4 | DISCUSSION

As a rare abnormality of the lower genital tract, cervical atresia with or without vaginal atresia is difficult both in diagnosis and treatment. MRI is the diagnostic gold standard.<sup>10</sup> Here, we agree the decision to include all variants of cervical dysgenesis in sub-class C4 as was made by the ESHRE/ESGE classification<sup>5</sup> to avoid an extremely extensive sub-classification, which does not seem to be user friendly.

We recommend early operation as the management of the disease. As early diagnosis and surgery is necessary to prevent endometriosis among patients with congenital cervical atresia<sup>11</sup> and can prevent significant morbidity and mortality.

Various methods of cervical reconstruction have been described in an attempt to create an epithelialized uterovaginal fistula to allow cyclic menstruation. However, many post-operative complications

are observed. Traditionally, hysterectomy has been the preferred mode of treatment owing to the high rate of recurrent cervical obstruction and risk of infection.<sup>8</sup> But hysterectomy leads to infertility and can have adverse effects on young patients. From our experience, we recommend the uterovaginal anastomosis as the first recommendation for all patients and epithelialization with a suitable graft of the neocervical canal.

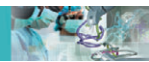In our study, all four patients underwent epithelialization with SIS graft. SIS graft is derived from the submucosal layer of pig small intestine that has been mechanically separated from the adjoining intestinal layers. It is one kind of extracellular matrix (ECM)-based collagen material. The graft is acellular and composed of noncross-linked collagen (types I, III and V), glycosaminoglycans, proteoglycans, glycoproteins and multiple growth factors.<sup>12</sup> Studies have demonstrated tissue incorporation and epithelialization in Mayer-Rokitansky-Ku<sup>ster</sup>-Hauser syndrome (MRKHS) patients.<sup>13</sup> The SIS is de-cellularized, biocompatible and does not produce an immunologic rejection response. It was reported to promote rapid growth and epithelialization of surrounding tissue.<sup>14</sup> From the follow-up of the four patients, the neovagina and anastomosis part all epithelialized to different levels. No stenosis occurred.

Uterovaginal anastomosis can be performed by laparotomy, laparoscopy and robotics. As minimally invasive surgery is important for patients, especially for younger patients, laparoscopic or robotic surgery may be more favorable. The disadvantages of the laparoscopic approach include two-dimensional vision, dependence on assistance skill, decreased range of motion and the degrees of freedom of the instruments. The incorporation of robotics brings unique benefits to surgery, including intraoperative wrist-like motion of the robotic arms, which provides finer and more dexterous movements to perform a delicate dissection and suture.<sup>15</sup> We recommend moving the trocars up in order to make a spacious cavity to perform surgery as most patients were teenagers.

After surgery, all the patients should wear the vaginal mould for about 12 months. For a teenage girl, it is very inconvenient and awkward to wear the vaginal mould. They cannot take part in strenuous exercise like running and swimming. Most of them stopped physical education classes. And one of them was absent from school for half a year. The disease and treatment have adverse effects on their social life. The procedure and opportunity for treatment needs improvement.

Clinical review every 3 months is recommended after surgery. Patients should take care of their volume of menstrual flow and if dysmenorrhea or periodic pain recur it is highly indicative of stenosis.

For patients with cervical atresia, uterovaginal anastomosis can maintain their menstruation and fertility potential. But successful pregnancy and delivery in a patient with congenital cervical atresia is a great challenge. Several factors may contribute to infertility in women with corrected cervical atresia, including deficient cervical mucus production, absence of functioning endometrium, hematometra formation, severe progressive endometriosis, and post-operative adhesive formation following surgical correction of the disorders.<sup>16</sup> Anttila *et al.* reported successful pregnancy after IVF and transmyometrial ET in a patient who had failed cervical reconstructive surgery.<sup>17</sup> After that, favorable pregnancy outcomes were described

**TABLE 1** Clinical characteristics of four patients with congenital complete vaginal and cervical atresia

Characteristics	Patient1	Patient2	Patient3	Patient4
Age (years)	12	13	13	17
Complaints	Periodic pain of abdomen for 2 months	Periodic pain of abdomen for 2 years	Periodic pain of abdomen for 1 month	Periodic pain of abdomen for 2 years
Gynecological examinations	Normal vulva with no vagina nor cervix,a 7 cm diameter hypertension mass in the pelvic	Normal vulva with no vagina nor cervix,a 5 cm diameter mass in the pelvic	Normal vulva with no vagina nor cervix,a 4 cm diameter mass in the pelvic	Normal vulva with no vagina nor cervix,a 6 cm diameter mass in the pelvic
MRI	Unicornous uterus in the right side, with the lower segment expanded to 7 cm of diameter, no sign of vagina nor cervix.,absent of the right kidney	Unicornous uterus in the left side, rudimentary horn of the uterus in the right side,with the hematometra of 5 cm,no sign of vagina nor cervix	No sign of vagina nor cervix with the hematometra of 4 cm in the lower segment of the uterus	No sign of vagina nor cervix with the hematometra of 6 cm in the lower segment of the uterus
Urinary system	Single kidney	Normal	Normal	Normal
Diagnosis	Congenital complete vaginal and cervical atresia with hemi-uterus	Congenital complete vaginal and cervical atresia with hemi-uterus	Congenital complete vaginal and cervical atresia	Congenital complete vaginal and cervical atresia
ESHRE/ESGE classification	U3C4V4	U3C4V4	U0C4V4	U0C4V4
Operation	Robotic assisted reconstruction of cervix and vagina by SIS graft and fusion of hemi-uterus	Robotic assisted reconstruction of cervix and vagina by SIS graft and fusion of hemi-uterus	Robotic assisted reconstruction of cervix and vagina by SIS graft	Robotic assisted reconstruction of cervix and vagina by SIS graft
Hospital days after surgery	11	11	10	8
Operation time (min)	260	340	200	130
Blood loss (ml)	300	300	200	100

**TABLE 2** Follow-up information on patients after robotic surgery

Characteristics	Patient1	Patient2	Patient3	Patient4
Follow up time (month)	15	12	11	10
Menstruation (day)	7per30–40	6 per 30–40	6 per 30	7 per 30
Periodic pain of abdomen	N	N	N	N
Vaginal mould wear(per day)	24 h	24 h	24 h	24 h
Length of vagina (cm)	9	8.5	9	9
Width of vagina (cm)	3	2.8	2.9	2.7

for different types of cervical agenesis and dysgenesis for women who underwent IVF, transmyometrial ET, transtubal ET, and spontaneously.<sup>18,19</sup> The surgery of cervico-vaginal anastomosis can provide patients with chances of spontaneous pregnancies. And before pregnancy and delivery, there are some potential obstetric complications patients must be counseled on, such as abortion, preterm delivery, cesarean section, uterine rupture, etc. In our study, all four patients were teenagers and we still need to follow-up their pregnancy outcomes.

## 5 | CONCLUSIONS

Our study found that cervical atresia might be successfully treated by uterovaginal anastomosis under robotics. We recommend the ESHRE/ESGE classification of cervical-vaginal abnormalities.

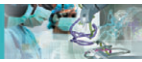With appropriate evaluation and individualized management, we believe that a successful treatment and pregnancy outcome might be achieved.

## ACKNOWLEDGMENTS

This work was supported by the foundation of Shanghai hospital development center (SHDC12015117). The authors thank colleagues in the Medical Record Department in the Obstetrics and Gynecology Hospital of Fudan University for their help. And also thank all the patients who took part in this study.

## CONFLICT OF INTEREST

None.



## REFERENCES

1. Li M, Zhang Z. Laparoscopically assisted biomaterial graft for reconstruction in congenital atresia of vagina and cervix. *Fertil Steril*. 2013;100(6):1784-1787.
2. Grimbizis GF, Tsalikis T, Mikos T, Papadopoulos N, Tarlatzis BC, Bontis JN. Successful end-to-end cervico-cervical anastomosis in a patient with congenital cervical fragmentation: Case report. *Hum Reprod*. 2004;19(5):1204-1210.
3. Al-Jaroudi D, Saleh A, Al-Obaid S, Agdi M, Salih A, Khan F. Pregnancy with cervical dysgenesis. *Fertil Steril*. 2011;96(6):1355-1356.
4. Shah TN, Venkatesh S, Saxena RK, Pawar S. Uterovaginal anastomosis for complete cervical agenesis and partial vaginal agenesis: A case report. *Eur J Obstet Gynecol Reprod Biol*. 2014;174:154-155.
5. Grimbizis GF, Gordts S, Di Spiezio Sardo A, et al. The ESHRE-ESGE consensus on the classification of female genital tract congenital anomalies. *Gynecol Surg*. 2013;10(3):199-212.
6. Buttram VC Jr, Gibbons WE. Mullerian anomalies: A proposed classification. (an analysis of 144 cases). *Fertil Steril*. 1979;32(1):40-46.
7. The American Fertility Society. Classifications of adnexal adhesions, distal tubal occlusion, tubal occlusion secondary to tubal ligation, tubal pregnancies, mullerian anomalies and intrauterine adhesions. *Fertil Steril*. 1988;49(6):944-955.
8. Rock JA, Roberts CP, Jones HW Jr. Congenital anomalies of the uterine cervix: Lessons from 30 cases managed clinically by a common protocol. *Fertil Steril*. 2010;94(5):1858-1863.
9. Taylor E, Gomel V. The uterus and fertility. *Fertil Steril*. 2008;89(1):1-16.
10. Kimble R, Molloy G, Sutton B. Partial cervical agenesis and complete vaginal atresia. *J Pediatr Adolesc Gynecol*. 2016;29(3):e43-e47.
11. Song X, Zhu L, Ding J, Xu T, Lang J. Clinical characteristics of congenital cervical atresia and associated endometriosis among 96 patients. *Int J Gynaecol Obstet*. 2016;134(3):252-255.
12. Soederer EE, Lantz GC, Kazacos EA, Hodde JP, Wiegand RE. Morphologic study of three collagen materials for body wall repair. *J Surg Res*. 2004;118(2):161-175.
13. Ding JX, Chen LM, Zhang XY, Zhang Y, Hua KQ. Sexual and functional outcomes of vaginoplasty using acellular porcine small intestinal submucosa graft or laparoscopic peritoneal vaginoplasty: A comparative study. *Hum Reprod*. 2015;30(3):581-589.
14. Ding JX, Chen XJ, Zhang XY, Zhang Y, Hua KQ. Acellular porcine small intestinal submucosa graft for cervicovaginal reconstruction in eight patients with malformation of the uterine cervix. *Hum Reprod*. 2014;29(4):677-682.
15. Damiani GR, Turolì D, Cormio G, et al. Robotic approach using simple and radical hysterectomy for endometrial cancer with long-term follow-up evaluation. *Int J Med Robot*. 2016;12(1):109-113.
16. Thijssen RF, Hollanders JM, Willemsen WN, van der Heyden PM, van Dongen PW, Rolland R. Successful pregnancy after ZIFT in a patient with congenital cervical atresia. *Obstet Gynecol*. 1990;76(5 Pt 2):902-904.
17. Anttila L, Penttilä TA, Suikkari AM. Successful pregnancy after in-vitro fertilization and transmyometrial embryo transfer in a patient with congenital atresia of cervix: Case report. *Hum Reprod*. 1999;14(6):1647-1649.
18. Xu C, Xu J, Gao H, Huang H. Triplet pregnancy and successful twin delivery in a patient with congenital cervical atresia who underwent transmyometrial embryo transfer and multifetal pregnancy reduction. *Fertil Steril*. 2009;91(5):1958.e1-1958.e3.
19. Huberlant S, Tailland ML, Poirey S, et al. Congenital cervical agenesis: Pregnancy after transmyometrial embryo transfer. *J Gynecol Obstet Biol Reprod (Paris)*. 2014;43(7):521-525.

**How to cite this article:** Zhang Y, Chen Y, Hua K. Outcomes in patients undergoing robotic reconstructive uterovaginal anastomosis of congenital cervical and vaginal atresia. *Int J Med Robotics Comput Assist Surg*. 2017;13:e1821. <https://doi.org/10.1002/rcs.1821>