

Relationship Between Clinical and Immunological Features with Magnetic Resonance Imaging Abnormalities in Female Patients with Neuropsychiatric Systemic Lupus Erythematosus

Hai-Peng Wang¹, Cui-Yan Wang¹, Zheng-Lun Pan², Jun-Yu Zhao³, Bin Zhao¹

¹Department of Magnetic Resonance Imaging, Shandong Medical Imaging Research Institute, Shandong University, Jinan, Shandong 250021, China

²Department of Internal Medicine, Division of Rheumatology, Qilu Hospital of Shandong University (Qingdao), Qingdao, Shandong 266035, China

³Department of Internal Medicine, Division of Endocrinology, Shandong Province Qianfoshan Hospital, Jinan, Shandong 250014, China

Abstract

Background: Conventional magnetic resonance imaging (MRI) is the preferred neuroimaging method in the evaluation of neuropsychiatric systemic lupus erythematosus (NPSLE). The purpose of this study was to investigate the association between clinical and immunological features with MRI abnormalities in female patients with NPSLE, to screen for the value of conventional MRI in NPSLE.

Methods: A total of 59 female NPSLE patients with conventional MRI examinations were enrolled in this retrospective study. All patients were classified into different groups according to MRI abnormalities. Both clinical and immunological features were compared between MRI abnormal and normal groups. One-way analysis of variance was used to compare the systemic lupus erythematosus disease activity index (SLEDAI) score for MRI abnormalities. Multivariate logistic regression analysis investigated the correlation between immunological features, neuropsychiatric manifestations, and MRI abnormalities.

Results: Thirty-six NPSLE patients (61%) showed a variety of MRI abnormalities. There were statistically significant differences in SLEDAI scores ($P < 0.001$), incidence of neurologic disorders ($P = 0.001$), levels of 24-h proteinuria ($P = 0.001$) and immunoglobulin M ($P = 0.004$), and incidence of acute confusional state ($P = 0.002$), cerebrovascular disease ($P = 0.004$), and seizure disorder ($P = 0.028$) between MRI abnormal and normal groups. In the MRI abnormal group, SLEDAI scores for cerebral atrophy (CA), cortex involvement, and restricted diffusion (RD) were much higher than in the MRI normal group ($P < 0.001$, $P = 0.002$, $P = 0.038$, respectively). Statistically significant positive correlations between seizure disorder and cortex involvement (odds ratio [OR] = 14.90; 95% confidence interval [CI], 1.50–151.70; $P = 0.023$) and cerebrovascular disease and infratentorial involvement (OR = 10.00; 95% CI, 1.70–60.00; $P = 0.012$) were found.

Conclusions: MRI abnormalities in NPSLE, especially CA, cortex involvement, and RD might be markers of high systemic lupus erythematosus activity. Some MRI abnormalities might correspond to neuropsychiatric manifestations and might be helpful in understanding the pathophysiology of NPSLE.

Key words: Magnetic Resonance Imaging; Neuropsychiatric Symptoms; Systemic Lupus Erythematosus; Systemic Lupus Erythematosus Disease Activity Index

INTRODUCTION

Systemic lupus erythematosus (SLE) is a chronic, systemic, autoimmune inflammatory disease characterized by a wide variety of clinical manifestations that affect multiple systems. The incidence of SLE has a striking 9:1 female predominance.^[1,2] Neuropsychiatric involvement is a sign of severe SLE and is the main cause of work loss,

Address for correspondence: Dr. Bin Zhao,

Department of Magnetic Resonance Imaging, Shandong Medical Imaging Research Institute, Shandong University, 324 Jingwu Road, Jinan, Shandong 250021, China
E-Mail: zhaobinyys@163.com

This is an open access article distributed under the terms of the Creative Commons Attribution-NonCommercial-ShareAlike 3.0 License, which allows others to remix, tweak, and build upon the work non-commercially, as long as the author is credited and the new creations are licensed under the identical terms.

For reprints contact: reprints@medknow.com

© 2016 Chinese Medical Journal | Produced by Wolters Kluwer - Medknow

Received: 08-11-2015 **Edited by:** Peng Lyu

How to cite this article: Wang HP, Wang CY, Pan ZL, Zhao JY, Zhao B. Relationship Between Clinical and Immunological Features with Magnetic Resonance Imaging Abnormalities in Female Patients with Neuropsychiatric Systemic Lupus Erythematosus. Chin Med J 2016;129:542-8.

Access this article online

Quick Response Code:



Website:
www.cmj.org

DOI:
10.4103/0366-6999.176996

reduced quality of life, and mortality in patients with SLE.^[3,4] Neuropsychiatric SLE (NPSLE) has diverse manifestations, varying from focal to diffuse. In 1999, the American College of Rheumatology (ACR) research committee published a set of case definitions for NPSLE manifestations^[5] that were divided into 12 central and 7 peripheral nervous system presentations. However, because of the different inclusion criteria and diagnostic methods used, the prevalence of NPSLE ranges from 13% to 91%,^[6-10] and only 33–40% of neuropsychiatric manifestations can be attributed directly to primary NPSLE.^[2,11]

The pathogenesis of NPSLE is still unknown. Increasing evidence from neuropsychiatric manifestations, imaging, and pathological studies indicate that an immune-mediated pathogenesis might account for NPSLE.^[2,9,12] Currently, the diagnosis of NPSLE is determined worldwide by the exclusion of other causes, assessment of clinical and immunological features, analysis of cerebrospinal fluid, electrophysiological studies, and neuroimaging combined^[2] but is lacking a gold standard.

Conventional magnetic resonance imaging (MRI) is the preferred neuroimaging method in the evaluation of NPSLE. It is widely available and exceptionally sensitive in some cases of NPSLE such as those with cerebral infarction, hemorrhage, and transverse myelitis. However, its sensitivity for lesions in white matter is low, at only 50–55%.^[11] Moreover, MRI abnormalities caused by primary NPSLE lacks specificity, making a differential diagnosis between primary and secondary NPSLE difficult.^[13] The validity and importance of MRI in the diagnosis of NPSLE are still not clear.^[14] Despite these disadvantages, conventional MRI could be useful to explore pathological mechanisms,^[12] facilitate differential diagnosis,^[11,15,16] quantify disease activity, and determine the prognosis of NPSLE.^[13] MRI often provides a better clue to the underlying causes of clinical manifestations in NPSLE than the manifestations themselves.^[17]

In this study, we investigated the association between clinical and immunological features and MRI abnormalities in female patients with NPSLE, to screen for the value of conventional MRI in NPSLE.

METHODS

In this retrospective study, all SLE inpatients with neuropsychiatric manifestations in Shandong provincial hospital from January 2001 to December 2013 were studied, and therefore informed consent was waived. All patients fulfilled, at least, four of the 11 ACR 1997 revised criteria for the classification of SLE,^[18] as well as at least one of the 1999 ACR case definitions^[5] for NPSLE manifestations. The neuropsychiatric manifestations of SLE patients were identified and classified by an experienced rheumatologist. The disease duration, clinical manifestations, immunological features, and treatment protocols of patients were recorded,

and the SLE disease activity index (SLEDAI) was used.^[19] The study protocol was approved by the institutional ethics committee of Shandong Medical Imaging Research Institute, Shandong University.

Exclusion criteria were: age >50 years; cerebral or systemic diseases that could cause neuropsychiatric manifestations, such as cerebral tumor, hypertensive cerebrovascular disease, multiple sclerosis, and reversible posterior leukoencephalopathy syndrome (RPLS); and neuropsychiatric manifestations in SLE patients attributed to secondary NPSLE such as inflammation, electrolyte disturbances, and drug intake.

Conventional MRI examinations were performed in all SLE patients in the study. The examinations were conducted with a 1.5-T device (Siemens Medical Systems, Magnetom Sonata Maestro Class, Germany) or a 3.0-T device (Philips Healthcare, Best, The Netherlands). Axial T1-weighted, T2-weighted, and fluid-attenuated inversion recovery cerebral images were acquired with 5 mm of thickness. Axial diffusion-weighted images (DWI) and apparent diffusion coefficient (ADC) and postcontrast T1-weighted images were also evaluated, if available. All acquired cerebral images were evaluated by an experienced neuroradiologist and were classified into two groups: MRI abnormal and MRI normal. The abnormal group was also classified into different groups according to various MRI abnormalities: periventricular white matter (PVWM) involvement, subcortical white matter (SWM) involvement, cortex involvement, basal ganglia (BG) involvement, infratentorial (IT) involvement, restricted diffusion (RD), and cerebral atrophy (CA). The Fazekas scale was used to determine the extent of PVWM and SWM involvement, which was graded as 0 = absence, 1 = punctate foci, 2 = beginning confluence of foci, and 3 = large confluent areas.^[20]

Statistical analysis

Categorical data were reported as a percentage, and continuous data as the mean \pm standard deviation (SD) or median (range). The normality of the variables was assessed by the Shapiro–Wilk test. Student's *t*-test was performed to compare the SLEDAI score between the MRI abnormal and normal groups. The Mann–Whitney *U*-test was performed to compare the immunological features between two groups. The χ^2 test was applied to evaluate the association of neuropsychiatric manifestations as independent variables between two groups. The neuropsychiatric manifestations with $P < 0.05$ were included in the subsequent multivariate logistic regression analysis, and analytical results were presented as the crude odds ratio (*OR*) and 95% confidence interval (*CI*).

One-way analysis of variance (ANOVA) was used to compare the SLEDAI score between different MRI abnormalities. The correlation between immunological features, certain neuropsychiatric manifestations, and various MRI abnormalities was also analyzed by using multivariate logistic regression analysis.

All statistical tests were two-sided, and a value of $P < 0.05$ was considered as statistically significant. The statistical analysis was carried out using SPSS version 19.0 (SPSS Inc., Chicago, IL, USA).

RESULTS

A total of 59 female SLE patients (median age: 24 years) were involved in the study. The median duration from SLE onset to neuropsychiatric events was 5.5 months, ranging from 10 days to 12 years. The mean SLEDAI of these patients was 24.4 ± 11.1 . Eleven of 19 ACR neuropsychiatric manifestations were present in the study, of which ten were central and one was peripheral nervous system manifestation. In these 59 patients, the most frequent neuropsychiatric manifestations were a headache (56%), acute confusional state (46%), seizure disorder (29%), and cerebrovascular disease (25%).

Six patients (10%) were diagnosed as having hypertension. However, their onset of neuropsychiatric manifestations was not believed related to high blood pressure. Fifteen patients (25%) had been on steroid therapy before the onset of neuropsychiatric manifestations and none had steroid psychosis. Five (9%) had a history of hypothyroidism that was well-controlled. Two (3%) had a history of diabetes mellitus.

Table 1 shows the clinical and immunological features of NPSLE patients in the MRI abnormal and normal groups. A total 36 NPSLE patients (61%) had an abnormal MRI. Compared with the MRI normal group, patients in the MRI abnormal group had higher SLEDAI scores ($P < 0.001$), higher incidence of neurologic disorders ($P = 0.001$), and higher levels of 24-h proteinuria ($P = 0.001$) and immunoglobulin M ($P = 0.004$). Among the univariate logistic regression analyses of the 11 neuropsychiatric manifestations seen in the study, acute confusional state ($P < 0.001$), cerebrovascular disease ($P = 0.003$), and seizure disorder ($P = 0.006$) were more likely to be present in the MRI abnormal group, with a headache more likely in the MRI normal group ($P = 0.026$). In the subsequent multivariate logistic regression analyses of neuropsychiatric manifestations, the incidence of acute confusional state ($P = 0.002$), cerebrovascular disease ($P = 0.004$), and seizure disorder ($P = 0.028$) showed statistically significant differences between MRI abnormal and normal groups [Table 2].

In the MRI abnormal group, white matter involvement (81%) was the most frequent MRI abnormality, with 19 patients (53%) showing SWM involvement and 15 (42%) showing PVWM involvement. In the SWM involvement group, the frontal lobe was the predilection site, observed in 13 patients (68%), and followed by the temporal and parietal lobes (63%). Most SWM involvement (68%) was bilateral and multiple. Using the Fazekas scale, eight patients (42%) with

SWM involvement showed punctate foci (Grade 1), seven patients (37%) showed beginning confluence of foci (Grade 2), and four patients (21%) showed diffuse involvement (Grade 3). In the PVWM involvement group, eight patients (53%) were rated as Grade 1 and seven patients (47%) as Grade 2; 80% of PVWM lesions were bilateral and multiple.

Gray matter involvement (56%) also had visible abnormalities in the MRI abnormal group. Cortex involvement was observed in ten patients (28%), of whom nine (90%) showed diffuse bilateral lesions and one had left frontal lobe involvement; 80% of those with cortex involvement showed corresponding SWM involvement. The PVWM in these ten patients was either not affected or only mildly affected. No predilection sites were found for cortex involvement. BG involvement was observed in 14 patients (39%), of whom ten (71%) showed bilateral BG involvement; all patients had adjacent PVWM involvement [Figure 1].

In addition, DWI and ADC images were available for 28 patients. RD (high DWI and low ADC) was performed in six patients (21%). There were no predilection sites for RD. The size of lesions varied from punctate to patchy. Postcontrast T1-weighted images were also acquired in 12 patients; enhancement was observed in three patients (25%), of whom one had mild enhancement in the bilateral BG region, one had multiple mild enhancement

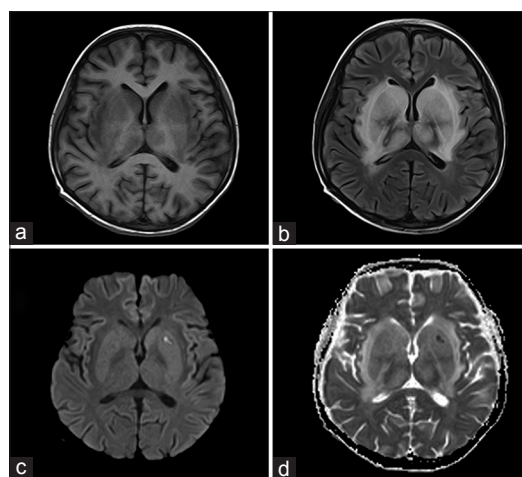


Figure 1: Diffuse BG involvement in a patient with active NPSLE, showing diffuse BG hypointensity on the T1-weighted images, (a) and increased signal intensity on the FLAIR images, (b) in an 11-year-old girl. Focal left lenticular nucleus high signal on DWI ($b = 1000$) (c) and low signal on the ADC map (d) were found, which indicated cytotoxic edema. In addition, white matter in the bilateral cerebral peduncles, temporal lobe, and centrum semiovale also was involved (not shown). The patient was hospitalized due to blunting of mood and affect and hydrosarca for 3 h and was diagnosed with active NPSLE. The SLEDAI score of this patient was 34. BG: Basal ganglia; NPSLE: Neuropsychiatric systemic lupus erythematosus; FLAIR: Fluid-attenuated inversion recovery; DWI: Diffusion weighted imaging; ADC: Apparent diffusion coefficient; SLEDAI: Systemic lupus erythematosus disease activity index.

Table 1: Clinical and immunological features in MRI abnormal and normal groups of female NPSLE patients

Variables	MRI abnormal group (n = 36)	MRI normal group (n = 23)	t/Z/ χ^2	P
Age (years), median (range)	25 (8, 48)	23 (5, 45)	-0.684 [†]	0.494
Duration of SLE (months), median (range)	21.0 (0.3, 240.0)	3.0 (0.7, 144.0)	-1.179 [†]	0.238
SLEDAI, mean \pm SD	28.8 \pm 11.5	17.5 \pm 7.3	4.594 [*]	<0.001
CRP (mg/L), median (range)	11.3 (0.7, 144.0)	4.0 (3.0, 21.4)	-1.666 [†]	0.096
ESR (mm/h), median (range)	55.0 (5.0, 119.0)	33.0 (1.0, 119.0)	-1.546 [†]	0.122
Proteinuria (g/24 h), median (range)	1.0 (0.1, 7.4)	0.1 (0.02, 1.9)	-3.242 [†]	0.001
ACR SLE criteria, n (%)				
Malar rash	22 (61)	18 (78)	1.891 [‡]	0.169
Discoid lupus	4 (11)	3 (13)	0.000 [‡]	1.000
Photosensitivity	9 (25)	6 (26)	0.000 [‡]	0.925
Oral ulcers	15 (42)	7 (30)	0.757 [‡]	0.384
Arthritis	22 (61)	16 (70)	0.438 [‡]	0.508
Pleuritis or pericarditis	6 (17)	3 (13)	0.000 [‡]	0.995
Renal disorders	18 (50)	9 (39)	0.668 [‡]	0.414
Neurologic disorder	26 (72)	6 (26)	12.035 [‡]	0.001
Hematologic disorder	18 (50)	6 (26)	3.326 [‡]	0.068
Immunologic disorder	24 (67)	18 (78)	0.920 [‡]	0.338
ANA positive	36 (100)	23 (100)	0.000 [‡]	1.000
Immunological features, median (range)				
Anti-dsDNA (RU/ml)	260.5 (10.0, 800.0)	453.3 (10.0, 800.0)	1.094 [†]	0.274
Anti SM (RU/ml)	19.6 (2.0, 193.6)	25.9 (2.0, 200.0)	0.289 [†]	0.773
ANuA (RU/ml)	24.1 (3.4, 200.0)	38.8 (2.0, 200.0)	0.550 [†]	0.582
Anti-RNP (RU/ml)	15.0 (2.7, 171.2)	24.9 (1.9, 200.0)	0.414 [†]	0.679
AHA (RU/ml)	18.7 (0.9, 172.1)	49.9 (2.0, 200.0)	1.120 [†]	0.263
ACL-IGA (U/ml)	4.1 (0.9, 13.2)	3.9 (1.1, 16.7)	0.472 [†]	0.637
ACL-IGG (U/ml)	3.3 (0.6, 39.3)	4.8 (1.3, 104.1)	1.067 [†]	0.286
ACL-IGM (U/ml)	4.6 (0.5, 58.9)	6.3 (0.6, 126.2)	0.828 [†]	0.408
IGA (g/L)	2.4 (0.3, 9.7)	2.1 (0.2, 4.1)	-1.753 [†]	0.080
IGG (g/L)	17.1 (2.9, 46.6)	16.0 (9.2, 29.2)	0.642 [†]	0.521
IGM (g/L)	0.9 (0.2, 6.3)	1.7 (0.5, 5.4)	2.899 [†]	0.004
C3 (g/L)	0.5 (0.1, 1.5)	0.5 (0.2, 1.6)	0.215 [†]	0.830
C4 (g/L)	0.08 (0.03, 0.4)	0.07 (0.05, 0.4)	-0.451 [†]	0.652
Neuropsychiatric manifestations, n (%)				
Headache	16 (44)	17 (74)	4.944 [‡]	0.026
Seizure disorder	15 (42)	2 (9)	7.438 [‡]	0.006
Cerebrovascular disease	14 (39)	1 (4)	8.831 [‡]	0.003
Movement disorder	1 (29)	0	0.000 [‡]	1.000
Myelopathy	1 (29)	0	0.000 [‡]	1.000
Acute confusional state	23 (64)	4 (17)	12.224 [‡]	<0.001
Psychosis	2 (6)	0	0.170 [‡]	0.680
Mood disorders	3 (8)	2 (9)	0.000 [‡]	1.000
Anxiety disorder	1 (3)	0	0.000 [‡]	1.000
Cognitive dysfunction	1 (3)	0	0.000 [‡]	1.000
Neuropathy, cranial	0	2 (9)	1.129 [‡]	0.288

Values are presented as a mean \pm SD, median (range) or n (%). ^{*}: t values; [†]: Z values; [‡]: χ^2 values. MRI: Magnetic resonance imaging; NPSLE: Neuropsychiatric systemic lupus erythematosus; SLE: Systemic lupus erythematosus; SLEDAI: Systemic lupus erythematosus disease activity index; CRP: C-reactive protein; ESR: Erythrocyte sedimentation rate; ACR: American College of Rheumatology; ANA: Antinuclear antibody; Anti-dsDNA: Anti-double-stranded DNA; Anti-SM: Anti-Smith; ANuA: Anti-nucleosome antibody; Anti-RNP: Anti-ribonucleoprotein; AHA: Anti-histone antibody; ACL: Anti-cardiolipin; IGA: Immunoglobulin A; IGG: Immunoglobulin G; IGM, Immunoglobulin M; C3: Complement 3; C4: Complement 4; SD: Standard deviation.

areas in the bilateral frontal lobe, and one had multiple marked enhancement areas in the cortex of the frontal and temporal lobes.

In addition, nine patients (25%) had IT involvement. Cerebellar involvement was observed in seven patients (19%) and brainstem involvement in six patients (17%). The volume of cerebrum was determined by subjective global

assessment, and CA was observed in 11 patients (31%). MRI abnormalities are shown in Table 3.

The SLEDAI scores of various MRI abnormalities are shown in Figure 2. In the ANOVA, the SLEDAI scores of CA (34.0 \pm 13.2), cortex involvement (33.2 \pm 7.6), RD (32.5 \pm 10.5), IT involvement (30.8 \pm 9.7), and SWM involvement (29.8 \pm 10.3) were higher than those in the

Table 2: Multivariate logistic regression analysis of neuropsychiatric manifestations in MRI abnormal and normal groups

Variables	B	Wals	OR	95% CI	P
CVD	3.5	8.5	31.90	3.10–326.60	0.004
ACS	2.4	9.2	10.50	2.30–48.30	0.002
Seizure disorder	2.1	4.9	8.10	1.30–52.00	0.028

MRI: Magnetic resonance imaging; B: Partial regression coefficient; OR: Odds ratio; CI: Confidence interval; ACS: Acute confusional state; CVD: Cerebrovascular disease.

Table 3: MRI manifestations in 59 SLE female patients

Variables	Values
Normal MRI	23 (39)
MRI abnormalities	36 (61)
PVWM lesions	15 (42)
Grade 1	8 (22)
Grade 2	7 (19)
SWM lesions	19 (53)
Grade 1	8 (22)
Grade 2	7 (19)
Grade 3	4 (11)
Basal ganglia lesions	14 (39)
Cortical lesions	10 (28)
Infratentorial lesions	9 (25)
Cerebral atrophy	11 (31)
Restricted diffusion	6/28 (21)
Contrast enhancement	3/12 (25)

Values are presented as *n* (%) or *n/N* (%). MRI: Magnetic resonance imaging; SLE: Systemic lupus erythematosus; PVWM: Periventricular white matter; SWM: Subcortical white matter.

MRI normal group ($P < 0.001$, $P = 0.002$, $P = 0.038$, $P = 0.028$, and $P = 0.004$, respectively). No significantly statistical difference was found between MRI abnormal groups.

Table 4 shows the association between immunological features, certain neuropsychiatric manifestations, and various MRI abnormalities using multivariate logistic regression analysis. No significant positive correlation was found between immunological features and MRI abnormalities ($P > 0.05$).

MRI abnormalities including cerebral atrophy (73%), cortex involvement (70%), and RD (67%) were most common in NPSLE patients with acute confusional states. After correction for age and duration dependencies, there was no significant positive correlation between acute confusional states and MRI abnormalities.

The most frequent MRI abnormalities in seizure disorder patients were cortex involvement (90%), IT involvement (67%), and CA (55%). Statistically significant positive correlations between seizure disorder and cortex involvement were found ($OR = 14.90$; 95% CI , 1.50–151.70; $P = 0.023$). The sensitivity of cortex involvement for seizure disorder in the MRI abnormal group was 61%, while the specificity was 95%.

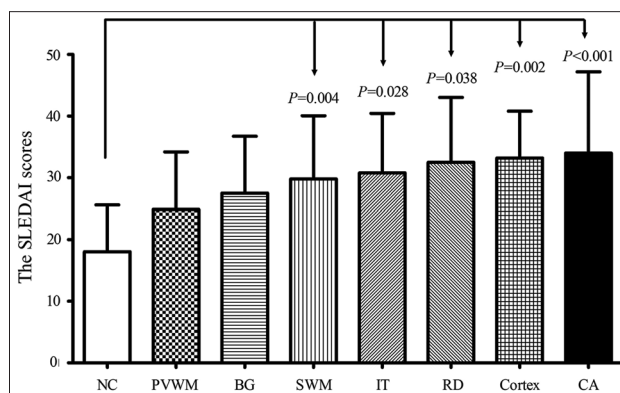


Figure 2: The SLEDAI scores of different MRI abnormalities. The SLEDAI scores of CA (34.0 ± 13.2), cortex involvement (33.2 ± 7.6), restricted diffusion (32.5 ± 10.5), IT involvement (30.8 ± 9.7), and SWM involvement (29.8 ± 10.3) were higher than NC ($P < 0.001$, $P = 0.002$, $P = 0.038$, $P = 0.028$, $P = 0.004$). No significantly statistical difference was found between differences in MRI abnormalities. SLEDAI: Systemic lupus erythematosus disease activity index; MRI: Magnetic resonance imaging; NC: Normal control; PVWM: Periventricular white matter; BG: Basal ganglia; SWM: Subcortical white matter; IT: Infratentorial; RD: Restricted diffusion; CA: Cerebral atrophy.

In addition, NPSLE patients with cerebrovascular disease had a higher incidence of the following MRI abnormalities: IT involvement (78%), RD (67%), and PVWM involvement (60%). There was a statistically significant positive correlation between cerebrovascular disease and IT involvement ($OR = 10.00$; 95% CI , 1.70–60.00; $P = 0.012$). The sensitivity and specificity of IT involvement for cerebrovascular disease in the MRI abnormal group were 50% and 91%.

DISCUSSION

In this study, we investigated the relationships between clinical and immunological features and MRI abnormalities in female patients with NPSLE. In the MRI abnormal group, the SLEDAI scores of CA, cortex involvement, and RD were much higher than in the MRI normal group. Statistically significant positive correlations were found between seizure disorder and cortex involvement, and cerebrovascular disease and IT involvement.

MRI abnormalities were found in 61% of NPSLE patients. The percentage was slightly higher than that reported in other recent studies.^[9,12,13,21,22] Conventional MRI is the preferred neuroimaging method for evaluation of NPSLE but has limited sensitivity and specificity. Some new MRI technologies, such as magnetic resonance spectroscopy,^[23] magnetization transfer imaging (MTI),^[24] and perfusion weighted imaging,^[25] might detect more abnormalities in NPSLE patients than conventional MRI, especially those in white matter. However, their sensitivity and specificity for NPSLE need to be confirmed.^[26]

The most frequent neuropsychiatric manifestations in our study were headache, acute confusional state, seizure disorder, and cerebrovascular disease, which were in

Table 4: The association between certain neuropsychiatric manifestations and various MRI abnormalities

Neuropsychiatric manifestations	MRI abnormalities	B	Wals	OR	95% CI	P
ACS	PWVM involvement	-2.9	6.3	0.06	0.01–0.50	0.012
	SWM involvement	-2.0	3.0	0.10	0.01–1.30	0.085
Seizure disorder	Cortex involvement	2.7	5.2	14.90	1.50–151.70	0.023
	Cerebral atrophy	2.0	3.1	7.20	0.80–65.60	0.080
	PVWM involvement	-2.7	4.9	0.07	0.01–0.70	0.027
CVD	IT involvement	2.3	6.3	10.00	1.70–60.00	0.012
AHA	BG involvement	-1.9	3.6	0.15	0.02–1.10	0.060
IGA	PWVM involvement	2.1	3.4	8.50	0.90–83.50	0.066

MRI: Magnetic resonance imaging; B: Partial regression coefficient; OR: Odds ratio; CI: Confidence interval; ACS: Acute confusional state; CVD: Cerebrovascular disease; IT: Infratentorial; BG: Basal ganglia; PVWM: Periventricular white matter; SWM: Subcortical white matter; AHA: Anti-histone antibody; IGA: Immunoglobulin A.

accordance with the data of Steup-Beekman *et al.*^[19] Headache was one of the most frequent neuropsychiatric manifestations in NPSLE patients in many studies.^[10,13,21] However, some researchers believed that a headache was frequent in the general population and was usually unrelated to SLE.^[2,27,28] In our study, the headache was more likely to be present in the MRI normal group ($P=0.026$), indicating a poor correlation between a headache and MRI abnormalities. Moreover, we found the incidence of acute confusional state, cerebrovascular disease, and seizure disorder in the MRI abnormal group was much higher than in the MRI normal group ($P < 0.001$, $P=0.003$, $P=0.006$, respectively), which indicated that MRI abnormalities might correspond to certain neuropsychiatric manifestations.

Generalized SLE activity is a major risk factor for SLE-related neuropsychiatric events.^[27-29] SLEDAI is a validated model for the overall evaluation of disease activity in SLE patients and can be of great use in treatment.^[19] In our study, the SLEDAI scores of the MRI abnormal group, especially for those with CA, cortex involvement, and RD were much higher than for the MRI normal group ($P < 0.001$, $P=0.002$, $P=0.038$, respectively). The appearance of certain MRI abnormalities might be markers of high SLE activity.

White matter involvement was the most frequent MRI abnormality. The role of white matter involvement in NPSLE was not clear. Similar white matter abnormalities can be found in patients with active NPSLE, in patients with the previous NPSLE and in SLE patients with no neuropsychiatric manifestations. In our study, no significant positive correlations between PVWM or SWM involvement and neuropsychiatric manifestations were found.

Cortex involvement was an important MRI abnormality in NPSLE in our study; 80% of patients with cortex involvement had corresponding SWM involvement, while 20% had none. These differing MRI abnormalities could not be explained by a vascular injury mechanism, indicating other or more diverse pathophysiological mechanisms in NPSLE. Luyendijk *et al.*^[12] also found that 12% of SLE patients in their study had diffuse cortex involvement without SWM involvement, and attributed this striking finding to the

immune response against neuronal components. In addition, Steens *et al.*^[24] found abnormalities in gray matter in NPSLE patients using MTI, while the white matter was not affected. Cortex involvement in our study supported the possibility that the mechanism might be a response to autoimmune inflammation injury.

DWI and ADC images were particularly effective in identifying certain brain injuries such as acute infarction and hemorrhage. In our study, RD was demonstrated in six patients (21%), four of whom were attributed to acute or subacute infarction, and two to an inflammatory injury, based on MRI abnormalities. Jennings *et al.*^[13] thought that DWI and ADC images might be a marker of “active” disease and should be taken as an indication for follow-up MRI in the evaluation of NPSLE. We found a high SLEDAI in RD (33.8 ± 13.1). DWI could help distinguish between severe and mild manifestations and could be a valid tool in daily clinical decision making.^[30]

CA has been observed in NPSLE.^[31,32] Compared with controls, NPSLE patients had reduced the cortical thickness and subcortical structure volume. In our study, CA was observed in 11 patients (31%) in the MRI abnormal group. A striking finding was the high SLEDAI of CA (34.0 ± 13.2), which could be regarded as an excellent marker of high SLE activity.

In our study, a significant positive correlation was found between seizure disorder and cortex involvement ($P=0.023$). Both the incidence and specificity of cortex involvement for seizure disorder were high (90% and 95%). This indicated a high correlation between seizure disorder and cortex involvement. Cortex involvement might be a risk factor for seizure disorder in NPSLE. A significantly positive correlation was also found between cerebrovascular disease and IT involvement ($P=0.012$), which indicated that vasculopathy also played an important role. IT involvement could become a marker of cerebrovascular disease in NPSLE.

There were some limitations in our study. Firstly, the MRI systems that we used were different, and the applied pulse sequences were accordingly inconsistent, which was inevitable in a 13-year retrospective study. Secondly, only

female NPSLE patients were enrolled in the study because of the small quantity of male NPSLE patient. Another limitation was the subjective assessment of CA. Quantitative assessment methods should be used in future studies.

In conclusion, the MRI abnormalities in NPSLE, especially CA, cortex involvement, and RD, might be markers of high SLE activity. Some MRI abnormalities might correspond to certain neuropsychiatric manifestations and might be helpful in understanding the pathophysiology of NPSLE.

Financial support and sponsorship

This study was supported by the Provincial Natural Science Foundation of Shandong (No. ZR2012HM042).

Conflicts of interest

There are no conflicts of interest.

REFERENCES

1. Sui W, Hou X, Che W, Yang M, Dai Y. The applied basic research of systemic lupus erythematosus based on the biological omics. *Genes Immun* 2013;14:133-46. doi: 10.1038/gene.2013.3.
2. Hanly JG. Diagnosis and management of neuropsychiatric SLE. *Nat Rev Rheumatol* 2014;10:338-47. doi: 10.1038/nrrheum.2014.15.
3. Conti F, Perricone C, Reboldi G, Gawlicki M, Bartosiewicz I, Pacucci VA, *et al.* Validation of a disease-specific health-related quality of life measure in adult Italian patients with systemic lupus erythematosus: LupusQoL-IT. *Lupus* 2014;23:743-51. doi: 10.1177/0961203314524466.
4. O'Neill S, Cervera R. Systemic lupus erythematosus. *Best Pract Res Clin Rheumatol* 2010;24:841-55. doi: 10.1016/j.berh.2010.10.006.
5. The American College of Rheumatology nomenclature and case definitions for neuropsychiatric lupus syndromes. *Arthritis Rheum* 1999;42:599-608. doi: 10.1002/1529-0131 (199904)42:4<599:AID-ANR2>3.0.CO;2-F.
6. Chiewthanakul P, Sawanyawisuth K, Foocharoen C, Tiamkao S. Clinical features and predictive factors in neuropsychiatric lupus. *Asian Pac J Allergy Immunol* 2012;30:55-60.
7. Unterman A, Nolte JE, Boaz M, Abady M, Shoenfeld Y, Zandman-Goddard G. Neuropsychiatric syndromes in systemic lupus erythematosus: A meta-analysis. *Semin Arthritis Rheum* 2011;41:1-11. doi: 10.1016/j.semarthrit.2010.08.001.
8. Ainiala H, Loukkola J, Peltola J, Korpela M, Hietaharju A. The prevalence of neuropsychiatric syndromes in systemic lupus erythematosus. *Neurology* 2001;57:496-500. doi: 10.1212/WNL.57.3.496.
9. Steup-Beekman GM, Zirkzee EJ, Cohen D, Gahrman BM, Emmer BJ, Steens SC, *et al.* Neuropsychiatric manifestations in patients with systemic lupus erythematosus: Epidemiology and radiology pointing to an immune-mediated cause. *Ann Rheum Dis* 2013;72 Suppl 2:ii76-9. doi: 10.1136/annrheumdis-2012-202369.
10. Abdul-Sattar AB, Goda T, Negm MG. Neuropsychiatric manifestations in a consecutive cohort of systemic lupus erythematosus; a single center study. *Int J Rheum Dis* 2013;16:715-23. doi: 10.1111/1756-85X.12213.
11. Bertias GK, Boumpas DT. Pathogenesis, diagnosis and management of neuropsychiatric SLE manifestations. *Nat Rev Rheumatol* 2010;6:358-67. doi: 10.1038/nrrheum.2010.62.
12. Luyendijk J, Steens SC, Ouwendijk WJ, Steup-Beekman GM, Bollen EL, van der Grond J, *et al.* Neuropsychiatric systemic lupus erythematosus: Lessons learned from magnetic resonance imaging. *Arthritis Rheum* 2011;63:722-32. doi: 10.1002/art.30157.
13. Jennings JE, Sundgren PC, Attwood J, McCune J, Maly P. Value of MRI of the brain in patients with systemic lupus erythematosus and neurologic disturbance. *Neuroradiology* 2004;46:15-21. doi: 10.1007/s00234-003-1049-2.
14. Postal M, Costallat LT, Appenzeller S. Neuropsychiatric manifestations in systemic lupus erythematosus: Epidemiology, pathophysiology and management. *CNS Drugs* 2011;25:721-36. doi: 10.2165/11591670-000000000-00000.
15. Kim SS, Richman DP, Johnson WO, Hald JK, Agius MA. Limited utility of current MRI criteria for distinguishing multiple sclerosis from common mimickers: Primary and secondary CNS vasculitis, lupus and Sjogren's syndrome. *Mult Scler* 2014;20:57-63. doi: 10.1177/1352458513491329.
16. Magro Checa C, Cohen D, Bollen EL, van Buchem MA, Huizinga TW, Steup-Beekman GM. Demyelinating disease in SLE: Is it multiple sclerosis or lupus? *Best Pract Res Clin Rheumatol* 2013;27:405-24. doi: 10.1016/j.berh.2013.07.010.
17. Zardi EM, Taccone A, Marigliano B, Margiotta DP, Afeltra A. Neuropsychiatric systemic lupus erythematosus: Tools for the diagnosis. *Autoimmun Rev* 2014;13:831-9. doi: 10.1016/j.autrev.2014.04.002.
18. Hochberg MC. Updating the American College of Rheumatology revised criteria for the classification of systemic lupus erythematosus. *Arthritis Rheum* 1997;40:1725. doi: 10.1002/art.1780400928.
19. Bombardier C, Gladman DD, Urowitz MB, Caron D, Chang CH. The committee of prognosis study in SLE and development of the SLE disease activity index: The SLEDAI. *Arthritis Rheum* 1992;35:630-40. doi: 10.1002/art.1780350606.
20. Fazekas F, Chawluk JB, Alavi A, Hurtig HI, Zimmerman RA. MR signal abnormalities at 1.5 T in Alzheimer's dementia and normal aging. *AJR Am J Roentgenol* 1987;149:351-6. doi: 10.2214/ajr.149.2.351.
21. Toledano P, Sarbu N, Espinosa G, Bargallo N, Cervera R. Neuropsychiatric systemic lupus erythematosus: Magnetic resonance imaging findings and correlation with clinical and immunological features. *Autoimmun Rev* 2013;12:1166-70. doi: 10.1016/j.autrev.2013.07.004.
22. Katsumata Y, Harigai M, Kawaguchi Y, Fukasawa C, Soejima M, Kanno T, *et al.* Diagnostic reliability of magnetic resonance imaging for central nervous system syndromes in systemic lupus erythematosus: A prospective cohort study. *BMC Musculoskelet Disord* 2010;11:13. doi: 10.1186/1471-2474-11-13.
23. Appenzeller S, Costallat LT, Li LM, Cendes F. Magnetic resonance spectroscopy in the evaluation of central nervous system manifestations of systemic lupus erythematosus. *Arthritis Rheum* 2006;55:807-11. doi: 10.1002/art.22228.
24. Steens SC, Admiraal-Behloul F, Bosma GP, Steup-Beekman GM, Olofsen H, Le Cessie S, *et al.* Selective gray matter damage in neuropsychiatric lupus. *Arthritis Rheum* 2004;50:2877-81. doi: 10.1002/art.20654.
25. Wang PI, Cagnoli PC, McCune WJ, Schmidt-Wilcke T, Lowe SE, Graft CC, *et al.* Perfusion-weighted MR imaging in cerebral lupus erythematosus. *Acad Radiol* 2012;19:965-70. doi: 10.1016/j.acra.2012.03.023.
26. Appenzeller S, Pike GB, Clarke AE. Magnetic resonance imaging in the evaluation of central nervous system manifestations in systemic lupus erythematosus. *Clin Rev Allergy Immunol* 2008;34:361-6. doi: 10.1007/s12016-007-8060-z.
27. Fanouriakis A, Boumpas DT, Bertias GK. Pathogenesis and treatment of CNS lupus. *Curr Opin Rheumatol* 2013;25:577-83. doi: 10.1097/BOR.0b013e328363eaf1.
28. Bertias GK, Ioannidis JP, Aringer M, Bollen E, Bombardieri S, Bruce IN, *et al.* EULAR recommendations for the management of systemic lupus erythematosus with neuropsychiatric manifestations: Report of a task force of the EULAR standing committee for clinical affairs. *Ann Rheum Dis* 2010;69:2074-82. doi: 10.1136/ard.2010.130476.
29. Toloza SM, Roseman JM, Alarcón GS, McGwin G Jr, Uribe AG, Fessler BJ, *et al.* Systemic lupus erythematosus in a multiethnic US cohort (LUMINA): XXII. Predictors of time to the occurrence of initial damage. *Arthritis Rheum* 2004;50:3177-86. doi: 10.1002/art.20578.
30. Sciascia S, Bertolaccini ML, Baldovino S, Roccatello D, Khamashta MA, Sanna G. Central nervous system involvement in systemic lupus erythematosus: Overview on classification criteria. *Autoimmun Rev* 2013;12:426-9. doi: 10.1016/j.autrev.2012.08.014.
31. Appenzeller S, Bonilha L, Rio PA, Min Li L, Costallat LT, Cendes F. Longitudinal analysis of gray and white matter loss in patients with systemic lupus erythematosus. *Neuroimage* 2007;34:694-701. doi: 10.1016/j.neuroimage.2006.09.029.
32. Jung RE, Segall JM, Grazioplene RG, Qualls C, Sibbitt WL, Roldan CA. Cortical thickness and subcortical gray matter reductions in neuropsychiatric systemic lupus erythematosus. *PLoS One* 2010;5:e9302. doi: 10.1371/journal.pone.0009302.