

## Herpes zoster ophthalmicus presenting as orbital abscess along with superior orbital fissure syndrome: A case report

Poonam Lavaju, Badri Prasad Badhu, Sangeeta Shah

Orbital abscess and superior orbital fissure syndrome (SOFS) are rare manifestations of herpes zoster ophthalmicus. Herein, we report a case of orbital abscess along with SOFS in a 2.5-year-old-male child secondary to herpes zoster infection. He presented with a 5-day history of proptosis and ptosis of the right eye that had been preceded by vesicular eruptions on the right forehead and scalp. Computed tomography scan of the head and orbit showed orbital abscess and right cavernous sinus thrombosis. A diagnosis of orbital abscess with SOFS secondary to herpes infection was made. The condition subsequently improved following antiviral therapy, intravenous vancomycin and amikacin, and oral corticosteroids.

**Key words:** Herpes zoster, orbital abscess, proptosis, superior orbital fissure syndrome

Herpes zoster ophthalmicus (HZO) is caused by varicella-zoster virus (VZV). Ocular manifestations include keratoconjunctivitis, keratitis, anterior uveitis, acute retinal necrosis, acute phthisis bulbi, central retinal artery occlusion, optic neuritis, orbital pseudotumors, and partial or complete paralysis of ocular motility.<sup>[1]</sup> Rarely, it can manifest as superior orbital fissure syndrome (SOFS).<sup>[2]</sup> Orbital abscess along with SOFS has not been reported in the literature. We herein report a case of a 2.5-year-old child presenting with orbital abscess and SOFS secondary to HZO.

### Case Report

A 2.5-year-old-male child was brought with a chief complaint of acute onset drooping of the right upper eyelid that persisted without improvement for 5 days. There was a preceding history of fever of 8 days duration followed by a vesicular eruption on the right scalp and forehead extending to the tip of the nose. Prior to the presentation at our institution, he had received oral paracetamol 5 ml t.i.d and Neosporin eye ointment applied locally. There was no improvement of condition with the treatment. Review of

systems was negative for a history of seizures, throat pain, and no similar rashes in any other part of the body. The child was afebrile and quiet with the pulse rate of 88/min and respiratory rate of 28/min.

Ocular examination revealed right eye axial proptosis with restriction of extraocular movements in dextroversion. There was a moderate blepharoptosis on the right side. Visual acuity was grossly normal. The anterior segment and fundus examination revealed no abnormalities. The left eye was normal [Fig. 1].

The remainder of the physical examinations was normal except for right submandibular and cervical lymphadenopathy. There were multiple healed hyperpigmented lesions on the right side of the scalp, forehead, and nose, suggestive of herpes zoster infection. There were no signs of meningitis.

Hematological examination showed a total leukocyte count - 12,700 cells/mm cu, neutrophils - 59%, lymphocytes - 49%, hemoglobin - 10.8 g/dl, platelet count - 411,000 cells/mm cu, random blood sugar - 95 mg/dl, Na/K - 138/4.8 mg/dl, urea/creatinine - 10/0.2mg/dl, prothrombin time - 16s, international normalized ratio - 1.26, HIV/hepatitis B surface antigen/hepatitis C virus test - negative, and amylase - 27 IU/L (25–200). Microbiological examination of the urine was normal. Blood and urine cultures revealed no organism. Ultrasonography of parotid region showed bulky right parotid gland, heterogeneous with multiple intraparotid lymph nodes, the largest measuring 9.5 mm. The left parotid gland was normal. There were multiple enlarged bilateral upper, mid, and lower cervical lymph nodes, the largest measuring 15 mm. X-ray of the chest and paranasal sinuses were normal. Computed tomography (CT) scan of the orbit and head showed orbital abscess in the right retrobulbar space and right cavernous sinus enlargement with filling defect suggestive of thrombosis. Maxillary and ethmoidal sinuses had features suggestive of sinusitis [Fig. 2a and b]. The child was commenced on intravenous injection vancomycin 60 mg/kg/day in two divided doses, amikacin 20 mg/kg 3 times daily and oral acyclovir 30 mg/day for 14 days. In a view of stable general condition, we continued with oral acyclovir. Intravenous antibiotics were added to treat intraorbital abscess with maxillary and ethmoidal sinusitis.

With treatment, ptosis and proptosis improved, and the patient regained full extraocular movements. Visual acuity was grossly normal. The patient was discharged after 2 weeks on oral Augmentin for further 2 weeks. At 5 months follow-up, the condition was improved [Fig. 3].

### Discussion

HZO is an infection triggered by the reactivation of VZV that lies dormant in the trigeminal nerve ganglia. In literature, 7% of

Access this article online	
Quick Response Code:	Website: www.ijo.in
	DOI: 10.4103/0301-4738.171006

Department of Ophthalmology, B.P. Koirala Institute of Health Sciences, Dharan, Nepal

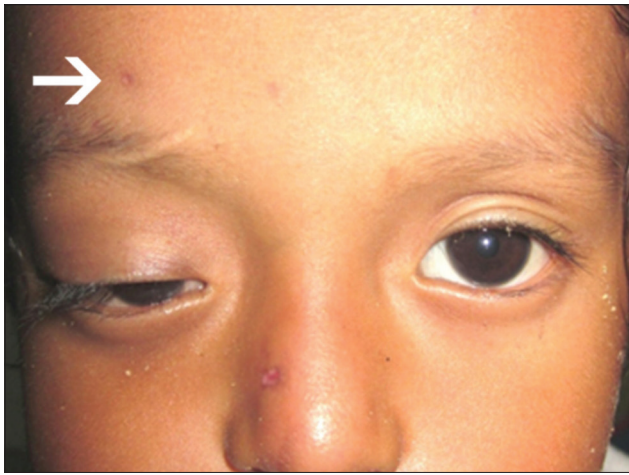**Correspondence to:** Dr. Poonam Lavaju, Department of Ophthalmology, B.P. Koirala Institute of Health Sciences, Dharan, Nepal. E-mail: drpoonamlavaju@yahoo.com

Manuscript received: 12.02.15; Revision accepted: 10.11.15

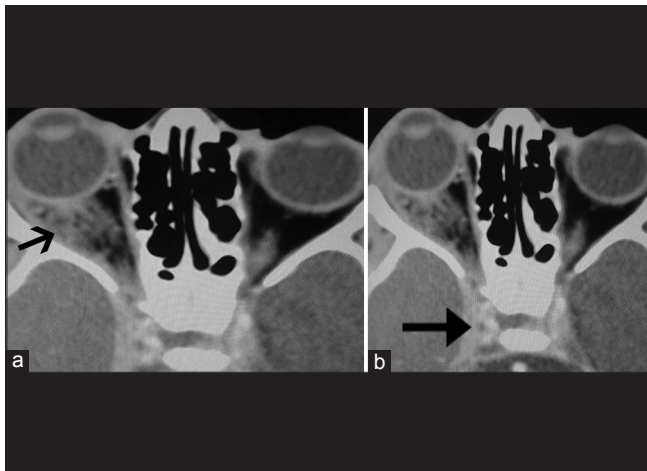
This is an open access article distributed under the terms of the Creative Commons Attribution-NonCommercial-ShareAlike 3.0 License, which allows others to remix, tweak, and build upon the work non-commercially, as long as the author is credited and the new creations are licensed under the identical terms.

**For reprints contact:** reprints@medknow.com

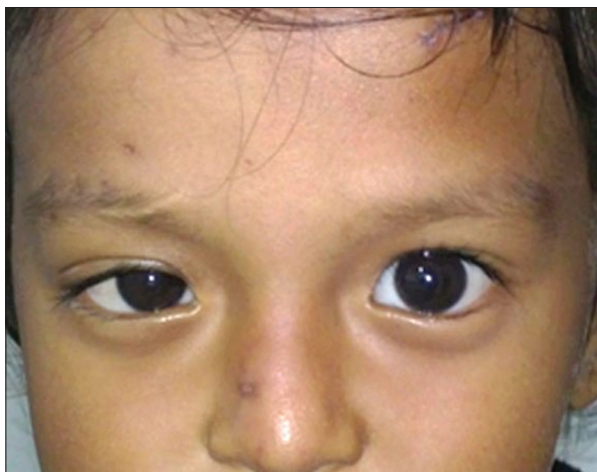**Cite this article as:** Lavaju P, Badhu BP, Shah S. Herpes zoster ophthalmicus presenting as orbital abscess along with superior orbital fissure syndrome: A case report. Indian J Ophthalmol 2015;63:733-5.



**Figure 1:** Right eye proptosis, ptosis, and healed hyperpigmented lesions involving the right side of face



**Figure 2:** (a) Computed tomography scan orbit and head showing the right eye intraorbital abscess. (b) Computed tomography scan orbit and head showing right enlargement of cavernous sinus with filling defect suggestive of thrombosis



**Figure 3:** Improvement of the ptosis and proptosis after the treatment

all cases of herpes zoster present as HZO. Of these cases, 20–79% has orbital involvement.<sup>[3]</sup> HZO is usually reported in older and

immunocompromised patients.<sup>[4]</sup> A review of literature showed that HZO has not been reported in the pediatric age group. In addition, few cases of total ophthalmoplegia due to HZO have been reported, with only four cases of SOFS secondary to HZO in the current literature.<sup>[2,5-7]</sup> Kirwan *et al.* reported a case of HZO in a 71-year-old man, which subsequently developed SOFS and herpes zoster encephalitis.<sup>[7]</sup>

The clinical presentation of the patient with a typical distribution of herpes zoster lesions, ptosis, proptosis, limited extraocular movements with intact pupillary reflex, and normal visual acuity were consistent with the diagnosis of SOFS with orbital abscess secondary to HZO. CT scan findings supported this diagnosis. To our knowledge, there are no published reports describing pediatric HZO presenting as orbital abscess along with SOFS.

Many pathogenic mechanisms are invoked as the cause of total ophthalmoplegia in herpes zoster infection. These include the third, fourth, and sixth cranial nerve compression from orbital soft tissue edema<sup>[4]</sup> and direct spread of the VZV from the fifth cranial nerve to the third, fourth, and sixth in the region of the superior orbital fissure or cavernous sinus.<sup>[4,5]</sup>

The available literature on HZO with SOFS has shown improvement with the use of systemic antiviral drugs and steroids.<sup>[2,5-7]</sup> Treatment regimens are controversial, and the effects of steroids or antiviral treatment have not been formally studied, requiring further randomized controlled clinical trials.

There are reported cases of orbital abscess that have improved with medical management alone.<sup>[8-10]</sup> Given the patient's general stable condition, he was treated with a combination of intravenous antibiotics and oral acyclovir which led to improvement of clinical signs and symptoms.

Patients <9 years respond to medical management more frequently than older patients, but recent studies confirm that even children over 9 years of age with small or moderate-sized abscesses and normal vision deserve a trial of medical therapy before surgical intervention.<sup>[8]</sup> Had there been no improvement, we would have considered surgical drainage of the abscess.

## Conclusion

The co-occurrence of orbital abscess with SOFS is a relatively unusual presentation of HZO. In this case, early diagnosis with an appropriate treatment led to a favorable outcome for the patient.

### Declaration of patient consent

The authors certify that they have obtained all appropriate patient consent forms. In the form the patient(s) has/have given his/her/their consent for his/her/their images and other clinical information to be reported in the journal. The patients understand that their names and initials will not be published and due efforts will be made to conceal their identity, but anonymity cannot be guaranteed.

### Acknowledgment

We acknowledge the help of junior residents Dr. Santosh Chaudhary, Dr. Namrata Gupta, and Dr. Pawan Mahat in the collection of the patient details.

### Financial support and sponsorship

Nil.

### Conflicts of interest

There are no conflicts of interest.

### References

1. Schoenlaub P, Grange F, Nasica X, Guillaume JC. Oculomotor nerve paralysis with complete ptosis in herpes zoster ophthalmicus: 2 cases. *Ann Dermatol Venereol* 1997;124:401-3.
  2. Yong VK, Yip CC, Yong VS. Herpes zoster ophthalmicus and the superior orbital fissure syndrome. *Singapore Med J* 2001;42:485-6.
  3. McCrary ML, Severson J, Tying SK. Varicella zoster virus. *J Am Acad Dermatol* 1999;41:1-14.
  4. Pavan-Langston D. Herpes zoster ophthalmicus. *Neurology* 1995;45 12 Suppl 8:S50-1.
  5. Shin HM, Lew H, Yun YS. A case of complete ophthalmoplegia in herpes zoster ophthalmicus. *Korean J Ophthalmol* 2005;19:302-4.
  6. Gupta D, Vishwakarma SK. Superior orbital fissure syndrome in trigemino-facial zoster. *J Laryngol Otol* 1987;101:975-7.
  7. Kirwan RP, Abdalla M, Hogan A, Tubridy N, Barry P, Power W. Superior orbital fissure syndrome in herpes zoster ophthalmicus. *Ir J Med Sci* 2009;178:355-8.
  8. Bedwell J, Bauman NM. Management of pediatric orbital cellulitis and abscess. *Curr Opin Otolaryngol Head Neck Surg* 2011;19:467-73.
  9. Harris GJ. Subperiosteal abscess of the orbit: Older children and adults require aggressive treatment. *Ophthal Plast Reconstr Surg* 2001;17:395-7.
  10. Younis RT, Anand VK, Davidson B. The role of computed tomography and magnetic resonance imaging in patients with sinusitis with complications. *Laryngoscope* 2002;112:224-9.
-