

## A study of microsporidiosis in corneal scrapings of keratitis patients referring to Farabi Eye Hospital, Tehran, Iran in 2013-14

Ghamiloui MM<sup>1</sup>, Valadkhani Z<sup>1\*</sup>, Rahimi F<sup>2</sup>

<sup>1</sup> Department of Parasitology, Pasteur Institute of Iran, Tehran, Iran

<sup>2</sup> Cornea Clinic, Farabi Research Eye Hospital, Professor of ophthalmology, Tehran University of Medical Science, Tehran, Iran

\*Corresponding author: Zarrintaj Valadkhani, Department of Parasitology, Pasteur Institute of Iran, Tehran, Iran. Email: valad.zarrin@gmail.com

(Received: 21 September 2015; Revised: 18 November 2015; Accepted: 21 November 2015)

### Abstract

**Background and Purpose:** Microsporidiosis is one of the emerging and opportunistic infections, which causing various clinical symptoms in humans. The prevalence of this infection varies, depending on the infected organ, diagnostic methods, and geographical conditions. In the present study, we aimed to investigate microsporidial keratitis in patients referring to Farabi Eye Hospital Tehran, Iran in 2013-14.

**Materials and Methods:** Two scraping samples were collected from 91 keratitis patients, five cases had prior history of receiving immune suppressive drugs. One of the two collected samples from each participant was used for Vero cell culture and the other was used for the preparation of Giemsa and Gram staining slides. After 30 days, the cells were scrapped and used for DNA extraction; afterwards, nested polymerase chain reaction (PCR) detection method was applied. Primer pairs of small-subunit ribosomal RNA gene were designed by CLC Genomics workbench software to amplify all major microsporidian pathogens, as well as *E. bienersi*, which was used as the positive control in this study.

**Results:** The nested PCR showed negative results regarding the presence of microsporidia in the samples. Similarly, Giemsa and Gram staining slides did not detect any spores.

**Conclusion:** The prevalence of human microsporidiosis ranges between 0% and 50%, worldwide. Based on all the negative samples in the present study, we can conclude that the prevalence of this infection among Iranian patients falls in the lower quartile. By gathering further evidence, researchers can take a step forward in this area and open new doors for the assessment of AIDS patients and users of immunosuppressive drugs.

**Keywords:** Cell culture, Cornea, Iran, Microsporidiosis, Nested PCR

➤ How to cite this paper:

Ghamiloui MM, Valadkhani Z, Rahimi F. A study of microsporidiosis in corneal scrapings of keratitis patients referring to Farabi Eye Hospital, Tehran, Iran in 2013-14. Curr Med Mycol. 2015; 1(3):39-44. DOI: [10.18869/acadpub.cmm.1.3.39](https://doi.org/10.18869/acadpub.cmm.1.3.39)

### Introduction

Microsporidiosis caused by different species, is one of the emerging and opportunistic infection. Based on phylogenetic analyses, microsporidia, as obligate intracellular parasites, have been reclassified from protozoa to fungi. Microsporidiosis was first reported in HIV patients, although organ transplant recipients, children, travelers, and contact lens wearers are vulnerable groups, as well [1]. Among 14 microsporidian species, recognized in human hosts, *Enterocytozoon bienersi* (*E. bienersi*) and *Encephalitozoon intestinalis*, are the most common types, associated with diarrhea and systemic diseases. Microsporidian species have been detected in different sources such as soil, mud and water; moreover zoonotic transmission is regarded as another

major source. The prevalence of human microsporidiosis ranges between 0% and 50%, depending on the infected organ, diagnostic methods, and geographical conditions [2]. Based on previous evidence, patients with ophthalmic infections are at a higher risk of corneal infections, particularly after minor corneal traumas, or use of immunosuppressive drugs, have been shown to be at a higher risk of developing corneal infection. Despite the scarcity of reliable data, recent studies have indicated a higher prevalence of microsporidial keratoconjunctivitis in rainy seasons, particularly in countries such as India and those with similar climates [3].

Spores are the resistant infective form of microsporidia. In order to cultivate these

organisms, specific tissue culture techniques are required [4]. For the amplification of various small (SSU) and large subunit (LSU) rRNA genes, as well as internal transcribed spacer regions, several polymerase chain reaction (PCR)-based methods, have been used to diagnose and differentiate species [5]. Among these methods, nested PCR-based detection has greatly enhanced the sensitivity and specificity of microsporidia detection [6].

Alcohol-fixed cytologic samples of scrapings from the conjunctiva or corneal epithelium and biopsy specimens have proven been shown to be useful in demonstrating blastospores [7]. These spores can be easily detected by Gram and Giemsa staining techniques [6]. According to a recent study, new cases of microsporidial intestinalis have been reported in Iran [8]. Therefore, in this study, we aimed to investigate microsporidial keratitis in patients, referring to the Corneal Clinic of Farabi Eye Hospital, in Tehran, Iran.

## Material and Methods

### Sample collection

Questionnaires were completed by 91 keratitis patients, referring to Farabi Eye Hospital. Informed consent forms were obtained from all the participants in this study. The patients' demographic characteristics including age, gender, occupational status, and educational level, as well as clinical symptoms, were gathered and recorded (Table 1). Two scraping samples were collected from each patient by an ophthalmologist. One sample was used for cultivating microorganisms in a Vero cell culture (Cell Bank, Pasteur Institute of Iran, Tehran, Iran), while the other sample was used for the preparation of Giemsa and/or Gram staining slides. Vero cells were cultured in Dulbecco's Modified Eagle Medium (DMEM) (Invitrogen, USA), containing 10% fetal calf serum and penicillin/streptomycin antibiotics [9], and were kept at 37°C.

### Genomic DNA extraction

The samples were cultured at 37°C for 30 days in DMEM until confluence. By using a

scraper, the cells were detached and centrifuged. As previously described, the pellets were then subjected to DNA extraction [10]. Given the fact that microsporidia are intracellular spore-forming fungi, *Aspergillus* species, were used from the culture medium in order to confirm DNA extraction method.

Given the lack of corneal microsporidial isolates in Iran, we had no access to positive control samples for standardizing the PCR method. In order to surmount this issue, the DNA sample of *E. bienewisi* strain (isolated from diarrhea sample), was set as the positive control [8].

### Nested PCR

The primer pairs were designed using CLC Genomics workbench (V.3.6.1) (QIAGEN) to amplify all major microsporidial pathogens infecting the cornea, such as *Encephalitozoon* species (i.e., *E. cuniculi*, *E. hellem*, and *E. intestinalis*), *Vittaforma corneae*, and *E. bienewisi* (although it does not cause keratitis), which, the former pathogen was used as the positive control in the tests. Moreover, the SSU rRNA gene was applied as the target gene, and the following primers were used:

**Table 1.** The frequency distribution of patients referring to Farabi Eye Hospital, based on their medical history

Patients' history	Male	Female
Symptoms(e.g., tears, pain, redness, foreign body sensation, photophobia, and decreased visual acuity)	53	38
Education level		
Basic education	32	19
University education	3	7
Illitera	18	13
Occupational status		
Employed	6	2
Farmer	5	0
Student	8	4
Self-employed	34	6
Housewife	0	26
Age		
> 20	11	6
21-30	8	14
31-40	7	3
41-50	6	3
51-60	5	2
> 61	16	10

MF1- [CAC CAG GTT GAT TCT GCC], MR1-[GAC GGG CGG TGT GTA C], MF2-[GTT GAT TCT GCC TGA CG], and MR2-[AAC GGC CAT GCA CCA C]. The first and second steps of PCR were performed in a 25 µl reaction mixture, containing 1-U Taq DNA polymerase, 12.5 pmol of each primer, 2 mM MgCl<sub>2</sub>, and 200 Mm deoxynucleotide (dNTPs) (all from CinnaGen Co., Iran). The cyclic conditions for the two steps of PCR, consisted of an initial denaturation at 94°C for 5 min, followed by 35 amplification cycles of denaturation for 1 min at 94°C, annealing for 1 min (at 55°C for the first round of PCR and at 65.2°C for the second round PCR), extension for 1 min at 72°C, and elongation at 72°C for 6 min.

The product of the first step of nested PCR was an 1183 bp segment, which was used as the template DNA for the second round of PCR, (a 911-bp segment was used as the positive control); however, there was no DNA template in the negative control. All the samples were examined for different microsporidial species (i.e., *E. cuniculi*, *E. hellem*, *E. intestinalis* and *Vittaforma corneae*).

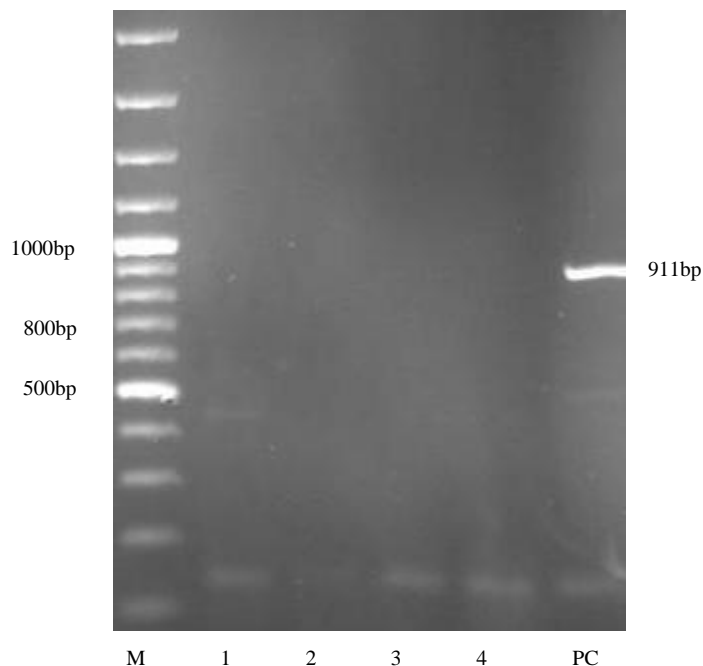
Furthermore, in order to examine the

possible co-infection of parasites, all the samples were simultaneously assessed for *Acanthamoeba* by culturing in a non-nutrient agar medium, and via PCR method.

## Results

In this study, microsporidial keratitis was investigated in a sample population of keratitis patients in Iran. The patients who were enrolled in this study were 17 to 90 years old (Table 1).

Five patients used immuneosuppressive drugs, prescribed by the physicians at the same clinic. However, there was no significant difference between these patients and their immunocompetent counterparts. With the exemption of positive samples, no bands were expected in the first round of nested PCR. However due to insufficient positive DNA for setting the test, non-specific bands were seen in a few samples (samples No. 1 and 3) as shown in Figure 1, this problem was resolved in the second step. The chance of optimizing PCR was greater in the second round due to the presence of more positive control DNA samples, which were obtained during the amplification of control DNA in the first round. No 911 bp bands



**Figure 1.** Agarose gel electrophoresis, indicates the DNA from *E. bieneusi* strain as the positive control (PC), ladder (M) and four samples in the second step of Nested PCR

were seen in this study except for the positive control. The nested PCR showed negative results regarding the presence of microsporidia in the samples Gram and Giemsa staining procedures also, detected no spores (Figure 1).

## Discussion

Microsporidia belong to the Phylum *Microspora*, and are recognized as opportunistic infectious agents worldwide [10]. Human infections caused by Microsporidia include intestinal, ocular, sinus, pulmonary, muscular, and renal diseases [11]. The risk of microsporidial keratoconjunctivitis is hypothesized to be associated with a seasonal trend towards disease onset during the monsoon season [12].

In this study, the samples were collected from patients mostly residing in Tehran, Iran. Differences in geographical conditions, environmental factors and even life style may affect the results. So far, no ocular infections by microsporidia have been reported among Iranian patients, and the reports have mainly focused on intestinal microsporidial infection, which mostly affects immunocompromised patients [8].

In this study, besides cell culture, Gram and Giemsa staining techniques were applied as diagnostic tools, although none of them could detect microsporidia. Other staining methods such as Weber-Green modified trichrome and Ryan Blue modified trichrome methods have been also applied for the detection of microsporidia [13]. Nested PCR is usually used in samples with a very low amount of target DNA accordingly, in the present study, this method was applied.

In a four years study by Loh et al., 50% of patients with microsporidial keratitis (n=124) had a prior history of exposure to soil [14]. However, in the present study, only about 10% of patients also had a prior history of exposure to soil. Additionally, HIV seropositive patients have been reported to be infected with ocular microsporidiosis [15]. In another study by Reddy et al., out of 30 corneal scrapings of patients, ten were positive for microsporidia, based on PCR results [16].

All the patients in this group were simultaneously checked for *Acanthamoeba* infection. according to the culture and PCR results, 5.6% of the samples were infected with *Acanthamoeba* species [17]. In the study, the possible relationship or coinfection of these two microorganisms was also investigated. The negative results rejected any possible relationship between the mentioned microorganisms.

The first case of ocular microsporidiosis was diagnosed in an 11-year-old Tamil boy with stromal keratitis in 1973 [18]. However the first case in an immunocompetent individual was reported in India, in 2003 [19]. Moreover, a case series of five patients with microsporidial stromal keratitis was reported in South India [20]. The first case of *E. bienewisi* infection was reported in a liver transplant patient, from Poland in 2013 [21]. With the increasing global reports, investigations are underway to identify the possibility of ocular microsporidiosis in Iran.

Although the etiology of ocular infections unclear, transmission of intestinal microsporidiosis due to inadequate hygienic can result in direct inoculation, or infection after trauma, as about 3% of patients in this study had accidental traumas [22]. Direct inoculation due to close contact with domestic animals such as cats and birds, may be also responsible [23]. Moreover, the relatively superficial location of conjunctiva and corneal tissues suggests that direct inoculation to the eye is another probable cause of infection [24].

As previously stated, the prevalence of human microsporidiosis ranges between 0%-50%, worldwide [2]. Based on all the negative samples, in this study, the rate of this infection among Iranian patients fall in the lower quartile. However, few reports are available on this issue and the parameters are poorly understood. By gathering further evidence, researchers can take a step forward in this area and open new doors for the assessment of AIDS patients and users of immunosuppressive drugs.

Studies focused in this field can move a step forward and can open new insights for

researchers to investigate in immune-suppressive drugs users and AIDS patients as well.

### Acknowledgments

The authors would like to thank Dr. Agholi- at Shiraz University of Medical Science for his sincere cooperation in providing *E. bienersi* DNA strains, isolated from stool samples (as the positive control). This study was funded by Pasteur Institute of Iran, Tehran (project No.: 598).

### Authors' Contributions

Z.V. designed and managed the research. F.R collected the samples directly from the patients. MM.G collected the samples, cultured and identified them in the parasitology laboratory. Z.V. wrote the manuscript and analyzed the data.

### Conflicts of Interest

The authors declare no conflicts of interests.

### Financial Disclosure

No financial interests related to the material of this manuscript have been declared.

### References

- Didier ES, Weiss LM. Microsporidiosis: current status. *Curr Opin Infect Dis.* 2006; 19(5):485–92.
- Didier ES, Stovall ME, Green LC, Brindley PJ, Sestak K, Didier PJ. Epidemiology of microsporidiosis: sources and modes of transmission. *Vet Parasitol.* 2004; 126(1-2):145-66.
- Sharma S, Das S, Joseph J, Vemuganti GK, Murthy S. Microsporidial keratitis: need for increased awareness. *Surv Ophthalmol.* 2011; 56(1):1-22.
- Visvesvara GS. *In vitro* cultivation of microsporidia in clinical importance. *Clin Microbiol Rev.* 2002; 15(3):401–13.
- Ghosh K, Weiss LM. Molecular diagnostic tests for microsporidia. *Interdiscip Perspect Infect Dis.* 2009; 2009:1-13.
- Garcia LS. Laboratory identification of the microsporidia. *J Clin Microbiol.* 2002; 40(6):1892–901.
- Schottelius J, da Costa SC. Microsporidia and acquired immunodeficiency syndrome. *Mem Inst Oswaldo Cruz.* 2000; 95(Suppl 1):133-9.
- Agholi M, Hatam GR, Motazedian MH. Microsporidia and coccidia as causes of persistence diarrhea among liver transplant children: incidence rate and species/genotypes. *Pediatr Infect Dis J.* 2013; 32(2):185-7.
- Joveeta J, Vemuganti GK, Sharma S. Microsporidia: emerging ocular pathogen. *Indian J Med Microbiol.* 2006; 23(2):80-91.
- Hervás-Aguilar A, Rodríguez JM, Tilburn J, Arst HN Jr, Peñalva MA. Evidence for the direct involvement of the proteasome in the proteolytic processing of the *Aspergillus nidulans* zinc finger transcription factor PacC. *J Biol Chem.* 2007; 282(48):34735-47.
- Dowd SE, Gerba CP, Pepper IL. Confirmation of human pathogenic microsporidia *Enterocytozoon bienersi*, *Encephalitozoon intestinals* and *vittaformae cornea* in the water. *Appl Environ Microbiol.* 1998; 64(9):3332-5.
- Reddy AK, Balne PK, Garg P, Krishnaiah S. Is microsporidial keratitis a seasonal infection in India? *Clin Microbiol Infect.* 2011; 17(7):1114-6.
- Ghoshal U, Khanduja S, Pant P, Prasad KN, Dhole TN, Sharma RK, et al. Intestinal microsporidiosis in renal transplant recipients: Prevalence, predictors of occurrence and genetic characterization. *Indian J Med Microbiol.* 2015, 33(3):357-63.
- Loh RS, Chan CM, Ti SE, Lim L, Chan KS, Tan DT. Emerging prevalence of microsporidial keratitis in Singapore: epidemiology, clinical features, and management. *Ophthalmology.* 2009; 116(12):2348-53.
- Taju S, Tilahun Y, Ayalew M, Fikrie N, Schneider J, Kempen JH. Diagnosis and treatment of microsporidial keratoconjunctivitis: literature review and case series. *J Ophthalmic Inflamm Infect.* 2011; 1(3):105–10.
- Reddy AK, Balne PK, Gaje K, Garg P. PCR for the diagnosis and species identification of microsporidia in patients with keratitis. *Clin Microbiol Infect.* 2011; 17(3):476–8.
- Ghamilouie M, Valadkhani Z, Rahimi F, Khoshzaban F, Aghighi Z, Hassan N. Isolation and genotyping of acanthamoeba strains from corneal scraps. *Iran J Ophthalmol.* 2014; 26(2):97-101.
- Ashton N, Wirasinha PA. Encephalitozoonosis (nosematosis) of the Cornea. *Br J Ophthalmol.* 1973; 57(9):669-74.
- Sridhar MS, Sharma S. Microsporidial keratoconjunctivitis in a HIV-seronegative patient treated with debridement and oral itraconazole. *Am J Ophthalmol.* 2003; 136(4):745-6.
- Vemuganti GK, Garg P, Sharma S, Joseph J, Gopinathan U, Singh S. Is microsporidial keratitis an emerging cause of stromal keratitis? A case series study. *BMC Ophthalmol.* 2005; 32(5):19-33.
- Bednarska M, Bajer A, Welc-Faleciak R, Czubkowski P, Teisseyre M, Graczyk TK, et al. The first case of *Enterocytozoon bienersi* infection in Poland. *Ann Agric Environ Med.* 2013; 20(2):287-8.
- Joseph J, Vemuganti GK, Sharma S. Microsporidia: emerging ocular pathogen. *Indian J Med Microbiol.* 2006; 23(2):80-91.
- Das S, Sharma S, Sahu SK, Nayak SS, Kar S. New microbial spectrum of epidemic keratoconjunctivitis: clinical and laboratory aspects of an outbreak. *Br J Ophthalmol.* 2008; 92(6):861-2.

24. Curry A, Mudhar HS, Dewan S, Canning EU, Wagner BE. A case of bilateral microsporidial keratitis from Bangladesh--infection by an insect

parasite from the genus *Nosema*. J Med Microbiol. 2007; 56(Pt 9):1250-2.