

# Spindle-Cell Sarcoma of the Heart: A Case Report of a Rare Cause of Cardiac Mass

Vaishali S. Badge, Mangesh Kohale, Anand Patil, Akshay Revadekar

Department of Cardiac Anaesthesia and Surgery, Wockhardt Hospitals, Mumbai, Maharashtra, India

## ABSTRACT

Spindle cell sarcoma of heart are the least reported primary cardiac tumours. We present a case of a 60-year-old man reported to us following successful resuscitation after cardiac arrest. This patient presented with symptoms of dyspnoea on exertion. The echocardiography showed features of cardiac tamponade. CT scan chest+ Abdomen + Pelvis confirmed echocardiography findings, and showed significant pericardial effusion with early cardiac tamponade. Patient continued to suffer dyspnoea even after pericardiocentesis and was unstable in the intensive care unit, hence he was shifted to operating room for re-exploration. The mass was excised in a piecemeal without instituting cardiopulmonary bypass. The total weight of the mass was approximately 500gms. The macroscopic examination of the specimen revealed a cystic mass with solid grey brown tissue. Following surgical debulking, chest X-ray in Intensive Care Unit showed improvement. The patient visited the outpatient clinic after 15 days of surgery. 2-D echocardiography revealed minimal pericardial effusion and patient was comfortable.

**Keywords:** Cystic mass, sarcoma, spindle cells

**Address for correspondence:** Dr. Vaishali S Badge, 1877, Dr Anandrao Nair Marg, Near Agripada Police Station, Mumbai Central, Mumbai, Maharashtra 400011, India.

E-mail: vsbadge@rediffmail.com

**Submitted:** 22-Sep-2020 **Revised:** 20-Apr-2021 **Accepted:** 10-May-2021 **Published:** 11-Apr-2022

## INTRODUCTION

Cardiac tumors may be primary or secondary, the incidence of secondary tumors being far more common almost 100 to 1000 times. Primary cardiac tumors are rare with an autopsy incidence of 0.001% to 0.03%.<sup>[1]</sup> Seventy-five percent (75%) of primary cardiac tumors are benign, which include myxomas around 50%, 10% each of lipomas, papillary fibroelastomas, and rhabdomyomas. Around 25% of primary cardiac tumors are malignant with 95% being sarcomas and 5% lymphomas. The most common cardiac sarcoma is the angiosarcoma (about 37%), whereas others are undifferentiated sarcoma (24%), malignant fibrous histiocytoma (MFH) (11%–24%), leiomyosarcoma (8%–9%), and osteosarcoma (3%–9%). The least reported cardiac tumors are spindle cell sarcomas.<sup>[1]</sup>

These tumors are rare and difficult to diagnose preoperatively as these patients present with nonspecific symptoms. Computerized tomography (CT) scan, cardiac, magnetic resonance imaging (MRI), and echocardiography (ECHO) make a preoperative diagnosis. However, transesophageal echocardiography aids in confirming the diagnosis of a mass, whereas sarcoma is confirmed by invasive tissue biopsy.<sup>[2]</sup>

## CASE REPORT

A 60-year-old gentleman was referred to our hospital for further management as he suffered cardiac arrest. The same patient was a known case of diabetes mellitus and hypertension since 1 and 1/2 years, and hypothyroidism since 6 months. The patient was comparatively alright

This is an open access journal, and articles are distributed under the terms of the Creative Commons Attribution-NonCommercial-ShareAlike 4.0 License, which allows others to remix, tweak, and build upon the work non-commercially, as long as appropriate credit is given and the new creations are licensed under the identical terms.

**For reprints contact:** WKHLRPMedknow\_reprints@wolterskluwer.com

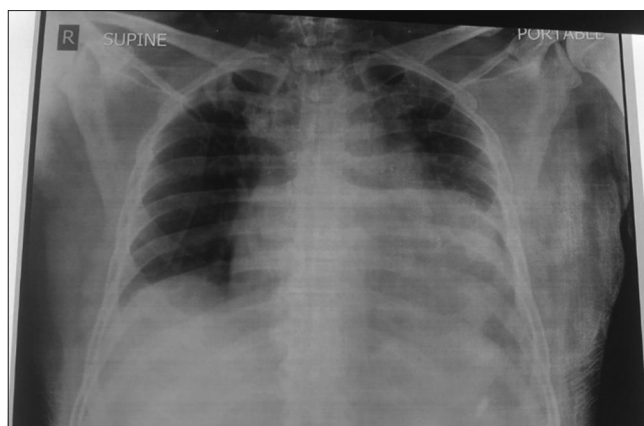
**How to cite this article:** Badge VS, Kohale M, Patil A, Revadekar A. Spindle-cell sarcoma of the heart: A case report of a rare cause of cardiac mass. *Ann Card Anaesth* 2022;25:220-4.

Access this article online	
Quick Response Code:	Website: www.annals.in
	DOI: 10.4103/aca.aca_242_20

3 months before reporting to the hospital when he started having dyspnea on exertion New York Heart Association (NYHA-III). He was admitted to a tertiary care hospital for further management. 2-D Echocardiography showed large pericardial mass along the free wall of the right atrium (RA) and right ventricle (RV) and posterior of the left ventricle (LV) displacing the heart causing tamponade to mass effect; left ventricular ejection fraction (LVEF) = 60%, Grade I diastolic dysfunction. CT scan chest + abdomen + pelvis showed significant pericardial effusion with early cardiac tamponade. Pericardiocentesis aspirated 200 mL hemorrhagic fluid and sent for investigations, but the report was inconclusive. Endobronchial ultrasound-guided biopsy (EBUS) of subcarinal lymph node was negative for malignancy or infective etiology. Acid Fast Bacilli (AFB) and *Mycobacterium Tuberculosis* (MTB) were not detected. Adenosine deaminase (ADA) was 33.58. Chest X-ray showed left pleural effusion and massive cardiomegaly. Subsequently, the patient was discharged.

Even after pericardiocentesis, the patient continued to have dyspnea on exertion. Hence, he was treated with Ayurvedic medicines, which relieved his symptoms temporarily. The patient's symptoms worsened from the morning of the day of admission to our unit. Hence, he was admitted to a hospital where the patient suffered a cardiac arrest. He was revived by giving cardiopulmonary resuscitation (CPR), intubated, and then shifted to our unit for further management. The patient was on glimepiride and metformin, sitagliptin, voglibose, metoprolol- AM, torasemide, amlodipine and telmisartan, and Thyrox for control of diabetes, hypertension, and hypothyroidism respectively since 1 and 1/2 years.

The patient was unstable in the Intensive Care Unit (ICU) showing the signs of cardiac tamponade, hence decided to do exploration. The patient was received to the operating room, intubated, on a ventilator, on IV noradrenaline infusion 0.1 mcg/kg/min with hemodynamics approximately arterial blood pressure 80–90 mm Hg systolic, HR was 100/min and regular, central venous pressure (CVP) = 16–18 cm H<sub>2</sub>O. Preoperative chest X-ray showed widened mediastinum with pleural effusion [Figure 1]. CT scan chest + abdomen + pelvis showed significant pericardial effusion with signs of early cardiac tamponade. The ECG revealed sinus tachycardia. Transthoracic echocardiography (TTE) showed large pericardial mass along the free wall of the RA/RV and posterior of the left ventricle (LV) displacing the heart, causing tamponade to mass effect, left ventricular ejection fraction (LVEF) = 60%, mild tricuspid regurgitation (TR) with mild pulmonary artery hypertension (PAH), type II



**Figure 1:** Preoperative chest X-ray showing massive pleural effusion and widened mediastinum

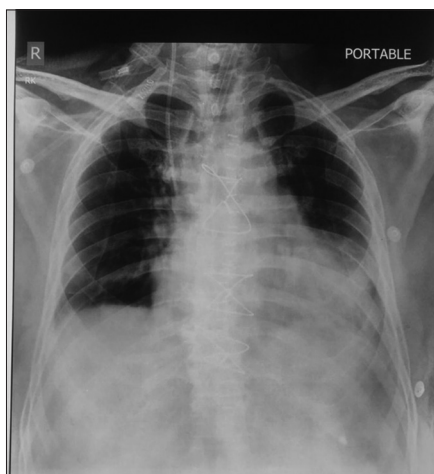diastolic dysfunction. Computed tomography pulmonary angiogram (CTPA) revealed moderate pericardial effusion of approximately 6 cm with compression of the right atrium (RA) and right ventricle (RV). A mass on RV-free wall was suggestive of possible thrombus. Significant pericardial effusion, dilated the inferior vena cava (IVC).

The patient was taken to the operating room, connected to the ventilator, central venous catheterization in the right internal jugular vein (IJV) and right radial artery cannulation were performed in the ICU. Intraoperatively, intravenous fentanyl, cisatracurium, and etomidate were used. A vasopressor infusion was continued. Transesophageal echocardiography (TOE) was suggestive of cardiac tamponade with right atrium (RA) and right ventricle (RV) compression. The surgeon aspirated approximately 20 mL of hemorrhagic pericardial fluid. Following midline sternotomy and pericardiotomy, it was noticed that pericardial fluid was hemorrhagic, and there was a big cystic mass sitting on the RV, which was extending to the LV. There was a mass compressing RA and RV. The surgeon excised the mass in a piecemeal without instituting cardiopulmonary bypass. The total weight of the mass was approximately 500 gm. The macroscopic examination of the specimen revealed a cystic mass with solid grey-brown tissue.

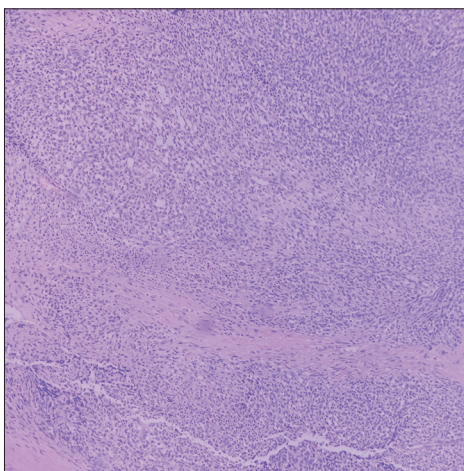
Following surgical debulking, chest X-ray done postoperatively in the Intensive Care Unit showed improvement [Figure 2]. Following discharge from the hospital, the patient visited the outpatient clinic after 15 days of surgery. 2-D echocardiography revealed minimal pericardial effusion. However, the patient was comfortable.

The cystic tissue measured 6 cm × 3 cm with a wall thickness of 0.3 cm–0.4 cm. The solid tissue piece measured 3.5 cm × 3 cm × 2.5 cm and quite friable.

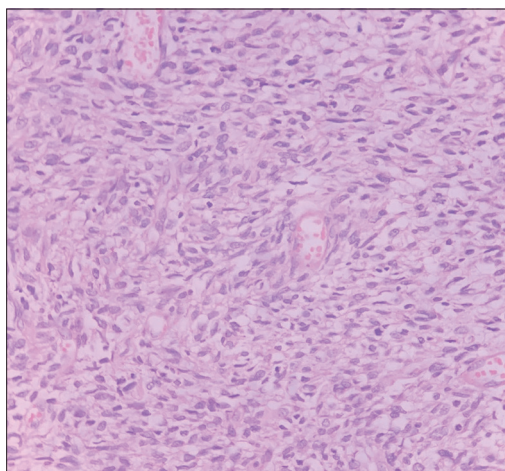
The cut section was grey-brown to grey white. The histopathology of the specimen revealed monophasic synovial sarcoma. The sections showed fragments of densely cellular tumor composed of spindle cells



**Figure 2:** Postoperative chest X-ray showing improvement as compared to preoperative chest X-ray



**Figure 3:** Section shows sheets of densely packed spindle cells



**Figure 4:** Arrow shows spindle cells

arranged in sheets and fascicles [Figure 3]. The cells displayed moderate, pale-staining cytoplasm, and oval to elongated nuclei with granular chromatin and prominent nucleoli [Figure 4]. The polyhedral cells were observed in few areas. Occasional mitoses were noticed (1–2/10 HPF). Stroma was collagenized and edematous. Interspersed thick and thin-walled blood vessels and broad irregular zones of fibrosis were seen. Foci of fresh hemorrhage were noted. The cystic piece showed fibrous tissue and clusters of similar tumor cells. There was no evidence of tumor necrosis. The immunohistochemistry showed that the spindle cells expressed cytokeratin (focal), Mic-2 (CD99 or single chain type-1 glycoprotein), high grade B-Cell lymphoma2 (bcl 2), calponin, and transducin-like enhancer of split-1 (TLE-1) and were immuno-negative for epithelial membrane antigen (EMA) and SRY-related HMG box-10 (SOX-10). The nuclear (intergrase interactor–1 (INI-1) expression was mosaic in nature. The mass was malignant but did not show any evidence of metastasis to the liver, lungs. The morphology of the cardiac tumor compared to the abdominal and immunostaining profile supported the diagnosis of cellular spindle cell sarcoma.

## DISCUSSION

The first tumor mass in the heart was described by Columbus in 1562.<sup>[3]</sup> In 1835, Albas, described a cardiac fibroma found at post mortem examination.<sup>[4]</sup> In 1936, Barnes was the first to diagnose a primary tumor of the heart in a living patient using an electrocardiogram and the information of a biopsy taken from a peripheral metastatic lesion.<sup>[5]</sup>

Intimal (spindle cell) sarcomas are mesenchymal tumors, more commonly observed in large arteries and are extremely rare in the heart, with less than 10 cases reported till now.<sup>[6]</sup> The incidence of intimal sarcomas affecting the pulmonary artery is more than the aorta.<sup>[7]</sup> The involvement of the pulmonary trunk is 80%, right and left pulmonary arteries (50%–70%), or both 40%. The pulmonary valve and right ventricular outflow tract involvement are noticed. Lung metastases occur in 40%, whereas extrathoracic metastasis occurs in 20% of the cases involving kidneys, lymph nodes, brain, and skin.<sup>[6]</sup> The involvement of bone, peritoneum, and liver, and mesenteric lymph nodes occurs by tumor emboli spread.<sup>[7]</sup> Spindle cell tumors are polypoid in appearance, whereas osteosarcomas may have hard and bony areas. Histologically, intimal sarcomas are poorly differentiated mesenchymal malignant tumors of fibroblastic or myofibroblastic differentiation, consisting of atypical spindle cells with variable degrees of atypia, mitotic activity, necrosis, and nuclear polymorphism.<sup>[5]</sup> The tumor

may have a large myxoid or epithelioid appearance and may resemble leiomyosarcoma and rarely rhabdomyomatous, angiosarcomatous, and osteosarcomatous appearance. The differential diagnosis of angiosarcoma or synovial sarcoma should be ruled out whenever sarcoma is encountered, especially in the heart. In our case, the spindle cells had expression for cytokeratin (focal), Mic-2 [cluster of differentiation 99 (CD99) or single-chain type-1 glycoprotein], B-Cell lymphoma2 (bcl-2), calponin, and transducin-like enhancer of split-1 (TLE-1) and were immuno-negative for epithelial membrane antigen (EMA) and SRY related HMG box-10 (SOX 10). Nuclear integrase interactor 1 (INI-1) expression was mosaic in nature.

The prognosis of spindle cell sarcomas is poor as these tumors are highly aggressive and rapidly infiltrating with mean survival being 3 months to 1 year although survival up to 11 years has been reported.<sup>[5]</sup> Almost 80% of patients have evidence of metastasis at the time of presentation. The effects of cardiac tumor depend on its location, size, invasiveness, friability, and rate of growth. The most important factor affecting the prognosis of these tumors is the anatomic location in the heart either intracavitary or intra/extramycardial growth.<sup>[5]</sup>

The most common primary cardiac tumor is angiosarcoma, which tends to involve the pericardium and most often in the right atrium. Rhabdomyosarcoma is the most common primary cardiac malignancy in children and tends to favor valvular involvement.<sup>[8]</sup> Primary cardiac lymphomas are commonly seen in immunocompromised patients but may respond to chemotherapy. Leiomyosarcoma, primary osteogenic cardiac sarcoma, and fibrosarcoma are more commonly seen in the left atrium.<sup>[9]</sup>

Wide surgical resection is the cornerstone of therapy for cardiac sarcomas. However, complete tumor resection is possible in less than 50% of patients.<sup>[6]</sup> It has been observed that patients undergoing surgery with negative resection margins have a life expectancy two times than those in whom complete resection was not feasible.<sup>[10]</sup> The added advantage of palliative resection is for relief of symptoms, biopsy to confirm a diagnosis, or repeated resections. The role of radiotherapy and chemotherapy in the treatment of primary cardiac sarcoma has not proven to be beneficial.<sup>[11]</sup> Cardiac transplantation is sometimes considered in patients with inoperable sarcomas.<sup>[8]</sup> There have been reports about patients with polymorphic spindle-cell sarcoma, where patients responded very well to complete resection and palliative chemotherapy with doxorubicin and ofosfamide.<sup>[9]</sup> Certain histological types like Ewing's sarcoma and potential embryonal rhabdomyosarcoma (PNET) were more

responsive to chemotherapy. The surgical debulking may provide hemodynamic relief even if curative resection is not achieved.

The most common cardiac sarcomas are angiosarcomas, followed by malignant fibrous histiocytomas (MFH). The angiosarcomas have affection towards the right side, whereas MFH on the left.<sup>[6]</sup> Echocardiography provides better resolution, and inexpensive tool to identify intracardiac masses though transesophageal echocardiography is better than transthoracic echocardiography. CT and MRI scans of the chest and abdomen complement echocardiography<sup>[6]</sup> because soft-tissue characterization and visualization of the mediastinum are better appreciated. CT and MRI have the advantage of assessing/diagnosing the extracardiac extent of tumor, presence of metastases, myocardial infiltration, and compression of cardiac chambers along with pericardial and great vessel involvement. Cardiac MRI is useful to assess tumor volume, tumor burden, mediastinal invasion, and response to therapy. The limitation of CMRI is the cost and dependence on regular electrocardiographic rhythms and cardiac gating.<sup>[6]</sup> Although chest X-ray is not diagnostic, it may show cardiomegaly, infiltrates suggestive of pulmonary edema due to congestive cardiac failure, pleural effusion, lung nodules, cardiac mass, or left hemidiaphragm paralysis.<sup>[12]</sup> An electrocardiogram shows nonspecific changes such as conduction block, right ventricular hypertrophy, atrial fibrillation, and paroxysmal atrial tachycardia. Preoperative transvenous end myocardial biopsy with histological confirmation before surgery is helpful in diagnosis.<sup>[13]</sup>

The incidence of primary cardiac tumors is rare and possess diagnostic and therapeutic challenge even in major cardiac centers. Autopsy studies reveal a 0.02% prevalence of cardiac tumors. The most common benign tumor is myxoma (50%–70%), whereas angiosarcoma (30%) is the most common malignant tumor followed by rhabdomyosarcoma (20%). The clinical presentation depends on the site and infiltration irrespective of tumor type. Urgent surgical treatment is advised to avoid secondary complications. Lymphomas are manifested as sub febrile increase in temperature, weight loss, exhaustion, coughing, and leukocytosis, whereas malignant tumors are accompanied by hemorrhagic pericardial effusion. The clinical representation in the region of atria or atrioventricular valves mimics stenosis of mitral or tricuspid valves. Tumor infiltration of neural pathways can cause arrhythmias, whereas detachment of tumor tissue can lead to stroke. Echocardiography is the first diagnostic procedure. The other diagnostic modalities such as computed tomography or magnetic resonance

imaging are employed if a tumor cannot be confirmed. However, 18F- fluorodeoxyglucose positron emission tomography/computed tomography (FDG-PET/CT) has a sensitivity of over 90% in differentiating benign and malignant tumors. Coronary angiography or CT coronary angiography confirms the diagnosis of coronary artery disease in symptomatic patients. Angiography is also helpful to determine the extent of highly vascular tumors like angiosarcoma. The management of cardiac tumor involves a multidisciplinary team approach, which includes oncologists, radiotherapists, and surgeons. Surgical resection of tumor is the main treatment though the benefit of radiotherapy and chemotherapy is not proven.<sup>[14]</sup> Involvement of the right coronary artery (RCA) requires coronary artery bypass grafting. Reconstruction of cardiac chambers, mitral, and tricuspid valve repair or replacement are performed in case of injury during debulking.<sup>[15,16]</sup> Implantation of an artificial heart can be considered if tumor involves the left heart with no metastases. Heart transplantation is the final treatment of choice provided distant metastasis is ruled out.<sup>[14]</sup>

## CONCLUSION

Cardiac sarcomas remain a challenge to treat due to the rarity and aggressive nature of these tumors. Lack of early symptoms and late presentation does not facilitate early detection of cardiac sarcomas even though advanced imaging techniques are available. Surgery is the gold standard of treatment. The prognosis depends on the histopathology, location, and extent of the specific tumor. These sarcomas have a poor response to adjuvant therapy. Hence, the decision of a cardiac surgeon should keep a balance between obtaining tumor-free margin and leaving behind a functioning heart.

## Declaration of patient consent

Informed consent was obtained from the patient for publication of this case report.

## Financial support and sponsorship

Nil.

## Conflicts of interest

There are no conflicts of interest.

## REFERENCES

1. Butany J, Nair V, Naseemuddin A, Nair GM, Catton C, Yau T. Cardiac tumours: Diagnosis and management. *Lancet Oncol* 2005;6:219-28.
2. Muturi A, Kotecha V, Ruturi J, Muhinga M, Waweru W. High-grade spindle cell sarcoma of the heart: A case report and review of literature. *J Cardiothorac Surg* 2015;10:46.
3. Perchinsky MJ, Lichtenstein SV, Tyers GF. Primary cardiac tumors: Forty years' experience with 71 patients. *Cancer* 1997;79:1809-15.
4. Chitwood WR Jr. Clarence Crafoord and the first successful resection of a cardiac myxoma. *Ann Thorac Surg* 1992;54:997-8.
5. Ibrahim A, Luk A, Singhal P, Wan B, Zavodni A, Cusimano RJ, *et al.* Primary intimal (Spindle cell) sarcoma of the heart: A case report and review of the literature. *Case Rep Med* 2013;2013:461815.
6. Li Z, Hsieh T, Salehi A. Recurrent cardiac intimal (Spindle cell) sarcoma of the left atrium. *J Cardiothorac Vasc Anesth* 2013;27:103-7.
7. Bode-Lesniewska B, Zhao J, Speel EJ, Biraima AM, Turina M, Komminoth P, *et al.* Gains of 12q13-14 and overexpression of mdm2 are frequent findings in intimal sarcomas of the pulmonary artery. *Virchows Arch* 2001;438:57-65.
8. Mehra S, Ibrahim O, Moshiri M, Cahill J, Bhargava P. Spindle-cell sarcoma of the heart: A rare cause for a cardiac mass. *Radiol Case Rep* 2012;7:792.
9. Mayer F, Aebert H, Rudert M, Königsrainer A, Horger M, Kanz L, *et al.* Primary malignant sarcomas of the heart and great vessels in adult patients--A single-center experience. *Oncologist* 2007;12:1134-42.
10. Burke A, Cowan D, Virmani R. Primary sarcomas of the heart. *Cancer* 1992;69:387-95.
11. Putnam J, Sweeny M, Colon R, Lanza L, Frazier O, Cooley D. Primary cardiac sarcoma. *Ann Thorac Surg* 1991;51:906-10.
12. Araoz P, Eklund H, Welch T, Breen J. CT and MR imaging of primary cardiac malignancies. *Radiographics* 1999;19:1421-34.
13. Basso C, Valente M, Poletti A, Casarotto D, Thiene G. Surgical pathology of primary cardiac and pericardial tumours. *Eur J Cardiothorac Surg* 1997;12:730-8.
14. Hoffmeier A, Sindermann JR, Scheld HH, Martens S. Cardiac tumors—Diagnosis and surgical treatment. *Dtsch Arztebl Int* 2014;111:205-11.
15. Bakaeen FG, Jaroszewski DE, Rice DC, Walsh GL, Vaporciyan AA, Swisher SS, *et al.* Outcomes after surgical resection of cardiac sarcoma in the multimodality treatment era. *J Thorac Cardiovasc Surg* 2009;137:1454-60.
16. Ekmektzoglou K, Samelis G, Xanthos T. Heart and tumors: Location, metastasis, clinical manifestations, diagnostic approaches and therapeutic considerations. *J Cardiovasc Med* 2008;9:769-77.