

## A rare cause of acquired immune deficiency syndrome related pancytopenia

Su Bin Kim,<sup>1</sup>

Makeardhwaj Sarvadaman Shrivastava,<sup>1</sup>  
Marianna Strakhan<sup>2</sup>

<sup>1</sup>Department of Medicine, <sup>2</sup>Department of Hematology/Oncology, Albert Einstein College of Medicine, Jacobi Medical Center, Bronx, NY, USA

### Abstract

A 21-year-old male with acquired immune deficiency syndrome, not on highly active antiretroviral treatment (HAART) was admitted after complaining of headache and intermittent diarrhea, found to have Cryptococcal meningitis. During the course of his hospitalization, patient developed pancytopenia. Anemia panel, serologies including Epstein barr virus, cytomegalovirus, and parvovirus were negative. Patient then developed high grade fever with elevated liver enzymes. Blood cultures, urine cultures, stool cultures, and repeat cerebrospinal fluid cultures remained negative. Patient subsequently developed skin lesions which on biopsy showed Kaposi's sarcoma, and upon endoscopy, noted to have gastrointestinal Kaposi's sarcoma involvement. Human herpes virus 8 was positive. Bone marrow biopsy revealed hemophagocytic lymphohistiocytosis. Despite having a concern for patient developing immune reconstitution syndrome which may worsen his meningitis, HAART was initiated and patient's symptoms improved including resolution of fevers and hematological as well as liver abnormalities. Kaposi's sarcoma improved as well.

### Introduction

Hemophagocytic lymphohistiocytosis (HLH) is a clinical entity characterized by hyperinflammation which may be due to primary or secondary causes including infections, autoimmune disorders, malignancies, immunosuppression and organ transplantation.<sup>1</sup> Fever is a common symptom for HLH, and majority of the time, patients are treated for presumed sepsis. In an autopsy study of 56 AIDS patients, 20 percent had histological evidence of HLH.<sup>2</sup> It is a rapidly life threatening syndrome if left untreated,<sup>1</sup> and having it diagnosed earlier will improve survival rate. We are presenting a case of a young male with AIDS and Cryptococcal meningitis who developed HLH.

### Case Report

A 21-year-old male with treatment naïve AIDS (CD4 count and HIV viral load 29/mm<sup>3</sup> and 486,021 copies/mL respectively), presented with intermittent bloody diarrhea and headache. Initial lumbar puncture that was performed on admission with elevated opening pressure. Cryptococcal antigen was positive (1:1024) in cerebrospinal fluid (CSF), and mycology revealed Cryptococcal neoformans. Patient was subsequently initiated on liposomal Amphotericin B and Flucytosine. His stool studies revealed Giardia infection, and patient was started on Flagyl. While receiving his treatment, patient developed pancytopenia (white blood cell count 1.8/nL, absolute neutrophil count of 1080/nL, hemoglobin 7.4 g/dL, hematocrit 24.8% and platelet count 78/nL), which was a new finding compared to his labs on admission. Investigations showed normal levels of folic acid, Vitamin B12, thyroid hormones and methylmalonic acid. Anti-nuclear antibody panel was negative. Serologies for Epstein barr virus (EBV), cytomegalovirus (CMV) and Parvoviruses were negative. Flucytosine was discontinued due to pancytopenia. Patient's fever curve gradually increased despite antibiotic treatment for Cryptococcal meningitis and Giardia. Patient had persistent fevers upto 104°F and chills. His repeat investigations showed newly deranged liver function tests with amino aspartate and amino alanine transaminase levels of 2375 and 832 U/L respectively, total bilirubin of 5.5 mg/dL (direct 4.4 mg/dL) and alkaline phosphatase of 214U/L. Serum ferritin was 13,378 g/L, triglyceride level was 250 mg/dL and fibrinogen level was 410 mg/dL. Multiple sets of blood cultures, blood Mycobacterium, EBV and CMV serologies, urine cultures, sputum cultures, *Pneumocystitis jiroveci* pneumonia, and stool cultures were all negative. His stool ova and parasite revealed Giardia in one sample. Imaging did not reveal any abnormality. Within a week, patient was noted with dark lesions on skin (Figure 1A) and in oral mucosa. Lesions were suspicious for Kaposi's sarcoma. Biopsy was performed which confirmed clinical suspicion [CD31 positive, human herpes virus 8 (HHV-8) Positive, smooth muscle actin negative, desmin negative, S100 negative]. Endoscopy revealed normal esophagus and erythematous mucosa in the stomach. Multiple raised erythematous lesions were found throughout duodenum (Figure 1B). Serology for HHV8 was positive, with viral load being 1.3 million copies/mL. Bone marrow aspiration and biopsy were performed given persistent fever and pancytopenia. Biopsy revealed normal tri-lineage hematopoiesis with increased myeloid: erythroid (M:E) ratio, without any

Correspondence: Su Bin Kim, Department of Medicine, Department of Medicine, Albert Einstein College of Medicine, Jacobi Medical Center, 1400 Pelham Parkway South, Bronx, NY 10461, USA.  
Tel.: +1.718.918.4581.  
E-mail: subin1004@gmail.com

Key words: pancytopenia; acquired immune deficiency syndrome; Kaposi sarcoma; hemophagocytic lymphohistiocytosis; abnormal liver function test.

Acknowledgements: authors would thank Dr. Farnoush Mohammadi (Pathology).

Contributions: SBK was involved in patient diagnosis, direct patient management and care, case write-up, literature search and review, and writing up discussion; MSS was involved in patient diagnosis, direct patient management and care, case write-up, literature search and review; MS was involved in diagnosis, management plan, literature review and discussion write-up.

Conflict of interests: the authors declare no potential conflict of interests.

Conference presentation: New York American College of Physicians poster presentation; February 2013: *Case report of a rare cause of AIDS related pancytopenia.*

Received for publication: 8 May 2014

Accepted for publication: 18 february 2015.

This work is licensed under a Creative Commons Attribution NonCommercial 3.0 License (CC BY-NC 3.0).

©Copyright S.B. Kim et al., 2015  
Licensee PAGEPress, Italy  
*Hematology Reports* 2015; 7:5475  
doi:10.4081/hr.2015.5475

dysplasia or atypical cells. There was a marked increase in marrow histiocytes (Figure 2) with >50% containing ingested hematopoietic elements -myeloid/erythroid precursors, red blood cells and lymphocytes; consistent with diagnosis of HLH. With a high suspicion that our patient's HLH was a result of human immunodeficiency syndrome (HIV) infection, HAART with raltegravir, tenofovir and emtricitabine was initiated. Over the course of one week the hematological and liver function test abnormalities resolved (Figure 3) and fever abated. Patient's Kaposi's skin manifestations have improved as well. Patient was discharged without any complications.

Plan was to initiate therapy for his Kaposi's sarcoma now that liver function tests normalized, however, patient was lost to follow up since his discharge.

## Discussion and Conclusions

Pancytopenia in HIV infected patients may be multifactorial in nature. It may occur secondary to HIV infection itself, can be drug induced, or can be secondary to an underlying concomitant infection or malignancy. Workup of our patient, including a bone marrow biopsy was notable for increased histiocytes with evidence of hemophagocytosis, revealing an underlying HLH which was the likely responsible for his worsening liver function tests, fevers, and pancytopenia.

Hemophagocytic lymphohistiocytosis is a life threatening illness that is characterized by dysregulation of natural killer (NK) T cell function with activation and proliferation of lymphocytes and histiocytes.<sup>3</sup> This leads to uncontrolled and ineffective immune activation, accumulation of activated T cells and histiocytes in many organs,<sup>4</sup> which ultimately leads to cellular damage and multiorgan dysfunction.<sup>5</sup> Macrophages become activated and hemophagocytosis occurs leading to pancytopenia.<sup>5</sup>

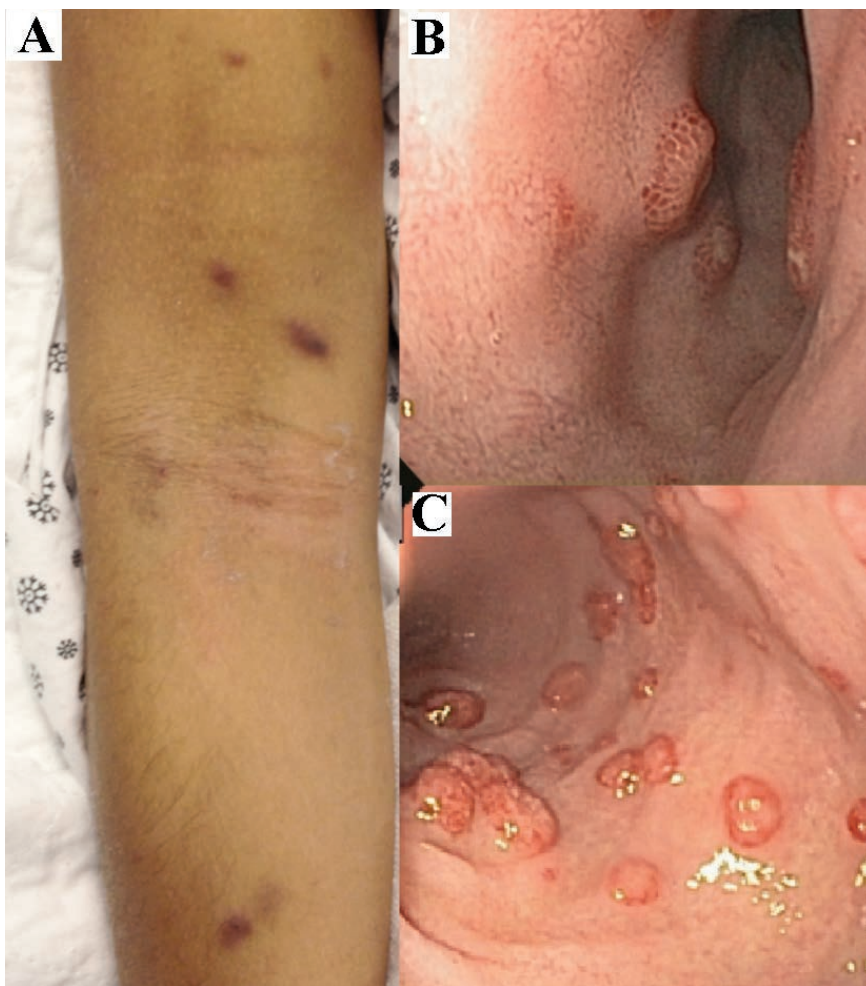Hemophagocytic lymphohistiocytosis is divided into primary and secondary hemophagocytic syndrome with secondary causes being infectious etiologies, HIV being one of them.<sup>5</sup>

Most of the HLH cases diagnosed in HIV patients have been identified in patients with advanced stages of HIV infection and were often found in association with concomitant infections or malignant disease. These patients have approximately 28% recovery rate, which suggests that HIV patients with HLH have a poor prognosis.<sup>6</sup> Worse outcome is seen in patients with CD4 count of less than 200 cells per  $\mu\text{L}$ .<sup>6</sup>

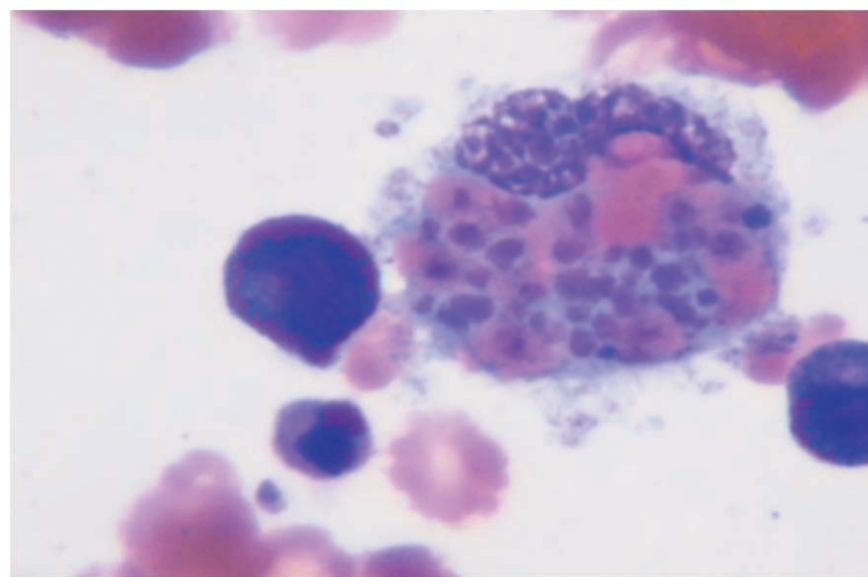
A large body of evidence has found that hemophagocytosis can also be one of the initial presentations of acute HIV infection.<sup>7</sup> Sun *et al.* have presented a case of 7 patients with acute HIV infection and HLH and have found them all to have fever, lymphadenopathy, and hepatomegally or splenomegally at presentation. All the patients survived after supportive care was instituted.<sup>7</sup>

Gotoh *et al.* reported a case of a patient with severe HLH and HIV infection who recovered after HAART. Their patient was similar to our patient as both had untreated HIV and concomitant infection which was treated and improved prior to the development of HLH.<sup>6</sup> The patient reported by Gotoh *et al.* recovered with minor change in the HAART regimen which led to complete resolution of HLH as proven by repeat bone marrow biopsy and normalization of cytopenia.

Our patient had several risk factors for HLH, including Cryptococcal Meningitis, Giardia, and newly developed Kaposi's sarcoma, HHV8



**Figure 1.** A) Kaposi's skin lesions; B) and C) endoscopic picture of duodenal mucosa showing multiple raised erythematous lesions of Kaposi's sarcoma



**Figure 2.** Hemophagocyte on bone marrow biopsy.

positive. HHV8 (Kaposi sarcoma associated herpes virus) is a common viral trigger and may be a contributing factor to our patient's development of HLH.<sup>2</sup> However, there is a strong possibility that the untreated HIV itself was responsible for the development of his HLH as symptoms appeared after treatment for meningitis and *Giardia* as well as prior to development of Kaposi's sarcoma lesions. With initiation of HAART treatment, the opportunistic infections have subsided as did the cytopenia, fevers, and hepatic dysfunction, leading us to believe that the HIV virus itself was the driving force of our patient's HLH.

The differential diagnosis of elevated liver function tests in patients with AIDS can be multifactorial. Some of the etiologies include medication induced, AIDS cholangiopathy, ductopenia, and other hepatic manifestations of AIDS.

Ductopenia, or Vanishing Bile Duct Syndrome (VBDS) is a group of acquired disorders associated with progressive destruction and disappearance of intrahepatic bile ducts and chronic cholestasis.<sup>8</sup> The disease onset may be rapid or gradual depending on the etiology of the VBDS. Most patients have typical manifestations of cholestasis such as pruritis and gallstone formation as well as malabsorption and hyperlipidemia.<sup>8</sup> Multiple infectious causes have been associated with ductopenia.

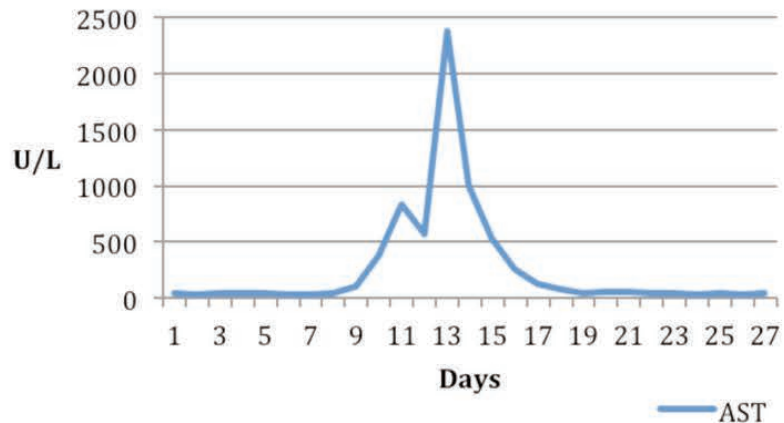
*Cryptosporidium parvum* has been linked as the cause of AIDS cholangiopathy.<sup>8</sup> Treatment depends on proper identification of etiology of ductopenia and withdrawal of offending agent or treatment of the infectious pathogen. Unfortunately, there is no treatment that can lead to biliary regrowth after its loss, thus treatment often centers in supportive care and symptom control.<sup>8</sup>

Given the fact that our patient's liver abnormality was acute in nature, and given rapid deterioration of the patient, we decided not to hold off further invasive procedures and urgently initiated HAART therapy in order to rapidly control patient's worsening clinical state.

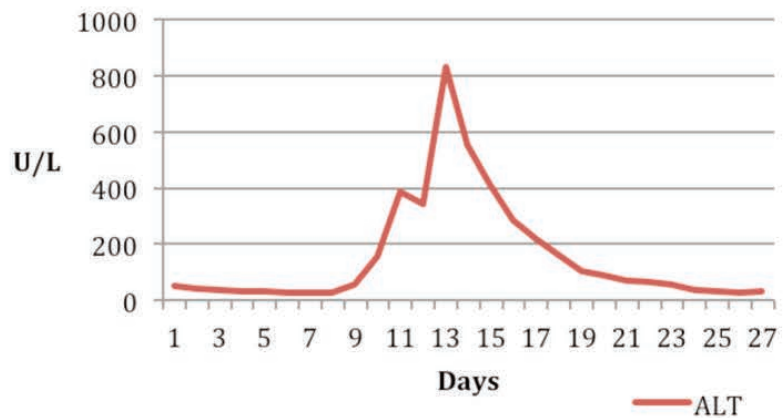
Hemophagocytic lymphohistiocytosis has also been described in several other settings: in Acute HIV seroconversion phase, in the setting of immune reconstitution inflammatory syndrome (IRIS) within 1-3 weeks of initiation of HAART, or 6 weeks after initiation of HAART.<sup>2</sup>

Immune reconstitution inflammatory syndrome, or immune reconstitution disease occurs in 10-27% of patients initiating on HAART therapy.<sup>9</sup> It can be associated with either worsening of previously controlled concomitant opportunistic infection, or *unmasking* of previously not apparent disease after initiation of HAART – leading to inflammatory response.<sup>9</sup> It is difficult to determine who will develop which syndrome, thus, optimally,

## Amino aspartate transaminase (AST)



## Amino alanine transaminase (ALT)



## Total bilirubin

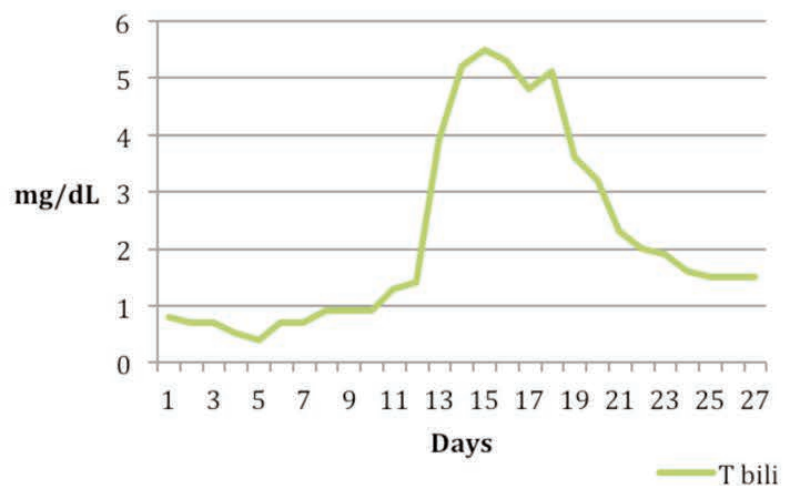


Figure 3. Trend of liver function test throughout the hospital course.



HAART treatment should be started early, before the development of full blown AIDS.<sup>9</sup>

In our review of literature, there were total of 8 cases reported for HIV as the primary infectious cause of HLH. Secondary HLH can manifest with fevers, hepatosplenomegaly, elevated ferritin levels, neurological and skin manifestations and lymph node enlargement.<sup>10</sup> Often the picture is akin to sepsis, so a high degree of suspicion is required to diagnose this syndrome, as prompt initiation of therapy can be life saving. International HLH treatment study group has established the criteria for the diagnosis of HLH,<sup>11</sup> some of which may only become apparent late in the course of disease.<sup>10</sup> Untreated HLH can be rapidly fatal and hence presence of all the criteria is not essential for initiation of therapy.<sup>10</sup> Human immunodeficiency virus (HIV) itself and opportunistic infections associated with HIV are all implicated as potential triggers for HLH.<sup>12</sup> HHV8 is the most common trigger for HLH in patients with HIV/AIDS.<sup>10</sup> Although our patient had HIV induced HLH, presence of Kaposi's lesions in a clinical scenario with HLH features should prompt the search for this entity. Treatment protocols using dexamethasone, etoposide and cyclosporin A (the HLH-94 trial)<sup>13</sup> and intrathecal methotrexate in those not responding to 2 weeks of dexamethasone (the HLH-2004 trial) are recommended for treatment of both secondary as well as primary HLH syndromes.<sup>14</sup> Secondary HLH also may resolve especially if underlying infections or malignancy are treated.<sup>15</sup> It is often difficult to tease out the primary versus secondary HLH.

If treatment targeting etiology for secondary HLH fails, management using treatment protocol should be attempted.

Hemophagocytic syndrome is highly fatal if left untreated.<sup>3</sup> Association between HIV and HLH is rare and likely underdiagnosed due to fact that both conditions share similar clinical and laboratory findings.<sup>3</sup> Delay in diagnosis can potentially lead to fatal outcome since life saving treatment may not be offered in time.<sup>2</sup>

From review of literature, HIV patients with HLH who are treatment *naïve*, should be started on HAART immediately. Development of HLH in patients already on HAART should prompt the physician to switch the regimen without delay.<sup>6</sup>

Treatment of HLH in a patient such as ours with HIV/AIDS can be extremely challenging given the potential for exacerbating opportunistic infections. Additionally, IRIS with initiation of HAART may also further complicate the situation. Despite these caveats, there are case reports of patients responding to initiation of HAART.<sup>16,17</sup> We present an example of such a case where early initiation of HAART was imperative in this patient's outcome. Hence HAART initiation or change in regimen should strongly be considered in AIDS patients with HLH.

## References

1. Janka GE. Familial and acquired hemophagocytic lymphohistiocytosis. *Ann Rev Med* 2012;233-46.
2. Niedt, GW, Schinella RA. Acquired immunodeficiency syndrome. *Clinicopathologic study of 56 autopsies. Arch Pathol Lab Med* 1985;109:727-34.
3. Roupheal NG, Talati NJ, Vaughan C, et al. Infections associated with hemophagocytic syndrome. *Lancet Infect Dis* 2007;7: 814-22.
4. Douka E, Economidou F, Nanas S. Infections associated with the hemaphagocytic syndrome. *Hosp Chronicles* 2012;7: 16-24.
5. Verbsky JW, Grossman WJ. Hemophagocytic lymphohistiocytosis: diagnosis, pathophysiology, treatment, and future perspectives. *Ann Med* 2006;38:20-31.
6. Gotoh M, Matsuda J, Gohchi K, et al. Successful recovery from human immunodeficiency virus (HIV)-associated

haemophagocytic syndrome treated with highly active anti-retroviral therapy in a patient with HIV infection. *Br J of Haematol* 2001;112:1090.

7. Sun HY, Chen MY, Fang CT, et al. Hemophagocytic lymphohistiocytosis: an unusual initial presentation of acute HIV infection. *J Acquir Immune Defic Syndr* 2004;37:1539-40.
8. Reau N, Jensen D. Vanishing bile duct syndrome. *Clin Liver Dis* 2008;12:203-17.
9. Haddow LJ, Moosa MYS, Mosam A, et al. Incidence, clinical spectrum, risk factors and impact of HIV-associated immune reconstitution inflammatory syndrome in South Africa. *PLoS One* 2012;7:e40623.
10. Doyle T, Bhagani S, Cwynarski K. Haemophagocytic syndrome and HIV. *Curr Opin Infect Dis* 2009;22:1-6.
11. Henter JI, Horne A, Arico M. HLH-2004: diagnostic and therapeutic guidelines for hemophagocytic lymphohistiocytosis. *Pediatr Blood Cancer* 2007;48:124.
12. Maakaroun NR, Moanna A, Jacob JT. Viral infections associated with hemophagocytic syndrome. *Rev Med Virol* 2010;20:93-105.
13. Henter JI, Arico M, Egeler RM, et al. HLH-94: a treatment protocol for hemophagocytic lymphohistiocytosis. HLH study Group of the Histiocyte Society. *Med Pediatr Oncol* 1997;28:342.
14. Weitzman S. Approach to hemophagocytic syndromes. *Hematology* 2011;2011:178-83.
15. Janka GE. Familial and acquired hemophagocytic lymphohistiocytosis. *Eur J Pediatr* 2007;166: 95-109.
16. Castilletti C, Preziosi R, Bernardini G, et al. Hemophagocytic syndrome in a patient with acute human immunodeficiency virus infection. *Clin Infect Dis* 2004;38: 1792-93.
17. Chen TL, Wong WW, Chiou TJ. Hemophagocytic syndrome: an unusual manifestation of acute human immunodeficiency virus infection. *Int J Hematol* 2003;78:450-2.