

## CASE REPORT

# Chromosome 22q11.21 and 11p15.4 microdeletions confirmed by high-throughput sequencing analysis in one patient with asymmetric cry syndrome: Case report and review of the literature

Yonghong Pang<sup>1</sup>  | Yang Yu<sup>1</sup> | Xiaoyi Deng<sup>1</sup> | Qian Liu<sup>1</sup> | Junmei Yan<sup>1</sup> | Xiangyu Gao<sup>2</sup>

<sup>1</sup>Neonatal Medical Center, Xuzhou Maternity and Child Health Hospital, Xuzhou, China

<sup>2</sup>Department of Neonatology, Children Diagnosis and Treatment Center of Xuzhou Hospital Affiliated to Southeast University, Xuzhou, China

## Correspondence

Yonghong Pang, Neonatal Medical Center, Xuzhou Maternity and Child Health Hospital. No.46, Heping Road, 221009 Xuzhou, China.  
Email: yhpang007@163.com

## Funding information

This study was supported in part by Xuzhou Science and Technology Development Plan (grant number: KC20081); Jiangsu Provincial Commission of Health and Family Planning Plan (grant number: F202058); Jiangsu Maternal and Child Health Association project (grant number: FYX201906); Xuzhou Medical University Research Project (grant number: 2018KJ19).

## Abstract

Healthcare providers treating newborns with asymmetric cry syndrome should consider 22q11.2 microdeletion within the differential diagnosis list and order appropriate genetic testing.

## KEYWORDS

asymmetric cry syndrome, high-throughput sequencing, microdeletion

## 1 | INTRODUCTION

The case report describes a newborn case of asymmetric cry syndrome (ACS) based on clinical presentation(s) and microdeletions of 22q11.21 and 11p15.4 using high-throughput sequencing analysis. This finding has implications for ACS

diagnosis and overcomes the limitations associated with FISH by using high-throughput sequencing across the whole genome.

Asymmetric cry syndrome is a genetic abnormality and is one of the recognized disorders of chromosome 22q11.2 deletion syndrome (22q11.2 DS). It was first described by

Yonghong Pang and Yang Yu contributed equally to this work.

This is an open access article under the terms of the Creative Commons Attribution NonCommercial License, which permits use, distribution and reproduction in any medium, provided the original work is properly cited and is not used for commercial purposes.

© 2021 The Authors. *Clinical Case Reports* published by John Wiley & Sons Ltd.

Cayler<sup>1</sup> in 1969, hence the name “Cayler cardiofacial syndrome.” A microdeletion of chromosome 22q11.2 is found in most of the patients with conotruncal anomaly face syndrome, Di George's syndrome (DGS), and velocardiofacial syndrome. Patients with 22q11.2 deletion syndrome may have several clinical abnormalities and different degrees of organ commitment, which include thymus dysfunction, cardiac diseases, immunodeficiencies, and other clinical problems.<sup>2</sup> ACS is a rare syndrome with asymmetric crying faces (ACF) in patients with congenital heart diseases.

The age at presentation of ACS varies according to specific anomalies in the patient. ACS in neonates is a rare condition and often manifested as clinically significant conotruncal defects, such as subaortic stenosis with malalignment of infundibular septum, truncus arteriosus, and tetralogy of Fallot.<sup>3</sup>

Asymmetric cry syndrome is a rare disease in China. Previously, no heart murmurs were reported to be associated with the condition, and the facial phenotypical features were so trivial that the patients were thought to be normal by their parents until a diagnosis was made. Thus, early diagnosis by fluorescence in situ hybridization (FISH) might be more difficult when a case has no evidence of chromosomal deletion of 22q11.2. According to a recent study, 31% of patients with 22q11 deletion syndrome (DS) were not diagnosed till when they are 10 years of age.<sup>4</sup>

To make an early diagnosis, it is important for clinicians to be aware of this syndrome and to familiarize themselves with related extracardiac manifestations. 22q11.2 DS is traditionally diagnosed with FISH. Array comparative genomic hybridization (aCGH) is considered as one of the alternatives in diagnostic modalities.<sup>5</sup> The application of high-throughput sequencing to comprehensively analyze microdeletions of 22q11.2 DS has not yet been reported in the literature. Earlier studies reported that Cayler Cardiofacial syndrome involves 22q11.2 DS, in which a small part of chromosome 22 was missing. Hence, in this case

report, a novel ACS with 22q11.21 and 11p15.4 microdeletions confirmed by high-throughput sequencing analysis is presented.

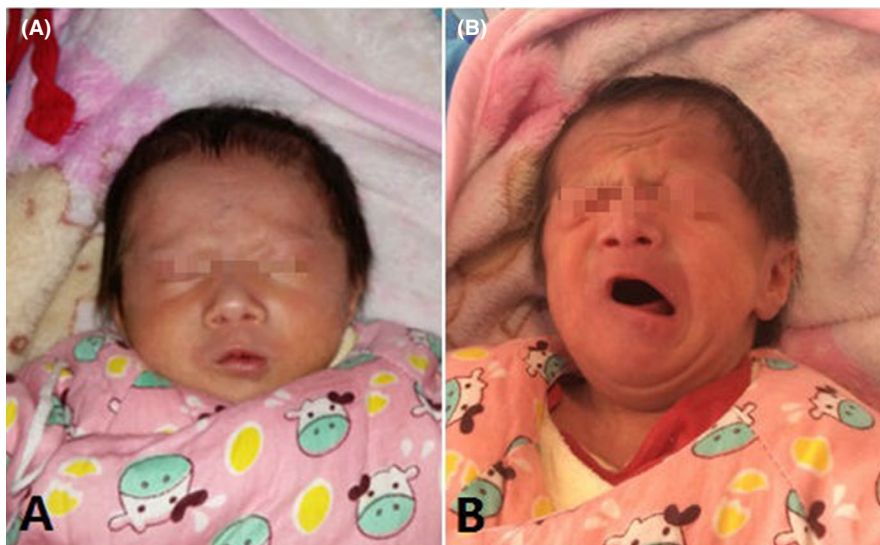## 2 | CASE PRESENTATION

### 2.1 | Clinical data

A 10-minute-old newborn male baby was admitted to our neonatal intensive care unit (NICU) department due to dyspnea. The baby was born to 20-year-old G1P1 preeclamptic (treated) mother at 34 weeks and 6 days of gestation through cesarean section and weighed 1.8 kg (weight centile less than the 10th). The baby had an Apgar score of 7-8 at 1 minute and then 5 minutes and was transferred to the NICU due to an increasingly worsening condition. There was no maternal infection(s), and no family history of hereditary, neurological, or systemic diseases was reported from the baby's paternal or maternal side.

On examination, the baby was fully conscious with a body temperature of 35.8°C, heart rate of 130/min, and respiratory rate of 58/min. Breathing sounds were clear and the heartbeat was regular, without any murmurs. There was nothing abnormal detected on neurological examination. Further inspection revealed no facial abnormalities, no cleft lip or palate, no low set or overfolded ears, no hypertelorism, no narrow palpebral fissures, no limb anomalies like syndactyly and polydactyly, no hypospadias, and no imperforate anus.

Due to the increasingly worsening condition, the infant was treated with nasal continuous positive airway pressure (NCPAP). Besides, a natural bovine surfactant with 100 mg/kg of phospholipids was given through an “endotracheal tube” to treat the respiratory distress syndrome (RDS) as manifested on the chest X-ray. Follow-up examination showed improvements in the saturations.



**FIGURE 1** Photographs of the neonate while sleeping and during crying. A, No asymmetry of face while sleeping; B, Asymmetry of the face with deviation of the mouth towards the left when the neonate is crying. The lower right facial weakness is evident only during crying, when the lower lip is pulled towards the normal or functioning side

The baby continued to perform well on gentle invasive ventilation, maintaining saturations of above 90%. On day 7 of admission, a heart murmur was discovered during routine physical examination. Meanwhile, his lower lip was pulled downwards deviating toward the left during a crying episode, but there was no facial asymmetry during sleeping or at rest (Figure 1). Furthermore, the baby had no difficulty in closing eyes and had normal forehead wrinkling and sucking movements which ruled out a possibility of facial nerve palsy. With these symptoms, ACS was preliminarily considered and so further investigations were performed. Cranial ultrasound showed a grade 1 periventricular hemorrhagic infarction (PVHI) and bilateral ventriculomegaly. Additionally, an echocardiogram revealed membranous ventricular septal defect (5.5 mm), multiple atrial septal defects (2.0 and 1.4 mm), and mild pulmonary arterial branch stenosis. The baby was examined with high-throughput sequencing analysis, which showed microdeletions of chromosomes 22q11.21 and 11p15.4 (Figure 2). Notably, a 2.92 Mb of chromosome 22q11.21 (18880001-21800000) was deleted, which included 75 RefSeq genes. In addition, a 0.12 Mb of chromosome 11p15.4 (10080001-10200000) was deleted, which contained 1 RefSeq gene. The final diagnosis is ACS. He was then discharged in a healthy condition and has been on regular follow-up since that time.

## 2.2 | High-throughput sequencing

With the approval of the Medical Ethics Committee of the Xuzhou Maternity and Child Health Hospital and after

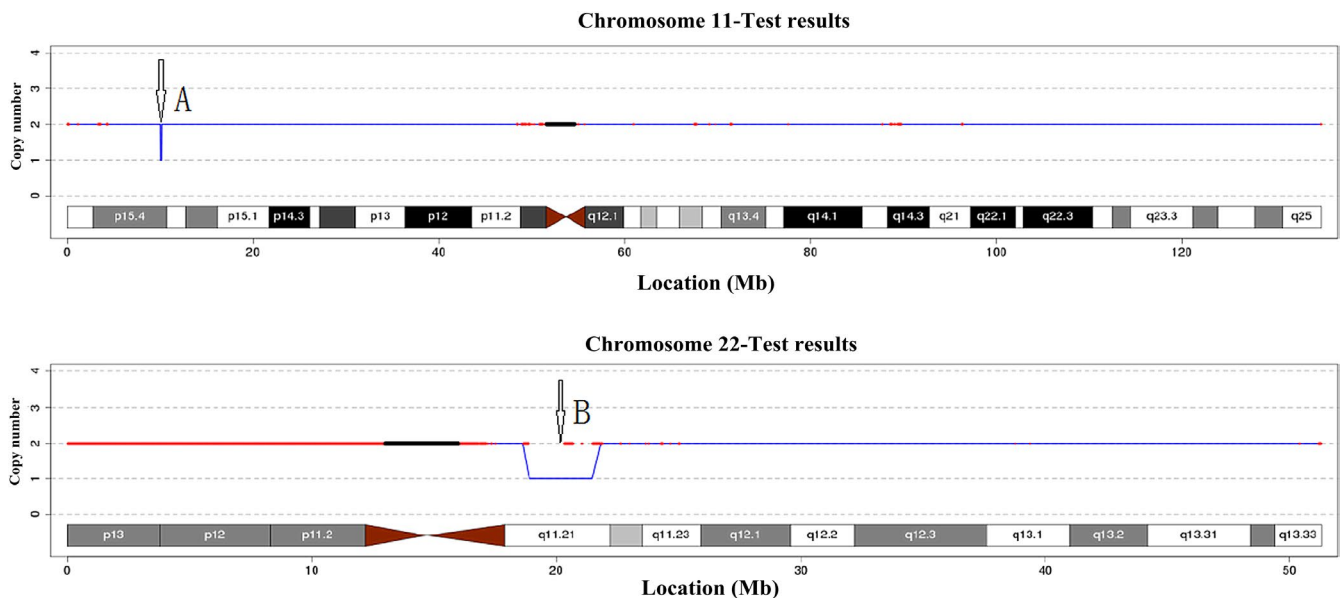
obtaining written informed consent from the parents of the patient, DNA was isolated from peripheral blood samples obtained from the patient. High-throughput sequencing was performed using the nextseqcn500 platform following the manufacturer's instructions (Berry Genomics).

## 3 | DISCUSSION

The general features of 22q11.2 DS vary widely (more than 180 phenotypic presentations) and include Di George's syndrome, Shprintzen's syndrome, and Cayler cardio-facial syndrome. The syndromes were named separately after their first description by the authors. Later, with the advancements in the diagnostic methods in the field of genetics, it was found that the 22q11.2 was deleted in all these syndromes. They are currently grouped under "the 22q11.2 deletion syndromes," as it is difficult to choose a single term.

22q11.2 DS is one of the most frequently encountered interstitial deletion syndromes in the population, with an estimated frequency of 1/4000-5000.<sup>6</sup> Despite usually sporadic and autosomal dominant inheritance, it has been reported in 10%-20% of the patients.<sup>7</sup>

Hypoparathyroidism and hypothyroidism are commonly observed in patients with 22q11.2 deletion and require much attention. Hypoparathyroidism is the first hormonal disturbance recognized in DGS and is documented by aplasia and hypoplasia of the parathyroid glands during surgery or autopsy. Furthermore, hypocalcemia can occur transiently during the neonatal stage with symptoms of seizures, tremors, or tetany, which mainly occur due to low parathyroid



**FIGURE 2** Microdeletions confirmed by high-throughput sequencing across the whole genome. 0.12 Mb deletion of Chromosome 11p15.4 (10080001-10200000) which contains 1 RefSeq gene (at arrow A). 2.92 Mb deletion of Chromosome 22q11.21 (18880001-21800000), which included 75 RefSeq genes (at arrow B)

reserve and abrupt cessation of maternal calcium supply after birth. In our case, serum calcium level was normal (2.3 mmol/L, reference range, 2.1–2.7 mmol/L), and no hypocalcemic symptoms of seizures, tremors, or tetany were observed on admission, which ruled out the possibility of hypocalcemia due to hypoparathyroidism. Although hypocalcemia may not be present during the neonatal period,<sup>8</sup> studies have shown that it can occur at any time during childhood,<sup>4,9</sup> adolescence,<sup>10</sup> and even in adulthood.<sup>11,12</sup> This is likely due to the recurrence of hypoparathyroidism precipitated by increased metabolic demand and acute illness during pregnancy, surgery, infection, or any physiologic stress conditions. Regular lifelong follow-up of calcium, magnesium, and PTH levels are required in patients with 22q11DS.<sup>13</sup> Calcium and vitamin D supplements are recommended to patients with 22q11DS, regardless of whether they have been diagnosed with hypocalcemia or not. However, iatrogenic hypercalcemia resulted in renal calculi and renal failure, and so should be avoided.<sup>11</sup>

Immunodeficiency has been reported in 80% of the patients with 22q11 syndrome. As a result of thymic hypoplasia, cell-mediated immunity is usually involved with 22q11DS, decreasing the T-cell numbers and functions. However, disorders of humoral immunity might also occur. Waters et al<sup>14</sup> reported a case of pneumonia in a 13-month-old male child with partial DGS, and the child died after inadvertently receiving live viral vaccines. Recently, Matsuoka<sup>15</sup> reported the first case of a teenage patient with chromosome 22q11.2 DS who died due to overwhelming postsplenectomy infection (OPSI) by *Streptococcus pneumoniae* despite appropriate prevention by pneumococcal vaccine. As such, it is appropriate to check immunoglobulin levels in the patient before vaccinations.

Congenital heart defects are one of the main clinical features of 22q11DS. Although serious cardiac anomalies were present in most of the patients in earlier studies, their prevalence accounted for about 40% according to the recent papers.<sup>11</sup> Interestingly, our patient had a ventricular septal defect and two atrial septal defects which warranted ongoing follow-up visits.

Some follow-up studies revealed that the frequency of psychomotor retardation and speech disorders was increased.<sup>16</sup> However, information regarding long-term outcomes and older age ranged in ACS has been limited in China. Our patient showed a normal neonatal behavioral neurological assessment (NBNA) score at a corrected gestational age of 41 weeks and his physical index was between P10–P90, but he still had ACF. During the final evaluation, he was aged 2 years 6 months, and had a developmental delay (height: 80 cm; and body weight: 11 kg), and speech deficits. However, the patient's intellectual level, cognitive and adaptive functioning and motor function were normal. The patient had undergone intracardiac repair during the prior month

which necessitated ongoing follow-up visits. The best-case scenario involves early interventions for developmental delay and learning difficulties. Parents required counseling due to long-term outcomes, as deletion of 22q11.2 is associated with learning difficulties and mental retardation.

Previously, karyotyping results by GTG banding were normal in most ACF patients. Recently, more sophisticated techniques such as FISH have been replaced by karyotyping studies in most laboratories. It is therefore not surprising that several ACF cases with chromosome 22q11 microdeletions have been or continue to be reported.<sup>8</sup> Some authors, therefore, suggested that newborns with ACF require additional screening of 22q11.2 DS.<sup>17</sup> In our case, genetic investigations were performed to exclude any underlying syndrome caused by 22q11 deletion. Notably, high-throughput sequencing analysis revealed two microdeletions of chromosomes 22q11.21 and 11p15.4, respectively. This, coupled with the clinical presentation, confirmed the diagnosis of “ACF” as a result of hypoplasia of the depressor anguli oris muscle.

Previous studies have reported that children diagnosed with Cayler Cardio-facial syndrome have an underlying condition called 22q11.2 DS, in which a small part of chromosome 22 is absent. More importantly, we detected additional chromosomal microdeletions in 11p15.4 in our patient. There are no reports of this copy number variant (CNV) at 11p15.4 in the public databases and multiple peer-reviewed publications, such as Online Mendelian Inheritance in Man (OMIM), human genome browsers (UCSC, Ensembl), Database of Genomic Variants (DGV), Database of Chromosomal Imbalance and Phenotype in Humans Using Ensembl Resources (DECIPHER) and PubMed. Only one gene (SBF2) was reported within this CNV. Moreover, little is known about its function potentially related to ACS. This CNV is classified as a variant of uncertain significance (VOUS) because of those mentioned above. As the literature and databases continue to expand, a wide spectrum of initially reported VOUS can be reclassified to either benign variants or pathogenic variants. Only by submitting and sharing data will the clinicians can accurately interpret the clinical consequence of CNVs.

Asymmetric cry syndrome is traditionally diagnosed using FISH with commercial probes. It is extremely accurate but limited to only one single-target sequence. Interestingly, our results showed the effectiveness of high-throughput sequencing, which overcame the limitations of FISH in terms of diagnostic yield and allowed whole-genome screening and detection of a larger number of deletions and/or duplications in ACS patients.

In conclusion, our report reinforces the fact that facial phenotypic and cardiac anomalies are manifestations associated with ACS. However, confirmation of this disease requires further genetic investigations. Apart from a microdeletion of chromosome 22q11.21, a novel microdeletion

of chromosome 11p15.4 was found in our case. We, therefore, suggest that newborns with ACS should be screened with high-throughput sequencing analysis across the whole-genome, which is more advantageous over the FISH technique and could contribute to further research.

## ACKNOWLEDGMENT

Published with written consent of the patient.

## CONFLICT OF INTEREST

None declared.

## AUTHOR CONTRIBUTION

YP was responsible for high-throughput sequencing data analysis and interpretation of sequence variants and drafting the manuscript. YY: managed the patient. XD: designed the report. QL and JY were involved in the acquisition, analysis, and interpretation of clinical data; XG was responsible for manuscript editing. All authors have reviewed the manuscript and approved the final version to be submitted.

## ETHICAL APPROVAL

We obtained the informed consent for information of the parents in this study.

## ORCID

Yonghong Pang  <https://orcid.org/0000-0003-0491-5390>

## REFERENCES

- Cayler GG. Cardiofacial syndrome. Congenital heart disease and facial weakness, a hitherto unrecognized association. *Arch Dis Child.* 1969;44(233):69-75. <https://doi.org/10.1136/adc.44.233.69>
- Kobrynski LJ, Sullivan KE. Velocardiofacial syndrome, DiGeorge syndrome: the chromosome 22q11.2 deletion syndromes. *Lancet.* 2007;370(9596):1443-1452. [https://doi.org/10.1016/S0140-6736\(07\)61601-8](https://doi.org/10.1016/S0140-6736(07)61601-8)
- Hanneman K, Newman B, Chan F. Congenital variants and anomalies of the aortic arch. *Radiographics.* 2017;37(1):32-51. <https://doi.org/10.1148/rg.2017160033>
- Friedman N, Rienstein S, Yeshayahu Y, Gothelf D, Somech R. Post-childhood presentation and diagnosis of DiGeorge syndrome. *Clin Pediatr.* 2016;55(4):368-373. <https://doi.org/10.1177/0009922815591090>
- Bahamat AA, Assidi M, Lary SA, et al. Use of array comparative genomic hybridization for the diagnosis of digeorge syndrome in saudi arabian population. *Cytogenet Genome Res.* 2018;154(1):20-29. <https://doi.org/10.1159/000487094>
- Scambler PJ. The 22q11 deletion syndromes. *Hum Mol Genet.* 2000;9(16):2421-2426. <https://doi.org/10.1093/hmg/9.16.2421>
- Bassett AS, McDonald-McGinn DM, Devriendt K, et al. Practical guidelines for managing patients with 22q11.2 deletion syndrome. *J Pediatr.* 2011;159(2):332-339. <https://doi.org/10.1016/j.jpeds.2011.02.039>
- Pawar SJ, Sharma DK, Srilakshmi S, Reddy Chejeti S, Pandita A. Cayler cardio-facial syndrome: an uncommon condition in newborns. *Iran J Pediatr.* 2015;25(2):e502. <https://doi.org/10.5812/ijp.502>
- Fu CH, Leung C, Kao CH, Yeh SJ. Noncardiac DiGeorge syndrome diagnosed with multiplex ligation-dependent probe amplification: a case report. *J Formos Med Assoc.* 2015;114(8):769-773. <https://doi.org/10.1016/j.jfma.2012.08.001>
- Yoo DY, Kim HJ, Cho KH, Kwon EB, Yoo EG. Delayed diagnosis of 22q11 deletion syndrome due to late onset hypocalcaemia in an 11-year-old girl with imperforated anus. *Ann Pediatr Endocrinol Metab.* 2017;22(2):133-138. <https://doi.org/10.6065/apem.2017.22.2.133>
- Fung WL, Butcher NJ, Costain G, et al. Practical guidelines for managing adults with 22q11.2 deletion syndrome. *Genet Med.* 2015;17(8):599-609. <https://doi.org/10.1038/gim.2014.175>
- Maldjian P, Sanders AE. 22q11 Deletion syndrome with vascular anomalies. *J Clin Imaging Sci.* 2018;8:1. [https://doi.org/10.4103/jcis.JCIS\\_66\\_17](https://doi.org/10.4103/jcis.JCIS_66_17)
- Cheung EN, George SR, Costain GA, et al. Prevalence of hypocalcaemia and its associated features in 22q11.2 deletion syndrome. *Clin Endocrinol.* 2014;81(2):190-196. <https://doi.org/10.1111/cen.12466>
- Waters V, Peterson KS, LaRussa P. Live viral vaccines in a DiGeorge syndrome patient. *Arch Dis Child.* 2007;92(6):519-520. <https://doi.org/10.1136/adc.2006.097493>
- Matsuoka K, Yanagihara I, Kawazu Y, et al. Fatal overwhelming postsplenectomy infection due to *Streptococcus pneumoniae* serotype 10A with atypical polysaccharide capsule in a patient with chromosome 22q11.2 deletion syndrome: a case report. *J Infect Chemother.* 2019;25(3):192-196. <https://doi.org/10.1016/j.jiac.2018.07.015>
- Cancrini C, Puliafito P, Digilio MC, et al. Clinical features and follow-up in patients with 22q11.2 deletion syndrome. *J Pediatr.* 2014;164(6):1475-1480. <https://doi.org/10.1016/j.jpeds.2014.01.056>
- Pasick C, McDonald-McGinn DM, Simbolon C, Low D, Zackai E, Jackson O. Asymmetric crying facies in the 22q11.2 deletion syndrome: implications for future screening. *Clin Pediatr.* 2013;52(12):1144-1148. <https://doi.org/10.1177/0009922813506606>

**How to cite this article:** Pang Y, Yu Y, Deng X, Liu Q, Yan J, Gao X. Chromosome 22q11.21 and 11p15.4 microdeletions confirmed by high-throughput sequencing analysis in one patient with asymmetric cry syndrome: Case report and review of the literature. *Clin Case Rep.* 2021;9:e04072. <https://doi.org/10.1002/ccr3.4072>